



CODEN [USA]: IAJ PBB

ISSN : 2349-7750

## INDO AMERICAN JOURNAL OF PHARMACEUTICAL SCIENCES

SJIF Impact Factor: 7.187

Available online at: <http://www.iajps.com>

Research Article

### RESULTS OF SACRAL PRESSURE SORES SURGICAL CLOSURE BY GLUTEAL SKIN FLAP

Dr. Hammal khan<sup>1</sup>, Dr Muhammad Anwar<sup>2</sup>, Dr Muhammad Bilal<sup>3</sup>, Dr Gul Muhammad<sup>4</sup>,  
Dr Arif mehmood<sup>5</sup>

<sup>1</sup>PGR Plastic surgery, Bolan Medical Complex Hospital, Quetta.

**Article Received:** October 2021    **Accepted:** November 2021    **Published:** December 2021

**Abstract:**

***Aim:** Pressure ulcers are a long-term medical problem; it was even found during the autopsy of Egyptian mummies. This prospective study was conducted to evaluate the surgical outcome of sacral pressure ulcer closure with gluteal skin flaps.*

***Place and Duration:** In the Plastic Surgery department of Bolan Medical Complex Hospital, Quetta for six months duration from April 2021 to September 2021.*

***Methods:** The study included 22 patients with stage III and IV pressure ulcers. More than two-thirds (68.2%) of the ulcers were stage III, and more than three-quarters (77.3%) had local signs of infection. While the mean horizontal and vertical length of the cavities before excision were 10.4 and 8.8 cm, respectively, after excision of the dead and dead tissue it increased to 12.6 and 10.6 cm, respectively. The mean medial lobe shift was 6.3 cm.*

***Results:** Postoperative observation of the flap revealed no infection, seroma, or hematoma in any of the patients. Only 2 (9.1%) patients had marginal flap loss. In two cases, marginal flap defects were excised and a direct suture was applied (secondary closure). Over 90% of the patients had good results.*

***Conclusions:** The study found that the gluteal flap gives a good result in the majority of patients with large cruciate wounds, with almost no complications and recurrences. The gluteal flap has advantages such as preserving the musculature, less morbidity at the site of collection, versatility in design, and less extraction effort.*

**Key words:** *pressure ulcers, gluteal flap, cross dressing.*

**Corresponding author:**

**Dr. Hammal khan,**

*PGR Plastic surgery, Bolan Medical Complex Hospital, Quetta*

QR code



*Please cite this article in press Hammal khan et al, Results Of Sacral Pressure Sores Surgical Closure By Gluteal Skin Flap., Indo Am. J. P. Sci, 2021; 08(12).*

**INTRODUCTION:**

Pressure ulcers are a difficult problem due to the high rate of wound complications and recurrences. Pressure ulcers place a significant burden on health resources and society (in terms of mortality and morbidity), with costs reaching \$ 6 billion annually [1-2]. Currently, it is an axiom that, in addition to the neuropathic factor and shear forces, the most important factor in the aetiology of pressure ulcers is ischemic necrosis resulting from persistent excessive pressure on bone protrusions. Sacral pressure ulcers are more common in patients who are breastfeeding in a supine position<sup>3</sup>. It is estimated that in the supine position, the maximum pressure on the sacrum is in the range of 40 to 60 mm Hg. Malnutrition, anaemia, infection, and chronic disease can also contribute to it by altering blood flow and delaying wound healing [4]. The necrosis at skin level is usually slight compared to the necrotic area of the bone and resembles an inverted cone. The following surgical principles should be considered:

- Complete excision of the wound, surrounding the wound and the underlying bursa.
- The bony prominences below are removed until healthy bleeding bone remains.
- Rejuvenation of the defect with healthy skin, including adequate subcutaneous cushioning.
- It is best to have a wide flap to prevent seams and minimize stress in pressure areas.
- Avoid disturbing adjacent rib areas as this may be necessary in the future [5-6].

The ideal cover for bedsores is to supplement the lost tissue, i.e., skin and subcutaneous tissue. The use of a flap of the buttock skin to close the pressure ulcers in the sacral area is ideal. It is considered the standard of care for the first-line therapy for sacral pressure ulcers that have failed with conservative treatment [7-8]. Gluteal flaps were used as originally described by Ger (1971). There are different types of buttock flaps that can be based on the flap transfer method, such as island flaps, VY plasty, rotation flaps, and depending on the tissue types involved, such as the skin flap or the myocutaneous flap [9]. Recently, gluteal flaps have been successfully used to close defects in the sacral region of the sores. The advantages of the gluteal skin flap in the reconstruction of sacral pressure ulcers are as follows:

- Ensures adequate blood supply in the case of a long-lasting –

- The likelihood of functional deformity in the donor area is lower.
  - Better reconstruction of the correct anatomical position in bone prominences
  - It does not rule out the use of other flaps to reconstruct recurrent ulcers.
  - Design versatility
  - Provides large flap, easy to lift, possible re-rotation.
- Despite possible flap defects, the resulting suture line

is directly above the sacrum in the midline, the bilateral gluteal flaps (upper and lower pedicles of the gluteal vessels) are horizontal to cover defects in the sacrum as VY progression [10-11]. Therefore, this study aims to evaluate the results of bilateral gluteal flaps in the treatment of cruciate wounds.

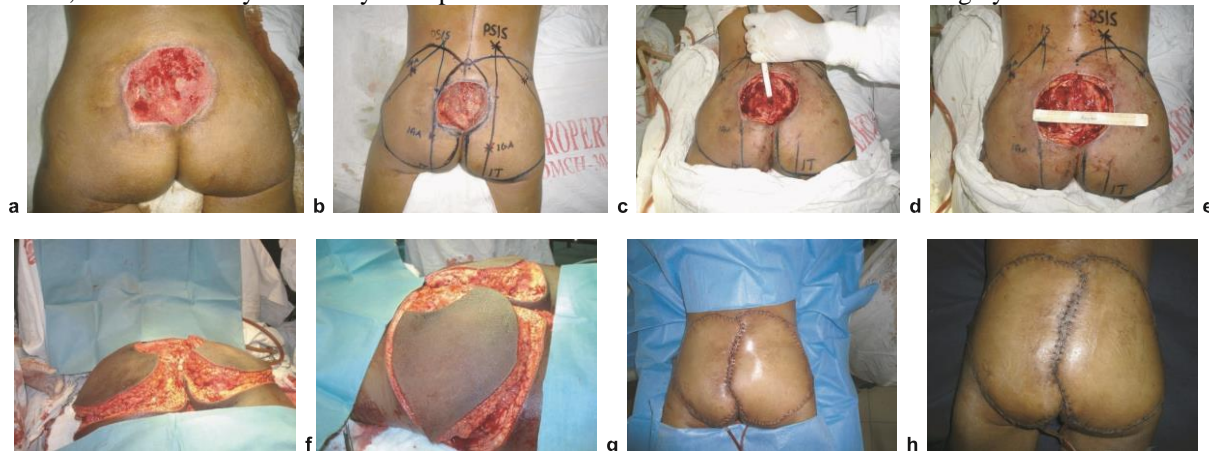
**METHODS:**

This prospective interventional study was conducted in the Plastic Surgery department of Bolan Medical Complex Hospital, Quetta for six months duration from April 2021 to September 2021. The study included 22 patients with stage III and IV pressure ulcers. All patients were prepared with nutritional aid, anaemia was corrected with blood transfusions, and wound infections were controlled with antibiotics and daily bandages based on culture and drug susceptibility testing. The operation was performed under spinal anaesthesia. The ulcer has been removed. This involved removing all scar tissue beneath the bursa and calcified soft tissues down to healthy tissue. The bone spurs were removed and the unevenness from the osteotomy was smoothed with a scraper to obtain a smoothly contoured sacrum. Adequate haemostasis has been achieved. The contour of the flap planned from the lateral to the medial in accordance with the size and direction of the excised area. The superior and inferior gluteal arteries were identified using anatomical landmarks such as the upper posterior iliac spine, the greater trochanter of the femur, and the sciatic tuberosity as surface markers. The superior gluteal artery (PEG) was marked on the skin of the hip one-third as far as it was, in a line drawn from the upper posterior iliac spine to the upper part of the greater trochanter. Similarly, the inferior gluteal artery (IGA) was marked on the skin of the hip at two-thirds of the length of the line running from the superior posterior iliac spine to the ischial tuberosity. The skin is designed as a convergent V-Y progression at its base along the sacrum and its sides along the upper and lower boundaries of the gluteus maximus muscle at the site of its introduction into the greater trochanter. A skin incision was made according to the flap design. The flaps were moved inwards as required by the defect. The wound was closed mainly with layers of low negative suction drainage. All patients followed the standard postoperative regimen which included:

- maintaining negative suction drainage until less than 10 cm<sup>3</sup> of fluid was produced in 24 hours
- maintaining a low-residue diet for the first week and avoiding pressure on the flap
- maintenance to accelerate the healing process wounds by nourishment, hydration and anemia control.
- According to the post-operative wound swab culture and sensitivity report, intravenous antibiotic therapy

was continued for 6 hours, then for 12 hours for 24 hours, and then every other day. All patients were

instructed to come for follow-up visits the first, third and sixth months after surgery to see the result.

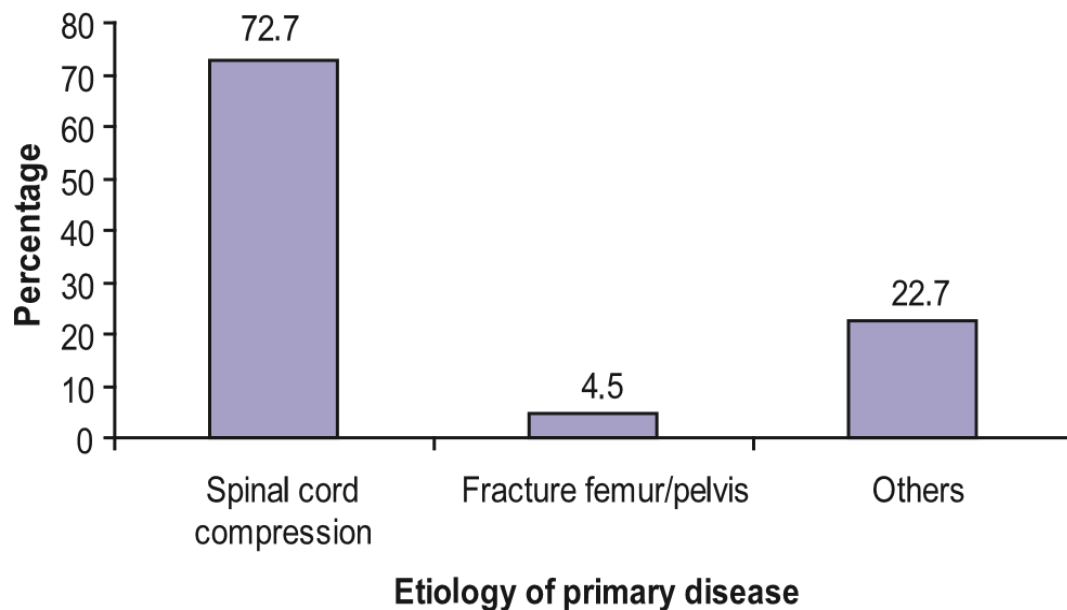


**Fig.-1:** a - Sacral pressure sore, b - Gluteal skin flap design, c - Excision of bony prominences, d - Defect created after excision, e - Elevation of Gluteal skin flap, f - Elevation of Gluteal skin flap, g - At the completion of surgery, h - 3<sup>rd</sup> Post operative day.

### RESULTS:

The mean age of the patients was 34.5 (range 14 to 60 years). A male predominance was observed with a male to female ratio of 3: 2. Primary and secondary education accounted for approximately one third (31.8%), and 27.3% of patients were illiterate. In

terms of occupation, approximately one third (31.8%) were farmers, and 22.7% were students. Approximately three-quarters (72.7%) of patients were bedridden with spinal cord injury, 4.5% with hip or pelvic fractures, and 22.7% for other reasons (Fig. 2).



**Fig. 2:** Distribution of patients by etiology of primary disease (underlying disease)

The mean horizontal and vertical length of the defect after removal of the dead tissue was 12.6 cm and 10.6 cm, respectively. The mean medial lobe shift was 6.3 cm.

**Table-I: Distribution of patients by characteristics of lesion (n = 22)**

Characteristics of lesion	Frequency (%)	Mean $\pm$ SD	Range
Stage of ulcer	15(68.2)	-	-
Stage-III	07(31.8)	-	-
Stage-IV	-	10.4 $\pm$ 2.6	7 – 15
Horizontal length of defect before excision(cm)	-	8.8 $\pm$ 1.8	5 – 12
Vertical length of defect before excision (cm)	17(77.3)	-	-
Local infection	22(100.0)	-	-
Discharge	7(31.8)	-	-
Bone exposed	-	-	-

The mean operative time was 168.4 minutes. All patients required blood transfusions before or during surgery (Table II)

**Table-II: Distribution of patients by their Per operative findings (n = 22)**

Per operative findings	Mean $\pm$ SD	Range
Horizontal length of defect after excision (cm)	12.6 $\pm$ 2.4	10 – 16
Vertical length of defect after excision (cm)	10.6 $\pm$ 2.4	7 – 14
Medial advancement of flap (cm)	6.3 $\pm$ 1.2	5 – 8
Operative time (min)	168.4 $\pm$ 38.3	100 – 245

In-hospital patient outcomes showed that only 2 (9.1%) patients had a medial marginal flap loss (<1 cm). No patient had infection, seroma, hematoma, or wound dehiscence in post-operative flap monitoring (Table III).

**Table-III: Distribution of patients by postoperative complications (n = 22)**

In-hospital outcome	Frequency (%)	Median $\pm$ SEM	Range
Flap loss	-	-	-
Marginal loss	2(9.1)	-	-
No loss	20(90.9)	-	-
Infection	0(0.0)	-	-
Seroma	0(0.0)	-	-
Hematoma	0(0.0)	-	-
Wound dehiscence	0(0.0)	-	-

In two patients, a material with a marginal flap defect was excised and a secondary suture was inserted (Table IV). Medial marginal necrosis was saved by cutting the necrotic border and closing the wound with secondary sutures.

**Table-IV: Management of complications (n = 22)**

Management of complications	Frequency	Percentage
Conservative	0	00.0
Excision and secondary suturing	2	09.1
Excision and advancement	0	00.0
Reconstruction with alternate procedure	0	00.0

During the follow-up period, none of the patients relapsed.

**DISCUSSION:**

Seeking better outcomes in reconstructive surgery, surgeons have used various flap techniques to achieve perfection in form and function (Geddes et al., 2003). Sacral pressure ulcers are common "sores" seen in bedridden and coma patients in medical and surgical emergencies and are especially common in paraplegic patients [12-13]. It was found that the majority of these patients were breastfed in the supine position without timely and appropriate posture changes due to ignorance and insensitivity. In the present study, with regard to the etiology of primary diseases in which patients were bedridden enough to develop sacral ulcers, approximately 72.7% were due to traumatic compression of the spine and 4.5% to femoral fractures and pelvic disease and 22% of meningitis, cerebrovascular disease, transverse myelitis etc. For these primary diseases, about three-quarters received conservative treatment, less than a quarter received surgery, and very few patients received treatment. This etiological study was performed by Edberg et al. (1973), Kosiak M (1959) and Maklebust J. (1987). Nutritional status, including BMI, percent haemoglobin, and serum albumin, are key parameters for flap absorption and survival. [14-15] In this study, 22.7% of the patients were underweight, 13.6% were overweight or obese and the remaining 63.7% were normal weight for their height. 86.4% of patients had anemia. Later, most of the patients were prepared with nutritional aid and anaemia corrected by blood transfusion [16].

During the follow-up period, none of the patients relapsed. Hentz (1979) found that the recurrence of pressure ulcers is proportional to the postoperative complications. As no significant complications developed in this study, there was no recurrence of the disease after 6 months of follow-up [17]. After four years of surgical closure of the sacral pressure ulcer by SH Khundkar and MA Kalam (2000), there was no recurrence. Therefore, the success rate of this study is consistent with the study by SH Khundkar and MA Kalam (2000). This similarity may be due to a similar geographic pattern, postoperative management was appropriate, and the sample size in both studies ruled out a different comorbid pathology. In the case of the perforator flap, the preparation of the perforator is tedious, requiring the use of a magnifying glass and the help of bipolar diathermy and vascular micro-clips to check the fine branches of the perforator muscle [17-18]. Sometimes complete skeletonization of the perforating vessel is required to allow the flap to reach the recipient site; This carries the risk of stretching, twisting, or twisting, which can lead to complications such as vasospasm and even complete loss of the flap and blockage of blood flow.

(Yuan-Sheng Tzeng et al., 2007 and Kroll and Rosenfield, 1988). Covering the flaps free of charge is a time-consuming process [18-19]. Flap reconstruction requires a highly skilled microvascular anastomosis technique and requires experience. A free microsurgical flap can only be considered when local tissue is not available (Foster RD, 2006) [20].

**CONCLUSION:**

Therefore, the advantages of gluteal flaps compared to dermal flaps include muscle protection, lower donor site morbidity, and versatile flap design improves patient recovery. Although the flap is thinner than the dermal-muscular variant, which some authors consider to be a gluteal flap defect, it satisfies the requirement for a reconstructive defect because the para-sacral region is naturally devoid of muscles (Geddes et al. 2003). In addition to the fact that the skin and subcutaneous tissue are less prone to ischemia than the muscles, the gluteal flap is preferred for closing the sacral pressure ulcer.

**REFERENCES:**

1. Chen CY, Chiang IH, Ou KL, Chiu YL, Liu HH, Chang CK, Wu CJ, Chu TS, Hsu KF, Huang DW, Tzeng YS. surgical treatment and strategy in patients with pressure sores: A single-surgeon experience. *Medicine*. 2020 Oct 30;99(44).
2. Tchienkam LW, Titchou F, Mbonda A, Kamto T, Nwaha AM, Kamla IJ, Tochie JN. The gluteus maximus VY advancement flap for reconstruction of extensive soft tissue loss following an advanced sacral pressure ulcer. A case report and mini review. *International Journal of Surgery Case Reports*. 2020 Jan 1;73:15-21.
3. Cheng J, Zhang Q, Feng S, Wu X, Huo W, Ma Y, Cai J, Liu M. Clover-Style Fasciocutaneous Perforator Flap for Reconstruction of Massive Sacral Pressure Sores. *Annals of Plastic Surgery*. 2021 Jan;86(1):62.
4. Arikrishnan D, Balakrishnan TM, Janardhanam J. Pedicled Chimeric Perforator Flap Based on Inferior Gluteal Vessel Axis for the Reconstruction of Stage-Four Primary Ischial Pressure Sores—A New Design. *Indian Journal of Plastic Surgery*. 2021 Apr;54(02):177-85.
5. Gopalakrishnan R, Rajalingam M, Rajagunasekaran B, Esakimuthu R. Reconstruction of pressure ulcers with flaps in a tertiary care centre. *International Surgery Journal*. 2021 Jan 29;8(2):647-53.
6. Boro S, Kalita D, Kiling D, Mathew AK. Reconstruction of a sacral defect with bilateral gluteus maximus VY advancement flap following resection of squamous cell carcinoma



- (Marjolin's ulcer). *Annals of Oncology Research and Therapy*. 2021 Jan 1;1(1):64.
7. Nassar MK, Jordan DJ, Quaba O. The internal pudendal artery turnover (IPAT) flap: A new, simple and reliable technique for perineal reconstruction. *Journal of Plastic, Reconstructive & Aesthetic Surgery*. 2021 Sep 1;74(9):2104-9.
  8. Arowojolu OA, Wirth GA. Sacral and Ischial Pressure Ulcer Management With Negative-Pressure Wound Therapy With Instillation and Dwell. *Plastic and Reconstructive Surgery*. 2021 Jan 1;147(1S-1):61S-7S.
  9. Sinnott CJ, Stavrides S, Boutros C, Kuruvilla A, Glickman LT. Dual-Plane Gluteal Myocutaneous Flap for Reconstruction of Ischial Tuberosity Pressure Wounds. *Annals of Plastic Surgery*. 2020 Jul 1;85(S1):S23-7.
  10. Shambhu SK. Involvement in the utilization of sugar glue dressing followed by recreation of sacral weight sore with VY fold: A solid answer for a significant issue.
  11. Abdelmofeed AM, Abdelhalim MF. Feasibility of gluteus maximus myocutaneous pedicled flap for presacral pressure sore reconstruction: a simple approach. *The Egyptian Journal of Surgery*. 2020 Jul 1;39(3):613.
  12. Estawrow MA, Farag SA. Versatility of Gluteal Arteries Perforator Flaps (for Local Coverage) Relative to Defect Size, Site, and Different Pathological Conditions. *The Egyptian Journal of Plastic and Reconstructive Surgery*. 2020 Oct 1;44(4):513-8.
  13. Hsu KF, Chen CY, Wang CH, Dai NT, Chen SG, Chen TM, Tzeng YS. Extensive Sacral Pressure Sore Reconstructed with Staged Negative Pressure Wound Therapy Dermatraction and Superior Gluteal Artery Perforator Flap Reconstruction--A Case Report. *臺灣整形外科醫學會雜誌*. 2021 Mar 1;30(1):39-47.
  14. Ellabban MA, Wyckman A, Abdelrahman I, Steinvall I, Elmasry M. Dual Reconstruction of Lumbar and Gluteal Defects with Freestyle Propeller Flap and Muscle Flap. *Plastic and Reconstructive Surgery Global Open*. 2021 Jan;9(1).
  15. Gascoigne AC, Flood S. Pressure Injuries. In *Plastic Surgery-Principles and Practice 2022* Jan 1 (pp. 642-650). Elsevier.
  16. Padilla PL, Hancock EL, Ruff ES, Zapata-Sirvent RL, Phillips LG. Pressure Injuries. In *Tips and Tricks in Plastic Surgery 2022* (pp. 367-376). Springer, Cham.
  17. Tsukuura R, Yamamoto T. Sensate superior gluteal artery perforator flap for reconstruction of sacrococcygeal large wound dehiscence: A case report and literature review. *Microsurgery*. 2021 Nov 9.
  18. Wei Z, Zhu J, Lin T, Cai H, Fang X, Zhu Y, Yang X, Cheng J. Application of damage control surgery in patients with sacrococcygeal deep decubitus ulcers complicated by sepsis. *Journal of International Medical Research*. 2021 Oct;49(10):030006052111049876.
  19. Alfeehan MJ, Aljodah MA, Al-Zajrawee MZ, Marzook AA. Random pattern hatchet flap as a reconstructive tool in the treatment of pressure sores: clinical experience with 36 patients. *The Annals of The Royal College of Surgeons of England*. 2021 May;103(5):374-9.
  20. Pignatti M, D'Arpa S, Roche N, Giorgini FA, Lusetti IL, Lorca-Garcia C, De Santis G, Berenguer B. Surgical treatment of pressure injuries in children: A multicentre experience. *Wound Repair and Regeneration*. 2021 Nov;29(6):961-72.