



CODEN [USA]: IAJ PBB

ISSN : 2349-7750

INDO AMERICAN JOURNAL OF PHARMACEUTICAL SCIENCES

SJIF Impact Factor: 7.187

Available online at: <http://www.iajps.com>

Research Article

EFFICIENCY OF CORNEAL REFRACTIVE SURGERY, COMPLICATIONS

Dr. Dina Abdulmannan

Department of Ophthalmology Faculty of Medicine, Umm Al-Qura University, Makkah,
Saudi Arabia.

Article Received: September 2021

Accepted: October 2021

Published: November 2021

Abstract:

Ever since femtosecond lasers were first introduced into refractive surgery, the ultimate goal has been to create an intrastromal lenticule that can then be manually removed as a single piece thereby circumventing the need for incremental photoablation by an excimer laser. We conducted a search through the electronic databases, using Mesh terms, for all reagents studies that were published concerning corneal refractive surgeries. Currently, refractive surgeons are in between many choices in different types, given the myriad of available refractive corneal procedures. However, each treatment necessitates careful considerations of its risks and benefits, however a number of studies have demonstrated a lower reduction and faster recovery of corneal sensation after SMILE than LASIK. Some studies have also used confocal microscopy to demonstrate a lower decrease in subbasal nerve fiber density after SMILE than LASIK.

Corresponding author:

Dr. Dina Abdulmannan.,

Department of Ophthalmology Faculty of Medicine,
Umm Al-Qura University, Makkah,
Saudi Arabia.

QR code



Please cite this article in press Dina Abdulmannan, *Efficiency Of Corneal Refractive Surgery, Complications.*, Indo Am. J. P. Sci, 2021; 08(11).

INTRODUCTION:

Myopia is the most common type of refractive error and has a 15 to 49% prevalence worldwide [1]. Refractive surgery is a way to correct refractive error and reduce dependence on eyeglasses or contact lenses [2]. Laser corneal refractive surgery has emerged as a good alternative to optical correction of refractive errors with glasses or contact lenses [1,2]. a large range of surgical techniques are developed that change the refractive error of the attention by removing corneal tissue and reshaping the cornea including; surface ablation procedures include photorefractive keratectomy (PRK), transepithelial photorefractive keratectomy (T-PRK), laser epithelial keratomileusis (LASEK) and epipolis laser in place keratomileusis (Epi-LASIK).4 Corneal stromal ablation procedures include laser in place keratomileusis (LASIK) with the flap created with either a mechanical microkeratome or femtosecond based microkeratome (FS-LASIK).5 Refractive corneal lenticule extraction procedures include femtosecond lenticule extraction (FLEX) and tiny incision lenticule extraction (SMILE) [3,4].

These kinds of corneal refractive surgery have a variation of individual advantages and downsides. Stromal ablation techniques like LASIK are generally less painful and offer faster visual rehabilitation than surface ablation methods. However, the surface based procedures avoid variety of surgical complications arising from the creation of a lamellar corneal flap required in LASIK and theoretically provide more stable corneal biomechanics [5]. The introduction of the femtosecond laser in refractive surgery enabled the creation of lamellar corneal flaps in a very more accurate, stable and safer manner. Following the introduction of the Visumax femtosecond laser from Meditec in 2007, the FLEX procedure was introduced initially followed by the SMILE procedure. With the elimination of the need for a corneal flap, SMILE potentially offers biomechanical advantages over LASIK [2,6].

We aimed by this review to emphasize the corneal refractive surgeries in different types, benefits, and complications.

DISCUSSION:

The principles of corneal refractive surgery date back to the 19th century. Snellen first studied astigmatic changes after cataract surgery, and Schioetz performed the first penetrating corneal incision in 1885 to treat high post cataract surgery astigmatism [7]. In the 940s and 1950s, Sato introduced anterior and posterior keratotomy as treatment for myopia and astigmatism [8]. The central a part of the cornea was flattened by up to 80 anterior or posterior incisions, but success was limited because the technique damaged the endothelium.

Myopia is that the commonest eye disorder worldwide, affecting up to quite 80% in some Asian populations [9]. The prevalence and progression are suffering from many variables like ethnicity, sex, familial disposition, age of onset, the degree of myopia, education level, near reading activities, still as outdoor activities [9]. Stability of myopia isn't considered to occur before the age of 21 and will even progress further during adulthood or occur as adult-onset myopia [10]. These are important confounding factors when analysing short and particularly long-term outcomes of refractive surgery.

In refractive eye disorders, the balance between eye length and therefore the overall refractive power of the cornea and therefore the lens is disturbed. In myopia, distant objects are focused ahead of the retina, while only near objects are seen clearly (**Fig. 1**) [11]. Myopia may be classified as either physiologic or pathologic with the dioptric power of the attention being but or greater than - 6.00 D. Myopia is typically caused by axial elongation, and in pathologic myopia, the excessive dimensions of the attention may end up in retinal degenerative changes and cause complications including reduced visual acuity.

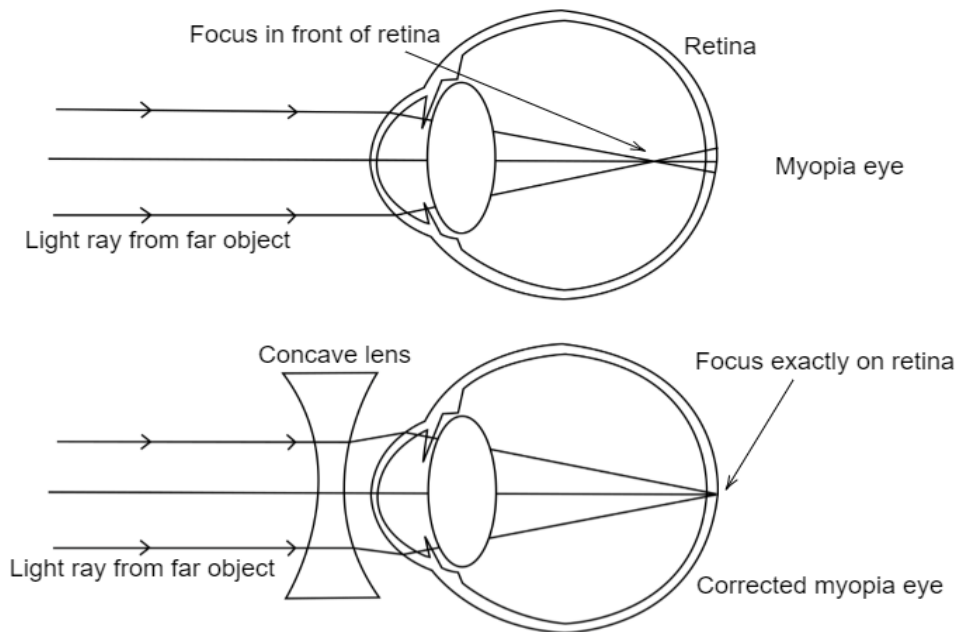


Fig 1: Schematic illustration of myopia

Photorefractive keratectomy (PRK):

In 1985, Seiler treated first human with huge location ablation to remove scarring using excimer laser [12] McDonald treated the initial sighted human eye in a refractive procedure in 1988 [13] Others did the same as well as doctors all over the world began making use of excimer laser to treat refractive mistakes in a procedure referred to as PRK today. PRK can be utilized for treatment of refractive mistakes from +3 D to -10 D and also approximately 4D of astigmatism. It can be performed through intact epithelium or following removal of the epithelium (**Fig. 2**) [4].

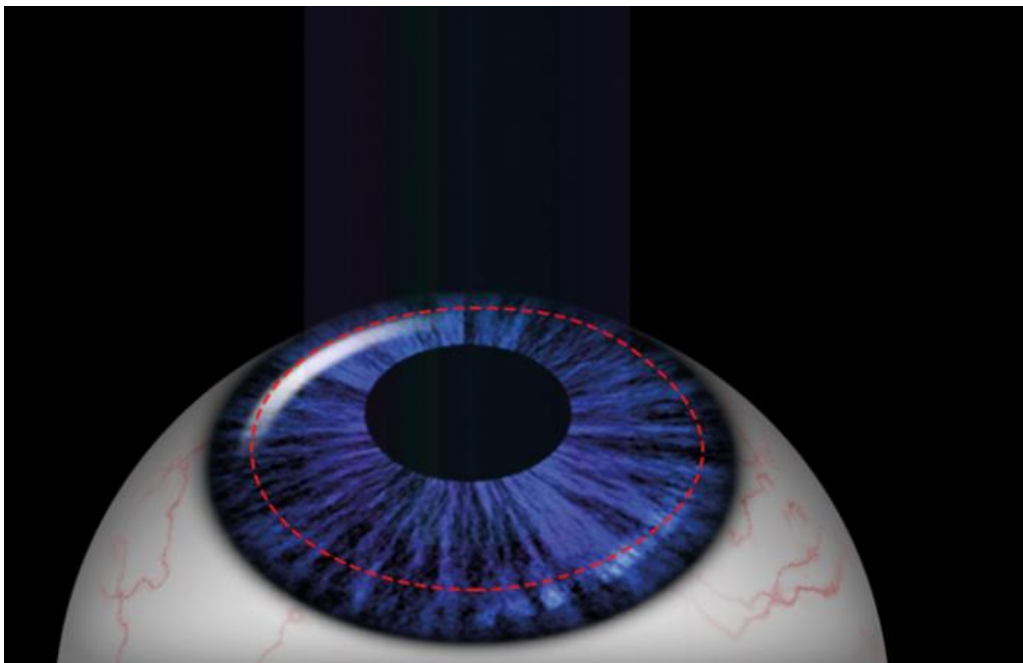


Fig. 2: PRK; involves excimer laser ablation through epithelium, Bowman's layer and stroma

Laser assisted in situ keratomileusis (LASIK):

The idea of using laser to treat cornea under a flap first started with creation of complete thin anterior caps and treating stroma underneath, followed by cap replacement [2,5]. LASIK (**Fig. 3**) allowed for faster and painless visual rehabilitation compared to PRK, gaining instant popularity [10].




Fig.3: LASIK, on the right-side Excimer laser applied on the stroma after an anterior flap is created

- **Small Incision Lenticule Extraction (SMILE)**

SMILE is a newer refractive surgery option; the pilot case was performed in 2007, and widespread implementation occurred between 2012 and 2016 [14]. SMILE is an intrastromal keratomileusis technique that needs one laser, femtosecond, to form a 3-dimensional lenticule that's extracted through a tiny low corneal incision starting from 2–5 mm. (**Fig. 4**) [14]. there's no corneal flap and there's preservation of the anterior-most stromal lamella and Bowman's layer, excluding the region of the incision. As an analogy SMILE might be compared to other varieties of corneal refractive surgery as modern small incision operative techniques. Based on a mathematical model created by Reinstein et al., SMILE has a higher postoperative relative tensile strength than PRK and LASIK [15].

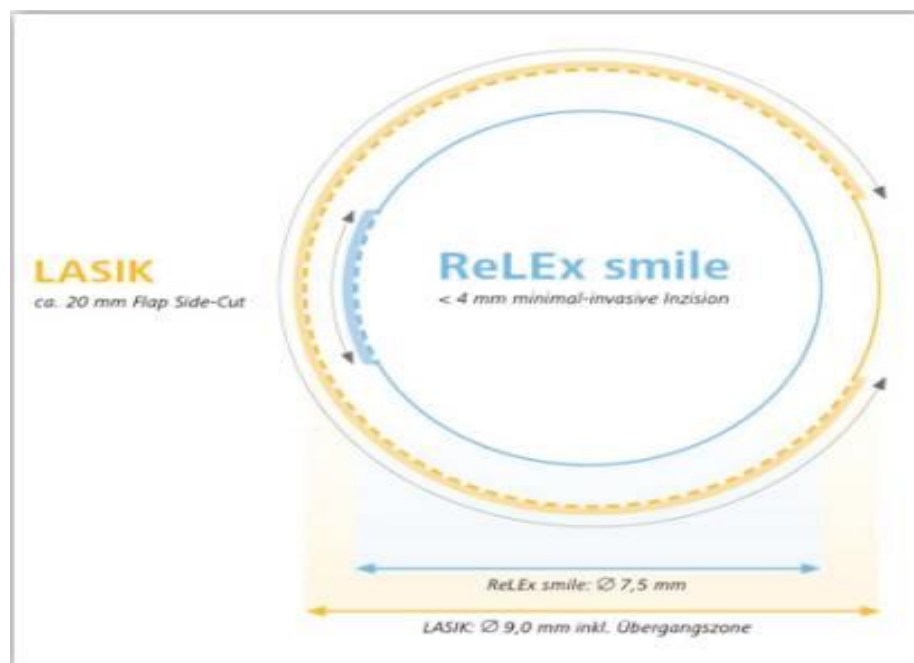


Fig.4: The difference in corneal incision in LASIK vs. SMILE.

Ectasia After Corneal Refractive Surgery:

Corneal ectasia is one of the complications of refractive surgery. Although its prevalence has been reported at between only 0.04 and 0.6%, corneal ectasia is sight-threatening and should require corneal transplantation in some severe cases [16]. Corneal biomechanical property changes can occur before the diagnosis of corneal ectasia, which is characterized by changes in corneal geometric features [17]. To gauge corneal biomechanics, the foremost widespread devices at the time of writing are ocular response analyzer (ORA) and Corvis ST system (CST) [18, 19].

Both of them are non-contact tonometry and share some common principle: an air pulse is produced and projects to the cornea, then a group of various variables are generated related to the cornea deformation [20].

Incidence of post-refractive ectasia are elusive within the present climate of inconsistent reporting of both ectasia and cases of laser vision correction. One study [2] found that post-refractive ectasia occurs at low rates in eyes undergoing PRK, with an estimated incidence of 20 per 100,000 eyes (0.020%). The preservation of corneal integrity with PRK is thought to be the explanation for the low incidence, despite the observation that eyes with thinner corneas underwent PRK. The rate of ectasia in LASIK is 4.5 times beyond that of PRK, with an incidence of 90 per 100,000 eyes (0.090%). SMILE has all-time low rate of ectasia within the present study with an incidence of 11 per 100,000 eyes (0.011%), though the relative novelty of this procedure precludes confirmation that SMILE is superior to LASIK and PRK in this regard.

CONCLUSION:

Corneal refractive surgery is an evolving field, which has altered over the decades. Ideas explored almost 70 years ago by early pioneers are made possible with the introduction of latest technologies, constant re-evaluation of old and current techniques, yet as strive for perfection. During the SMILE procedure, the patient is raised to the contact glass of the femtosecond laser. At the instant of contact between the individually calibrated curved contact glass and also the cornea, a meniscus tear film appears, at which point the patient is in a position to determine the fixation target very clearly because the vergence of the fixation beam is concentrated consistent with the patient's refraction. However, variety of studies have demonstrated a lower reduction and faster recovery of corneal sensation after SMILE than LASIK. Some studies have also used confocal microscopy to

demonstrate a lower decrease in subbasal nerve fibre density after SMILE than LASIK.

REFERENCES:

1. Pan C-W, Ramamurthy D, Saw S-M. Worldwide prevalence and risk factors for myopia. *Ophthalmic Physiol Opt.* 2012;32:3–16. doi: 10.1111/j.1475-1313.2011.00884.x.
2. Guo H, Hosseini-Moghaddam SM, Hodge W. Corneal biomechanical properties after SMILE versus FLEX, LASIK, LASEK, or PRK: a systematic review and meta-analysis. *BMC Ophthalmol.* 2019;19(1):167. Published 2019 Aug 1. doi:10.1186/s12886-019-1165-3
3. He TG, Shi XR. Clinical study of ultra-thin flap LASIK and LASEK for the treatment of high myopia with thin cornea. *Chinese Journal of Ophthalmology* 2006;42(6):517-21.
4. Bailey MD, Zadnik K. Outcomes of LASIK for myopia with FDA-approved lasers. *Cornea.* 2007;26:246–254. doi: 10.1097/ICO.0b013e318033dbf0.
5. Manche EE, Carr JD, Haw WW, Hersh PS. Excimer laser refractive surgery. *West J Med.* 1998;169(1):30-38.
6. Al-Fayez M. Long-term results of LASEK vs. LASIK for mild to moderate myopia. *American Academy of Ophthalmology*; 2008 Nov 8-11; Atlanta (GA). Atlanta (GA), 2008:247.
7. Schiötz H (1885): Ein Fall von hochgradigem Hornhautastigmatismus nach Staarextraction: Besserrung auf operativem Wege. *Arch Augenheille* 15: 178–781.
8. Sato T, Akiyama K & Shibata H (1953): A new surgical approach to myopia. *Am J Ophthalmol* 36: 823–829.
9. Lee YY, Lo CT, Sheu SJ & Lin JL (2013): What factors are associated with myopia in young adults? A survey study in Taiwan Military Conscripts. *Invest Ophthalmol Vis Sci* 54: 1026–1033.
10. Azar DT, Azar NF, Brodie SE, Hoffer KJ, Korn TS, Mauger TF, Strauss L & Thall EH (2013): *Clinical Optics, Section 3.* American Academy of Ophthalmology, San Francisco, CA, USA 88.
11. Steinert RF, Hersh PS. Spherical and aspherical photorefractive keratectomy and laser in-situ keratomileusis for moderate to high myopia: two prospective, randomized clinical trials. Summit technology PRK-LASIK study group. *Trans Am Ophthalmol Soc.* 1998;96:197-227.
12. Seiler T, Kahle G, Kriegerowski M. Excimer laser (193 nm) myopic keratomileusis in sighted and blind human eyes. *Refract Corneal Surg* 1990;6(3):165-73.

13. McDonald MB, Liu JC, Byrd TJ, *et al.* Central photorefractive keratectomy for myopia. Partially sighted and normally sighted eyes. *Ophthalmology* 1991.
14. Doane JF, Cauble JE, Rickstrew JJ, Tuckfield JQ. Small Incision Lenticule Extraction SMILE - The Future of Refractive Surgery is Here. *Mo Med*. 2018;115(1):82-84.
15. Reinstein DZ, Archer TJ, Gobbe M. Small incision lenticule extraction (SMILE) history, fundamentals of a new refractive surgery technique and clinical outcomes. *Eye Vis [Internet]*. 2014;1(1):1–12.
16. Sutton G, Lawless M, Hodge C. Laser in situ keratomileusis in 2012: a review. *Clin Exp Optom*. 2014;**97**:18–29. doi: 10.1111/cxo.12075.
17. Bao F, Geraghty B, Wang Q, Elsheikh A. Consideration of corneal biomechanics in the diagnosis and management of keratoconus: is it important? *Eye Vis*. 2016;3. 10.1186/s40662-016-0048-4.
18. Damgaard IB, Reffat M, Hjortdal J. Review of corneal biomechanical properties following LASIK and SMILE for myopia and myopic astigmatism. *Open Ophthalmol J*. 2018;**12**:164–174. doi: 10.2174/1874364101812010164.
19. Jędzierowska M, Koprowski R. Novel dynamic corneal response parameters in a practice use: a critical review doi:10.1186/s12938-019-0636-3.
20. Peña-García P, Peris-Martínez C, Abbouda A, Ruiz-Moreno JM. Detection of subclinical keratoconus through non-contact tonometry and the use of discriminant biomechanical functions. *J Biomech*. 2016;**49**:353–363. doi: 10.1016/j.jbiomech.2015.12.031.