



Can Nerve Detection be Performed with Dermatome Mapping in Open Hernia Repair?

Açık Fıtık Onarımında Dermatome Haritalama ile Sinir Tespiti Yapılabilir mi?

Eljona XHELILI¹ [ID], Frenki VILA² [ID], Bülent Cavit YÜKSEL³ [ID]

¹Department of General Surgery, Kukës Regional Hospital, Kukës, Albania.

²Department of General Surgery, Spitali Rajonal Memorial, Fier, Albania.

³Department of General Surgery, Ankara City Hospital, University of Health Sciences, Ankara, Turkey.

Article Info: Received; 16.10.2021. Accepted; 16.11.2021. Published; 28.11.2021.

Correspondence: Frenki Vila; MD, Department of General Surgery, Spitali Rajonal Memorial, Fier, Albania. E-mail: frenkivila06@gmail.com

Abstract

Inguinal hernia repair is one of the most common surgical procedures in the world. Currently, recurrence rates have reduced to less than 5% after mesh repair, but chronic groin pain (CGP) remains a major concern in open hernia surgery. The aim of the study was to detect neuropathic pain associated with iatrogenic nerve damage using the dermatome mapping test (DMT) and to evaluate the preventability of CPG. The study was designed and conducted as a prospective longitudinal observation study in postoperative open hernioplasty patients. The study included 71 adult patients with a primary inguinal hernia, who underwent a standard open surgical procedure for hernia repair using a polypropylene mesh (*Lichtenstein's technique*). The dermatome mapping classification was performed in each patient, and the test results were recorded. Seven (9.9%) patients with surgery-related pain lasting for three months or longer after surgery were considered to have CGP, and pain was related to iatrogenic nerve damage in two of these cases. Based on the results, we consider that the anatomical location of the nerves can be easily determined using DMT, and CGP can be prevented.

Keywords: Hernia, Pain, Nerve.

Özet

Kasık fıtığı tamiri dünya çapında en sık gerçekleştirilen cerrahi uygulamalardan biridir. Günümüzde açık kasık fıtığı onarımında meş kullanımından sonra nüks oranları %5'in altına düşmüş, ancak kronik kasık ağrısı (CGP, *chronic groin pain*) açık fıtık cerrahisinde önemli bir endişe olmaya devam etmektedir. Çalışmanın amacı açık fıtık tamiri prosedüründe iyatrojenik sinir hasarına bağlı gelişen nöropatik ağrıyı dermatome haritalama yöntemi (DMT) ile belirlemek ve CPG'nin önlenilebilirliğini değerlendirmektir. Çalışma, ameliyat sonrası açık hernioplasti hastalarında bir prospektif longitudinal gözlem çalışması olarak tasarlandı ve yürütüldü. Bu çalışmaya primer kasık fıtığı olan ve her birine fıtık onarımı için polipropilen mesh kullanılarak (*Lichtenstein tekniği*) standart açık cerrahi prosedür uygulanan 71 erişkin hasta dahil edildi. Her bir hasta için dermatome haritalama sınıflandırması prosedürü uygulandı ve sonuçlar kaydedildi. Ameliyatla ilişkili postoperatif ağrısı 3 ay ve daha uzun süren yedi (%9.9) hasta CGP hastası olarak kabul edildi ve bu vakaların ikisinde ağrının iyatrojenik sinir hasarı ile ilişkili olduğu belirlendi. Bu sonuçlara dayalı olarak DMT ile sinirlerin anatomik yerleşiminin kolaylıkla belirlenebileceğini ve CGP'nin önlenilebileceğini düşünüyoruz.

Anahtar Kelimeler: Fıtık, Ağrı, Sinir.

Introduction

Globally, inguinal hernia repair is one of the most common general surgical procedures, with an incidence of more than 20 million people each year [1]. The lifetime incidence of developing a hernia that includes viscera or adipose tissue protrusions through the inguinal or femoral canal is 27-43% in men and 3-6% in women [1,2]. Surgery is the only successful cure for an inguinal hernia. Currently, recurrence rates have reduced to less than 5% after mesh repair in open hernia surgery, but the main concern remains chronic groin pain (CGP) [3]. Only a quarter of patients are severely affected by CGP in their daily lives [4]. The International Association for the Study of Pain (IASP) defined CGP as groin pain reported by the patient at or beyond 3-months following inguinal hernia repair [5].

CGP is considered to be predominantly of neuropathic origin, although it also has a non-neuropathic component [6]. The recognition of the anatomical distribution of the inguinal nerves and their variants are important in the prevention and treatment of CPG [1,7]. In inguinal hernia repair, the ilio-hypogastric nerve (IHN), the ilioinguinal nerve (IIN), the genital branch of the genitofemoral nerve (GFN), and occasionally the femoral branch of the GFN or the lateral femoral cutaneous nerve should be taken into consideration [7,8]. The prediction of the dermatomes mainly supplied by the branches of each of these three nerves has become crucial in evaluating patients with CGP. In 1998, Alvarez et al. developed the dermatome mapping test (DMT) as an easy instrument in patient assessment [9]. Ever since, DMT has been regarded a simple tool with high precision when coupled with surgical findings [6,9].

In this study, we aimed to detect neuropathic pain associated with iatrogenic nerve damage using DMT and to evaluate the preventability of CPG in patients undergoing open hernia repair.

Material and Method

In this prospective longitudinal observation study, all patients undergoing open hernioplasty were observed and evaluated for CGP starting at the postoperative first week, one month and six months. Seventy-one adult patients that

underwent surgery due to the primary hernia of the inguinal canal were included in this study. Lichtenstein's technique with a polypropylene mesh was applied in all patients as a standard open procedure for hernia repair. Patients with recidive (*recurrent*) and bilateral hernia were excluded from the study.

The operations were conducted in regional Kukes Hospital Albania from April 2019 to April 2021. Patients with postoperative pain after three months were classified to have CGP. DMT was applied to all patients with CGP, and the test results were recorded in their files.

Dermatome mapping test (DMT)

A normal marker pen was used with a slight pressure to evaluate the sensation of each dermatome taken into evaluation. The steps of this process were as follows: (i) We determined a point on a 2.5 cm lateral line of the umbilicus, crossing a line extending from the iliac crest to the midline as the reference point of the region to be evaluated, (ii) we marked new points sequentially from the superior iliac crest to the median line laterally at a 2.5 cm distance of each other, and (iii) in the determined region, we continued to mark downward to the upper part of the scrotum and penis in men and the labia in women (Figure-1) [10].

When DMT was completed, a photograph was taken to have a clear view of the area and compare the results with previous mapping results in cases of vague pain or selective or multiple neurectomy pain analysis (preoperative versus postoperative). The evaluation was performed as follows: A simple circle was used in case of similar sensation to the reference point in the para-umbilical area, a cross in areas in which the patient felt pain and/or hypersensitivity, a minus in areas where the patient felt hypoesthesia, anesthesia, or discomfort, such as superficial burning and/or numbness. The type and intensity of pain perceived by each patient were recorded.

The Visual Analog Scale (VAS) was used with dermatome mapping [9,11], to evaluate four aspects of CGP: location, type, source, and intensity. VAS was used as part of the dermatome mapping system with roman numerals from I

representing vague pain to X representing strong pain. Each patient also completed a questionnaire in the preoperative and postoperative periods for the comparison of pain before and after surgery. Preoperative pain was localized according to the dermatome mapping pain for each patient. Each patient was asked for local symptoms while performing a physical examination.




Figure 1. Preoperative dermatome mapping of the ilioinguinal and ilio- hypogastric nerves in one of our patients. Circles (O) show normal sensation and crosses (x) show pain areas. The crosses marked in a square-like shape show the area of maximum pain.

Pain severity was classified according to the VAS score and compared with the pain level in the postoperative period. During surgery, we identified IIN, IHN and GFN to preserve these

nerves and protect them against damage during hernia repair.

To classify the type of pain, we used code N for neuropathic pain, NN for non-neuropathic pain, and D for denervation/discomfort pain. Neuropathic pain is associated with the involvement of IHN, IIN and GFN during surgery, and we predicted that their topography could be detected using DMT, and thus these nerves could be protected. Pain related to granuloma, recurrent hernia, meshoma, orchialgia, and pubalgia was determined as non-neuropathic pain.

Results

The mean age of the patients was 55.8 ± 15.5 years. Of the patients, 51 had indirect and 20 had direct hernias. The patients with symptomatic hernia had a symptom duration of $20.2 \text{ years} \pm 7.6$ months. More than half of the patients (63.4%, 45/71) had preoperative groin pain; 28 (62.2%) during activity and 17 (37.8%) at rest (Table 1).

Of the 71 patients, 61 patients had pain in the first week after surgery, 30 had pain at one month after surgery, and seven (9.9%) had persistent pain after three months of surgery, and these patients were classified to have CGP Figure 2 (left). In this subgroup, the type of pain non-neuropathic in four (57.1%) patients, neuropathic (28.6%) in two, and denervation in one (14.3%). Of the patients with non-neuropathic pain, three (42.9%) had orchialgia, one had pubalgia (14.3%).

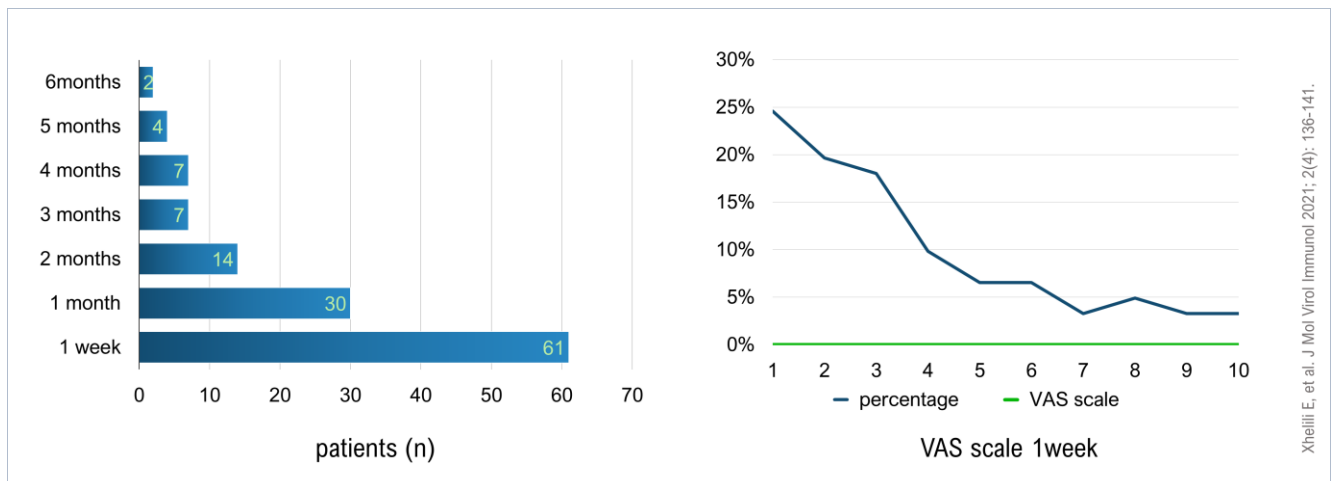


Figure 2. Change in pain during the postoperative six-month period (left), change in pain over time (right).

We evaluated the level of pain according to the VAS scale in the first week after surgery. Among the 61 patients that had pain after surgery, the level of pain was I in 24.6% (15/61), II in 19.7% (12/61), III in 18% (11/61), IV in 9.8% (6/61), V in 6.56% (4/61), VI in 6.56% (4/61), VII in 3.28% (2/61), VIII in 4.92% (3/61), IX in 3.28% (2/61), and X in 3.28% (2/61), [Figure 2 \(right\)](#).

The intraoperative nerve identification rates were 84.5% for IIN (n=60), 73.2% for IHN (n=52), and 49.3% for GFN (n=35). Fifty-one patients had standard anatomical nerve

localization for IHN, IIN, and GFN. The branches of IIN or the genital branch was not adjacent to the blue line and IIN was absent in 18 patients. In one case, we accidentally dissected IIN with scissors, and therefore we had to perform neurectomy, which resulted in hypoesthesia in the postoperative dermatome of IIN.

In the whole sample, two patients had iatrogenic nerve damage, one had IHN damage, and another had postoperative pain in the IIN dermatome probably due to maneuvers in the cord structures and suture bites in the nerve trunk.

Table 1. Distribution of pain according to the nerves at rest and during activity.

	During activity (%)	At rest (%)
<i>Ilioinguinal nerve</i>	1 (3.57)	1 (5.88)
<i>Ilio-hypogastric nerve</i>	2 (7.14)	4 (23.5)
<i>Genitofemoral nerve</i>	2 (7.14)	0
<i>Ilioinguinal nerve + genitofemoral nerve</i>	13 (46.4)	9 (52.9)
<i>Ilio-hypogastric nerve + ilioinguinal nerve</i>	3 (10.7)	2 (11.8)
<i>Ilio-hypogastric nerve + genitofemoral nerve</i>	5 (17.9)	1 (5.88)
<i>Ilio-hypogastric nerve + ilioinguinal nerve + genitofemoral nerve</i>	2 (7.14)	0
Total (n)	28	17

Discussion

Hernia recurrence is no longer a primary problem, and it has become important for surgeons to shift their focus on preventing CGP. Ideally, the nerves must be always preserved from injury, but this is not always possible. Nerve damage in Lichtenstein repair is not uncommon. We had two cases of CGP related to nerve damage, although nerve identification was carried out carefully in all of our cases. As shown in the literature data, the identification and preservation of the three inguinal nerves reduce the possibility of CGP development [12].

DMT is an easy technique that only requires an ordinary black marker and is performed under office conditions without any additional cost. A simple photograph provides a sufficient view of the surgical field to make an effective postoperative evaluation of chronic pain. DMT has a high sensitivity when matching mapped results with surgical findings and postsurgical evaluation

and outcomes. Several studies have shown that nerve identification during open hernia surgery is important to avoid postoperative pain [1,12,13], however, not all surgeons perform nerve identification during hernia surgery. Nerve identification is important in order to avoid nerve damage during hernia repair and perform neurectomy in case of interference with mesh positioning. In one of our cases, we accidentally dissected IIN and had to perform neurectomy to prevent postoperative pain.

Of our 71 patients, seven had postoperative CGP, of whom two had neuropathic pain in the dermatome of IIN and IHN, respectively, the four patients had non-neuropathic pain, and one patient had denervation pain. Neuropathic pain is usually aggravated by physical activity; however, non-neuropathic pain usually continuous at rest [4]. Non-neuropathic pain is generally derived from mesh-related tissue inflammation (mainly associated with mesh displacement or meshoma)

and fibrosis, excessive inflammatory response to foreign material, and periostitis if sutures are placed in the tuberculum pubis [4]. Of our four patients with non-neuropathic pain, three had orchialgia and one had pubalgia.

In this study, the intraoperative nerve identification rates were 84.5% (60 patients) for IIN, 73.2% (52 patients) for IHN, and 49.3% (35 patients) for GFN. In a previous cadaver study, the prevalence of nerve identification was reported as 74.2%, 84.3%, and 48.2% for IHN, IIN, and GFN, respectively [14]. If the nerves are not accurately identified, they may be exposed to more trauma (nerve entrapment) mostly due to the suturing of IHN superior to the internal ring in which the nerve through the fibers of the internal oblique muscle. The genital branch can be damaged during the handling of the spermatic cord and the inability to recognize the blue line as an anatomical landmark for the cremasteric vein to which the nerve is usually adjacent. In our study, 51 patients had standard anatomical nerve localizations, while nerve identification was not possible in 18 patients due to small variations, such as the branches of IIN or the genital branch not being adjacent to the blue line or the absence of IIN. Our results are consistent with a previous cadaver study reporting that one quarter (4/18) of the cases did not have IIN [15]. Therefore, nerve identification and preservation are crucial during hernia surgery even for surgeons with excellent familiarity with the normal anatomical characteristics of the inguinal canal.

The most common nerve of interest is IIN, followed by the genital branch, particularly in patients with plugs positioned in the internal ring where the genital branch surfaces or the round ligament has been torn off. In the laparoscopic approach, the femoral branch of the genitofemoral nerve is usually damaged due to traction, pulling, or rupture of this structure during the dissection of the iliac vessels nearby. This is probably the reason why most of these patients improve with conservative management, since the mechanism of damage is not entrapment [6].

Patients often describe neuropathic pain as neuralgia, hypoesthesia, hyperesthesia, a burning

sensation, or paraesthesia. Sometimes patients with neuropathic pain describe non-painful motive (allodynia) or an enhanced pain response to a painful stimulus (hyperalgesia). Stabbing, burning, pulling, throbbing, shooting, prickling, and sharp sensations are usually reported by patients with neuropathic pain. In these cases, pain can be concentrated on a certain point or radiate to the scrotum, labium, and/or upper thigh [12,16,17].

In order to avoid IIN damage during surgery, it is important to leave the cremasteric layer intact, and care must also be taken to performed restoring a not to narrow external ring to avoid the entrapment of IIN during the closure of the external oblique muscle. The surgeon must also be careful not to lift IIN and IHN from their beds when manipulation these nerves and use blunt dissection to avoid damage to the superficial branches of these nerves. Caution must be exercised in suturing the lower portion of the internal oblique muscle into the inguinal ligament since a suture may injury the intramuscular segment of IIN. In order to prevent nerve scarring, the nerve can be cut in retraction to ensure that it is hidden beyond the peritoneum or the resected nerve can be buried within the fibers of the internal oblique muscle to avoid its adhesion to the inguinal ligament or external oblique aponeurosis [4]. Some authors suggest that if the nerve has been damaged, the intramuscular part of the nerve must be resected, and simply cutting the nerve at the point of its emergence is not appropriate. The resection of the nerve can be performed distal to its origin, leaving the site of the injured nerve intact to continue to generate a pain signal and exposing it to neuroma formation [9,18-20].

Conclusion

CGP after open inguinal hernia surgery is an important condition that affects the life quality of patients. This study showed that the topography of the nerves could be easily detected during the operation with the use of DMT in every patient scheduled to undergo this surgery. In conclusion, we consider that the anatomical location of the nerves can be determined with DMT, and thus CGP can be prevented.

Conflict of interest: The authors declare that there is no conflict of interest. The authors alone are responsible for the content and writing of the paper. **Financial disclosure:** There is no financial support to this study. **Ethical aspect:** Informed consent was obtained from all participants in the study and all procedures were conducted in accordance with the Declaration of Helsinki.

References

1. HerniaSurge Group. International guidelines for groin hernia management. *Hernia* 2018; 22(1): 1-165. [[Crossref](#)]
2. Primatesta P, Goldacre MJ. Inguinal hernia repair: incidence of elective and emergency surgery, readmission and mortality. *Int J Epidemiol* 1996; 25(4): 835-9. [[Crossref](#)]
3. Neumayer L, Giobbie-Hurder A, Jonasson O, Fitzgibbons R Jr, Dunlop D, Gibbs J, et al; Veterans Affairs Cooperative Studies Program 456 Investigators. Open mesh versus laparoscopic mesh repair of inguinal hernia. *N Engl J Med* 2004; 350(18): 1819-27. [[Crossref](#)]
4. Hakeem A, Shanmugam V. Current trends in the diagnosis and management of post-herniorrhaphy chronic groin pain. *World J Gastrointest Surg* 2011 27; 3(6): 73-81. [[Crossref](#)]
5. Merskey H, Bogduk N. Classification of chronic pain: descriptions of chronic pain syndromes and definitions of pain terms. In: Patrinos GP, Ansorge W (eds), *Classification of Chronic Pain*, IASP Task Force on Taxonomy (2nd edition). 1994, IASP Press, Seattle, Washington. pp: 209-14.
6. Álvarez R. Dermatome Mapping: Preoperative and Postoperative Assessment. In: Jacob B, Chen D, Ramshaw B, Towfigh S (eds), *The SAGES Manual of Groin Pain*. 2016, Springer, Cham, Switzerland. pp: 277-92. [[Crossref](#)]
7. Rab M, Ebmer And J, Dellon AL. Anatomic variability of the ilioinguinal and genitofemoral nerve: implications for the treatment of groin pain. *Plast Reconstr Surg* 2001; 108(6): 1618-23. [[Crossref](#)]
8. Amin N, Krashin D, Trescot AM. Ilioinguinal and Iliohypogastric Nerve Entrapment: Abdominal. In: Trescot AM (ed), *Peripheral Nerve Entrapments*. 2016, Switzerland. pp: 413-24. [[Crossref](#)]
9. Álvarez Quintero R, Anaya Prado R, Malé VE. Inguinodynia: Mapping of dermatomes as a diagnostic method. *Cirujano General* 2004; 26(4): 265-9.
10. Álvarez Quintero R, Mayagoitia González JC. Dolor inguinal crónico posoperatorio o inguinodinia (Chapter 37). In: Mayagoitia González JC (ed), *Hernias de la pared abdominal: tratamiento actual* (3rd edition). 2015, Editorial Alfil, México. pp: 293-9.
11. Loos MJ, Houterman S, Scheltinga MR, Roumen RM. Evaluating postherniorrhaphy groin pain: Visual Analogue or Verbal Rating Scale? *Hernia* 2008; 12(2): 147-51. [[Crossref](#)]
12. Hakeem A, Shanmugam V. Inguinodynia following Lichtenstein tension-free hernia repair: a review. *World J Gastroenterol* 2011; 17(14): 1791-6. [[Crossref](#)]
13. Smeds S, Löfström L, Eriksson O. Influence of nerve identification and the resection of nerves 'at risk' on postoperative pain in open inguinal hernia repair. *Hernia* 2010; 14(3): 265-70. [[Crossref](#)]
14. Cirocchi R, Henry BM, Mercurio I, Tomaszewski KA, Palumbo P, Stabile A, et al. Is it possible to identify the inguinal nerves during hernioplasty? A systematic review of the literature and meta-analysis of cadaveric and surgical studies. *Hernia* 2019; 23(3): 569-81. [[Crossref](#)]
15. Wijsmuller AR, Lange JF, Kleinrensink GJ, van Geldere D, Simons MP, Huygen FJ, et al. Nerve-identifying inguinal hernia repair: a surgical anatomical study. *World J Surg* 2007; 31(2): 414-20; discussion 421-2. [[Crossref](#)]
16. Bjurstrom MF, Nicol AL, Amid PK, Chen DC. Pain control following inguinal herniorrhaphy: current perspectives. *J Pain Res* 2014; 7: 277-90. [[Crossref](#)]
17. Cunningham J, Temple WJ, Mitchell P, Nixon JA, Preshaw RM, Hagen NA. Cooperative hernia study. Pain in the postrepair patient. *Ann Surg* 1996; 224(5): 598-602. [[Crossref](#)]
18. Alfieri S, Rotondi F, Di Giorgio A, Fumagalli U, Salzano A, Di Miceli D, et al; Groin Pain Trial Group. Influence of preservation versus division of ilioinguinal, iliohypogastric, and genital nerves during open mesh herniorrhaphy: prospective multicentric study of chronic pain. *Ann Surg* 2006; 243(4): 553-8. [[Crossref](#)]
19. Amid PK. A 1-stage surgical treatment for postherniorrhaphy neuropathic pain: triple neurectomy and proximal end implantation without mobilization of the cord. *Arch Surg* 2002; 137(1): 100-4. [[Crossref](#)]
20. Alfieri S, Amid PK, Campanelli G, Izard G, Kehlet H, Wijsmuller AR, et al. International guidelines for prevention and management of post-operative chronic pain following inguinal hernia surgery. *Hernia* 2011; 15(3): 239-49. [[Crossref](#)]