



Incidental Gastric Diverticulum in an Elderly Male with Chronic Dyspepsia

Kronik Dispepsili Yaşlı Erkek Hastada İnsidental Saptanan Gastrik Divertikül

Abdirahman ALASSO¹ [ID], Najib WEHLIE¹ [ID], Mehmet TAHTABAŞI² [ID], Sadettin ER¹ [ID]

¹Department of General Surgery, Mogadishu Somalia-Turkey Recep Tayyip Erdoğan Training and Research Hospital, Mogadishu, Somalia.

²Department of Radiology, Mogadishu Somalia-Turkey Recep Tayyip Erdoğan Training and Research Hospital, Mogadishu, Somalia.

Article Info: Received; 06.01.2020. Accepted; 20.01.2020. Published; 20.01.2020.

Correspondence: Sadettin Er; MD, Department of General Surgery, Mogadishu Somalia-Turkey Recep Tayyip Erdoğan Training and Research Hospital, Mogadishu, Somalia. E-mail: ersadettin74@gmail.com

Cite as: Alasso A, Wehlie N, Tahtabaşı M, Er S. Incidental Gastric Diverticulum in an Elderly Male with Chronic Dyspepsia. Life Med Sci 2022; 1(1): 30-32.

Abstract

Gastric diverticula are usually asymptomatic. When symptoms surface, they are mostly upper abdominal pain, nausea, and vomiting, while dyspepsia is less common. In this case, there was determined as an incidental of gastric diverticula that was managed by medical treatment. 70-year-old male came to our clinic complaining chronic epigastric pain and dyspepsia, with no known co-morbidities. Esophagogastroduodenoscopy and tomography were performed at diagnosis. Medical treatment (proton pump inhibitor) was started and followed because the gastric diverticulum was 2 cm below. The patient is still under follow-up and has no clinical findings.

Keywords: Gastric diverticula, Elderly male.

Özet

Gastrik divertiküller genellikle asemptomatiktir. Semptomlar ortaya çıktığında, çoğunlukla üst karın ağrısı, bulantı ve kusma olurken, dispepsi daha az görülür. Bu olguda da tıbbi tedavi ile yönetilen bir gastrik divertikül insidental olarak saptanmıştır. 70 yaşında erkek hasta bilinen bir morbiditesi olmayan kronik epigastrik ağrı ve dispepsi şikayeti ile kliniğimize başvurdu. Tanıda, özofagogastroduodenoskopi ve tomografi yapıldı. Gastrik divertikül, 2 cm altında olduğundan medikal tedaviye (proton pompa inhibitörü) başlandı ve takip edildi. Hasta halen takip edilmekte ve klinik bulgusu da bulunmamaktadır.

Anahtar Kelimeler: Gastrik divertikül, Yaşlı erkek.

Introduction

Gastric diverticulum (GD) is sac-like projection of the gastric wall sac are rare and noticed by chance in the course of routine gastroscopy. Prevalence of GD according to the different diagnostic modality like endoscopy, radiographs, and autopsies 0.01%, 0.02% and 0.04% respectively [1,2]. The incidence of GD is fifty-fifty in both sexes and mostly may present at the age from 50th up to 60th the absence of the specific pathognomonic symptoms makes his condition difficult to diagnose. In our goal was to underline on the diagnosis and dissimilar treatment options for GD.

Case Report

70-year-old male came to our clinic complaining chronic epigastric pain and dyspepsia, with no known co-morbidities, he had history of hospitalization in 1978 for this condition, he underwent endoscopy but unfortunately, he had lost the documents, and he was prescribed magnesium milk for treatment at that time. We did investigations and made esophagogastro-duodenoscopy (OGD), we found single out pouching measuring 1-2 cm in the gastric fundus (Figure 1) and also food material inside the pouch. A GD was confirmed on oral and intravenous contrast computed tomography (CT). CT reported 1.5-2 cm GD (Figure 2). Medical treatment was started and followed because the gastric diverticulum was 2 cm below. The patient is still under follow-up and has no clinical findings.

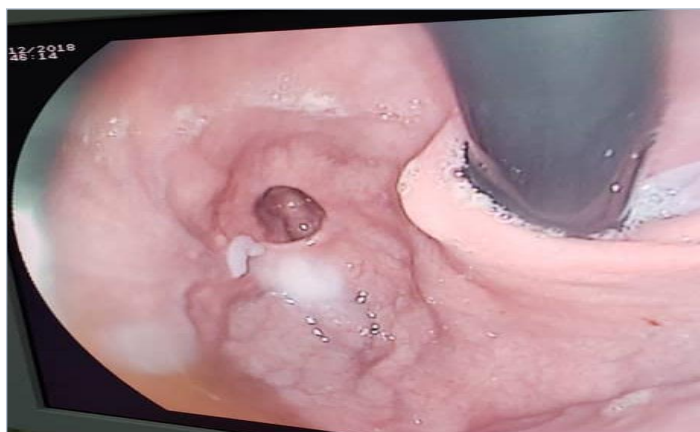

Figure 1. Diverticulum seen in gastric fundus in gastroscopy.

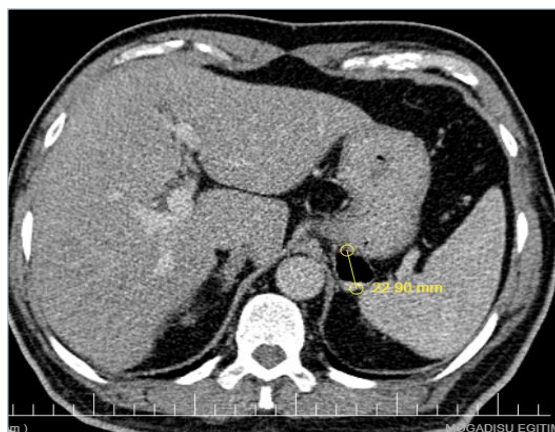


Figure 2. Computed tomography showed an exophytic diverticulum extending from the stomach fundus (yellow arrow).

Discussion

GD is a sac-like projection, which commonly consists of in the posterior wall of the fundus, as mentioned in above case. GD is minimal gastrointestinal (GI) diverticula, with widespread rates with respect to upper GI contrast studies, OGD and autopsy studies is 0.04% (165/380000), 0.01-0.11% and 0.02% (6/29900) respectively [3]. These can be classic: innate or acquired, true or false (GD can be categorized to two kinds innate, or true diverticula and acquired, or false diverticula). A true diverticulum consists of all three layers of the intestine; lining mucosa, muscularis and serosa. It does not contain the false diverticulum muscularis and is therefore very thin-walled. Innate diverticula are characteristically true and compose of three quarters of all GD's, while those that are acquired are characteristically false [3]. Innate diverticula are usually discovered throughout the rear wall of the fundus, while acquired diverticula are based in or close the antrum [4]. The manner of development of a disease of false diverticula is situated on pressure which may be internal known as pulsion diverticula, or external known as traction diverticula [5,6]. GD may not be symptomatic. However, providing those symptoms consist of, the sick usually complain longtime history epigastric ache, nausea, vomiting, dyspepsia, and beforetime satiety. Because of the uncertain symptoms, these may be related to another abdominal pathologies and precise diagnosis is usually made by chance in the gastroscopy in 1951, after the review of 49 symptomatic cases of GD, Palmer suggested that symptomatic diverticula are generally seen in the existence of other gastric situations like ulceration or gastritis [4,7]. Besides, it demonstrates the significance to search for another pathology both in clinical terms and with biopsy. Cases with unexpected relationship such as malignancy or obstruction have been referred to in the literature. Jayarajah et al. [3] announced a case admitting with gastric outlet obstruction who was determined to have a prepyloric diverticulum on endoscopic OGD. Fork et al. [8] reported the case of a 77- year-of old male who is known with GD s, who was Later on discovered to have a malignant polypoid lesion developing inside it 11 years later. On this basis, any unusual findings in a GD should trigger further

investigation. In this case, the patient applied to our clinic with dyspeptic complaints. The diagnosis was made incidentally.

The standard investigation tool is OGD. To investigate with CT is other option, yet this is lesser sensitive in detection and may cause misdiagnosis like adrenal pathology diverticulum, which was in advance visualized on endoscopic OGD and contrast swallow. Management of GD depends on the patient profile, size, and presenting complaints, with associated complications. Medical management with the use of medications like antacids, proton pump inhibitors were showed to present some symptomatic relief without resolving the primary pathology [1,4]. Surgical resection is recommended if the diverticulum has findings, such as perforation, bleeding, or malignancy. Both laparoscopic and open resection are good options. Surgery ranges from partial gastrectomy to diverticulum invagination.

Conclusion

In conclusion, the symptoms of GD are often variable. Our patient was determined to have chronic epigastric pain and dyspepsia. He was investigated with two different modalities such as OGD, and CT scan. After treatment, he is still on regular follow up. In this manner, it was concluded that non-operative treatment is also an option for such patients.

Declaration of interest: The authors declare no conflict of interest and alone is responsible for the content and writing of the paper.

This article previously published as: "Somalia Turkey Journal of Medical Science 2020; 1(1): 14-16." Currently, Somalia Turkey Journal of Medical Science was merged with Life and Medical Sciences.

References

1. Rashid F, Aber A, Iftikhar SY. A review on gastric diverticulum. *World J Emerg Surg* 2012; 7(1): 1. [[Crossref](#)] [[PubMed](#)]
2. Palmer ED. Gastric diverticulosis. *Am Fam Physician* 1973; 7: 114-7. [[PubMed](#)]
3. Baloyi ER, Rose DM, Morare NMT. Incidental gastric diverticulum in a young female with chronic gastritis: A case report. *Int J Surg Case Rep* 2019; 66: 63-7. [[Crossref](#)] [[PubMed](#)]
4. Shah J, Patel K, Sunkara T, Papafragkakis C, Shahidullah A. Gastric Diverticulum: A Comprehensive Review. *Inflamm Intest Dis* 2019; 3(4): 161-6. [[Crossref](#)] [[PubMed](#)]
5. DuBois B, Powell B, Voeller G. Gastric diverticulum: "a wayside house of ill fame" with a laparoscopic solution. *JLS* 2012; 16(3): 473-7. [[Crossref](#)] [[PubMed](#)]
6. Marano L, Reda G, Porfidia R, Grassia M, Petrillo M, Esposito G, et al. Large symptomatic gastric diverticula: two case reports and a brief review of literature. *World J Gastroenterol* 2013; 19(36): 6114-7. [[Crossref](#)] [[PubMed](#)]
7. Palmer ED. Gastric diverticula. *Int Abstr Surg* 1951; 92: 417-28. [[PubMed](#)]
8. Fork FT, Tóth E, Lindström C. Early gastric cancer in a fundic diverticulum. *Endoscopy* 1998; 30(1): S2. [[Crossref](#)] [[PubMed](#)]