



ISSN NO. 2320-5407

Journal Homepage: - www.journalijar.com

INTERNATIONAL JOURNAL OF ADVANCED RESEARCH (IJAR)

Article DOI: 10.21474/IJAR01/13506
DOI URL: <http://dx.doi.org/10.21474/IJAR01/13506>



INTERNATIONAL JOURNAL OF
ADVANCED RESEARCH (IJAR)
ISSN 2320-5407
Journal Homepage: <http://www.journalijar.com>
Journal DOI: 10.21474/IJAR01

RESEARCH ARTICLE

UNRAVELLING (COVID) MUCORMYCOSIS, DENTISTS AT THE DEEP END – A MINI REVIEW

Dr. Nirmala Chandrasekaran¹, Dr. Anil Kumar Ramachandran², Dr. G. Padmanabha Kumar³ and Dr. Siddharth Dhanraj⁴

1. Sr. Lecturer, Department of Conservative Dentistry & Endodontics, Ragas Dental College and Hospital, Uthandi, Chennai, India.
2. Professor and Head, Department of Conservative Dentistry & Endodontics, Ragas Dental College and Hospital, Uthandi, Chennai, India.
3. Associate Professor and Head, Department of Oral & Maxillofacial Surgery, Faculty of Dentistry, MAHSA University, Kuala Lumpur, Malaysia.
4. Senior Lecturer, Dept of Oral & Maxillofacial Surgery, Faculty of Dentistry, International Medical University, Kuala Lumpur, Malaysia.

Manuscript Info

Manuscript History

Received: 31 July 2021

Final Accepted: 31 August 2021

Published: September 2021

Key words: -

Mucormycosis, Covid, Post covid complication, Surgical Management

Abstract

COVID-19 otherwise called as SARS-Cov-2 caused by severe acute respiratory syndrome declared as pandemic by WHO, resulted in increased mortality globally. Post covid recovered patients developed a wide range of opportunistic bacterial and fungal infections including mucormycosis. Even though mucormycosis is known as a life-threatening disease in immunocompromised patients and patients with uncontrolled diabetes with high rates of morbidity and mortality, application of a proper protocol and adhering to the standard guidelines in the management from initial stage to advanced complex stage can reduce the morbidity and mortality. Since the early clinical signs and symptoms arise in the oral and maxillofacial region, the role of general dentist in early detection of the clinical signs and symptoms and in particular the early surgical intervention by the Oral & Maxillofacial surgeons can definitely reduce the morbidity and mortality caused by mucormycosis. Poor prognosis and increased morbidity are often related to delayed diagnosis and delayed management without proper guidelines. This article aims to describe in brief mucormycosis with the current update and the role of an endodontist in diagnosis and management of this fungal infection.

Copy Right, IJAR, 2021., All rights reserved.

Introduction: -

Mucormycosis is a rare, fulminant, rapidly spreading opportunistic infection which invariably affects immunocompromised patients¹. Mucormycosis previously known as phycomycosis or zygomycosis was first described in 1885 by Paltauf². The most common organisms that are isolated from patients with Mucormycosis, belong to a saprophytic fungus especially *Rhizopus* and *Mucor* species^{1,3}. Mucormycosis is prevalent in patients with diabetes mellitus especially ketoacidosis, neutropenia, cancer, transplantation of organs, and/or increased available iron serum levels⁴.

Corresponding Author:- Dr. Nirmala Chandrasekaran

Address:- Sr. Lecturer, Department of Conservative Dentistry & Endodontics, Ragas Dental College and Hospital, Uthandi, Chennai, India.

Recently, an increase in rhino-orbital mucormycosis is being reported in people with COVID-19 due to rampant use of corticosteroids⁵. Oral mucormycosis is caused by inhalation of sporangiospores of mucormycetes, molds or direct contamination of open oral wound. The first clinical sign leading to mucormycosis diagnosis is ulceration^{6,7}. High risk patients who report with dental pain and palatal ulcer necessitates appropriate diagnosis and treatment plan. Since dentists are the one who objectively assess the dental pain, they play a major role in diagnosis of mucormycosis as mucormycosis can mimic odontogenic pain.

Review of Literature: -

Mucormycosis is defined as an angio invasive insidious fungal infection caused by Mucorales and zygomycotic species⁸. It can occur as acute and aggressive forms and are caused commonly by saprophytic organisms of the genera *Rhizopus*, *Mucor*, *Cunninghamella* and *Rhizomucor*⁹.

History

Paltauf *et al* reported the first case of Mucormycosis in 1885 and described it as Mycosis Mucorina. Gregory *et al* published the first case of rhino-orbital cerebral mucormycosis in 1943^{8,10}. The association between poorly controlled diabetes and Mucormycosis was reported in 1943¹¹. In 1980s and 1990s rapidly increasing cases of Mucormycosis was reported in immunocompromised patients. Mucormycotina have also been found in soil and decaying fruit and vegetables, but they are not harmful. They are not a commensal in oral cavity like *Candida*⁸. It has also been reported to occur during natural disasters like the 2004 Indian ocean tsunami and the Missouri tornado in 2011¹². Currently, a number of cases have been reported in association with COVID-19¹³.

Classification

Based on the anatomic location in which it occurs, Mucormycosis is classified as

1. Rhinocerebral – affects sinus and brain
2. Pulmonary – affects the lungs
3. Cutaneous – affects the skin
4. Gastrointestinal – affects stomach and intestine
5. Disseminated – spreads through distant sites through blood
6. Uncommon presentations – affects less commonly involved sites¹⁴

Clinical features

Mucormycosis can occur in humans in two forms

1. Superficial and Visceral
2. Localized and Disseminated

The superficial type occurs as cutaneous mucormycosis and can also be seen in external ear and finger nails. The localized form affects the lungs, intestine, sinus and brain^{8,15}. Patients may experience fever, rhinorrhoea, cephalgia, ocular pain, vision loss, palpebral oedema, facial oedema and proptosis.

Oral manifestations of mucormycosis may be the first clinical sign due to high vasculature of the oral tissues. Hard palate is commonly infected due to its close anatomic relationship to the paranasal sinus and nasal fossa. The initial presentation may be seen as an intraoral swelling which can ulcerate and cause tissue destruction to appear as necrotic and black^{16,17,18}. Lesions affecting the sinus can cause erosion of the hard palate along with the mobility of the maxillary teeth. Perineural spread and cavernous sinus invasion can occur due to the invasion of the fungal hyphae¹⁹. Cases of periodontal mucormycosis have also been reported secondary to haematological malignancies. They manifest as oedematous plaques with necrotic changes and gingival pain²⁰.

Radiographic Features

CT scans can demonstrate isodense and hyperdense areas of sinuses due to obstruction²¹. MRI can show orbital soft tissues invasion, infiltration of skull base, perineural spread, intracranial changes and vascular obstruction of the internal carotid artery²².

Pathogenesis

Infection occurs by inhalation of spores, contamination of traumatized tissue, ingestion and direct inoculation of spores causing angioinvasion, thrombosis, ischemia and necrosis of the tissues involved²². Dental extractions cause bleeding and rupture of the blood vessels that can serve as an opening for the entry of the fungi²³.

Maxillary sinus, the biggest of the paranasal sinus, has the apex of the sinus extending into the zygomatic process of the maxilla and the base formed by the lateral wall of the nose. Floor of the orbit forms the roof and the alveolar process forms the floor. They are located above the level of the first and second premolars, the third molar and the root of the canine. Ethmoidal sinus lies between the upper parts of the nasal cavities and the orbits, and is separated from these cavities by thin bony lamellae. The maxillary sinuses are located under the orbit, the frontal sinuses above the orbit, the ethmoidal sinuses are between the orbit and the sphenoidal sinuses are behind the orbit^{24,25}.

Due to the proximity of the paranasal sinus cavities and the orbit, it is not uncommon for patients with primarily sinonasal pathology to present with ophthalmologic symptoms²⁶. Upon germination, the invading fungus may spread to the palate inferiorly, to the sphenoid sinus posteriorly, laterally into the cavernous sinus involving the orbits, or cranially to invade the brain. Following inhalation of spores into the paranasal sinuses, the infection begins in the nasal turbinates with a reservoir in the pterygopalatine fossa. It mimics as an acute sinusitis as it spreads from the sinus to the orbit and the hard palate. The fungi invade the blood vessels causing arterial occlusion resulting in ischemia. From the orbit, the organisms invade the cavernous sinus and then the brain causing embolization, seizures and cerebrovascular occlusion^{27,28,29}.

Mucormycosis and Covid-19

COVID-19-associated pulmonary aspergillosis, candidiasis and mucormycosis have been reported³⁰. In India, the prevalence of mucormycosis is approximately 0.14 cases per 1000 population, which is 80 times the prevalence in developed countries³¹. The incidence of COVID-19 associated mucormycosis cases is 8,800 as of May 23rd 2021³².

The causes attributed to the rise of COVID-19 mucormycosis are uncontrolled diabetes, excessive use of corticosteroids for immunosuppression and long-term stay in the intensive care unit, malignancy, post-transplant comorbidity and variconazole therapy^{33,34}. SARS-CoV-2 infection can affect CD4+ and CD8+ T-cells thereby resulting in a reduction of lymphocytes and T-cells which increases the risk of developing invasive mucormycosis³¹.

A cumulative dose of prednisolone more than 600 mg or a total methyl prednisone dose of 2–7 g prescribed, can predispose immunocompromised patients to mucormycosis³⁵. The invasion and destruction of mucormycosis can be due to the low serum inhibitory activity against *Rhizopus* species especially in diabetic patients with ketoacidosis, reduction of pH and the reduced capacity of diabetes mellitus patients to inhibit *Rhizopus* germination⁸. Hyperglycemia causes reduction in iron binding allowing increased free iron. Patients with COVID-19 exhibit increase in cytokines especially interleukin-6, which further increases free iron by increasing the ferritin levels due to increased synthesis and decreased transport of iron. Free iron serves as an ideal medium for the growth of mucormycosis³⁶. Receptor Glucose-Regulated Protein (GRP) 78 is one of the receptors for SARS-CoV-2 entry into the cells. Hyperglycemia induce the endothelial GRP 78 and the adhesin spore coat protein homologs (CotH) of Mucorales resulting in increased adhesion and penetration of Mucorales to the endothelium³⁷. Zinc inhibits ribonucleic acid polymerase and is also a component of Angiotensin-converting enzyme 2 (ACE2) which facilitates cellular entry of coronavirus³⁸. It has also been observed that zinc deficiency induces stress in fungal cells and inhibits fungal development³⁹. It has also been postulated that non-sterile water used in humidifiers, unsterilized oxygen equipment and non-medical oxygen cylinders can also cause mucormycosis⁴⁰. Masks which are unhygienic masks, re-using unwashed masks and poorly ventilated rooms have also been put forward as causes for the development of mucormycosis in COVID-19 patients⁴¹.

Mucormycosis can occur during COVID-19 infection or a few weeks after recovery⁴².

Signs and symptoms to suspect mucormycosis in COVID-19 patients

1. Nasal obstruction
2. Nasal discharge
3. Facial pain and swelling
4. Odontogenic pain
5. Mobility of teeth
6. Discoloration of teeth
7. Ulceration of palate
8. Blackish discoloration over bridge of nose/palate
9. Blurred vision
10. Worsening of respiratory symptoms

Diagnosis

1. KOH smear
2. Microbial culture
3. Matrix-assisted laser desorption/ionization (MALDI-TOF)
4. CT and MRI to assess disease extent

In the initial stage, the radiological signs may be minimal and subtle and may not demonstrate sinusitis and bone erosion. But the lack of these signs does not exclude diagnosis^{34,43}.

Management

Guideline for management of Mucormycosis in Covid – 19 patients by Directorate General of Health Services (DGHS) suggests the use of liposomal Amphotericin B -5mg/kg body weight (10 mg/kg body wt. in case of CNS involvement) initially. Liposomal Amphotericin B should be diluted in 5% or 10% dextrose, as it is not compatible with normal saline/ Ringer Lactate. After the disease is stabilized oral Posaconazole (300 mg delayed release tablets 1-0-1 x 1 followed by 300 mg daily) or Isavuconazole (200 mg 1-1-1 x 2 followed by 200 mg daily) can be given. If liposomal Amphotericin B is not available, the conventional form (deoxy cholate) in the dose 1-1.5mg/kg can be prescribed if the renal functions and serum electrolytes are within normal range⁴⁴.

Amphotericin B is a polyene class of antifungals with a half-life from 24 hours to 15 days. Three types of Amphotericin B are available- Liposomal Amphotericin B, Amphotericin B lipid complex and Amphotericin B cholesteryl sulfate complex⁴⁵. Liposomal Amphotericin B is the drug of choice for treatment of mucormycosis associated with COVID-19⁴³. It acts by binding to ergosterol in the fungal cell membrane which leads to formation of ion channels resulting in the loss of protons and monovalent cations causing depolarization and concentration-dependent cell killing. It also causes oxidative damage to the cells and has a stimulatory effect on phagocytic cells resulting in cell death⁴⁵.

Surgical Management

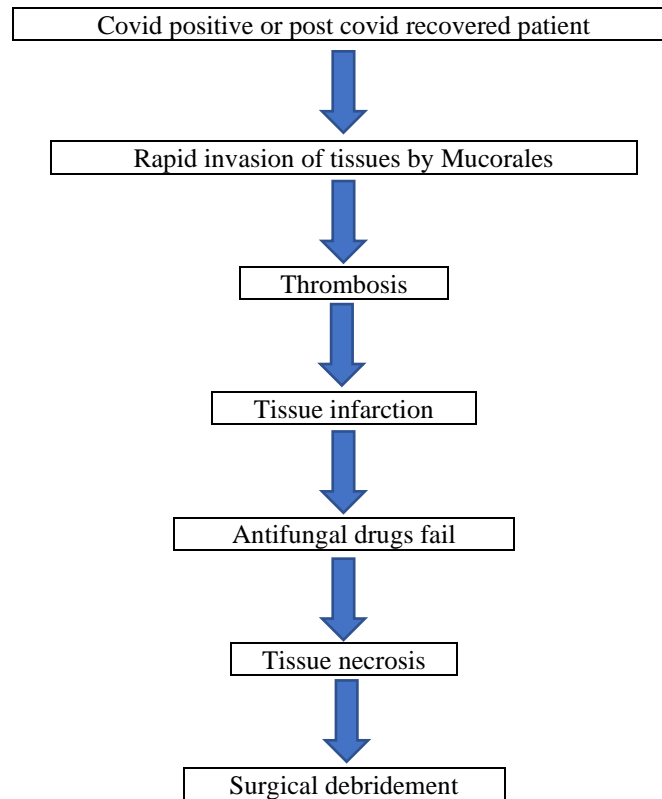
Different countries were following different protocols in medical and surgical management of mucormycosis. The treatment plan varied in different regions based on the different diagnostic techniques and available therapeutic options. The treatment protocol varied based on specific systemic problems and disease patterns. In January, 2018, experts from 33 countries of the European Confederation of Medical Mycology (ECMM) did the retrospective analysis of mucormycosis management and reviewed various treatment guidelines followed in different parts of the world. One of the recommendations included immediate and appropriate imaging of suspected cases of mucormycosis to find out extent of disease, which will be useful to apply the guidelines in both medical and surgical management⁴⁶.

The European Confederation of Medical Mycology (ECMM), in association with the Mycoses Study Group Education & Research Consortium (MSG ERC), issued a comprehensive guideline and tried to clear the doubts on confused areas in the treatment of mucormycosis.

Rapid invasive nature of the mucormycosis leads to thrombosis, tissue infarction and tissue necrosis. This prevents the penetration of antifungal agents and results in failure of antifungal agents in which condition, surgery is the next best option left. Early surgical intervention and debridement of the involved structures helps to prevent the spread and protect the adjacent structures. Surgical excision of the involved soft tissues, debridement of the involved structures like surgical resection of infected lung tissue in localized pulmonary lesions and surgical debridement in rhino orbital cerebral region is also part of the extensive surgical treatment.

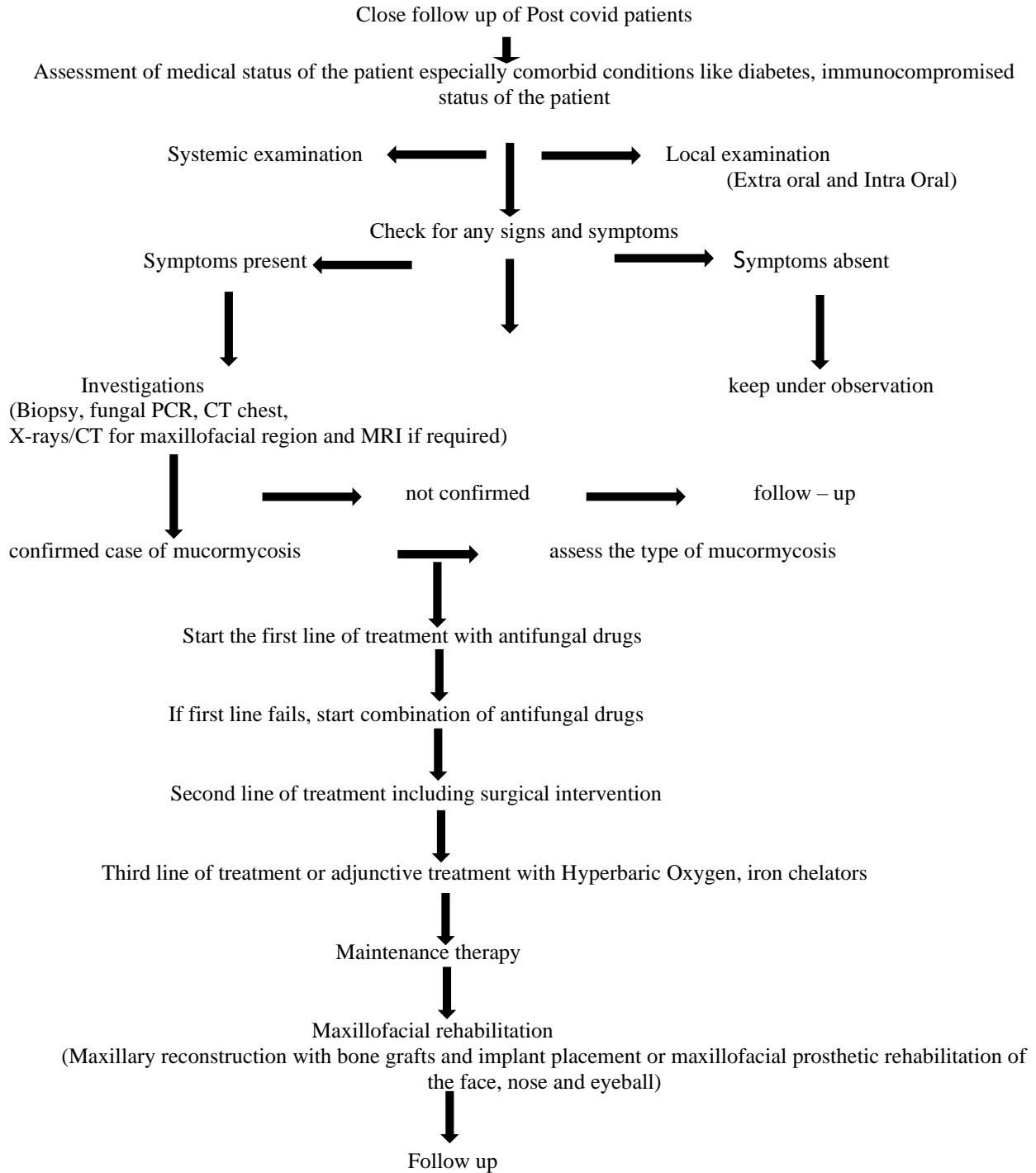
Adjunctive Treatment

This includes treatment with hyperbaric oxygen therapy or adjunctive treatment with deferasirox or deferiprone. Iron chelation by deferasirox or deferiprone appears to be a rational adjunct to antifungal treatment. In rhino-orbito-cerebral mucormycosis adjunctive hyperbaric oxygen appears more promising but not much results are currently available⁴⁷.

Pathophysiology leading to surgery in Post-Covid Mucormycosis**Checklist for diagnosis of Mucormycosis in COVID patients**

1. Post covid patient with suspected signs and symptoms of mucormycosis
2. Systemic and local examination
3. Assessment of medical status of the patient especially comorbid conditions like diabetes, immunocompromised status of the patient etc.
4. Intra oral examination
5. Investigations like Biopsy, culture, fungal PCR, CT chest, maxillofacial region and MRI
6. Confirmatory diagnosis of mucormycosis
7. First line of treatment with antifungal drugs
8. If first line treatment fails, combination of antifungal drugs
9. Second line of treatment including surgical intervention
10. Third line of treatment or adjunctive treatment with HBO, iron chelators
11. Maintenance therapy
12. Maxillofacial rehabilitation with maxillary reconstruction with bone grafts and implant placement or maxillofacial prosthetic rehabilitation of the face, nose and eyeball.
13. Periodic follow up.

Schematic representation of treatment plan for post covid Mucormycosis



Conclusion: -

The role of the dental surgeons and in particular, the maxillofacial surgeons at the early stages can avert the late complications and advanced surgical interventions. The dental surgeons should have basic knowledge about oral manifestations of post covid mucormycosis. They should do thorough clinical examination of the hard and soft tissues of the maxillofacial region and in particular the oral cavity. If they are able to perform early detection of

signs and symptoms like ulcerations, changes in the colour of the oral mucosa, sinus discharge and other features, they can refer the patient to the specialists like maxillofacial surgeons or ENT surgeons, who can start the first line of treatment and if required minimal surgical intervention.

The surgical phase again depends upon the severity of extension of the lesion. It may vary from simple extraction, multiple extraction, gingivoplasty, curettage, alveoloplasty, subtotal or partial maxillectomy to entire maxillectomy or even removal of the entire middle third of the face bilaterally involving the orbital region including the globe. Minor oral surgical procedures can be performed under local anaesthesia in the dental clinics with antibiotic coverage and antifungal coverage. Major surgical interventions like maxillectomy, orbital exenteration and other osteotomy surgeries are done under General anaesthesia. Associated systemic problems like existing diabetes or post covid diabetes should also be taken into consideration before planning for surgery. If the patients are continuing the blood thinners, then, INR values should be assessed and discussion with the patient's physician about the change of blood thinners or stopping should be carried out. A good team comprising pathologists, microbiologists or virologists, maxillofacial surgeons, ENT surgeons, chest physicians and neuro surgeons will give faster and better results.

References: -

1. Nilesh K, Vande AV. Mucormycosis of maxilla following tooth extraction in immunocompetent patients: Reports and review. *J Clin Exp Dent*. 2018;10(3): e300-e305.
2. A. Paltauf. *Mycosis mucorina*. Virchows Arch Pathol Anat Physiol Klin Med, 102 (1885), pp. 543-564.
3. A Skiada, C Lass-Floerl, N Klimko, A Ibrahim, E Roilides, G Petrikos, Challenges in the diagnosis and treatment of mucormycosis, *Medical Mycology*, Volume 56, Issue suppl_1, April 2018, Pages S93–S101.
4. Ibrahim AS, Spellberg B, Walsh TJ, Kontoyiannis DP. Pathogenesis of mucormycosis. *Clin Infect Dis*. 2012;54 Suppl 1(Suppl 1): S16-S22.
5. Wadhesh Kumar Singh, Ritu Singh, Shashank R. Joshi, Anoop Misra. Mucormycosis in COVID-19: A systematic review of cases reported worldwide and in India, *Diabetes & Metabolic Syndrome: Clinical Research & Reviews*. 2021.
6. Héctor Hernández Méndez, Alejandra Rodríguez Hidalgo. Endodontic patient with rhinocerebral mucormycosis: clinical case report. *Rev. Odont. Mex* 2015.vol.19 no.2.pp-120-125.
7. Nicolatou-Galitis, Ourania & Sachanas et al. Mucormycosis presenting with dental pain and palatal ulcer in a patient with chronic myelomonocytic leukaemia: case report and literature review. *JMM Case Reports*. 2015; 2. e000014-e000014.
8. Nishanth, Anitha, N. Aravindha Babu, L. Malathi. Mucormycosis - A Review. *European Journal of Molecular & Clinical Medicine*, 2020, Volume 7, Issue 3, Pages 1786-1791.
9. Rajendra Santosh, A.B., Muddana, K. & Bakki, S.R. Fungal Infections of Oral Cavity: Diagnosis, Management, and Association with COVID-19. *SN Compr. Clin. Med*. 2021.
10. Bell S, Mahoney L. Mucormycosis: a case study. *Crit Care Nurse*. 2000 Feb;20(1):18-23.
11. Chander, Jagdish. "Mucormycosis". *Textbook of Medical Mycology (4th ed.)* New Delhi: Jaypee Brothers Medical Publishers Ltd. 2018. pp. 534–596.
12. Dannaoui, Eric; Lackner, Michaela. "Special Issue: Mucorales and Mucormycosis". *Journal of Fungi*. 2020;6 (1): 6.
13. Mehta S, Pandey A. Rhino-Orbital Mucormycosis Associated with COVID-19. *Cureus*. 2020;12(9): e10726.
14. George Petrikos, Anna Skiada, Olivier Lortholary, Emmanuel Roilides, Thomas J. Walsh, Dimitrios P. Kontoyiannis, Epidemiology and Clinical Manifestations of Mucormycosis, *Clinical Infectious Diseases*, Volume 54, Issue suppl_1, February 2012, Pages S23–S34.
15. Kwon-Chung KJ. Taxonomy of fungi causing mucormycosis and entomophthoromycosis (zygomycosis) and nomenclature of the disease: molecular mycologic perspectives. *Clinical Infectious Diseases*, 2012; 54(suppl_1): S8-15.
16. Manjunatha BS, Das N, Sutariya RV, Ahmed T. Mucormycosis of the hard palate masquerading as carcinoma. *Clin Pract*. 2012;2(1): e28.
17. Kumar JA, Babu P, Prabu K, Kumar P. Mucormycosis in maxilla: Rehabilitation of facial defects using interim removable prostheses: A clinical case report. *J Pharm Bioallied Sci*. 2013;5(Suppl 2): S163-S165.
18. Alexandro Bonifaz, Andrés Tirado-Sánchez, Fernando Paredes-Farrera, Joaquín Moreno-Moreno, Javier Araiza, Gloria M. González, Oral involvement in mucormycosis. A retrospective study of 55 cases, *Enfermedades Infecciosas y Microbiología Clínica*, 2020.

19. McLean FM, Ginsberg LE, Stanton CA. Perineural spread of rhinocerebral mucormycosis. *American Journal of Neuroradiology*. 1996 Jan 1;17(1):114-6.
20. Bonifaz, Alexandro & Fuentes-Nava, Ana & Tirado, Andres & Kassack, Juan & Vega-Muñoz, Juan & Treviño-Rangel, Rogelio & González, Gloria. Gingival mucormycosis: case report and literature review. *Our Dermatology Online*. 2020.
21. Herrera DA, Dublin AB, Ormsby EL, Aminpour S, Howell LP. Imaging findings of rhinocerebral mucormycosis. *Skull Base*. 2009;19(2):117-125.
22. Lone PA, Wani NA, Jehangir M. Rhino-orbito-cerebral mucormycosis: Magnetic resonance imaging. *Indian Journal of Otolaryngology*. 2015 Jul 1;21(3):215.
23. Sugar AM. Mucormycosis. *Clin Infect Dis*. 1992;14(Suppl 1): S126–9.
24. Lafci Fahrioglu S, VanKampen N, Andaloro C. Anatomy, Head and Neck, Sinus Function and Development. In: *StatPearls*. 2021.
25. Cappello ZJ, Minutello K, Dublin AB. Anatomy, Head and Neck, Nose Paranasal Sinuses. In: *StatPearls*. 2021.
26. Agarwal M, Michel MA. Sino-orbital pathologies: An approach to diagnosis and identifying complications. *Appl Radiol*. 2017;46(8):8-20.
27. Odessey, E., Cohn, A., Beaman, K., & Schechter, L. Invasive Mucormycosis of the Maxillary Sinus: Extensive Destruction with an Indolent Presentation. *Surgical Infections*. 2008.9(1), 91–98.
28. Salisbury PL, 3rd, Caloss R, Jr, Cruz JM, et al. Mucormycosis of the mandible after dental extractions in a patient with acute myelogenous leukemia. *Oral Surg Oral Med Oral Pathol Oral Radiol Endod*. 1997; 83:340–4.
29. S Sarvestani A, Pishdad G, Bolandparvaz S. Predisposing Factors for Mucormycosis in Patients with Diabetes Mellitus; An Experience of 21 Years in Southern Iran. *Bull Emerg Trauma*. 2013;1(4):164-170.
30. Centers for Disease Control and Prevention (CDC). Fungal Diseases and COVID-19. January 12, 2021.
31. Revannavar SM, P S S, Samaga L, et al. COVID-19 triggering mucormycosis in a susceptible patient: a new phenomenon in the developing world. *BMJ Case Reports*. CP 2021;14: e241663
32. Soutik Biswas. Black fungus: India reports nearly 9,000 cases of rare infection. 23 May 2021.
33. Akshay Raut, Nguyen Tien Huy. Rising incidence of mucormycosis in patients with COVID-19: another challenge for India amidst the second wave. *Lancet Respir Med*. 2021.
34. Indian Council of Medical Research. Evidence based advisory in the time of COVID-19 (screening, diagnosis & management of mucormycosis). May 9, 2021.
35. M.S. Lionakis, D.P. Kontoyiannis. Glucocorticoids and invasive fungal infections. *Lancet*. 2003; 362, pp. 1828-1838.
36. C. Baldin, A.S. Ibrahim. Molecular mechanisms of mucormycosis -The bitter and the sweet. *PLoS Pathog*. 2017;13(8).
37. John TM, Jacob CN, Kontoyiannis DP. When Uncontrolled Diabetes Mellitus and Severe COVID-19 Converge: The Perfect Storm for Mucormycosis. *Journal of Fungi*. 2021; 7(4):298.
38. Thomas S, Patel D, Bittel B, et al. Effect of High-Dose Zinc and Ascorbic Acid Supplementation vs Usual Care on Symptom Length and Reduction Among Ambulatory Patients With SARS-CoV-2 Infection: The COVID A to Z Randomized Clinical Trial. *JAMA Netw Open*. 2021;4(2):e210369
39. Leonardelli F, Macedo D, Dudiuk C, et al. In Vitro Activity of Combinations of Zinc Chelators with Amphotericin B and Posaconazole against Six Mucorales Species. *Antimicrob Agents Chemother*. 2019;63(5): e00266-19.
40. Times of India. EXPLAINED: Can industrial oxygen be behind the outbreak of black fungus? May 28, 2021.
41. Zee Media Bureau. Re-using a mask could cause 'Fungus', experts suggest these tips to avoid infection. May 22, 2021.
42. Bhandari J, Thada PK, Nagalli S. Rhinocerebral Mucormycosis. In: *StatPearls*. 2021.
43. All India Institute of Medical Sciences. Covid-19 Infection and Rhino-orbito-cerebral Mucormycosis. Guidance for patients. May 18, 2021.
44. Directorate General of Health Services (DGHS). Guideline for management of Mucormycosis in Covid – 19 patients. 2021.
45. Noor A, Preuss CV. Amphotericin B. In: *StatPearls*. 2021.
46. Cornely OA, Alastruey-Izquierdo A, Arenz D, et al. Global guideline for the diagnosis and management of mucormycosis: an initiative of the European Confederation of Medical Mycology in cooperation with the Mycoses Study Group Education and Research Consortium. *Lancet Infect Dis*. 2019;19(12):e405-e421.
47. Kursun E, Turunc T, Demiroglu YZ, Alishkan HE, Arslan AH. Evaluation of 28 cases of mucormycosis. *Mycoses*. 2015;58(2):82-87.