



Journal Homepage: - [www.journalijar.com](http://www.journalijar.com)

## INTERNATIONAL JOURNAL OF ADVANCED RESEARCH (IJAR)

Article DOI: 10.21474/IJAR01/13418

DOI URL: <http://dx.doi.org/10.21474/IJAR01/13418>



### RESEARCH ARTICLE

#### DIAGNOSING NTM IN IMMUNOCOMPETENT CHRONIC LYMPHADENITIS: AN EMERGING ENTITY

Dr. Sushil Kumar Munjal<sup>1</sup>, Hari Babu Prasad<sup>1</sup> and Ajoy Kumar Verma<sup>2</sup>

1. Department of Tuberculosis and Respiratory Diseases, Sri Aubindomarg New Delhi, India.
2. Department of Microbiology, National Institute of Tuberculosis and Respiratory Diseases, Sri Aubindomarg New Delhi, India.

#### Manuscript Info

##### Manuscript History

Received: 19 July 2021

Final Accepted: 23 August 2021

Published: September 2021

#### Abstract

**Introduction:** Cervical lymph node infection due to nontuberculous mycobacteria in immunocompetent patients are emerging problem globally. It is presented as chronic enlargement of gland with pain and pus discharge sometimes. Traditionally diagnosis is done through clinical examination, lymph node aspirated samples pathological finding or ZN microscopy, which altogether indicate mycobacterial infection only, unable to differentiate MTB from NTM infection. Increasing incidence of LNTB cases not responding to antituberculous treatment prompted us to pinpoint the etiological agent by doing liquid culture of FNA samples in microbiology laboratory.

**Materials and Methods:** In this study 154 cases were recruited having chronic cervical lymph node swelling of suspicion of mycobacterial infection during January - December, 2014. Therein detailed history and thorough clinical examination of patients were reviewed. All patients were subjected for fine needle aspiration (FNA) using 10 ml syringe fitted with 21 G needle. The aspirated samples were subjected to smear microscopy by Ziehl-Neelsen (ZN) stain examination, May Grunwald - Giemsa stain and MGIT culture. Positive cultures were primarily identified by cord formation in ZN smear examination, detection of MPT-64 antigen by immuno-chromatographic test (Capilia test).

**Results:** A total 154 lymph node samples were received and processed for culture during the study period. Out of total suspects 7/154 (4.5%) were identified as non-tuberculous mycobacterial lymphadenitis. Clinical examination showed that all the seven cases were presented with lymph node swelling and fever and previous ATT history. Other features seen were pain (2/7; 28%), pus discharge (3/7; 42%) and montoux positive (3/7; 42%). The most common species identified was *M. chelonae* (3/7, 42%) followed by *M. fortuitum* (2/7, 28%), *M. abscessus* (1/7, 14%) and *M. terricomplex* (1/7, 14%). Four patients were managed surgically, one with surgical resection and medical treatment and 2 patients were lost to followup.

**Conclusion:** Definitive and detailed microbiological examination is vital for diagnosing the nontuberculous lymphadenitis. *M. chelonae* is an important etiological agent. NTMs are important definitive

Corresponding Author:- Dr. Sushil Kumar Munjal

Address:- Department of Tuberculosis and Respiratory Diseases, Sri Aubindomarg New Delhi, India.

etiological agents in cervical lymph node swelling. Clinical and pathological findings help in suspecting the infection.

*Copy Right, IJAR, 2021., All rights reserved.*

---

### **Introduction:-**

The incidence of Nontuberculous mycobacterium (NTM) is increasing in reported cases of pulmonary and extra pulmonary infections. Around 50 out of 125 NTM known species, are potential infective agents (1). Amongst the NTM associated extra pulmonary infections, cervical LN infection is the common site of involvement. NTM associated LN infection/diseases are usually seen in children but may have been reported in adults too (2,3). Traditionally diagnosis of lymph node aspirated samples is done through clinical examination, pathological finding or ZN microscopy, which altogether indicate mycobacterial infection only, unable to differentiate MTB from NTM infection. NTM are impossible to diagnose on clinical basis. Signs and symptoms of NTM and MTb infections are similar, which cannot be distinguished by radiological interventions or in pathology lab. The NTM infection may manifest mild or even destructive/fatal diseases (4). The drug susceptibility pattern of NTM are significantly different from mycobacterium tuberculosis infection. Separate drug regimens for different species are prescribed to control the NTM infections. Generally, based on clinical and pathological diagnosis patients are put on ATT treatment, who in case of non-resolving swelling, are treated with incision and drainage leading to sinus tract formation (5,6).

In routine practice, NTM infection is identified only when the patient stops responding to ATT regimen and put for further investigation i.e.cultureand identification. Increasing incidence of LNTB cases, not responding to antituberculous treatment prompted us to pinpoint the etiological agent by doing liquid culture of FNA samples in microbiology laboratory. Study was approved by research and ethical committee.

### **Aims and Objectives:-**

Diagnosing nontuberculous mycobacteria from patients of chronic cervical lymphadenitis and its clinical and pathological correlation.

### **Materials and Methods:-**

Patients with suspected tuberculous cervical lymphadenitis, who were attending the OPD and given consent were recruited in the study held during January - December, 2014. A detailed history and thorough clinical examination of patients was recorded. All patients with superficial cervical lymph nodes were subjected for fine needle aspiration (FNA) using 10 ml syringe fitted with 21 G needle. The aspirated samples were subjected for cross examinations in pathology and microbiology labs.

In pathology lab a portion of aspirate is used to prepare smear for cytological examination after air drying and fixing in methanol for 5 minutes. Fixed smears were used for May Grunwald - Giemsa stain (7).

In microbiology lab the lymph node aspirated samples were processed inside the BSL-3 facility. Samples were decontaminated and concentrated by the N-acetyl-Lcystein/sodium hydroxide (NALC-NaOH) method. Few millilitres of concentrated sample were used for smear microscopy by Zeihl Neelson (ZN) staining method and 500 µl of sediment was used for inoculation in 7ml of modified Middlebrook 7H9 broth base enriched with growth supplement and cocktail of antibiotics. The inoculation and incubation were done according to the BACTEC MGIT 960 Instrument Manual (8). Positive cultures were primarily identified by subcultures in BHIA, ZN smear examination, detection of MPT-64 antigen by immuno-chromatographic test (Capilia test)(9), as well as by various biochemical tests for NTM.

### **Results:-**

Clinical findings: After thorough clinical, pathological and microbiological investigation of suspected lymphadenitis cases 7 cases of NTM associated lymph node swelling were identified. The demographic profile of 7 nontuberculous mycobacterial lymphadenitis (NTM LAP) showed 5/7 (71.4%) were below 14 years and 2/7 (28.6%) were above 14 years and sex ratio female: male was 2.5:1 (71.4%). Clinical history showed following sign and symptoms; fever, enlargement of lymph node and history of ATT (standard regimen) in all the cases. Other sign and symptom observed during the study are pain in lymph node (1/7) (14%), pus discharge (2/7), unilateral enlargement

5/7 (71.4%), bilateral enlargement 2/7 (28.6%), single lymph node involvement 5/7(71.4%), matted lymph node 2/7 (28.6%), mobile lymph node (4/7), fixed lymph node 1/7 (14%), soft lymph node 5/7 (71.4%), firm lymph node 1/7(14%). All lymph nodes were > 1 centimetre. Fluctuations was present in 5/7(71.4%) patients. Other additional feature observed was scar over the swelling 1/7(14%). Minimum duration of symptom was 20 days to maximum duration of symptom was 180 days. Mantoux negative 5/7 (71.4%) and Mantoux positive 2/7 (28.65) with 5 tuberculin unit (TU). All patients were HIV negative.

Cytopathology results: In cytopathological examination following findings were observed; epithelioid granuloma with caseation (3/7), necrosis and inflammation (2/7) and occasional epithelioid cells with few inflammatory cells (2/7).

Microbiology results: A total 154 lymph node samples were received and processed for culture during the study period. Out of total sample, 27/154 (17.5%) was identified as mycobacterium tuberculosis lymphadenitis (MTB LAP) and 7/154 (4.5%) were non-tuberculous mycobacterial lymphadenitis (NTM LAP) cases. The 7 NTM were identified: M.chelonae (3/7, 42%), M. fortuitum (2/7, 28%), M. abscessus (1/7, 14%) and M.terrae complex (1/7, 14%) by using various biochemical tests.

Treatment history: All the patients diagnosed as NTM lymphadenitis advised therapy according to species and ATS guidelines 2007. 4/7 (57.1%) were treated with surgical excision and follow up showed no relapse and any reappearance of symptoms. 1/7 (14%) patients was treated with excision biopsy and followed by medical treatment for residual lymph nodes for 1 year. After 1 year there was resolution of residual nodes and without any relapse. 2/7 (28.6%) patients were lost follow up who were advised for surgical excision.

**Table 1:-** Sample distribution of suspected mycobacterial infection.

Parameter	Total number (%)
Total suspected lymph node samples	154
Smear positive	14
Culture positive	34
Mycobacterium tuberculosis complex	27
Nontuberculous mycobacterium	07

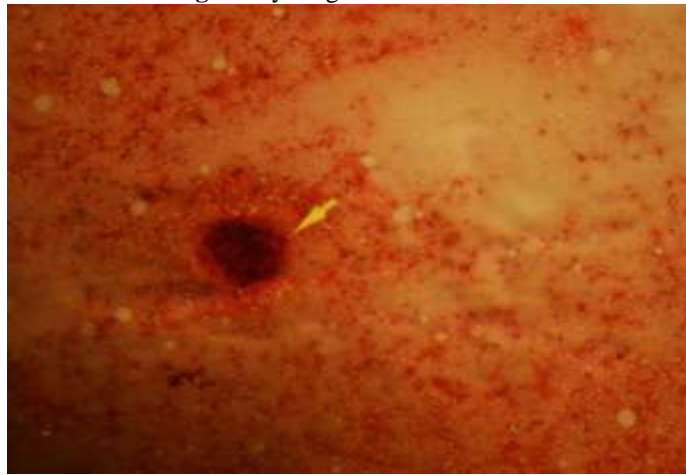
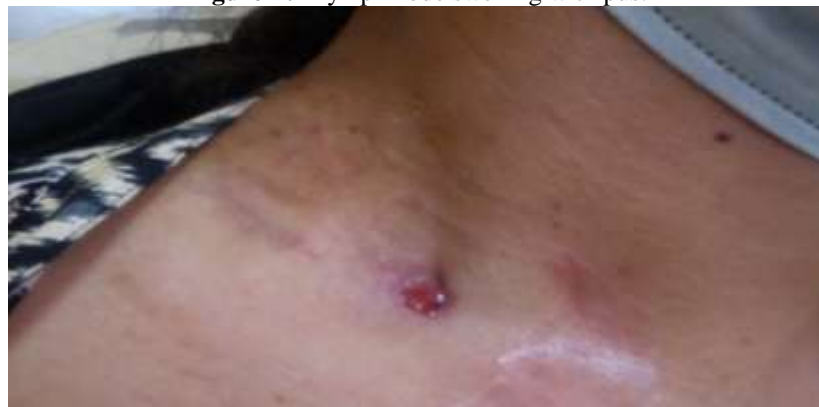**Table 2:-** Demographic profile of patients according to species.

NTM spp	Age in years	Sex	ATT history	MGIT Culture	Cyto-path results
M. Chelonea	5	M	Yes	Positive	epithelioid granuloma with caseation
M. Chelonea	16	F	Yes	Positive	epithelioid granuloma with caseation
M. Chelonea	14	M	Yes	Positive	occasional epithelioid cells with few inflammatory cells
Mfortuitum	12	F	Yes	Positive	epithelioid granuloma with caseation
Mfortuitum	11	F	Yes	Positive	epithelioid granuloma with caseation
M. abscessus	21	F	Yes	Positive	necrosis and inflammation
M.terrae complex	26M	F	Yes	Positive	epithelioid granuloma with necrosis

**Table 3:-** Clinical and pathological correlation.

NTM species	Size	Unilateral /bilateral	Single/matted	Consistency	Fluctuation	Scar	Contact history	pain
M. chelonae	>1cm	Unilateral	Single	Soft	Present	no	Absent	no
M.fortuitum	>1cm	bilateral	Single	firm	Absent	no	Absent	no
M.abscessus	>1cm	Unilateral	Single	Soft	Present	yes	Absent	yes

<b>M.terrae complex</b>	<b>&gt;1cm</b>	<b>unilateral</b>	<b>Matted</b>	<b>soft</b>	<b>present</b>	<b>No</b>	<b>Absent</b>	<b>no</b>
-------------------------	----------------	-------------------	---------------	-------------	----------------	-----------	---------------	-----------

**Fig 1:-** Cytological Examination.**Figure-2:-** Lymph node swelling with pus.**Table 3:-** Clinical and pathological correlation.

<b>NTM species</b>	<b>Size</b>	<b>Unilateral /bilateral</b>	<b>Single/matted</b>	<b>Consistency</b>	<b>Fluctuation</b>	<b>Scar</b>	<b>Contact history</b>	<b>pain</b>
<b>M. chelonae</b>	<b>&gt;1cm</b>	<b>Unilateral</b>	<b>Single</b>	<b>Soft</b>	<b>Present</b>	<b>no</b>	<b>Absent</b>	<b>no</b>
<b>M.fortuitum</b>	<b>&gt;1cm</b>	<b>bilateral</b>	<b>Single</b>	<b>firm</b>	<b>Absent</b>	<b>no</b>	<b>Absent</b>	<b>no</b>
<b>M.abscessus</b>	<b>&gt;1cm</b>	<b>Unilateral</b>	<b>Single</b>	<b>Soft</b>	<b>Present</b>	<b>yes</b>	<b>Absent</b>	<b>yes</b>
<b>M.terrae complex</b>	<b>&gt;1cm</b>	<b>unilateral</b>	<b>Matted</b>	<b>soft</b>	<b>present</b>	<b>No</b>	<b>Absent</b>	<b>no</b>

**Discussion:-**

In high TB burden countries like India the cervical lymph adenitis cases should be thoroughly investigated for NTM infection as per national and international guidelines (10,11,12). Cervical lymph node involvement is the most common site in case of NTM-LAP. Hazara et al in his study has also observed that the most common manifestation of infection due to nontuberculous mycobacteria (NTM) in children is cervical lymphadenitis. He identified 19 cases of proven lymphadenitis due to NTM in a years' span (13). This study has shown that NTM LAP is seen mostly in the children but can also be seen in young adults with predominance in female population. Lai et al. from Boston showed that atypical mycobacterium in lymphadenitis is commonly seen in children and with female predominance (14). Piersimoni et al discussed that NTM lymphadenitis is an indolent disease; most patients are otherwise healthy and

have as their sole clinical sign a chronic neck mass that does not respond to antimicrobial drug therapy (15). In our study NTM adenitis patients barring fever other symptom were not common but should be investigated thoroughly if symptom like pain, pus discharge. Chronic enlarged, non-tender mass in the cervico facial area present from weeks to months, unresponsive to antimicrobials are significant clues for diagnosing NTMLAP (16,17). In our study also patients of NTMLAP presented with chronic enlargement, pain in some cases and pus discharge in one case. The NTM species involvement in lymphadenitis are reported differently in different at different geographic location, time and place. During 1970 *Mycobacterium scrofulaceum* was common species, subsequently it was replaced by *M. avium-intracellulare* complex, However, in two recent studies, *M. haemophilum* was recognized as an important pathogen in children with NTM adenitis, and was isolated in 24–51% of cases with positive cultures (18,19,20,21). However in present study the common NTM identified were *M. chelonae*, *M. fortuitum* and *M. abscessus*. Chetchotisakd et al and Zacharia et al described that rapidly growing mycobacteria are the etiological agents in the cases of chronic bilateral lymphadenitis patients in patients having opportunistic coinfection and reactive skin diseases (22,23). In this study rapidly growing mycobacteria were found without any opportunistic co infection. While NTM cervical lymphadenitis has been successfully treated in children with antimicrobials, surgery, or both, as well as observation alone (24,25). Current ATS/IDSA guidelines recommend complete surgical excision in immunocompetent patients and antimicrobial therapy based on NTM species (19). In this study also the patients were managed with specific protocol depending upon the case i.e surgery alone, only by appropriate antimicrobial and thorough complete surgical resection followed by medical treatment.

### Conclusion:-

NTMs are important definitive etiological agents in cervical lymphnode swelling. Definitive and detailed microbiological examination is vital for proper treatment and patient management. Surgical management along with appropriate antibacterial agents like clarithromycin has shown, potential in complete remission of disease progression. Timely and reliable identification of isolates will help in managing the affected patients.

### References:-

1. Maiga M1., Siddiqui S, Diallo S, Diarra B, Traore B, Shea Y R , Zelazny A M , Dembele B P P, Goital D, Kassambara H, Hammond A S , Polis M A , Tounkara A. Failure to recognize nontuberculous mycobacteria leads to misdiagnosis of Chronic Pulmonary Tuberculosis. PLoS ONE 2012; 7: e36902.
2. Marras TK, Daley CL Epidemiology of human pulmonary infection with
3. nontuberculous mycobacteria. Clin Chest Med 2002; 23: 553–567.
4. Tortoli E. Impact of genotypic studies on mycobacterial taxonomy: the
5. new mycobacteria of the 1990s. Clin Microbiol Rev 2003 16: 319–354.
6. Hazra R, Robson CD, Perez-Atayde AR, Husson R. Lymphadenitis
7. due to nontuberculous mycobacteria in children: presentation
8. and response to therapy. Clin Infect Dis 1999;28:123–129.
9. Inderlied CB, Kemper CA, Bermudez LE. The mycobacterium
10. avium complex. Clin Microbiol Rev 1993;6:266–310.
11. Al Jarad N, Demertzis P, Jones DJ, Barnes NC, Rudd RM, et al. Comparison
12. of characteristics of patients and treatment outcome for pulmonary non-tuberculous mycobacterial infection and pulmonary tuberculosis. Thorax 1996;51: 137–139.
13. Hematology: Principles and Procedures, Sixth Edition, Brown AB, Lea & Febiger, Philadelphia 1993; p101.
14. Hanna BA, Ebrahimzadeh A, Elliott LB, Morgan MA, Rusch-Gerdes S, Cio M, et al. Multicenter evaluation of the BACTEC MGIT 960 system for the recovery of mycobacteria. J Clin Microbiol. 1999;37:748–752.
15. G-H. Shen,\*† C-H. Chen,‡ C-H. Hung,§ K-M. Wu,¶ C-F. Lin,# Y-W. Sun,¶ J-H. Chen. Combining the Capilia TB assay with smear morphology for the identification of *Mycobacterium tuberculosis* complex. INT J TUBERC LUNG DIS 13(3):371–376.
16. Standard for TB Care in India- World Health Organization . www.searo.who.int/india/mediacenter/event/2014/.pdf. Griffith D E, Aksamit T, Brown-Elliott B A, et al. An official ATS/IDSA statement: diagnosis, treatment, and prevention of non-tuberculous mycobacterial diseases. Am J Respir Crit Care Med 2007; 175: 367–416.
17. American Academy of Pediatrics. Tuberculosis. In: Peter G, ed. 1997 Red book: report of the Committee on Infectious Diseases. 24th ed. Elk Village, Illinois: American Academy of Pediatrics, 1997:541–546.
18. Hazra R, Robson C D, Perez-Atayde A R, and. Husson R N. Lymphadenitis Due to Nontuberculous Mycobacteria in Children: Presentation and Response to Therapy. Clin Infect Dis 1999;28:123–129.

19. Lai, KK, Stottmeier KD, Sherman IH, McCabe WR. Mycobacterial cervical lymphadenopathy, Relation of etiologic agents to age. *JAMA* 1984; 251: 1286-1288.
20. Piersimoni C and Claudio Scarparo. Extrapulmonary Infections Associated with Nontuberculous Mycobacteria in Immunocompetent Persons. *Emerging Infectious Diseases* 2009;15: 1351-1358.
21. Stewart MG, Starke JR, Coker NJ. Nontuberculous mycobacterial infections of the head and neck. *Arch Otolaryngol Head Neck Surg* 1994;120:873-876.
22. Thompson JN, Watanabe MJ, Greene GR, Morozumi PA, Kohut RI. Atypical mycobacterial cervical adenitis: clinical presentation. *Laryngoscope* 1980;90:287-294.
23. Wolinsky E. Mycobacterial lymphadenitis in children: a prospective study of 105 nontuberculous cases with long-term follow-up. *Clin Infect Dis* 1995; 20: 954-963.
24. Griffith DE, Aksmit T, Brown-Elliot BA, et al. American Thoracic Society: diagnosis, treatment and prevention of nontuberculous mycobacterial diseases. *Am J Respir Crit Care Med* 2007; 175: 367-416.
25. Lindeboom JA, Prins JM, Bruijnesteijn van Coppenraet ES, Lindeboom R, Kuijper E. Cervical lymphadenitis in children caused by *Mycobacterium haemophilum*. *Clin Infect Dis* 2005; 41: 1569-1575.
26. Haimi-Cohen Y, Amir J, Ashkenazi S, et al. *Mycobacterium haemophilum* and lymphadenitis in immunocompetent children, Israel. *Emerg Infect Dis* 2008; 14: 1437-1439.
27. Chetchotisakd P, Kiertiburanakul S, Mootsikapun P, Assanasen S, Chaiwarith R, and Anunnatsiri S. Disseminated Nontuberculous Mycobacterial Infection in Patients Who Are Not Infected with HIV in Thailand. *Clinical Infectious Diseases* 2007; 45:421-427.
28. Zacharia A, Eidlitz-Markus T, Haimi-Cohen S, Samra Z, Kaufman L, Amir J. Management of nontuberculous mycobacteria-induced cervical lymphadenitis with observation alone. *Pediatr Infect Dis J* 2008; 27: 920-922.
29. Zeharia, A., T. Eidlitz-Markus, Y. Haimi-Cohen, et al. 2008. Management of nontuberculous mycobacteria-induced cervical lymphadenitis with observation alone. *Pediatr. Infect. Dis. J.* 27:920-922.
30. Pilkington, E., C. MacArthur, S. Beekman, et al. 2010. Treatment patterns of pediatric nontuberculous mycobacterial (NTM) cervical lymphadenitis as reported by nationwide surveys of pediatric otolaryngology and infectious disease societies. *Int. J. Pediatr. Otorhinolaryngol.* 2010;74:343-346.