



CODEN [USA]: IAJPBB

ISSN : 2349-7750

## INDO AMERICAN JOURNAL OF PHARMACEUTICAL SCIENCES

SJIF Impact Factor: 7.187

Online at: <http://www.iajps.com>

Research Article

### KNOWING THE MICROPERIMETRY OR OPTICAL COHERENCE TOMOGRAPHY WHICH MAY IDENTIFY POTENTIAL ILLNESS IN INDIVIDUALS HAVING SOLITARY FOCAL ISCHEMIC GLAUCOMATOUS FELLOW EYE

**Dr. Hafiz Muhammad Jahan Zaib, Dr. Inayat Ullah Khan, Dr. Ijaz Khan, Dr. Syed  
Muhammad Waleed, Dr. Khadija Khan, Dr. Amina Khalid**

Pakistan Institute of Medical Sciences, Islamabad

**Article Received: July 2021**

**Accepted: July 2021**

**Published: August 2021**

**Abstract:**

***Aim:** Individuals with solitary focal ischemic glaucoma may be able to identify early illness in the opposite eye using microperimetry or optical coherent tomography.*

***Methods:** Thirty-nine successive percent of adults having unilateral focal ischemic glaucoma and independent split-fixation were studied. Graphic field fault on simple product perimetry was chosen, having normal SAP in the other eye. Our current research was conducted at Mayo Hospital Lahore from March 2020 to February 2021. All patients had microperimetry of the central 12 degrees and OCT tomography of retinal nerve fiber layer in both eyes. Other eye OCT imaging revealed that the retinal nerve fiber layer had thinned and/or reduced sensitivity.*

***Results:** As a result of microperimetry, thirty other eyes showed aberrant global thresholds, and 23 had aberrant OCT imaging tests. Among tests in the opposite eye, Kappa agreement was poor ( $p = 0.2549$ ). Microperimetry revealed that fixation in other eyes was considerably poorer than in glaucoma-affected eyes ( $p 0.002$ ). Microperimetry revealed reduced retinal sensitivity at fixation in the other affected eyes.*

***Conclusion:** Most individuals with solitary ischemic focal glaucoma have reduced retinal fixation sensitivity, and OCT indicates pivotal depletion of retinal nerve fiber layer in the other eye. OCT imaging of the optic disc in this clinical situation must be correlated using microperimetry in the opposite eye.*

***Keywords:** Microperimetry, Optical Coherence Tomography.*

**Corresponding author:**

**Dr. Hafiz Muhammad Jahan Zaib,**

*Pakistan Institute of Medical Sciences, Islamabad*

QR code



*Please cite this article in press Hafiz Muhammad Jahan Zaib et al., Knowing The Microperimetry Or Optical Coherence Tomography Which May Identify Potential Illness In Individuals Having Solitary Focal Ischemic Glaucomatous Fellow Eye., Indo Am. J. P. Sci, 2021; 08(08).*

**INTRODUCTION:**

In the globe, glaucoma is the main risk factor in the development blindness, with retinal ganglion cells permanently lost. Many types of glaucomatous optic neuropathy are characterized by early impairments in the peripheral or paracentral visual area [1]. Early in the phase of the disease, fixation may be compromised due to localized notching of neuroretina rim and concomitant visual field loss ("split-fixation" visual field defect). Women, younger ages, and repeated optic nerve hemorrhage are all linked with the subtype of focal ischemic glaucoma [2]. Other risk factors include nocturnal hypotension, vasospasm, migraine, and Raynaud's singularity. Those through central ischemic glaucoma experience loss of retinal awareness at or around the site of fixation [3]. Glaucoma in these patients' other eyes must be detected early to avoid the possibility of permanent, bilateral central visual field abnormalities that might impair reading abilities and statutory driving limits. Life quality is negatively impacted by early visual field defects. Standard automated perimetry can identify neuroretina rim defects before visual field impairments. As a result, it is necessary to develop more sensitive functional perimetric instruments. In microperimetry, the retinal sensitivity may be measured at precise places on the fundus using perimetry led by the fundus [4]. It has been utilized in certain glaucoma clinical trials; however, the focus is on macular sensibility rather than peripheral retinal sensitivity. The aim of this exercise was to see if micro-perimetry and optical coherence tomography (OCT) imaging of the parotid retinal nerve fiber layer could tool to analyze disorders in the fellow eye of patients with suspected legislative focal ischemic glaucoma who had achieved a full visual field on SAP in the fellow eye. We were also curious to investigate if abnormalities observed by microperimetry and OCT imaging in much the same eye were identical [5].

**METHODOLOGY:**

A glaucoma clinic at Mayo Hospital in Lahore, Pakistan was used to enroll potential patients for the study. Between March 2020 and February 2021, patients who met the inclusion criteria and consented to cooperate in the trial were selected in a sequential manner: 46 individuals were included in the research. Primary focal ischemic glaucoma optic neuropathy in adults (>19 years of age); localized neuroretina rim loss on physical exam confirmed by OCT imaging of the papillary retinal nerve fiber layer; and congruent unilateral visual field loss near to obsession on SAP. At least one point on the design deviation test that was outside of normal boundaries was detected as having a p value of less than 0.04 percent. Better than Log MAR

0.7 visual acuity in either eye; myopia of more than 9.00 DS or hypertrophy of more than +6.00 DS; inability to perform perimeter for any reason; macular pathology in the constructive, fellow eye recognized medically or on OCT imaging of the macula; non-glaucoma optic nerve pathology; significant lens or posterior capsular opacity in the fellow eye; ocular history. Our current research was conducted at Mayo Hospital Lahore from March 2020 to February 2021.

**Statistical Analysis:** The Shapiro–Wilk technique was used to determine normalcy. To evaluate the data of two eyes, paired t-tests or Wilcoxon signed-rank tests remained used. The Spearman rank association was utilized to evaluate the relationship of microperimetry and OCT. With Kappa's approval, this was investigated further.

**RESULTS:**

The mean microperimetry barrier in the glaucoma eyes was 19.7 6.5 dB compared to 27.5 2.5 dB in control eyes (p 0.06). The median microperimetry verges of eyes by focal ischemic glaucoma and healthy eyes were examined. Shapiro–Wilk testing revealed that information for glaucoma eyes remained not uniformly distributed, but the data for the other eyes were. The Wilcoxon signed-rank test remained performed to examine difference microperimetry regular brinks among it two eyes (p 0.0002; Fig. 2a). The overall RNFL height in glaucoma eyes was 72.8 12.7 m against 86.7 12.4 m in nonglaucoma eyes (p 0.07). The typical RNFL thickness measurements (global value) using OCT imaging remained evaluated among eyes with focal ischemic glaucoma and healthy eyes. Both data sets were found to be normal by Shapiro–Wilk. Whenever the micro-perimetry averages of lowermost five readings in surgeon's fellow eyes labelled OCT imaging as "outside of normal limits" remained related to those chosen as "inside reasonable boundaries," there has been no substantial difference (Fig. 2b; Table 2). On microperimetry, 32 of the 42 colleague eyes showed aberrant global retinal sensitivity levels, and 21 had abnormal OCT imaging tests (Table 2 and Fig. 1). Once those tests remained shared, only four other eyes showed normal OCT imaging findings and normal microperimetry retinal sensitivity. For colleague eyes, the Kappa concordance for microperimetry and OCT was 0.089231 (SE = 0.135167). The 96% CI for kappa = 0.175689 to 0.35416 (p = 0.2547). On microperimetry evaluation, two-way obtained through different testing with Bonferroni adjustment for continuous outcomes indicated a significant relationship seen between inner ring and other rings for both glaucoma eyes besides attached eyes (p

0.006). The change in attached eyes remained inside test–retest limits, but not in glaucoma eyes (Supplement 2). Figure 3 depicts an average of retinal sensitivity values obtained by microperimetry in

glaucoma and healthy eyes at every retinal location. This indicate that consumers with focal ischemic glaucoma have decreased retinal sensibility in the superior macula.

**Table 1:**

	Study Eye	Glaucoma Eye
Age		73 (52 to 86)
Sex		
Man	25 (mean age—67.2)	
Woman	15 (mean age—71.8)	
Central corneal thickness	539 (451 to 632)	538 (450 to 616)
Visual acuity	-0.08 (-0.20 to +0.10)	-0.07 (-0.20 to +0.30)
Pattern standard deviation	1.84 (1.16 to 3.08)	7.86 (3.42 to 13.54)
Number of topical glaucoma agents	1.43 (0 to 3)	1.64 (0 to 3)

**Table 2:**

	Microperimetry abnormal	Microperimetry normal
OCT Non-Normal	18	5
OCT normal	14	6

**Figure 1:**

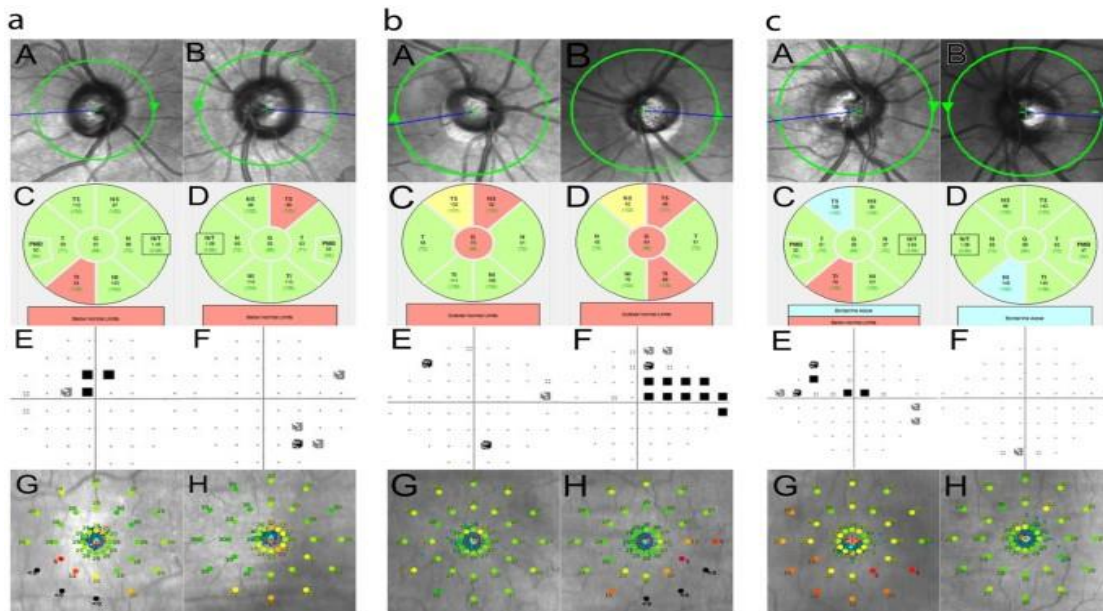


Figure 2:

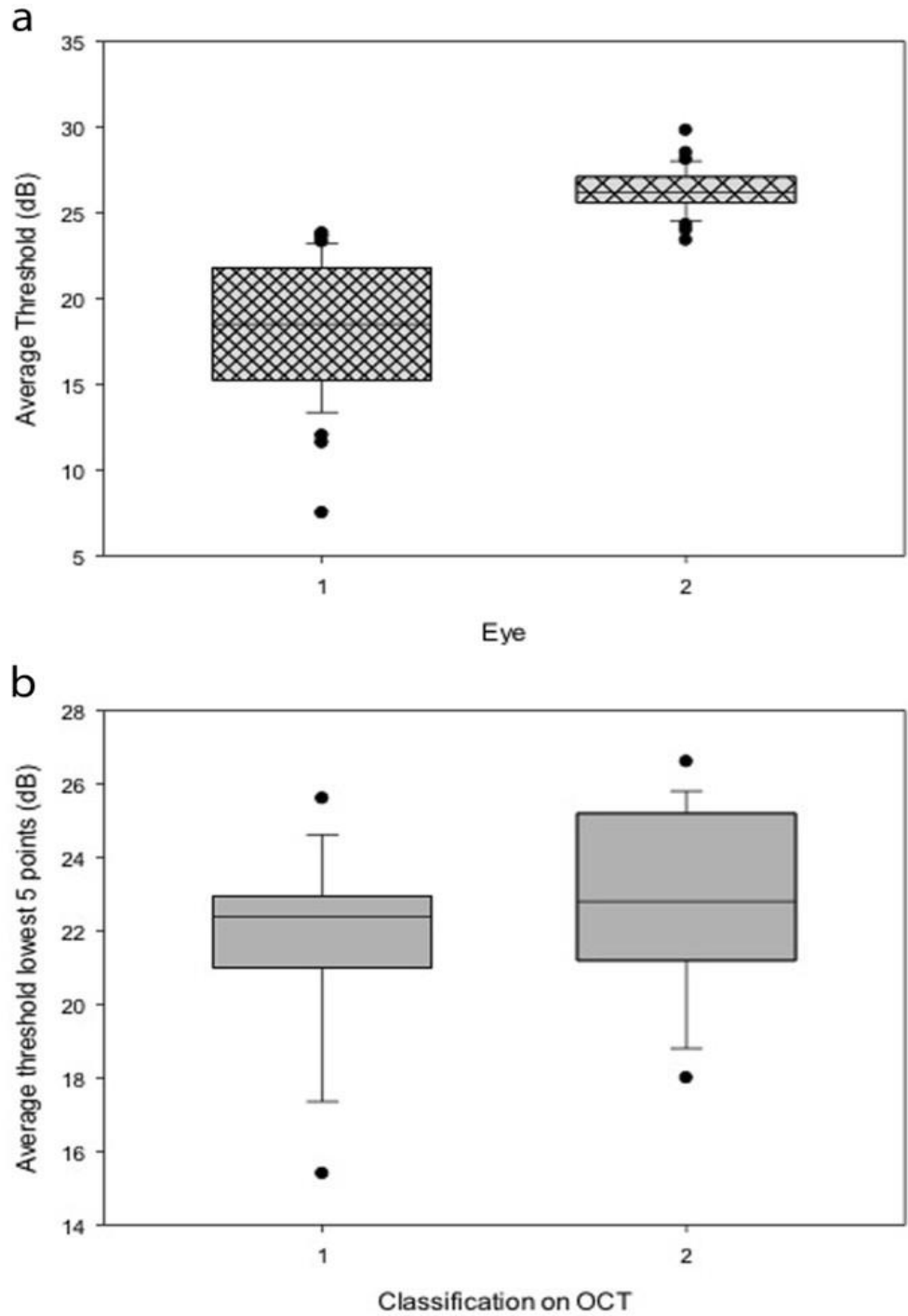
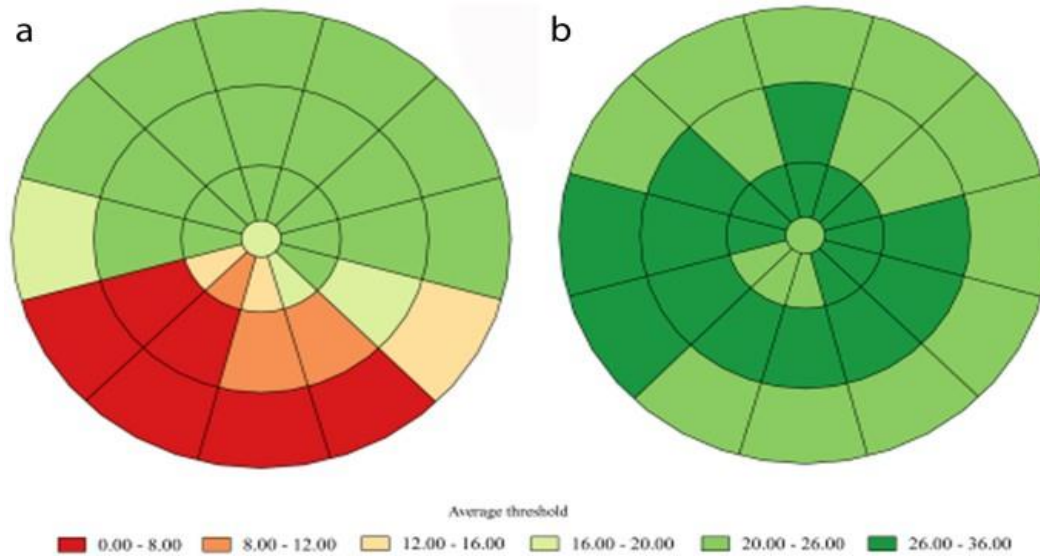


Figure 3:



### DISCUSSION:

Throughout this investigation, we discovered that the majority of clinically suspected unilateral focal ischemia glaucoma and the normal SAP test in other eye exhibit irregularities on OCT imaging of RNFL (57%) or decreased retinal sensitivity on microperimetry (82%) in the other eye [6]. In entirely, 86 half of residents exhibited irregularities on whichever microperimetry or OCT imaging, and only seven individuals out of 39 with suspected unilateral illness had normal testing through both OCT imaging and microperimetry in partner eye. Microperimetry is an excellent functional technique for detecting modest visual field impairments in fellow eyes in the current individual population, wherever scotomas are expected to form near to fixation [7]. This subjective test has become recognized as a reliable primary outcome in macular illness clinical trials for the assessment of retinal sensitivity and fixation behavior thresholds. Microperimetry is most commonly employed in medical glaucoma investigations to assess useful features of the center 13 degrees surrounding fovea, although it cannot presently measure visual field impairments in the peripheral retina [8]. Real-time eye tracking and testing modifications, in principle, enhance dependability of threshold measurements owing to constancy of visual space being tested and during examination, however it's not been objectively validated. It is unexpected to find statistically significant worse fixation in the fellow eye in individuals in this research where focus is compromised in the eye with glaucoma [9]. The causes for this result are unknown, although it is conceivable that glaucoma-affected eyes have evolved

to maintain stable fixation with the tiny, central visual field deficiency. Furthermore, in one research, the test-retest variability of microperimetry was characterized and shown to be superior in healthy eyes as contrasted to eyes having fixation-threatening glaucoma. Microperimetry fixation instability was already proposed as an early indicator of glaucoma [10].

### CONCLUSION:

Finally, focal ischemic glaucoma is distinguished by primary visual field impairments that jeopardize fixation. In children with spastic illness, early detection and treatment of illness in the other eye is serious to avoid bilateral central scotomas, that can impair reading or driving vision. SAP is frequently used as a main diagnostic technique to detect early illness in neighboring eyes. Our current research shows that microperimetry and OCT imaging of RNFL can way to recognize illness in individuals with suspected one-sided focal ischemic glaucoma who had regular SAP testing in the colleague eye. These tests may have a significant medical benefit in lowering danger of bilateral vision damage in patients.

### REFERENCES:

1. Sommer A, Katz J, Quigley HA, Miller NR, Robin AL, Richter RC, et al. Clinically detectable nerve fiber atrophy precedes the onset of glaucomatous field loss. *Arch Ophthalmol.* 2019;109:77–83. [[PubMed](#)] [[Google Scholar](#)]
2. Kerrigan-Baumrind LA, Quigley HA, Pease ME, Kerrigan DF, Mitchell RS. Number of ganglion

- cells in glaucoma eyes compared with threshold visual field tests in the same persons. *Invest Ophthalmol Vis Sci.* 2020;41:741–8. [[PubMed](#)] [[Google Scholar](#)]
3. Reyes RD, Tomita G, Kitazawa Y. Retina nerve fiber layer thickness within the area of apparently normal visual field in normal tension glaucoma with hemifield defect. *J Glaucoma.* 2018;7:329–35. [[PubMed](#)] [[Google Scholar](#)]
  4. Guedes V, Schuhman JS, Hertzmark E, Wollstein G, Correnti A, Mancini R, et al. Optical coherence tomography measurement of macular and nerve fiber layer thickness in normal and glaucomatous human eyes. *Ophthalmology.* 2013;110:177–89. [[PMC free article](#)] [[PubMed](#)] [[Google Scholar](#)]
  - Lisboa R, Leite MT, Zangwill LM, Tafreshi A, Weinreb RN, Medeiros FA. Diagnosing preperimetric glaucoma with spectral domain optical coherence tomography. *Ophthalmology.* 2019;119:2261–9. [[PMC free article](#)] [[PubMed](#)] [[Google Scholar](#)]
  5. Weingessel B, Sacu S, Vécsei-Marlovits PV, Weingessel A, Weingessel A, Richter-Mueksch S, et al. Interexaminer and intraexaminer reliability of the microperimeter MP. *Eye (Lond)* 2019;23:1052–8. [[PubMed](#)] [[Google Scholar](#)]
  6. Okada K, Watanabe W, Koike I, Tsumamoto Y, Mishima HK. Alternative method of evaluating visual field deterioration in very advanced glaucomatous eye by microperimetry. *Jpn J Ophthalmol.* 2013;47:178–81. [[PubMed](#)] [[Google Scholar](#)]
  7. Miglior S. Microperimetry and glaucoma. *Acta Ophthalmol Scand Suppl.* 2002;236:19. [[PubMed](#)] [[Google Scholar](#)]
  8. Rensch F, Jonas JB. Direct microperimetry of alpha zone and beta zone parapapillary atrophy. *Br J Ophthalmol.* 2018;92:1617–9. [[PubMed](#)] [[Google Scholar](#)]
  9. Oztürk F, Yavas GF, Küsbeci T, Ermis SS. A comparison among Humphrey field analyzer, Microperimetry, and Heidelberg retina tomograph in the evaluation of macula in primary open angle glaucoma. *J Glaucoma.* 2018;17:118–21. [[PubMed](#)] [[Google Scholar](#)]