

Prosthetic management of oromaxillary defect: A case report.

Beenish Javed¹, Swatantra Agarwal², Dipti Nayak¹, Kunal Singh¹.

¹Post graduate student, Department of Prosthodontics and Crown and Bridge Kothiwal Dental College, Moradabad.

²Principal and Head, Department of Prosthodontics and Crown and Bridge, Kothiwal Dental College, Moradabad.

Abstract

Congenital or acquired defect of the palate resulting in communication between oral cavity and nose/or maxillary sinus requires management which presents challenge to the clinician. An obturator is a maxillofacial prosthesis used to close a congenital or acquired tissue opening, primarily of the hard palate and/or contiguous alveolar/soft tissue structures. It must be comfortable, esthetically acceptable, easy to fabricate, and lightweight, and must restore functions such as mastication, deglutition, and speech. This case report describes the fabrication of closed hollow bulb obturator restoring the patient's original dentition and facial and palatal form.

Keywords: Maxillofacial prosthesis, closed hollow bulb obturator, partial maxillectomy.

Address of correspondence: Dr. Kunal Singh, PG boys hostel, Kothiwal Dental College and Research Centre, Moradabad.

Email- e-mail: kunal.charlie@gmail.com

Submitted: 31-Mar-2021 **Revised:** 4-Apr-2021 **Accepted:** 9-Apr-2021 **Published:** 15-Apr-2021

Introduction

Maxillofacial defects which cause facial disfigurement affects the quality of life of the patient. Maxillary defects must be the most common cause among all intraoral defects that can appear in the form of communication between oral cavity and maxillary sinus or nasopharynx. Depending on their origin, side effects can be congenital and acquired, which may result due to some injury or surgery. Such defects vary on the basis of etiology, location and size. The size of the defect may be from small to large, including soft palate, hard palate alveolar bone, floor of nasal cavity, maxillary sinus which may extend up to floor of orbit and zygomatic complex.^[1]

Small sized defect can be easily reconstructed surgically leading to favourable tissue response. Large maxillary defects are often associated with the loss of hard tissues including bone and teeth complicated with overlying soft tissue collapse.^[2] In general, such defects can be prosthodontically rehabilitated by prosthesis called obturator. The maxillofacial prosthodontist, as a member of the surgical team, aids in the recovery and rehabilitation of the maxillectomy patient by fabricating and placing a surgical obturator.^[3] Placement of a surgical

obturator during the intervention is the usual treatment sequence followed. Following this, five to ten days later it is removed, and a removable interim obturator is constructed for the wound healing period. Finally, the definitive obturator is constructed and placed about 3–6 months post-surgery, when major changes in tissue conformation are no longer expected.^[4] Because of communication between the oral cavity, the nasal cavity and maxillary sinus, insufficient retention and stability is provided. Another reason for impaired retention is increased volume and weight of the obturator which results in prosthetic loosening. To avoid this, fabrication of closed hollow bulb obturator is recommended.^[5]

The present case report describes the fabrication of closed-hollow bulb obturator for restoration of patient's function, phonetics and esthetics.

Case Report

A fifty one year old male patient reported to the department of Prosthodontics and Crown & Bridge with the complaint of nasal discharge and a hole in his left side of palate since 10 month. An intraoral examination revealed that patient had

undergone partial maxillectomy for mucormycosis (superimposed with osteomyelitis) of left maxilla. The defect was a partial edentulous arch with Aramany's class I defect (Figure 1) according to Aramany's classification (resection along the midline of the maxilla teeth maintained on one side of arch).^[6] The treatment plan was to fabricate a closed hollow bulb obturator for the defect.

Procedure

The patient was examined carefully and further preparations for fabrication of obturator were initiated.

1. A dampened gauze tied to a suture thread was placed in the surgical site to cover the unwanted undercuts (anterior and medial) and to aid in removal of the impression.
 2. A dentulous, perforated tray was selected and the preliminary impressions of the maxillary and the mandibular arch were made with alginate (irreversible hydrocolloid, Zhermack, Italy). Before making the impressions, defect was cleaned free of mucus crustings. It was ensured to involve the lateral and posterior margin of the defect (Figure 2). The impression was poured with type III gypsum material (Kalstone; Kalabhai Karson, Mumbai, India) to obtain a working cast.
 3. The cast was retrieved (Figure 3) and the undercuts were blocked out with the dental wax. A prosthetic baseplate was fabricated with autopolymerized acrylic resin (DPI Cold Cure; Dental Products of India).
 4. Border molding was done first on the un-resected side and then on the resected side (Figure 4) using the green stick compound (DPI Tracing Sticks, Dental Products of India, Mumbai, India). Patient was asked to perform exaggerated head movements turning right to left with the head level and then with the neck flexed and extended.
- Also, patient was asked to open and close the mouth and move the mandible laterally. The final impression was taken with elastomeric impression material (Aquasil, Dentsply) followed by an alginate pick up impression to record the remaining teeth (Figure 5).
5. The master cast was retrieved and denture base and occlusal rims were fabricated. The maxillomandibular relationships were recorded. The casts were mounted on a articulator, and the artificial teeth were arranged. To obtain balanced occlusion, occlusal disharmonies were corrected with selective grinding as with conventional complete dentures.
 6. A clinical wax try-in was performed to evaluate the esthetics and occlusion (Figure 6, 7). After the try in of the waxed up palatal obturator prosthesis the master cast was invested along with the trial prosthesis in the Hanau's Flask. After that dewaxing procedure was performed in conventional manner.
 7. The packing of the prosthesis was done in two parts. The bulb portion was first packed followed by the remaining part of the prosthesis containing teeth. Bulb portion of the prosthesis was made hollow by filling the defect with the table salt. The two halves of the flask were closed and curing was completed using short curing cycle. On completion of curing, a small hole was made on the base of the hollow bulb and to dissolve all the salt, it was placed in water. Wash the hollow bulb with water in syringe to completely remove the salt. It was then sealed with auto-polymerizing resin. The obturator was finished, polished and inserted in the patient's mouth (Figure 8).
 8. At the time of insertion, patient was educated regarding mastication and speech. The post insertion follow up was done at an interval of 24 hours, three days and one week. At subsequent post-insertion appointments, the patient

reported satisfaction with the denture with respect to comfort, function and esthetics.

Discussion

Prosthetic rehabilitation of edentulous patients with maxillectomy defects is often difficult because of the absence of natural teeth to retain and support an obturator. Retention is severely compromised in these patients resulting in difficulties in speech and mastication. The primary goal of the treatment is to give a prosthetic obturation which closes the defect and separates the oral cavity from the sino-nasal cavities.^[7]

Fabrication of definitive prosthesis is the last active phase of rehabilitation of maxillary defect patients. The definitive prosthesis has different rationale and designing aspects when compared to others

The definitive prosthesis should restore the anatomy on oral side and to obturate the defect-on-defect side. The maxillary obturator will have artificial teeth, artificial palate and bulb to fill the defect. The defect part is to be rehabilitated with part of prosthesis known as bulb.^[8]

Wu and Schaaf reported that the weight reduction of hollow-type obturator prostheses ranged from 6.55% to 33.06%, depending on the size of the defect. It helps in resonance for speech production, more comfortable for the patient, provide support to facial soft tissue and helps in restoring facial form. The closed bulb design is more commonly recommended when compared to open design. In restricted mouth opening, size of the bulb should not interfere with prosthesis insertion. Also it should provide support to the content of the orbit to prevent ophthalmic complication. The patients form and function should be restored with the oral part of the definitive prosthesis. The oral part will have posterior teeth for mastication, and the anterior teeth for esthetic. In the case of the edentulous patient, the oral part will be more like complete denture. For partially edentulous

cases, the design will be comparable to removable partial denture and will more commonly have the base metal framework.^[8,9]

Summary

Management of maxillectomy defect requires a multidisciplinary approach. Depending on the case, the operator should select the best suitable material and technique for successful rehabilitation which improves quality of life of the patient.

References

1. Meenakshi A, Shah D. The obturator prostheses for maxillectomy. *SRM J Res Dent Sci* 2012;3(3):193-7.
2. Patil PG, Nimbalkar PS. Lost wax-bolus technique to process closed hollow obturator with uniform wall thickness using single flasking procedure. *J Indian Prosthodont Soc* 2017;17:84-8.
3. Patil P. New technique to fabricate an immediate surgical obturator restoring the defect in original anatomical form. *J Prosthodont* 2011;20:494-8.
4. Rilo B, Dasilva JL, Ferros I, Mora MJ, Santana U. A hollow-bulb interim obturator for maxillary resection. A case report. *J Oral Rehab* 2005;32: 234-6.
5. Wu CW, Hung CC. An alternative method for fabrication of an open hollow obturator- case report. *J Dent Sci* 2008; 3(2):102-7.
6. Aramany MA. Basic principles of obturator design for partially edentulous patients. Part I: classification. *J Prosthet Dent* 1978; 40: 554-7.
7. Sridevi JR, Kalavathy N, Jayanthi N, Manjula N. Techniques for fabricating hollow obturator: Two case reports. *SRM J Res Dent Sci* 2014;5:143-6.
8. Chalian VA, Drane JB, Standish SM. Maxillofacial Prosthetics.

Multidisciplinary practice. Unites States: The William & Wilkins Company; 1972, p.133-48.

of solid and hollow obturator prostheses. J Prosthet Dent 1989;86:559-61.

9. Wu YL, Schaaf NG. Comparison of weight reduction in different designs

Figures

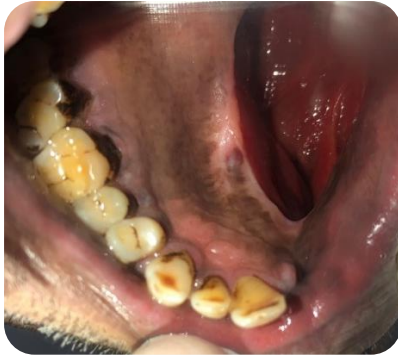

Figure 1

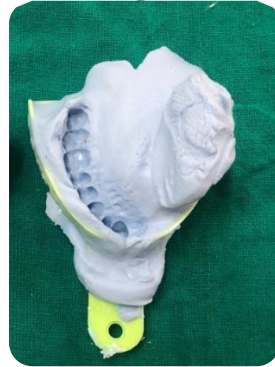

Figure 2

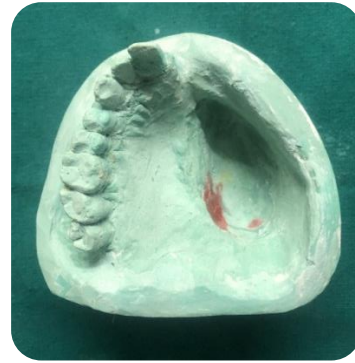

Figure 3



Figure 4

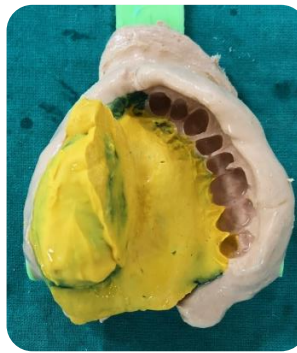


Figure 5

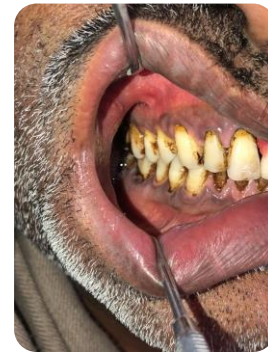

Figure 6

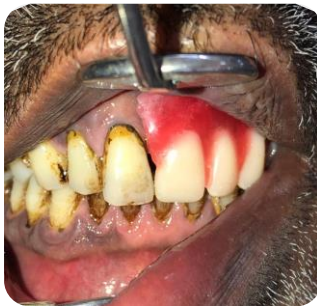

Figure 7

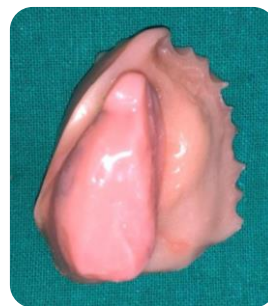

Figure 8

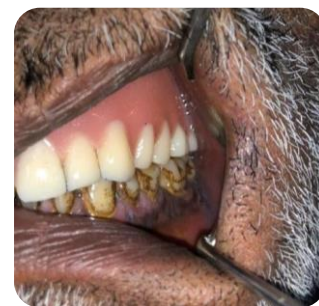

Figure 9

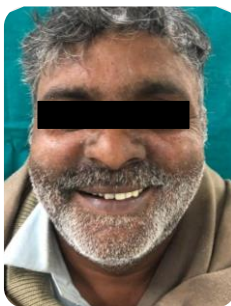

Figure 10