

Restoring lost smile with immediately placed implant: A case report.

Yuvraj Kapoor¹, Tabish Ahmed¹

¹Post Graduate, Department of Prosthodontics and Crown & Bridge, Inderprastha Dental College and Hospital, Ghaziabad

Abstract

The loss of tooth in the esthetic area is one of the most traumatic experience for the patient. This case report describes a case of fractured upper front tooth, which was extracted and replaced by immediate placement of a dental implant in the prepared socket and loading the same immediately. The tooth was extracted with minimal damage to hard and soft tissue and without flap reflection. The socket was prepared to the desired depth and a dental implant was inserted. An impression was made one week following the surgery, and a definitive restoration was placed. The patient exhibited no clinical or radiologic complications through one year of clinical monitoring after loading. The atraumatic operating technique and the immediate insertion of the implant resulted in the preservation of the hard and soft tissues at the extraction site, while maintaining the function.

Keywords: Dental implant, immediate loading, atraumatic extraction, esthetics.

Address of correspondence: 194 – Jagriti Enclave, New Delhi – 110092

E-mail address: yuvraj873@gmail.com

Submitted: 26-Mar-2021 **Revised:** 30-Mar-2021 **Accepted:** 2-Apr-2021 **Published:** 15-Apr-2021

Introduction

Oral health and oral health care are important for maintaining a proper functional and psychological well-being of individual.^[1] The loss of one or more teeth may adversely affect the oral health with an affected appearance being the most serious consequence for the patient.^[2] Tooth loss can be attributed to a number of etiological factors which includes congenital absence, trauma, diseases of the dentition (e.g., caries or periodontal disease), mechanical failure or as a result of various systemic diseases such as diabetes and osteoporosis.^[3] A missing tooth or teeth can be replaced with a removable dental prosthesis, fixed dental prosthesis, or using dental implants. Each of these alternatives have their own benefits and shortcomings.^[1, 2] However, it is important to consider the patient's financial, medical, and emotional condition as well as his esthetic desires before initiating the treatment.

Implant by definition “means any prosthetic device or artificial substitute that is inert and made up of alloplastic material which is implanted into the oral tissues beneath the mucosa/ periosteal layer and on/or within the bone to provide retention and support

for a removable / fixed dental prosthesis”.^[4] For years, endosseous implants have been the treatment of choice for replacing missing teeth, particularly in the esthetic regions. Branemark was the first person to place an endosteal titanium implant successfully in the year 1965.^[4, 5] Original protocols required the placement of implants into healed edentulous ridges followed by a crown after the implant has successfully osseointegrated with the bone. Taking this into consideration, the patient had to wait for a time period of up to 8–12 months to get a lost tooth replaced.^[6] Because of these inherent shortcomings of the conventional technique, strategies were developed to substantially shorten the entire treatment by placing implants immediately following extraction of tooth and loading them with a prosthesis.^[7, 8] Present case reports the immediate esthetic rehabilitation of a fractured maxillary left central incisor followed by extraction while preserving the soft and hard tissue architecture.

Case Report

A 20 year old male patient reported to Department of Prosthodontics, with the

chief complaint of difficulty in mastication owing to fractured tooth in the upper front region of the jaw since three months. Clinical and radiological evaluation revealed grade two mobility with respect to 21, adequate alveolar bone, absence of periapical pathology but fracture line was below the crest of alveolar bone and was limited to the tooth (Figure 1 and 2).

The patient was aware of the poor condition of tooth, and was willing for extraction followed by fixed replacement. Patient was explained regarding the various treatment options available along with the associated drawbacks. He was very concerned about his esthetic appearance and was willing for earliest possible replacement of teeth in question. Hence, he readily opted for immediate implant placement. Treatment plan included oral prophylaxis followed by extraction of root fragment and immediate placement and loading of implant w.r.t 21. Presurgical radiographic evaluation was done with panoramic radiograph (Figure 3). Appropriate length and width of available bone were determined and accordingly dental implant of dimension 4.5mm x 10mm (Bredent, Germany) was selected for insertion. Patient was administered with 2 g amoxicillin via oral route, 1 hr before the surgery and the surgical site was locally anaesthetised with lignocaine with adrenaline. As preservation of alveolar bone is the pre requisite for the success of immediate implants thus, the tooth has to be extracted with minimal possible trauma to the supporting tissues. The root fragment was extracted with luxators and small periosteal elevators without excessive enlargement of the socket thus, preserving the thin cortical plates (Figure 4, 5 and 6). Extraction socket was thoroughly debrided and inspected with a periodontal probe for any defect or possible perforation of cortical plate. Osteotomy site was prepared with sequential order of drills recommended by the manufacturer. Implant was inserted in the prepared osteotomy site with insertion torque of 35 Ncm (Figure 7

and 8). Postoperative intraoral periapical radiograph was taken, confirming the accuracy of placement of implant (Figure 9, 10, and 11). Postoperative instructions were given to the patient, and the patient was on regular recall.

The patient was recalled after 1 week for the prosthetic procedures. Impression was made in a custom formed acrylic tray using closed tray technique with light body and putty polyvinyl siloxane rubber base material (Aquasil, Dentsply, Surrey, UK) (Figure 12,13, and 14). Impression was sent to the laboratory for fabrication of porcelain fused to metal (PFM) crown. A PFM crown was fabricated and screwed to the abutment after 1 week and the patient was dispatched with a reminder of oral hygiene instructions & the recall programme.

Discussion

Endosseous dental implant therapy is used as the prosthetic standard of care for a number of routine clinical applications. However, despite of the high success rates it is yet to achieve wide public acceptance and utilization.^[1] Elias and Sheiham carried out a review of available literature and found that, in general, patients were more concerned about getting there anterior tooth replaced as compared to a posterior tooth, and they gave preference to esthetics over function while getting there tooth replaced.^[8] An obvious area of focus has been to substantially reduce the duration of time necessary to complete implant therapy. Various approaches have been used by clinicians to achieve these goals. Some of the routinely used modalities to achieve this are immediate implant loading, improving implant surface technology, and immediate placement of an endosseous implant following extraction.^[9, 10]

Immediate implant placement, referred to as placing a dental implant immediately into fresh extraction socket site following tooth extraction, is been considered a predictable and acceptable procedure.^[5, 6] In the modern era, immediate implant concept

is gaining popularity for replacing missing teeth, especially when anterior teeth are missing as there is no need to wait for 4–6 months after extraction for the bone to form and crestal bone loss is found to be less in immediately placed implants rather than conventionally placed implants.^[9, 10] Further, the decreased surgical trauma of immediate placement type decreases the risk of bone necrosis and permit bone remodeling process to occur rapidly as the natural socket is rich in periodontal cells, thus favourably increasing the success rate of immediately placed implants.^[11]

Although immediately placed and immediate loading implants are more predictable and successful than before,^[12] however, this approach cannot be applied to every immediate implant patient. In comparison to conventional implant treatment, the immediate procedure requires more chair-side time at the time of implant placement for both the restorative dentist and the patient. Further, case selection, proper diagnosis, treatment planning, and initial stability are very important factors for the success of an immediate implant and should be given paramount importance.^[1]

Conclusion

In this case, the condition of fractured tooth and supporting tissues were indicating of immediate implant placement. Using this technique, we were able to provide the patient with a desirable esthetic and functional outcome. Immediate implant placement may be a highly technique sensitive procedure. However, with careful case selection and treatment planning good esthetic results aren't difficult to achieve.

References

1. Wagenberg BD, Ginsburg TR. Immediate implant placement on removal of the natural tooth: retrospective analysis of 1,081 implants. *Comp Cont Educ Dent*. 2001; 2(2): 399-404.
2. Craddock HL. Consequences of tooth loss: The patient perspective – Aesthetic and functional implications. *Dent Update*. 2009; 3(6): 616–9.
3. Anil S, Preethanath RS, AlMoharib HS, Kamath KP, Anand PS. Impact of osteoporosis and its treatment on oral health. *Am J Med Sci*. 2013; 34(6): 396–401.
4. Branemark PI, Hansson BO, Adell R. Osseointegrated implants in the treatment of the edentulous jaw: Experience from a 10-year period. *Scand J Plast Reconstr Surg*. 1977; 16: 1–132.
5. Schwartz AD, Chashu G. The ways and wherefores of immediate placement of implants into fresh extraction sites. A literature review. *J Periodontol*. 1997; 6(8): 915-23.
6. Lazzara RM. Immediate implant placement into extraction sites. Surgical and restorative advantages. *Int J Periodontics Restorative Den*. 1989; 9(5): 333-43.
7. Schropp L, Isidor F. Timing of implant placement relative to tooth extraction. *J Oral Rehabil*. 2008; 3(5): 33–43.
8. Elias AC, Sheiham A. The relationship between satisfaction with mouth and number and position of teeth. *J Oral Rehabil*. 1998; 2(5): 649–61.
9. Douglass GL, Merin RL. The immediate dental implant. *J California Dent Assoc*. 2002; 30(2): 362-5.
10. Becker W, Goldstein M. Immediate implant placement: Treatment planning and surgical steps for successful outcome. *J Periodontol*. 2008; 4(7): 79-89.
11. Bajali M, Abdulgani A, Abu HM. Extraction and immediate implant placement, and provisionalization with two years follow up: a case report. *Int J Dent Health Sci*. 2014; 1(2): 229-36.
12. Del Fabbro M, Testori T, Francetti L, Taschieri S, Weinstein R. Systematic review of survival rates for immediately loaded dental implants. *Int J Periodonol Restor Dent*. 2006; 2(6): 249–63.

Figures:

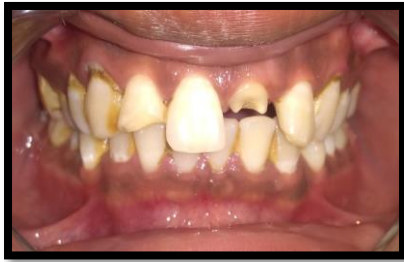

Figure 1

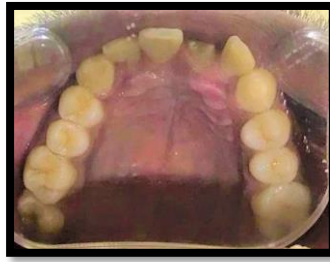

Figure 2

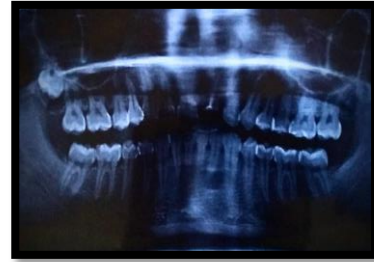

Figure 3

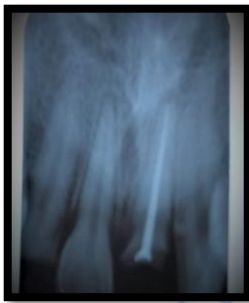

Figure 4

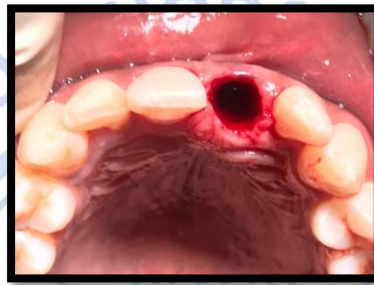

Figure 5

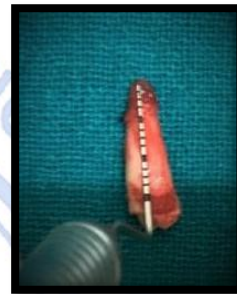

Figure 6

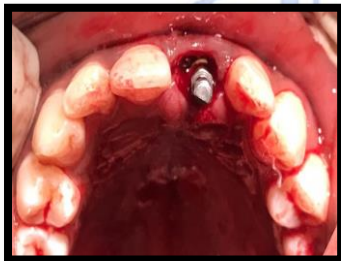

Figure 7

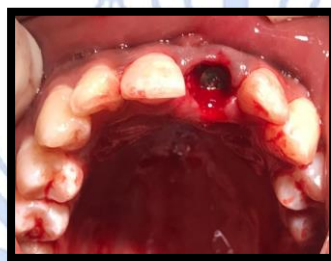

Figure 8

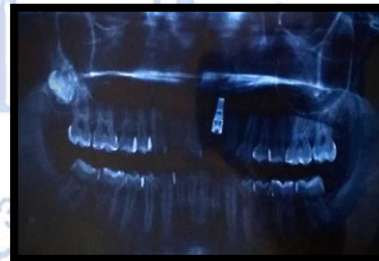

Figure 9

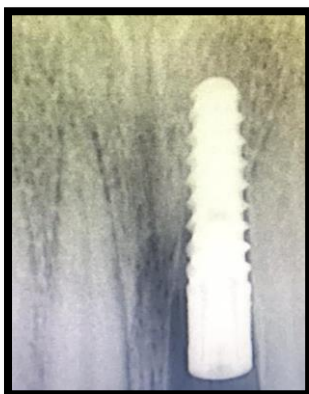

Figure 10

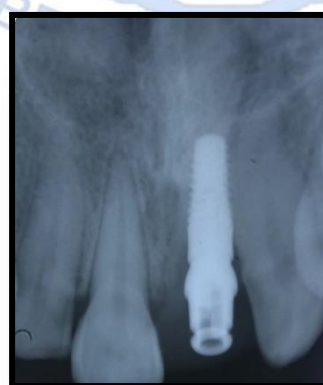

Figure 11

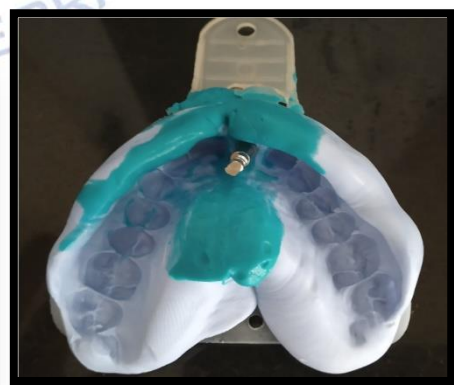

Figure 12

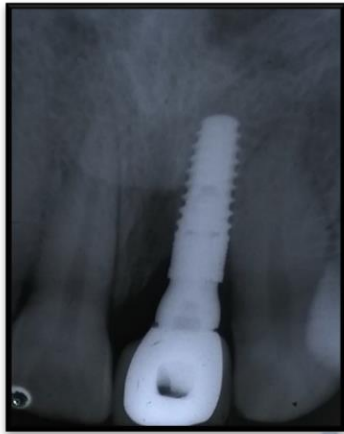


Figure 13

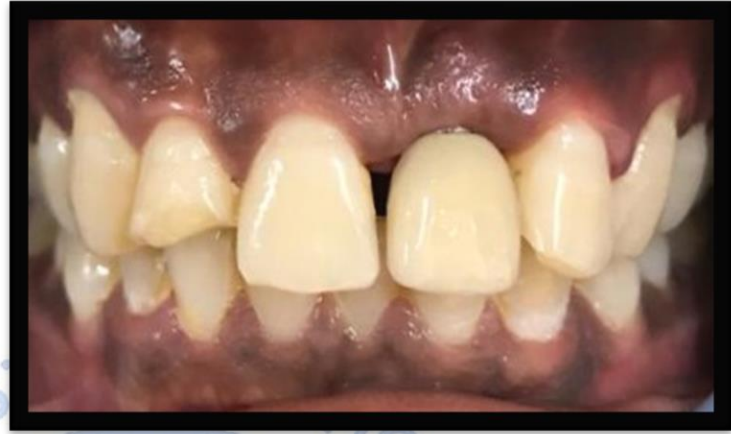

Figure 14

