

## Atypical heterotopic facial pain felt as a tooth ache? – A case report.

Nikita Parasrampur

Senior Lecturer, Dept. of Prosthodontics KSD Jain Dental College and Hospital.

### Abstract

Vascular pain can be a very debilitating pain condition for many patients. Migraine is such a in a kind for neurovascular origin which is the most commonly found. However neurovascular variants are pain disorders with the same origin but may present with atypical clinical characteristics, the main difference being that of the location. When this pain is reported near on in the teeth, it presents a particular problem for the dentist. A thorough history and clinical examination is very important and crucial to reach a definitive diagnosis. The following paper presents a case report of a 21-year-old female. who reported with an atypical heterotopic facial pain felt as a tooth ache?

**Key Words:** Neurovascular pain, heterotopic, facial migraine, toothache

**Address of correspondence:** Dr. Nikita Parasrampur, 54/10DC Dey Road, Active Acers, Tower 5 Flat 17C Kol-700015

E-mail: [nikitaparsrampur@gmail.com](mailto:nikitaparsrampur@gmail.com)

**Submitted:** 27-Mar-2021 **Revised:** 31-Mar-2021 **Accepted:** 4-Apr-2021 **Published:** 14-Apr-2021

### Introduction

Facial pain has been associated with etiologies including dental, otorhinolaryngological, and neurological disorders, often leaving the clinician faced with an array of possible diagnoses.<sup>[1]</sup>

Headaches and facial pain have been often found to have similar association and origin of sorts. This association has been reported in several recent papers, reflecting an attempt by the scientific community to clarify a common clinical observation. Among the various conditions that can cause facial pain, temporomandibular disorders (TMD) are highly prevalent with symptoms present in around 33% of the population.<sup>[2,3]</sup>

The head and neck have very complex anatomical configuration, which can produce heterotopic pain that can be felt in the teeth. These heterotopic pains occur as secondary effects from central sensitization or excitation of second order neurons produced by a constant barrage of nociceptive input from deep structures.<sup>[4]</sup> This kind of heterotopic pain poses a definite diagnostic problem for the clinician. The patient's chief complaint is

toothache but the origin of the pain lies elsewhere. The following paper diagnoses a case of neurovascular pain, that started as a toothache.<sup>[4]</sup>

### Neurovascular variants<sup>[4]</sup>

They are pain disorders that have neurovascular origins, but their clinical presentations are different than those of migraine, tension type, and cluster headaches. The primary difference for distinction of above is location. Neurovascular variants can present as a very focal area of pain in the face. When the location of pain is in the maxilla or mandible, it may be called lower face migraine or facial migraine. When this pain is reported near the teeth or in the teeth, it presents a particular problem for the dentist.

Deep somatic origin for the neurovascular pain variants has been established. The location of the pain felt with a neurovascular variant varies according to the vascular tissue that is involved. The location of the pain does not affect the quality or characteristics of the problem.

### Diagnostic considerations

The behaviour of the facial neurovascular pain is very diverse. Different similarities definitely coexist between the masticatory muscle pain and neurovascular variant since both represent deep somatic pain.

The following guidelines should serve to differentiate between them.<sup>[4]</sup>

- Neurovascular variants have a characteristic pulsatile, throbbing quality
- They follow vascular arborization, thereby violating the neuroanatomical boundaries. Frequently the pain is simultaneously felt in the side of neck, sometimes shoulder. Vessel wall edema may occur and is identified as palpable tenderness in superficial arteries. Occipital muscle discomfort may be present.
- They vary in intensity from low enough almost to go unnoticed to a sudden exacerbation of high intensity pain. Lower intensity pain is predominantly myalgic and non pulsatile, whereas high intensity exacerbations may have a temporal regularity unrelated to functioning. These attacks may be frequently nocturnal
- Neurovascular variants are prone to occur in episodes lasting several weeks and are separated by pain free remissions of several weeks or months. The episodes relate more to emotional stress and fatigue than to functional demands.
- They do not cause appreciable dysfunction unless there is a dominant component of secondarily induced muscle co contraction. However, to differentiate it from a masticatory muscle disorder, it is important to note that neurovascular pain presents with recurring exacerbations of throbbing pain, which is wholly inconsistent with masticatory pain.

- Neurovascular variants present characteristic autonomic effects – (nasal congestion, lacrimation, injection of conjunctiva, edema of the eyelids and face) on the affected side. These central excitatory effects may be confused with allergic rhinitis and sinusitis clinically. It should be noted that rhinitis is always bilateral.
- When a neurovascular variant is being suspected, the throbbing component may be reduced by oral administration of sumatriptan or applying pressure manually on the carotid artery.

### Case Describing the heterotopic pain felt as tooth ache with accompanied myofascial pain secondary to a neurovascular source.

#### History

A 21 years old woman presented with recurrent episodes of steady, dull aching, throbbing / pulsating pain diffusely located in the maxillary left molar tooth, with associated numbness of the face.

The onset of the pain was slow in nature and patient related its occurrence to increased bouts of stress and **perimenstrual time**. The patient can pinpoint the exact location which then slowly spreads all through the circumference of the head. The temporal nature of the pain has progressively worsened with time. The spontaneous periods of high intensity throbbing pain located in the maxillary left teeth and jaw, is associated with ipsilateral lacrimation and nasal congestion, sometimes with noticeable nausea There is constant mild aching in the face, left massetric region, preauricular and occipital areas and slowly progresses upwards. Each episode of pain lasts from a variable of 2 – 48 hours. The frequency of recurrence is thrice in a month.

The pain is aggravated by stress, fatigue, heat, hard chewing, head movements, increased light or sound decibels, empty

stomach, Chinese food, coffee. When the pain is intense it is also accompanied by tearing, paleness, flushing and redness of the left side of the face. Exacerbation of pain leads to nausea, vomiting, phonophobia, photophobia

The pain sometimes wakes up with a headache and difficulty in jaw movements with stiffness around the neck.

The complaint had been recurrently present for the last 3 years. The recurrent throbbing pain in the maxillary left 1<sup>st</sup> molar was treated with occlusal adjustments without lasting benefit, with several efforts being made medically, otolaryngologically and neurologically, and the patient was duly treated for sinusitis and rhinitis. None of the above mentioned resolved the issue and remission occurred last month again with

the same intensity. No medications are being taken presently.

The previous medical history elicited that the patient has been suffering from Polycystic ovarian syndrome and clinical depression.

### Examination

**Intra oral** – No specific dental or oral cause for complaint was found clinically or radiographically. No occlusal instability reported. There was some minor masseteric, temporal and preauricular discomfort with hard chewing.

**TMJ's** – Both joints are normal clinically and radiographically.

MUSCLE PALPATION:					
	Right	Left		Right	Left
<b>Ant. Temporalis</b>	Moderate pain	Mild Pain	<b>Mid Temporalis</b>	Mild Pain	Mild Pain
<b>Superficial Masseter</b>	Moderate pain	Moderate pain	<b>Trapezius</b>	Mild Pain	Mild Pain
<b>SCM</b>	Moderate pain	Mild Pain	<b>Post. Cervicals</b>	Moderate pain	Moderate pain

Cervical Screening – Appeared to be within normal limits. Cranial nerves – No abnormality detected.

### Diagnostic test

1. 50 mg trial dose of Sumatriptan was administered which gave relief during spontaneous exacerbation of tooth pain/headache.

### Diagnosis

Heterotopic pain felt as Tooth ache with accompanied with chronic moderate myofascial pain / myalgia secondary to pre-existing neurovascular pain source.

### Discussion

The neurovascular variants as described in the above cases are pain disorders that elicit atypical clinical presentations with the major difference being the location of their origin. This type of pain poses a particular challenge to the dentist, otolaryngologist, as they may be mistaken for odontogenic, or neuropathic disorders.

The case above confirms the diagnosis for facial migraine / lower face migraine as defined by the characteristics, nature, and location of the pain (maxillae). The history highlights that the pain is also associated to menstrual cycle, which can be collaborated with the age of the patient and the previous medical history of PCOS. The role of hormonal influences in causing such

kind of throbbing pain cannot to be ruled out.

Migraine is a common disabling primary headache disorder. The two most common types of migraine are migraine without aura and with aura.<sup>[5]</sup> Fifteen percent of migraineurs will report daily or chronic (near daily) headache.<sup>[6]</sup> Migraine affects 6% of men and 18% of women in the adult population.<sup>[7,8]</sup> Its prevalence peaks between the ages of 35 and 45.<sup>[9]</sup> Migraine is associated with significant burden and decreased quality of life.<sup>[8,10]</sup>

### Clinical features

Patients with migraine often complain of potential triggers that include stress; altered sleep patterns; certain foods, such as cheese and chocolate; alcohol (wine); bright or flashing lights; menstruation; or changes in barometric pressure.<sup>[11,12]</sup> The various phases typically present with distinctive clinical findings.

**Phase 1** (prodrome): occurs hours or days before the headache onset. Associated with cravings, lethargy, tiredness, stiff neck, and difficulty concentrating.<sup>[13]</sup>

**Phase 2** (aura): occurs in patients with migraine with aura. Auras may be visual, such as scotomas or fortification spectrum; sensory, such as numbness, and pins and needles; or motor, such as dysarthria.<sup>[14]</sup> The aura develops within five to twenty minutes, and the trigger may last upto 1 hour. **Phase 3** (headache): a unilateral pain is found to be localized around the frontal, temporal, and ocular regions. Occipital and neck area also may be involved.<sup>[15-17]</sup> Patients report throbbing or pulsating pain at moderate to severe intensity.<sup>[4,14,15,17]</sup> Aggravation of the pain with physical activities and sudden head movements is often reported.<sup>[14,15]</sup> Duration of the headache is usually between 4 and 72 hours, although it can last longer.<sup>[15]</sup> Most patients report fewer than 1 headache monthly,

although some patients may suffer up to 4 migraines a month.<sup>[7,18]</sup> Migraine also may be chronic, whereby the headache may occur more than 15 days per month. Many migraine sufferers report nausea (80%), vomiting (50%), and photophobia and/or phonophobia (>50%).<sup>[15,16]</sup> **Phase 4** (postdrome): Increased feeling of tiredness, irritation, depression, allergies, stroke and other associated pain conditions.<sup>[19-22]</sup>

### Pathophysiological features<sup>[4]</sup>

Brain is a visceral organ with a pain signalling mechanism. Most of the structures of the head, the trigeminal nerve carries the nociceptive input from the innervated intracranial structures to the brain stem by the way of the trigeminal tract nucleus. This system of neural innervation of the intracranial structures is called the trigeminovascular system.

All of the supra tentorial pain sensitive structures such as the meninges and intracranial vessels are innervated by the trigeminovascular system. Trigeminal system is stimulated by both neural (electrical) and chemical activators (Figure 1).

Accompanying the trigeminal reflex activity is the effect of the locus ceruleus on the cerebral cortex that initiates cortical oligemia and spreading depression

### The spreading depression of activity in the cerebral cortex- Aristides A. P. Leao.<sup>[23]</sup>

Liao's theory has been adapted and explained from his original paper below: In the initial phases of development of the study an interesting response was observed in the rabbit's cortex. The response was elicited by electrical stimulation and a marked, enduring reduction of the spontaneous electrical activity of the cortex, was seen.

In rabbits, under dial narcosis, weak faradic or mechanical stimulation of the exposed cerebral cortex elicits a characteristic response designated "spreading depression". Shortly after the stimulation the spontaneous electrical activity decreases markedly at the stimulated region. The slowly spreading depression was found to be across all directions and adjacent areas were also affected.

The depression can be initiated in any of the regions involved in the spread, but is usually more readily obtained from the frontal than from the occipital areas.

Recovery of the initial pattern of spontaneous activity is slow; it requires, as a rule, 5 to 10 minutes at each region. If only weak stimuli are used, depression at any region runs the same course regardless of what region is stimulated.

Only with supra minimal stimulation does the depression spread to the opposite hemisphere, then appearing first in the region symmetrical to the point of stimulation and thence spreading as in the stimulated hemisphere. The spreading depression affects not only the spontaneous electrical activity, but also several cortical responses; i.e., responses to touch, to electrical stimulation of afferent nerves, to illumination of the retina, to ipsilateral or contralateral cortical electrical stimulation, and to local application of strychnine or of eserine plus acetylcholine. Single shocks applied to a depressed region fail to elicit typical responses in the opposite nondepressed hemisphere. The most common type of this activity is composed of large, slow, localized potential waves, during which one electrode becomes negative with respect to others 1 to 3 mm. distant. Fast components may also appear, and the activity when intense closely resembles the "seizure pattern" of experimental epilepsy.

The above stated theory is associated with wave of decreased blood flow.

**Management considerations for migraine** <sup>[4]</sup>:

### 1. Patient education and trigger avoidance

- a) Trigger factors identification
- b) Maintenance of pain diary for record
- c) Reassurance and comforting the patient about the disease
- d) Other factors controlling the disease should be identified and addressed with appropriately.

### 2. Non pharmacologic methods

- a) Relaxation training
- b) Biofeedback
- c) Hypnosis
- d) Cognitive-behavioural therapy
- e) Formal psychotherapy

### 3. Pharmacologic management

#### Abortive Medications

Triptans: Sumatriptan is available in oral tablets.

DHE – Dihydroergotamine (Powerful vasoconstrictive quality).

In some patients, Analgesics such as

1. Aspirin
2. Acetaminophen
3. NSAID's may be effective

#### Preventive Medications

- a. Beta – adrenergic Agents
- b. Calcium channel blockers
- c. Tricyclic Antidepressants
- d. Antiepileptic drugs

Many of the drugs used to manage migraine have significant side effects, especially on the cardiovascular system.

#### Conclusion

Neurovascular variants may follow facial trauma, including tooth extraction and other minor oral surgery. As such, they may be confused with other post traumatic pain problems. Because of the extreme

versatility of this type of pain and its property to stimulate other facial pain disorders, especially those involving dental practice, errors in diagnosis may be made. The dental examiner should be constantly alert and cautious in advising definitive therapy either to the teeth or the masticatory apparatus, until a confirmed diagnosis is established

## References

1. Eross EJ, Dodick DW, Swanson JW & Capobianco DJ. A review of intractable facial pain secondary to underlying lung neoplasms. *Cephalalgia* 2003; 23:2–5. London. ISSN 0333- 1024.
2. de Leeuw R, Klasser GD. *Orofacial Pain: Guidelines for Assessment, Diagnosis and Management*. Hannover Park: Quintessence Publishing Co; 2013.
3. Friction J, Look JO, Wright E, Alencar FG Jr, Chen H, Lang M et al. Systematic review and meta-analysis of randomized controlled trials evaluating intraoral orthopedic appliances for temporomandibular disorders. *J Orofac Pain*. 2010;24:237–254.
4. Jeffrey P. Okeson, *Bell's Oral and Facial Pain*. Seventh edition. USA: Quintessence Publishing; 2014. Chapter 17, Vascular and Neurovascular Pains; p-667-747.
5. Benoliel R, Elishoov H, Sharav Y. Orofacial pain with vascular-type features. *Oral Surg Oral Med Oral Pathol Oral Radiol Endod* 1997;84(5):506–12.
6. Daudia AT, Jones NS. Facial migraine in a rhinological setting. *Clin Otolaryngol Allied Sci* 2002;27(6):521–5.
7. Penarrocha M, Bandres A, Penarrocha M, et al. Lower-half facial migraine: a report of 11 cases. *J Oral Maxillofac Surg* 2004;62(12):1453–6.
8. Czerninsky R, Benoliel R, Sharav Y. Odontalgia in vascular orofacial pain. *J Orofac Pain* 1999;13(3):196–200.
9. Benoliel R, Birman N, Eliav E, et al. The international classification of headache disorders: accurate diagnosis of orofacial pain? *Cephalalgia* 2008;28(7): 752–62.
10. Rasmussen BK. Epidemiology of headache. *Cephalalgia* 1995;15(1):45–68.
11. Lyngberg AC, Rasmussen BK, Jorgensen T, et al. Incidence of primary headache: a Danish epidemiologic follow-up study. *Am J Epidemiol* 2005;161(11):1066–73.
12. Lyngberg AC, Rasmussen BK, Jorgensen T, et al. Has the prevalence of migraine and tension-type headache changed over a 12-year period? A Danish population survey. *Eur J Epidemiol* 2005;20(3):243–9.
13. Spierings EL, Ranke AH, Honkoop PC. Precipitating and aggravating factors of migraine versus tension-type headache. *Headache* 2001;41(6):554–8.
14. Karli N, Zarifoglu M, Calisir N, et al. Comparison of pre-headache phases and trigger factors of migraine and episodic tension-type headache: do they share similar clinical pathophysiology? *Cephalalgia* 2005;25(6):444–51.
15. de Filippis S, Salvatori E, Coloprisko G, et al. Headache and mood disorders. *J Headache Pain* 2005;6(4):250–3.
16. Pringsheim T, Davenport W, Mackie G, et al. Canadian Headache Society guideline for migraine prophylaxis. *Can J Neurol Sci* 2012;39(2 Suppl 2):S1–59.
17. Katsarava Z, Obermann M, Yoon MS, et al. Prevalence of cluster headache in a population-based sample in Germany. *Cephalalgia* 2007;27(9):1014–9.
18. Sjaastad O, Bakketeig LS. Cluster headache prevalence. Vaga study of head-ache epidemiology. *Cephalalgia* 2003;23(7):528–33.
19. Ekbohm K, Svensson DA, Pedersen NL, et al. Lifetime prevalence and concor-

- dance risk of cluster headache in the Swedish twin population. *Neurology* 2006;67(5):798–803.
20. Ekblom K. Patterns of cluster headache with a note on the relations to angina pectoris and peptic ulcer. *Acta Neurol Scand* 1970;46(2):225–37.
21. Campbell JK. Diagnosis and treatment of cluster headache. *J Pain Symptom Manage* 1993;8(3):155–64.
22. Brooke RI. Periodic migrainous neuralgia: a cause of dental pain. *Oral Surg Oral Med Oral Pathol* 1978;46(4):511–6
23. Leao AAP. Further observations on the spreading depression of activity in the cerebral cortex. *J Neurophysiol* 10: 409 - 414, 1947

### Figures

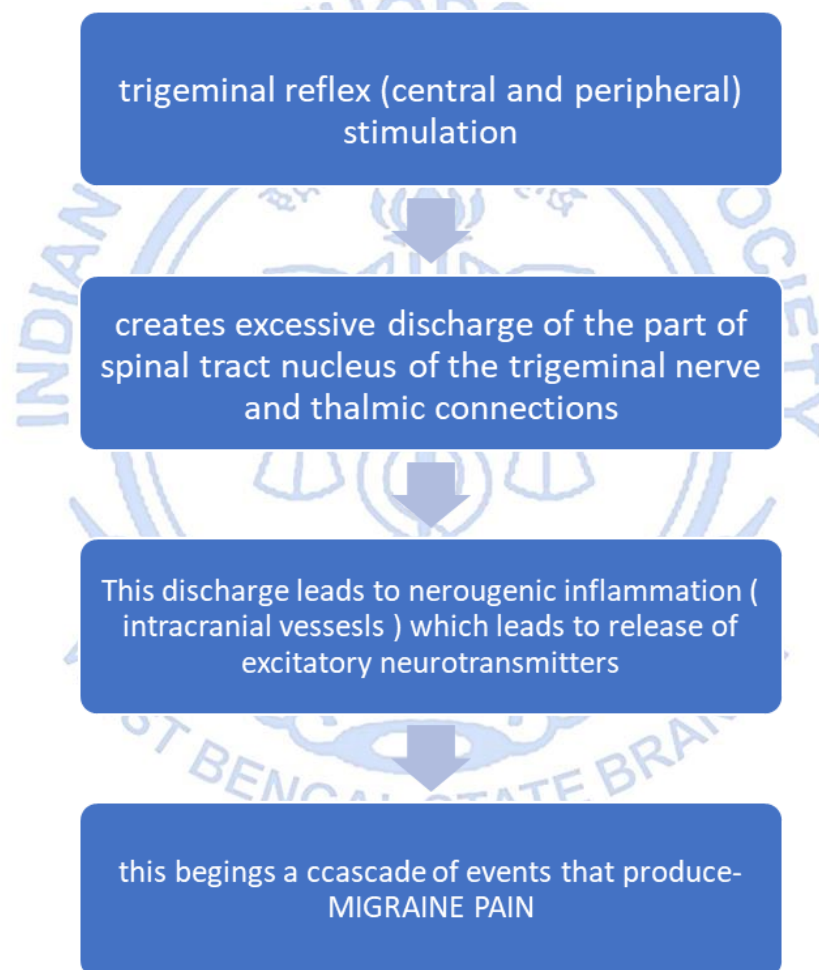


Figure 1