

Shetty SS¹, Shetty CK^{2*}

¹Medical Lecturer, Faculty of Medicine and Health Sciences, Department of Surgery, UCSI University, Kampus Kuala Terengganu, Terengganu, Malaysia.

²Medical Lecturer, Faculty of Medicine and Health Sciences, Universiti Sultan Zainal Abidin (Unisza), Kampus Kota, Jalan sultan mahmud, Kuala Terengganu, Terengganu, Malaysia.

Abstract

Eosinophilic enteritis is a rare disorder presenting mostly with diarrhea, malabsorption, abdominal pain, weight loss and hypersensitivity. Surgical manifestation of eosinophilic gastrointestinal disorders depends on the site and extent of involvement. In our case series of four patients two of them had ileocaecal masses with recurrent subacute intestinal obstruction with past history of intake of anti-tubercular drugs for 9 months. On histopathological examination both of them proved to have eosinophilic enterocolitis. Thus it is a clinical dilemma to differentiate between these two conditions. The other two patients presented as acute abdomen with perforation and intussusception. All four patients were treated surgically. Post operatively they recovered well with no symptoms on one year follow up. In Indian set up tuberculosis being rampant there may be under reporting or wrongly diagnosed cases of eosinophilic enteritis. Thus a strong clinical suspicion and awareness of this clinical entity is essential among surgical community.

Keywords: Eosinophilic Colitis (EC); Eosinophilic Enteritis (EE); Obstruction; Perforation; Anti-Tubercular Drugs (AKT).

*Corresponding Author:

Dr Charan Kishor Shetty MBBS, MD,
Medical Lecturer, Department of Forensic Medicine, Faculty of Medicine, Universiti Sultan Zainal Abidin (Unisza), Kampus Kota, Kuala Terengganu, Terengganu, Malaysia 20400.
Tel: 609-6275546/609-6275740
Fax: 609-6275771/609-6275772
E-mail: shettykishor.k@rediff.com

Received: January 19, 2015

Accepted: March 10, 2015

Published: March 11, 2015

Citation: Shetty SS, Shetty CK (2015) Spectrum of Surgical Presentation of Eosinophilic Enteritis: A Case Series. *Int J Surg Res* 2(2) 8-12. doi: <http://dx.doi.org/10.19070/2379-156X-150003>

Copyright: Shetty CK[©] 2015. This is an open-access article distributed under the terms of the Creative Commons Attribution License, which permits unrestricted use, distribution and reproduction in any medium, provided the original author and source are credited.

Introduction

Eosinophilic gastroenteritis is a rare disorder where affected patients present primarily with diarrhea, malabsorption, abdominal pain, weight loss and hypersensitivity. Surgical manifestation of eosinophilic gastrointestinal disorders depends on the site and extent of involvement and accordingly they can be divided into eosinophilic esophagitis, eosinophilic enteritis, eosinophilic gastritis, and eosinophilic colitis. Eosinophilic gastrointestinal disorders can be primary as a part of a Hyper eosinophilic syndrome (HES) or Systemic disease (e.g. connective tissue disease, vasculi-

tis, Celiac disease, inflammatory bowel disease), or secondary to infections (e.g. helminthic and fungi) and drugs (e.g. naproxen, clozapine, rifampicin, gold) [1].

Presentation tends to be dependent on which intestinal layer is most affected by the eosinophilic infiltration. Mucosa predominant disorder is associated with mucosal injury and patients present with malabsorption, diarrhoea, and protein-losing enteropathy. Transmural disease presents with colonic wall thickening and features of intestinal obstruction. Eosinophilic predominant ascites is a manifestation of serosal involvement. Eosinophilic colitis can present acutely with abdominal symptoms such as caecal volvulus causing intestinal obstruction, intussusception, and perforation [2]. Treatment of eosinophilic enterocolitis is antihistamines, mast cell stabilizers, glucocorticosteroids, and immunosuppressive agents along with surgery for acute surgical emergencies.

In Indian scenario where abdominal tuberculosis is widely prevalent, eosinophilic enterocolitis remain under reported. Eosinophilic colitis mimics abdominal tuberculosis with identical symptoms of fever, weight loss, abdominal pain, recurrent sub-acute intestinal obstruction and ascites. CT scan also has a similar picture of pulled up caecum, strictures, ascites especially in the transmural type of enterocolitis.

Case Presentation

Case 1

A 57-year old male with features of recurrent sub-acute intestinal obstruction from past one year. Patient was evaluated with

ultrasonography which showed multiple dilated bowel loops with sluggish peristalsis. We suspected tuberculosis of abdomen as patient gave history of intake of anti-tubercular drugs for 9 months 1 year back. Patient contrast enhanced CT scan showed thickening in the ileocaecal region with mesenteric lymphadenopathy and dilated bowel loops. Patient had an elevated ESR and lymphocytosis. Patient had diagnostic laparoscopy which showed pulled up thickened shrunken caecum with ileal stricture. The patient underwent a right laparoscopic hemicolectomy (figure 1). Post operatively the patient recovered well. On histopathological examination of the specimen, eosinophilic infiltration was seen in all layers of intestine. Patient's absolute eosinophilic count was 550/cumm.

Case 2

A 32-year old male patient arrived to emergency surgical department with acute abdominal pain. On examination the patient had tachycardia with blood pressure of 100/60mmHg and high colored urine. Abdominal examination revealed generalized tenderness, guarding and rigidity. Patients abdominal x-ray erect showed air under diaphragm. Patient underwent an exploratory laparotomy in view of features suggestive of perforative peritonitis. The patient had perforated ileum with two distal ileal strictures and a fibrosed caecum. Ileo transverse bypass was performed with closure of the ileal perforation after taking biopsy. (Figure 2). Post operatively after histopathological examination the patient developed eosinophilic enteritis. Patient was given a course of steroids and anti-helminthic drugs. However, his post-operative course was uneventful. We gave steroid in the second patient because we had not done any resective procedure in this patient. We only took

multiple biopsies from perforated area and did an ileo transverse bypass procedure and left the affected bowel as patient presented in septic shock.

Case 3

A 24-year old male came with history of obstipation, recurrent vomiting and abdominal distention since 1 day. On evaluation, the patient had tachycardia with low blood pressure. Patient's abdominal x-ray showed multiple air fluid level and CT scan showed intestinal obstruction with target sign suggestive of intussusception. Patient was had exploratory laparotomy which showed dilated bowel loops with ileoileal intussusception at the level of distal ileum (figure 3). Resection anastomosis was performed. Specimen analysis showed eosinophilic enteritis. Patient had elevated absolute eosinophilic count. On one year follow up patient was symptom free.

Case 4

A 6- year old male with history of recurrent sub-acute intestinal obstruction since 3 months. Patient was evaluated with ultrasonography which showed multiple dilated bowel loops with sluggish peristalsis. Patients contrast enhanced CT scan showed thickening in the ileocaecal area with dilated bowel loops. Patient had an elevated ESR and lymphocytosis and also gave history of known case of tuberculosis with intake of anti-tubercular drugs 35 years back for a year. Patient had normal eosinophil count. Exploratory laparotomy and right hemi colectomy done in view of thickened pulled up ileocecal junction and dilated proximal loops. Post operatively patient recovered well. On histopathological examination of specimen eosinophilic infiltration was seen in

Figure 1. Ileocaecal mass specimen after laparoscopic hemicolectomy (case 1).

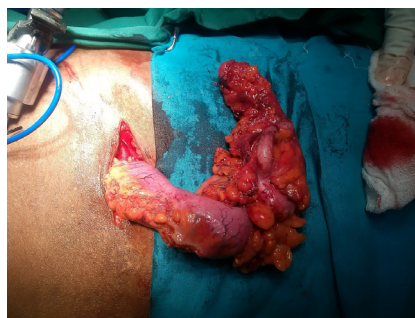


Figure 2. Ileal perforation with stricture (Case 2).

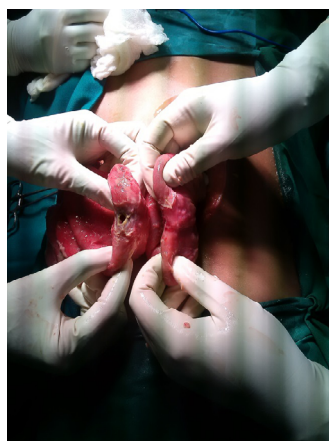


Figure 3. Ileoileal intussusception in a case of eosinophilic enteritis (Case 3).

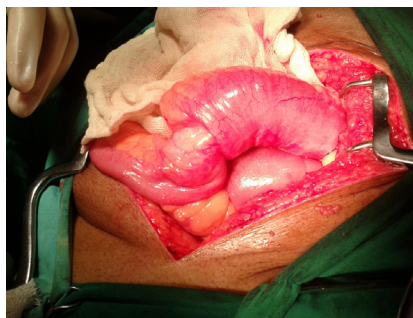


Figure 4. Resected specimen of ileum and caecum after right hemi colectomy (case 4).

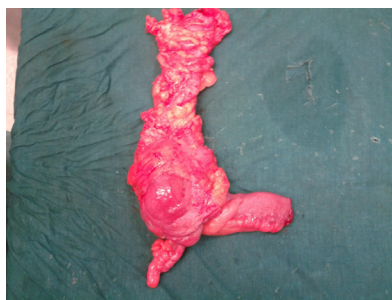
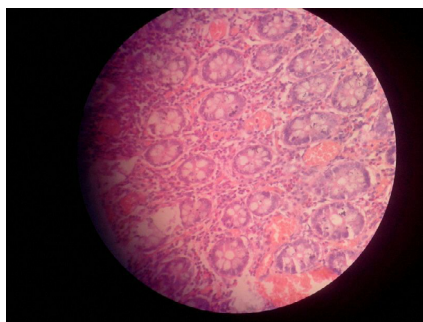


Figure 5: Hematoxylin and eosin stain showing eosinophilic infiltrations (More than 100cells/HPF) in all layers of intestine (Case 4)



all layers of intestine. (Figure 4 and 5).

Discussion

Eosinophilic enteritis (EE) was first described by Kaiser in 1937 [3]. In India, Venkataraman et al have reported seven cases of EE over a ten-year period [4]. Diagnosis is one of exclusion and the criteria put forward for the diagnosis are the presence of gastrointestinal (GIT) symptoms, infiltration of the GIT by eosinophils in one or more areas, absence of parasitic infestation and exclusion of eosinophilic involvement in organs other than the GIT [5]. The diagnosis of EE is made from the presence of gastrointestinal symptoms, peripheral eosinophilia, endoscopic and histological findings, and eosinophilic ascites, with no well-defined causes of eosinophilia on thorough evaluation. In the present case series only two patients had elevated peripheral eosinophil counts but all had eosinophilic infiltration of > 100 cells/hpf on histopathological examination. Hence in a suspected case of EE a colonoscopic biopsy at multiple sites showing eosinophilic infiltration can be one of the diagnostic tools in confirming the disease.

In our case series of four patients two of them had ileocaecal mass with recurrent subacute intestinal obstruction with past history of intake of anti-tubercular drugs for 9 months. On histopathological examination both of them proved to have eosinophilic enterocolitis. Thus, it is a clinical dilemma to differentiate

between these two conditions. The other two patients presented as acute abdomen with perforation and intussusception. All four patients were treated surgically. Post operatively they recovered well with no symptoms on one year follow up.

Various case reports have been reported where eosinophilic enteritis mimics tuberculosis and ulcerative colitis. In the present case series also out of four patients two of them had a history of abdominal tuberculosis in the past and treatment for the same was taken. Lange et al proposed rifampicin as a cause of eosinophilic colitis as its side effect [6]. In present case series whether patients were wrongly diagnosed cases of tuberculosis in actual case of eosinophilic enteritis or patient had eosinophilic enteritis as a side effect to consumption of rifampicin was an enigma.

Both these patients did not have a proven biopsy suggestive of tuberculosis before starting treatment. According to history they were on anti-tubercular drugs only based on clinical suspicion and CT picture. Drugs reported to cause colonic eosinophilia include nonsteroidal anti-inflammatories, tacrolimus, carbamazepine, rifampicin, sulphasalazine, and naproxen. None of the patients in the case series had any h/o allergic rhinitis or atopy or food allergy. Thus, it is essential to conduct colonoscopic biopsy to differentiate between eosinophilic enterocolitis and tuberculosis. Biopsy has to be taken at multiple sites as the disease has tendency for skip lesions.

Table 1. Clinical Manifestation, Ultrasound Findings And Clinical Diagnosis.

No	Age/sex	Symptoms /drug history	Radiological finding	Clinical diagnosis	Laboratory findings
1	57/M	Recurrent constipation Vomiting, Distention on and off 1 year Anti tubercular drugs for 9 months (CAT 1)	CECT: thickening in ileocaecal area with mesenteric lymphadenopathy with dilated loops	Recurrent intestinal obstruction	ESR : 108 AEC:550 cells/ Cumm Chest x ray: Signs of fibrosis healed tuberculosis Stool examination: NAD Montoux test: negative
2	32/M	Acute abdomen Guarding Rigidity Tachycardia Hypotension No h/o of chronic medication	X ray erect chest/abdomen showed air under diaphragm	Acute perforative peritonitis	ESR: 100 AEC: 320 cells/ cumm Chest x ray : NAD Stool examination : NAD Montoux test: negative
3	24/M	Obstipation, vomiting, abdominal distention since 1 day No h/o chronic medication	X ray abdomen: multiple air fluid level CECT abdomen: target sign suggestive of intussusception with obstruction	Acute intestinal obstruction due to ileo ileal intussusception	ESR: 25 AEC:600 cells/cumm Chest x ray : NAD Stool examination : NAD Montoux test: negative
4	62/M	Constipation, abdominal distention, vomiting on and off since past 3 months h/o intake of amlodipine, aspirin, atorvastatin for 20 years anti tubercular treatment 35 years back	USG: Multiple dilated loops with sluggish peristalsis CECT: thickening in ileo caecal area with proximal dilated loops	Acute intestinal obstruction	ESR: 90 AEC: 70 Cells/cumm Chest xray: NAD Stool examination : NAD Montoux test: negative

AEC: absolute eosinophil count: normal range: 40-400cells/cumm

NAD: no abnormality detected

ESR: 0-20mm/hr in male (normal range)

Table 2. Management of individual patient.

No	Medical line of management	Surgical management
1	Recusitation, IV antibiotics, albendazole, Anti tubercular treatment, analgesic, pantoprazole, pyridoxine	Laprosopic right hemicolectectomy
2	Recusitation, IV antibiotics, albendazole, analgesic, prednisolone oral Pantoprazole	Closure of ileal perforation with biopsy ileo transverse bypass due to multiple ileal stricture and fibrosed caecum
3	Recusitation, IV antibiotics, albendazole, analgesic, pantoprazole and traneximic acid	Resection and anastomosis of intussuscepted ileal segment
4	Recusitation, IV antibiotics, albendazole, analgesic, pantoprazole, amlodipin, SC low molecular weight heparin.	Exploratory laprotomy with right hemicolectomy

Eosinophilic enterocolitis also presents as a mass lesion which can be confused with neoplasm. In the third case, the patient had a lump on CT scan with target lesion which was suspected as malignancy causing a leading point for intussusception but was surprisingly proved as EE. Thus eosinophilic gastro intestinal disorders even though rare has to kept as differential diagnosis as it is a benign and an easily treatable entity.

Supportive treatment with pharmacotherapy, mainly oral glucocorticosteroids, is indicated for those with obstructive symptoms. Patients with mucosal layer involvement may benefit from anti-inflammatory medications (e.g, oral glucocorticoids) and/or diet elimination therapy, particularly if they report a history of food intolerance or allergy. Drugs, such as montelukast, ketotifen, and mycophenolate mofetil, and alternative Chinese medicines have been advocated but are generally not successful. Recurrence is common even after surgical resection.

Conclusion

Eosinophilic enteritis even though a rare disorder has a varied spectrum of presentation which is easily misinterpreted as neoplasm, tuberculosis and inflammatory bowel disease. Since it can be easily treated medically and surgically it has to be diagnosed with certainty. In Indian set up, tuberculosis being rampant there may be under reporting or wrongly diagnosed cases of eosinophilic enteritis. Thus, a strong clinical suspicion and awareness of this clinical entity is essential among surgical fraternity.

References

- [1]. Abdulrahman A. Alfadda, Martin A. Storr, Eldon A. Shaffer (2010) Eosinophilic colitis: epidemiology, clinical features, and current management. *Ther Adv Gastroenterol* 4(5): 301-309.
- [2]. Ong GY, Hsu CC, Changchien CS, Lu SN, Huang SC (2002) Eosinophilic gastroenteritis involving the distal small intestine and proximal colon. *Chang*

- Gung Med J 25(1): 56-61.
- [3]. Kaijser R (1937) Zurkenntnis der allergischen des verdauungskabals von-standpunkt des chiruugan aus. Arch Klin Chir 36:188.
- [4]. Venkataraman S, Ramakrishna BS, Mathan M, Chacko A, Chandy G, et al. (1998) Eosinophilic gastroenteritis -an Indian experience. Indian J Gastro-enterol.17(4):148-149.
- [5]. Talley NJ, Shorter RG, Phillips SF, Zinsmeister AR (1990) Eosinophilic gastroenteritis: a clinicopathological study of patients with disease of the mucosa, muscle layer, and subserosal tissues. Gut 31(1): 54-58.
- [6]. Lange P, Oun H, Fuller S, Turney JH (1994) Eosinophilic colitis due to rifampicin. Lancet 344 (8932): 1296-1297.