

A rare case of accelerated gingival overgrowth with high dose amlodipine therapy

Rakesh B M¹, Sahithi Sharma^{1*}, Chandana K H¹

¹Department of General Medicine, Vydehi Institute of Medical Sciences and Research Centre (VIMS&RC), Bangalore, Karnataka, India


*Corresponding author/authors complete details (E-mail and Telephone); Email ID: sahithifaps@gmail.com, Ph. No: +917899858800

DOI: 10.5281/zenodo.4904455

Web of Science Researcher ID: AAG-2177-2021

ORCID ID: 0000-0003-4095-3714

Abstract

Date Received: 04/12/2020 Date Revised: 05/01/2021 Date Accepted: 18/01/2021	Gingival overgrowth represents an over-exuberant response to a variety of local and systemic conditions. Certain anticonvulsants, immunosuppressive drugs, and a number of calcium channel blockers have been shown to produce similar gingival overgrowth in susceptible patients. Among the calcium channel blockers, nifedipine is most frequently associated with gingival overgrowth. Whereas, there is limited evidence of amlodipine-induced gingival hyperplasia. We report a case of accelerated drug-induced gingival overgrowth in a 60-year-old hypertensive patient taking amlodipine at a dose of 10 mg.
Keywords Hypertension, calcium channel blockers, drug-induced gingival hyperplasia, adverse drug reaction	
	An official publication of Global Pharmacovigilance Society; Published under licence of Creative Commons Attribution 4.0 International COPYRIGHT © 2021 Author(s)

Introduction

Gingival overgrowth (GO) refers to an excessive proliferation of gingival soft tissue. It is one of the chief clinical manifestations of gingival pathology (Triveni, *et al.*, 2009). GO has a multifactorial etiopathogenesis including hereditary and malignant causes; adverse effects of certain drugs and is associated with poor dental hygiene (Bhatia *et al.*, 2007). Medications commonly implicated are anticonvulsants like phenytoin, immunosuppressants such as ciclosporin and calcium channel blockers (CCB) (Seymour *et al.*, 1996). Nifedipine-induced gingival overgrowth has been well documented in literature, but amlodipine rarely causes the same. Aside from GO, CCBs are commonly implicated with other adverse effects such as palpitations, tachycardia, ankle oedema, flushing, headaches and constipation (Livada *et al.*, 2014; Dougall *et al.*, 1996).

Amlodipine is a third generation dihydropyridine (DHP) calcium channel blocker used commonly in the management of angina and hypertension due to its favourable pharmacological profile (Ellis *et al.*, 1993). It is prescribed as a first line anti-hypertensive across many populations and countries, including India (Fares *et al.*, 2016). Amlodipine has a longer duration of action and safer side effect profile making it a better choice than nifedipine. The prevalence of GO in patients taking amlodipine was reported to be 3.3 %, against 47.8 % in those taking nifedipine (Nery *et al.*, 1995)

Here a case of accelerated, severe GO in a patient taking amlodipine at a dose of 10mg for two months has been reported. This case report highlights the role of high dose amlodipine in the rapid progression of overgrowth.

Case presentation

A 60-year-old male presented to the department of General Medicine at VIMS&RC with history of rapid gum enlargement in the lower jaw in a period of one month. The swelling caused pain and interfered with chewing. His medical history included hypertension, chronic kidney disease and recent recovery from a cerebrovascular accident. He had no significant past dental history. He was on amlodipine 10 mg once daily anti-hypertensive therapy for three months prior to presentation. He was concomitantly taking metoprolol 50 mg once daily, frusemide 40 mg once daily, prazosin 5 mg twice daily, clonidine 0.1 mg twice daily and aspirin 75 mg once daily.

Systemic examination was within normal limits, with the exception of blood pressure of 148/90 mmHg. Local examination revealed a firm overgrowth of inflamed gingiva throughout the mandible on the buccal surface (Refer figures 1 and 2). Dental evaluation was unremarkable for alternative local causes of the gingival overgrowth. Thorough clinical examination and basic lab investigations were negative for systemic causes of gingival overgrowth. A clinical diagnosis of amlodipine-induced gingival overgrowth was made thereafter and the drug was discontinued. Subsequent review showed a significant reduction in the overgrowth. Naranjo causality score was calculated as 7 indicating that amlodipine was the probable cause for this adverse drug reaction (Naranjo *et al.*, 1981)

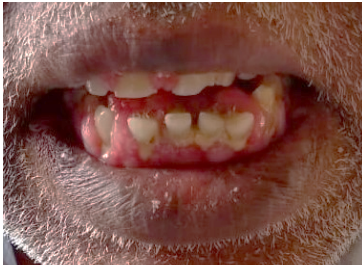

Figure 1: Facial view of extensive lower buccal gingival overgrowth

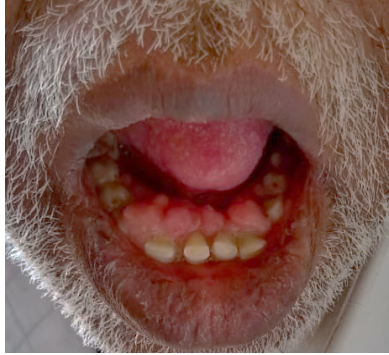

Figure 2: Lingual view of lower gingival overgrowth

The patient underwent dental procedures including scaling and was shifted to labetalol 100 mg twice daily for the further management of hypertension. On reassessment after six weeks, a drastic improvement in the clinical picture of gingiva was noted with complete resolution of inflammation.

Discussion

Amlodipine is the most frequently prescribed calcium channel blocker in the management of hypertension due to its favourable duration of action and side effect profile. It is structurally analogous to nifedipine but pharmacodynamically distinct from it. Nifedipine and other classes of drugs including antiepileptics and immunosuppressants, are typically implicated in drug-induced gingival hyperplasia. The prevalence of drug-induced gingival overgrowth is least with amlodipine when compared to other CCBs used in the treatment of hypertensive heart disease. Amlodipine-induced gingival overgrowth generally ensues within the first three months of initiating a 10 mg/day regime and presents at first as interdental papillary enlargement (Jorgenson *et al.*, 1997). This patient reported rapid gum enlargement within two months of initiation of the drug. Cases reported thus far are suggestive of gradual enlargement over months.

Review of the etiopathogenesis of drug-induced gingival overgrowth in which they represented it as a complex multifactorial model. Age, genetic predisposition, pharmacokinetic properties, drug-induced modifications in gingival connective tissue homeostasis, histopathology, ultrastructural factors and inflammatory changes, and drug-induced activation of growth factors play a pivotal role in the pathogenesis of GO. Human gingival fibroblasts when exposed to calcium channel blockers and elevated levels of interleukin-1 β (pro-inflammatory cytokine) simultaneously, produce large amounts of

collagenous proteins. Interleukin-6 also plays an important role in the fibrogenic response of gingiva to these medications. It triggers fibroblast proliferation and positively regulates collagen and glycosaminoglycans synthesis (Seymour *et al.*, 1996).

Drug-induced gingival overgrowth is postulated to involve inflammatory and non-inflammatory pathways. The proposed non-inflammatory mechanisms include decreased folic acid uptake causing defective collagenase activity; and inhibition of adrenal cortex aldosterone synthesis with consequent positive feedback elevating levels of adrenocorticotrophic hormone and causing upregulation of keratinocyte growth factor. Alternatively, high concentrations of these drugs in crevicular gingival fluid have direct toxic effects on the gingiva. This inflammation can cause upregulation of several cytokine factors including transforming growth factor- β 1 (Nyska *et al.*, 1994; Marshall *et al.*, 1999; Lafzi *et al.*, 2006).

It has been found that calcium channel blockers inhibit the intracellular Ca^{2+} uptake thereby stimulating gingival fibroblasts. The increase in size is due to a build-up of collagen in the extracellular matrix, and not because of epithelial/connective tissue hyperplasia or hypertrophy. The reason for only some patients who receive the drug to develop gingival enlargement can be, the abnormal susceptibility of gingival fibroblasts to that drug in those individuals. It has been proposed that the existence of differential proportions of fibroblast subsets in each individual determines their susceptibility to drug-induced gingival overgrowth. It has also been shown that functional heterogeneity exists in gingival fibroblasts in response to various stimuli (Seymour *et al.*, 1991).

Medical management consists of stopping or replacing the offending drug if possible and providing folic acid and ascorbic acid supplements. It has been reported that the size of gingival overgrowth reduces within a week of drug withdrawal and may subsequently result in complete resolution (Raman *et al.*, 1988). Rarely, histopathological evaluation is required for the confirmation of diagnosis. Medical physicians must evaluate for and rule out systemic causes of GO like HIV, diabetes, Crohn's disease, lymphoma and vitamin deficiencies. Patients benefit from effective oral hygiene measures, professional tooth cleaning, scaling, and root planning. If gingival overgrowth persists after careful consideration of the previously mentioned approaches, these cases need to be treated by surgery interventions such as gingivectomy or flap surgery (Mavrogiannis *et al.*, 2006). An integrated approach between the medical and dental physician is crucial to the successful management of drug-induced gingival hyperplasia.

Conclusions

Amlodipine is a frequently prescribed first line drug in the management of hypertension and angina pectoris. This case report highlights the need for physicians to be cognizant of rare side effects like accelerated gingival overgrowth seen with the use of high dose amlodipine.

Early recognition and timely integrated intervention by medical and dental physicians, is vital for its successful management.

Acknowledgment

We thank the Department of General Medicine, VIMS&RC, Bangalore for their support and encouragement.

Conflict of interest

There are no conflicts of interest.

Funding

None

References

- Lafzi A, Farahani RMZ, and Shoja MM. Amlodipine-induced gingival hyperplasia. *Medicina Oral Patologia Oral y Cirugia Bucal*, 2006; 11(6):E480–E482.
- Nyska A, Shemesh M, Tal H, Dayan D. Gingival hyperplasia induced by calcium channel blockers: mode of action. *Medical Hypotheses*, 1994;43(2):115-118.
- Bhatia V, Mittal A, Parida AK, Talwar R, Kaul U. Amlodipine induced gingival hyperplasia: a rare entity. *International journal of cardiology*, 2007;122(3):e23-e24.
- Dougall HT, McLay J. A comparative review of the adverse effects of calcium antagonists. *Drug safety*, 1996;15(2):91-106.
- Ellis JS, Seymour RA, Thomason JM, Monkman SC, Idle JR. Gingival sequestration of amlodipine and amlodipine-induced gingival overgrowth. *Lancet*. 1993;341(8852):1102-1103.
- Fares H, DiNicolantonio JJ, O'Keefe JH, Lavie CJ. Amlodipine in hypertension: a first-line agent with efficacy for improving blood pressure and patient outcomes. *Open Heart*, 2016;3(2):e000473.
- Livada R, Shiloah J. Calcium channel blocker-induced gingival enlargement. *Journal of human hypertension*, 2014;28(1):10-14.
- Jorgensen MG. Prevalence of amlodipine-related gingival hyperplasia. *Journal of periodontology*, 1997;68(7):676-678.
- Mavrogiannis M, Ellis JS, Thomason JM, Seymour RA. The management of drug-induced gingival overgrowth. *Journal of clinical periodontology*, 2006;33(6):434-439.
- Naranjo CA, Busto U, Sellers EM, et al. A method for estimating the probability of adverse drug reactions. *Clinical pharmacology and therapeutics*, 1981;30(2):239-245.
- Nery EB, Edson RG, Lee KK, Pruthi VK, Watson J. Prevalence of nifedipine-induced gingival hyperplasia. *Journal of periodontology*, 1995;66(7):572-578.
- Raman PG, Mishra VN, Singh D. Nifedipine induced gingival hyperplasia. *The Journal of the Association of Physicians of India*, 1988;36(3):231-233.
- Seymour RA, Thomason JM, and Ellis JS. The pathogenesis of drug-induced gingival overgrowth. *Journal of Clinical Periodontology*, 1996;23(3):165-175.
- Seymour RA. Calcium channel blockers and gingival overgrowth. *British dental journal*, 1991;170(10):376-379.
- Marshall RI, Bartold PM. A clinical review of drug-induced gingival overgrowths. *Australian dental journal*, 1999;44(4):219-232.
- Triveni MG, Rudrakshi C, Mehta DS. Amlodipine-induced gingival overgrowth. *Journal of Indian Society of Periodontology*, 2009;13(3):160-163.