

Deep learning for fully-automatic quantification of avascular necrosis of the femoral head on 3D hip MRI in young patients eligible for joint preserving hip surgery: A pilot study

Adrian Ruckli¹, Florian Schmaranzer², Till Lerch², Adam Boschung², Simon Steppacher³, Juergen Burger¹, Moritz Tannast⁴, Klaus Siebenrock³, Kate Gerber¹, Nicolas Gerber¹

1. sitem Center for Translational Medicine and Biomedical Entrepreneurship, University of Bern, Switzerland 2. Department of Diagnostic-, Interventional- and Pediatric Radiology. Inselspital, University of Bern, Switzerland 3. Department of Orthopaedic Surgery and Traumatology. Inselspital. University of Bern, Switzerland 4. Department of Orthopaedic Surgery and Traumatology. Kantonsspital Fribourg, University of Fribourg, Switzerland

INTRODUCTION & AIM

Size of necrosis is an important prognostic factor in the management of femoral head necrosis (AVN), which is usually estimated on radiographs and MRIs. Ideally, a fast-volumetric assessment of necrosis size would be desirable. Thus, we evaluated a deep-learning method to automatically quantify the necrotic bone in AVN.

METHOD & DATASET

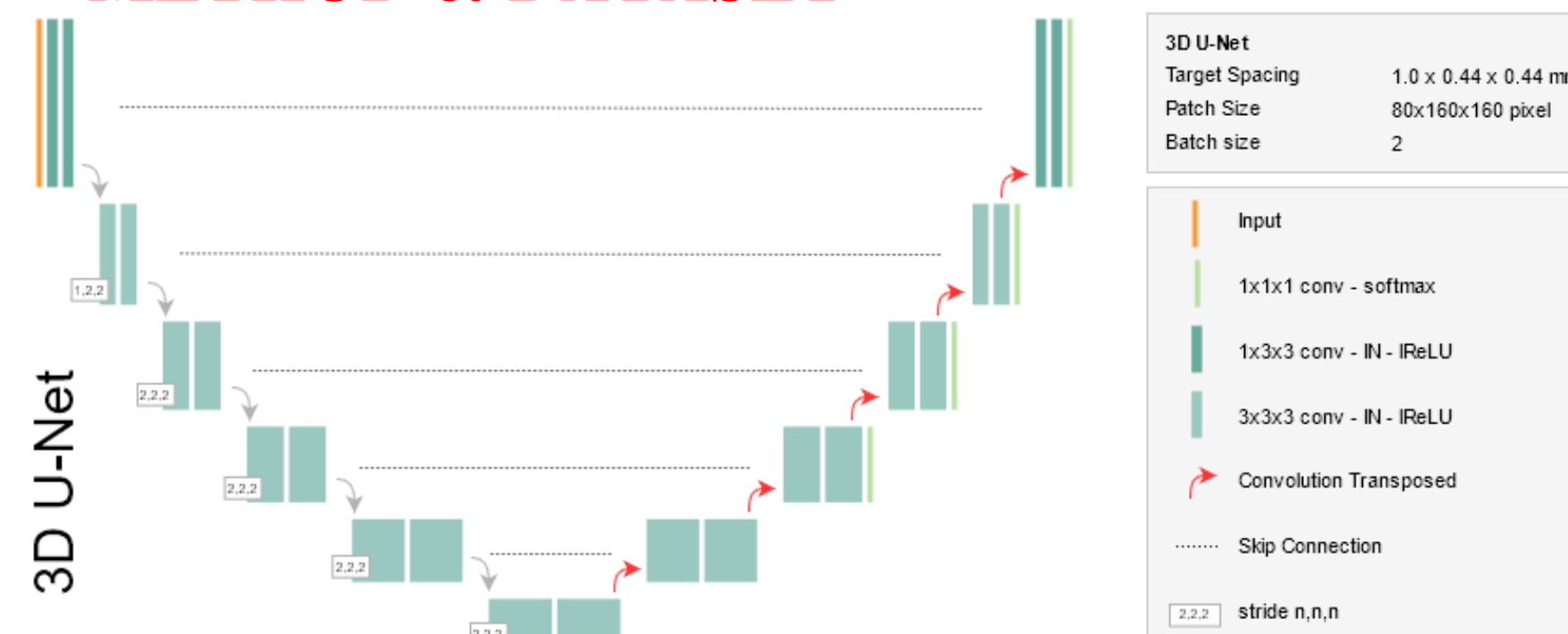


Figure 1. The architecture of the underlying 3D U-net is shown. The nnU-Net: a self-configuring method for deep learning-based biomedical image segmentation (Isensee et al. Nature Methods 2020) was used to train and predict the segmentation of the femoral head necrosis.

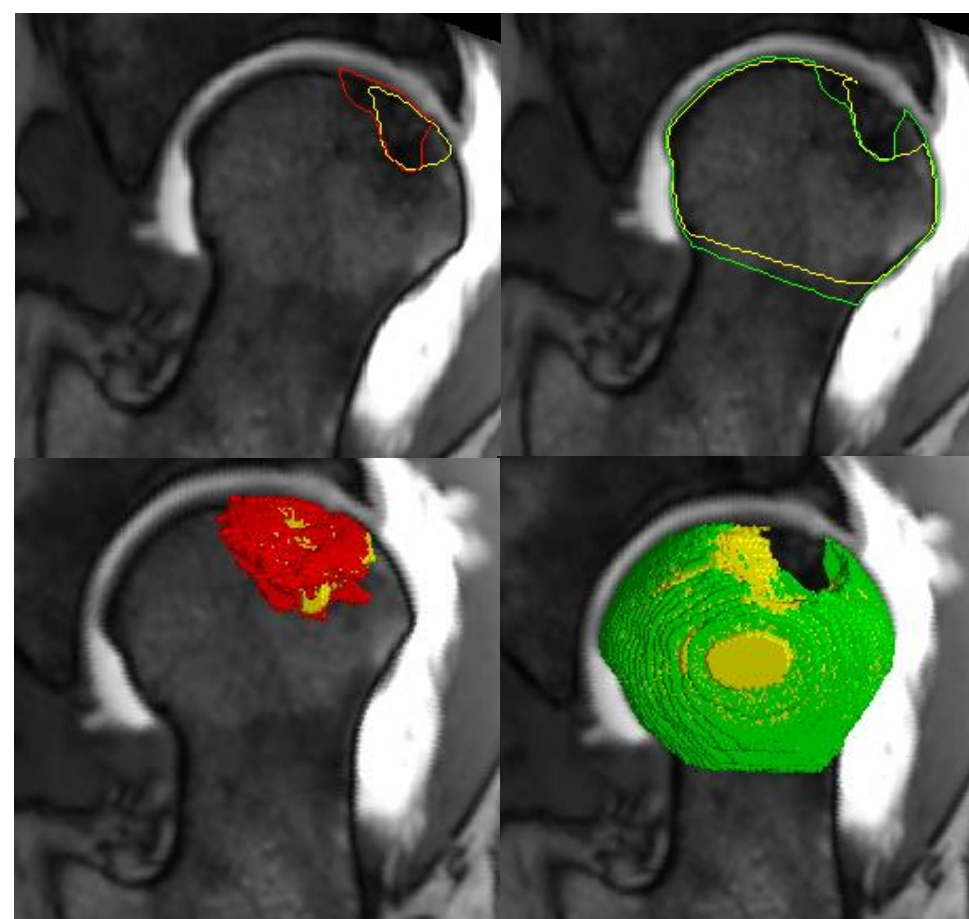
Dataset & Preprocessing

- The dataset contains 34 hip MR images with 2019 ARCO grading I: 3 hips; II: 5 hips; IIIA: 14 IIIB: 12; from the university hospital of Bern.
- Patients underwent preoperative 3T hip MRI including 0.8 mm³ 3D T1VIBE.
- All MR images were volume cropped and resampled to 80×160×160 voxels and 1×0.44×0.44 mm, respectively.
- 5-fold cross-validation was performed between manual and automatic volumetric analysis of absolute/relative necrosis volume.

EXPERIMENTS & RESULTS

The configuration with the best performance was the ensemble of the 2D and 3D U-net. The mean Dice coefficient for the vital femoral head bone and necrosis was 89±9% and 69±25%, respectively.

Figure 2. Visual segmentation results. Left: necrotic bone. Right: vital bone. Top: segmentation on axial oblique slice. Bottom: 3D model overlay. Red/Green: ground truth. Yellow: automatic segmentation.



Mean absolute and relative AVN volume was comparable between manual (8.2±7.4cm³, 17±15%) and automatic (7.3±6.7cm³, 15±14%) segmentation (both p>0.05) and showed a strong correlation (r_p = 0.90 and 0.92, respectively, both p<0.001). Manual and automated segmentation detected a difference (both p<0.05) in relative necrosis volume between early (ARCO I/II) and advanced (ARCO III) AVN: 8±8% vs 20 ±16% and 7±8% vs 18±14%, respectively.

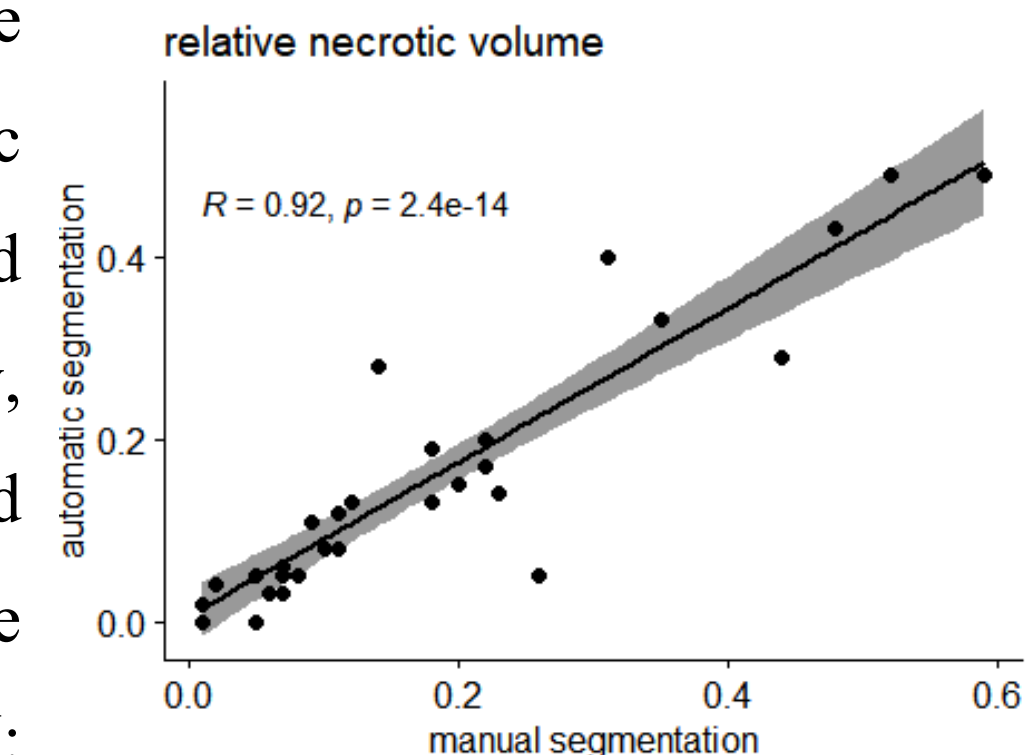


Figure 3. Scatter plot of relative necrotic volume. Manual vs. automatic segmentation.