



Journal Homepage: [-www.journalijar.com](http://www.journalijar.com)

INTERNATIONAL JOURNAL OF ADVANCED RESEARCH (IJAR)

Article DOI:10.21474/IJAR01/12544
DOI URL: <http://dx.doi.org/10.21474/IJAR01/12544>



RESEARCH ARTICLE

PENIS NECROSIS IN A DIABETIC PATIENT AND CHRONIC HEMODIALYSIS

Khalid Ouatar, Cheikh Saad Bouh Khattraty, Mustapha Ahsaini, Soufiane Mellas, Med Fadl Tazi, Jalal Eddine El Ammari and My Hassan Farih

Department of Urology, Andrology and Renal Transplantation, University Hospital Hassan II, University Sidi Mohamed Ben Abdellah, Fez, Morocco.

Manuscript Info

Manuscript History

Received: 05 January 2021

Final Accepted: 09 February 2021

Published: March 2021

Abstract

Penis necrosis is a rare entity. Most often serious and it could have life-threatening prognosis because in the majority of cases it's found in severe peripheral arterial disease it occurs mainly in chronic kidney failure patients with diabetes or diabetic patients. Penis has a very good blood supply; Arterial obstruction secondary to arteriolic calcification can cause distal necrosis. the treatment is essentially surgical. We report a case of penis necrosis treated by partial amputation.

Copy Right, IJAR, 2021,. All rights reserved.

Introduction:-

Penis necrosis is a rare entity. Most often serious and it could have life-threatening prognosis because in the majority of cases it's found in severe peripheral arterial disease it occurs mainly in chronic kidney failure patients with diabetes or diabetic patients.

Penis has a very good blood supply; Arterial obstruction secondary to arteriolic calcification can cause distal necrosis.the treatment is essentially surgical. We report a case of penis necrosis treated by partial amputation.

Observation:-

A 62 year old man with type 2 diabetes on insulin, discovered 22 years ago, with chronic hemodialysis two sessions per week.He presented to the emergency room for acute urine retention for six days, associated with blackish coloration of glans penis that appeared two weeks earlier.

On the clinical examination, we find a patient stable in the hemodynamic respiratory and apyretic levels. The abdominal examination finds a hypogastric sensitivity associated with hypogastric yoursure, examination of the external genitalia finds a localized necrosis at the glans penis that extends a bit more on the ventral face(picture 1). The biological balance showed hyperleucocytosis at 13400/ml, a CRP:133 mg/l hemoglobin (hb): at 8.4 mg/dl a creatinine at 45 mg/l. The urine test (CBEU) came back sterile.

The patient received a cystostomy (picture 2) and then went to the operation room where he received a partial penectomy(picture3).

The post-operative steps were simple, with good clinical and biological improvement.The remaining part of the penis is well vascularized has been sent to anatomopathology for etiological research including calciphylaxis.

Corresponding Author:- Khalid Ouatar, Khattraty Cheikh Saad Bouh

Address:- Service d'urologie, CHU Hassen II.

Discussion:-

Penis gangrene is a rare but serious complication often is a part of systemic calciphylaxis [2], few cases have been reported in the literature.

The penis ischemia is progressively installed [5]

Two main etiologies implicated in the pathophysiology of the penis ischemia are type 2 diabetes and the accumulation of calcium deposits due to end-stage chronic kidney failure[6]. However other causes have been reported in the second lineage, including thromboembolic disease, clotting disorders secondary to a neoplastic disease, trauma and infection[3].

Clinical differentiation between dry gangrene due to ischemic disease and wet gangrene with infection is decisive in choosing the appropriate treatment.[7]

MRI is the most effective examination for the exploration of cavernous bodies, it shows a clear boundary between necrotic tissue and healthy tissue.[2]

The indication of conservative treatment usually involves small, circumscribed lesions or high-risk patients, [7] Aggressive treatment is recommended for patients who do not have severe comorbidities.[4]

Harris and Mydlo reported no progression of necrosis in three patients who had initial debridement of necrosis, combined with local care and antibiotic therapy [9]. Stein et al. reported a mortality rate of 71% in a series of seven patients[5,8]. Weiner and Lowe, in a series of seven patients with ischemic

gangrene of the penis during diabetes, reported a 57% mortality rate within six months of diagnosis[5,7]

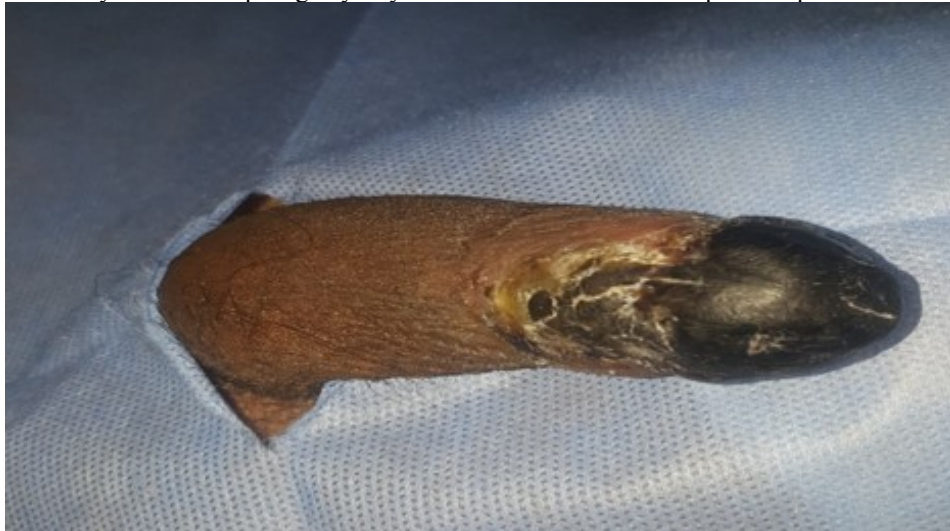They noted that early penectomy, even if it does not decrease the mortality rate, it can improve quality of life by preventing or limiting locoregional complications[1].

In our case a conservative treatment was performed, including a partial Penectomy.

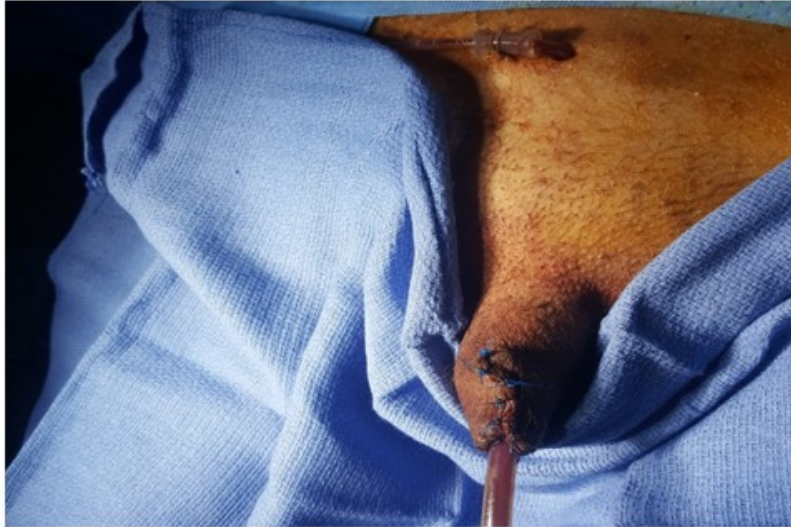Conclusion:-

Gangrene of the penis is a rare entity that often testifies to severe peripheral artery disease, most often a systemic calciphylaxis. Type 2 diabetes and end-stage kidney failure are the main factors involved. Two therapeutic modalities can be considered. Conservative treatment and radical surgical treatment based on penectomy.

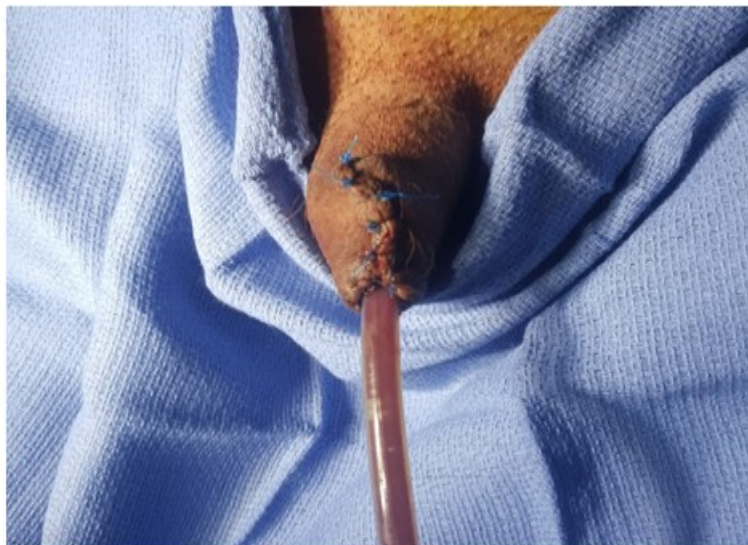
Prevention is essentially based on depistage by a systematic examination of the penis of patients at risk.



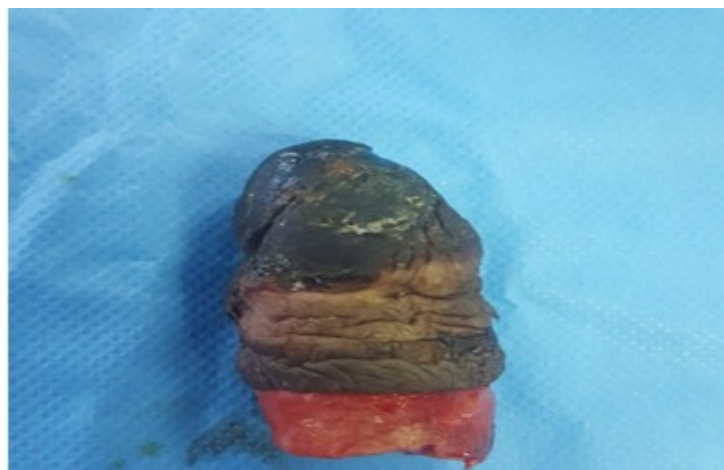Picture 1:- Necrosis of the glans penis that extends to the ventral face of the penis.



Picture 2:- Cystostomy probe in place.



Picture 3:- Partial penectomy.



Picture 4:-Operating piece.

Reference:-

1. T. el moutawakil et al. : la gangrene ischemique de la verge chez un patient diabétique 2015 2-4
2. Bouzouita, w.kerkeni et al . la gangrene de la verge : une rare complication de la calciphylaxie systemique a depister 2013; 2-3
3. khader El, et al. Une necrose du gland. La revue de medecine interne. 2011;32(5):321-322.
4. Srikantaiah Hc. Idiopathique gangrene du penis. Journal de la recherche clinique et de diagnostic. 2011;5(2):353-354.
5. Vijayan P. Gangrene of the penis in a diabetic male with multiple amputations and follow-up. Indian J Urol. 2009;25(1):123-125.
6. Chien JC-W, et al. Penile gangrene in a patient on renal dialysis: ct findings. Computerized medical imaging and graphics. 2007;31(2):103-105.
7. Gillitzer R, et al. Complete gangrene of penis in patient with arterial vascular disease. J urology. 2004;64(6):1231.
8. Constantine Harris F, Jack Mydlo H. Ischemia and gangrene of the penis. The journal of urology. 2003;169(5):1795.
9. David, et al. Surgical management of ischemic penile gangrene in diabetics with stage atherosclerosis. American Urological Association. 1996;155(3):926-929.