

Editorial

Advancing Clinical Dysmorphology Diagnostic Skills: Weaver Syndrome

Aamir Jalal Al-Mosawi*

Baghdad Medical City and the National Center of Training and Development, Iraq

EDITORIAL

There are now too many of rare clinical syndromes and dysmorphic syndromes including genetic syndromes, and it is difficult for most physicians to equip themselves with adequate professional knowledge that help them to make an early useful diagnosis for many of the syndromes they may encounter [1-5].

We have previously described our pioneering extensive experiences with clinical genetics and dysmorphology in a plethora of publications. We have previously reported a large number of rare conditions in Iraq [6-14], and we have also helped physicians in the diagnosis and publication of rare syndromes observed in other countries [15]. The aim of this papers is to help clinicians in advancing the diagnostic skills in the field of clinical syndromes by reviewing briefly a rare syndrome that have not been reported in Iraq, but it is associated with certain clinical characteristics that allow clinicians who see the syndrome for the first time, capable of making an easy diagnosis by knowing few information about the condition.

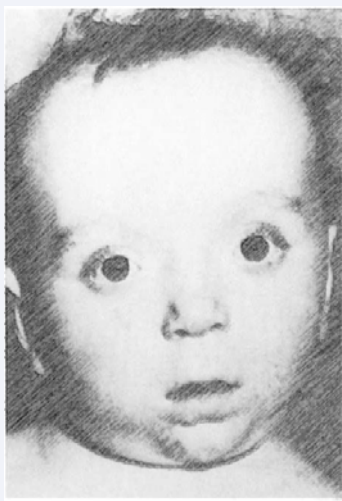

Figure 1 A sketch of the facial dysmorphism of Weaver syndrome which include broad forehead and face, large ears, hypertelorism, and, micrognathia.

*Corresponding author

Aamir Jalal Al-Mosawi, Advisor doctor and expert trainer, Baghdad Medical City and the National Center of Training and Development, Baghdad, Iraq, Email: almosawiAJ@yahoo.com

Submitted: 28 October 2020

Accepted: 24 November 2020

Published: 27 November 2020

ISSN: 2373-9312

Copyright

© 2020 Al-Mosawi AJ

OPEN ACCESS

Weaver syndrome is a rare mental retardation-overgrowth syndrome with prenatal and postnatal excessive growth. Features that make the syndrome distinctive from other overgrowth syndromes such Soto's syndrome include broad forehead and face, large ears, hypertelorism, micrognathia, camptodactyly or clinodactyly.

The syndrome was first reported by David Weaver and his



Figure 2 Camptodactyly, a flexion deformity of the proximal interphalangeal joint in the antero-posterior] plane with inability to extend the joint.

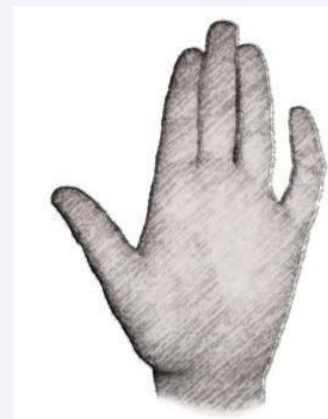


Figure 3 Clinodactyly, an angular deformity in the radio-ulnar plane.



Figure 4 David D. Weaver, an American physician who was born in 1939.

colleagues (Figure1-4), in 1974. Knowing that Weaver syndrome is a mental retardation-overgrowth syndrome associated with distinctive facial features and camptodactyly or clinodactyly, will make the condition in most instances make the syndrome not difficult to diagnose, but difficult to miss.

Of the three important mental retardation-overgrowth syndrome, Soto syndrome and Weaver have not been reported in Iraq, but Beckwith Wiedemann syndrome has been well-described and reported in Iraq [17].

REFERENCES

1. Al-Mosawi AJ. Mostyn Embrey syndrome. 1st ed., Saarbrücken; LAP Lambert Academic Publishing: 2016.
2. Al-Mosawi AJ. Congenital Chevalier Jackson syndrome. 1st ed., Saarbrücken; LAP Lambert Academic Publishing. 2016.
3. Al-Mosawi AJ. Unilateral Renal Agenesis and the Awareness of Mostyn Embrey Syndrome. *Journal of Renal Medicine*. 2017; 1: 1-4.
4. Al-Mosawi AJ. The Twenty Eighth Case of Congenital Chevalier Jackson. *Ann Clin Case Reports*. 2019; 4: 1-4.
5. Al-Mosawi AJ. The Case Number 104 of Sanjad Sakati Richardson Kirk Syndrome. *J Res Notes*. 2019; 2: 1-3.
6. Al-Mosawi AJ. Rare genetic disorders in Iraq. (Ed). LAP Lambert Academic. 2011.
7. Al-Mosawi AJ. Genetic and Hereditary Disorders in Iraqi Children. *Ann Med & Surg Case Rep*. 2019; 1 (2): 1-8.
8. Al-Mosawi AJ. Clinical Genetics and Dymorphology: Our Extraordinary Experiences. *SunKrist J Neonatology and Pediatr*. 2020; 2: 1-10.
9. Al-Mosawi AJ. Uncommon and Rare Pediatric Syndromes Associated with Surgical Conditions in Iraqi Children. *Global J Surg Surgical Techniques*. 2020; 21: 1-8.
10. Al-Mosawi AJ. The Uncommon and Rare Genetic Disorders in Iraq. 1st ed., Saarbrücken; LAP Lambert Academic Publishing: 2018.
11. Al-Mosawi AJ. Les maladies génétiques rares et peu communes en Irak (French edition). Editions Notre Savoir (2020-05-27).
12. Al-Mosawi AJ. Clinical genetics and dysmorphology: A unique pioneering experiences .1st ed., Saarbrücken; LAP Lambert Academic Publishing. 2020.
13. Al-Mosawi AJ. Klinische Genetik und Dymorphologie: Eine einzigartige bahnbrechende Erfahrung (German Edition). Verlag Unser Wissen. 2020.
14. Al-Mosawi AJ. Genetica clinica e dismorfologia: Un'esperienza pionieristica unica (Italian Edition). Edizioni Sapienza. 2020.
15. Al-Mosawi AJ, Fewin L. The first case of Niikawa-Kuroki syndrome in Kazakhstan associated with café au lait spots. *G Ital Dermatol Venereol*. 2009; 144: 613-615.
16. Weaver DD, Graham CB, Thomas IT, Smith DW. A new overgrowth syndrome with accelerated skeletal maturation, unusual facies, and camptodactyly. *J Pediatr*. 1974; 84: 547-552.
17. Al-Mosawi AJ. Beckwith Wiedemann syndrome. 1st ed., Saarbrücken; LAP Lambert Academic Publishing. 2016.

Cite this article

Al-Mosawi AJ. *Advancing Clinical Dymorphology Diagnostic Skills: Weaver Syndrome*. *Ann Pediatr Child Health* 2020; 8(10): 1211.