

ISSN 1759-0116 (Online)

ZooNova

Occasional Papers in Zoology

Number 6, Pages 1 – 15

OBSERVATIONS ON ABNORMALITIES IN SOUTH AFRICAN REPTILES

LYNN R. G. RAW

Published on-line at zoonova.afriherp.org

Afriherp Communications, Greenford, United Kingdom

Date of publication: 9 March 2021

Copyright: L.R.G. Raw 2021

Electronic copies deposited in

The British Library; National Library of Scotland; National Library of Wales;

Bodleian Library, Oxford; University Library, Cambridge;

Library of Trinity College, Dublin.

Observations on Abnormalities in South African Reptiles

Lynn R. G. Raw

Kirkebakken 37, Ålsø, 8500 Grenaa, Denmark

Email: lynn@afriherp.org

<https://orcid.org/0000-0003-4944-4334>

ABSTRACT

Abnormalities or aberrations in various reptiles are briefly discussed. Details and photographs are provided of some abnormalities observed in a few South African species. These include major differences in the body scales of a specimen of *Pseudocordylus subviridis*, deformed full-term foetuses of *Causus rhombeatus* and *Boaedon capensis*, minor differences in head scales in *Dendroaspis angusticeps*, *Tropidosaura montana natalensis*, *Philothamnus occidentalis* and *Philothamnus semivariatus*, as well as colour mutations in *Philothamnus* spp. and other snakes.

KEYWORDS:

dicephalism, colour mutations, abnormal scales, developmental deformities.

INTRODUCTION

Developmental abnormalities in reptiles are well known, particularly dicephalism in snakes, lizards and chelonians (e.g., Kim *et al*, 2013; Spadola and Insacco, 2009; Wallach, 2007). Brown, et. al. (2017), who investigated aberrant scalation in the Australian snake *Stegonotus cucullatus* state that “Variation in phenotypic traits is a complex result of genetic and epigenetic factors, maternal effects and developmental environments, as well as interactions between these processes.” The authorities for the scientific names used in the text are given in Table 1. This has been done to avoid confusion between name authorities and literature citations in the text.

Broadley (1975) reported Zimbabwean examples of dicephalism in a Striped Skink (*Trachylepis*), a Cape Wolf Snake (*Lycophidion capense*) and a Herald Snake (*Crotaphopeltis hotamboeia*).

Further examples have been personally seen in another Herald Snake (Fig. 1), captive born reptiles (Yellow Anaconda (*Eunectes notaeus*) and Slider Terrapin (*Trachemys* sp.)) and in another Striped Skink (Fig. 2). There are many causes of dicephalism during embryonic development Wallach (2007) provides a list of eleven possible causes of dicephalism including unusually high or low temperatures or anoxia (hypoxia?) during development, prolonged retention in the oviducts increasing exposure to metabolic toxins and environmental toxins such as result from pollution.

More common colour mutations are xanthism, leucism, albinism and melanism. Some examples of melanistic *Philothamnus* spp., leucistic *Crotaphopeltis hotamboeia*, amongst others, are provided. Aberrant patterns are much rarer, particularly in snakes, e.g. striped Puff Adders (*Bitis arietans*) (Branch, 1988: 114). Mahabal & Thakur (2014) have reviewed aberrant colours and patterns among the Indian herpetofauna and have examined the causes and effects involved. Partial albinism (aberrant white scales or patches) has been recorded in Natal Purple-glossed Snakes (*Amblyodipsas concolor*) (Bourquin, 1970; Raw, 1971) and a Natal Black Snake (*Macrelaps microlepidotus*) (Raw, 1971) from KwaZulu-Natal.

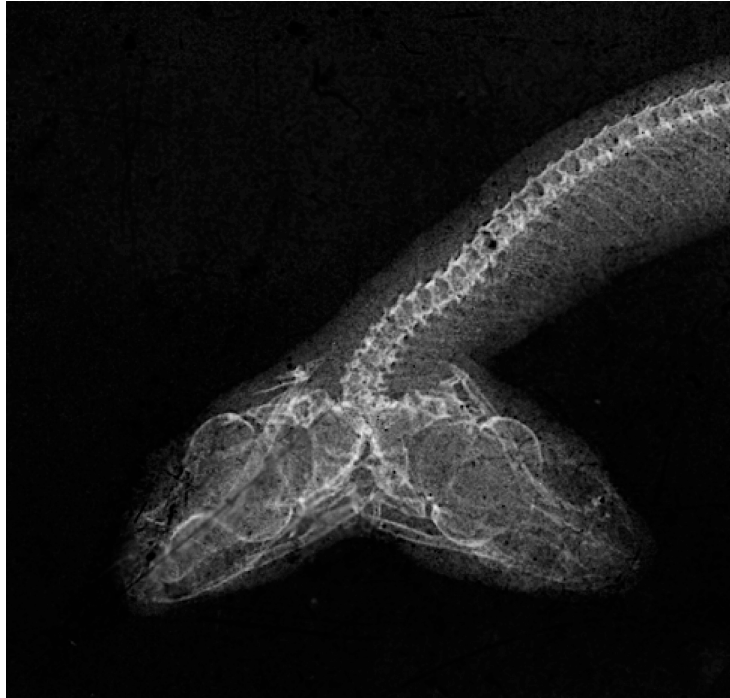

Figure 1. Radiograph (X-ray) of two-headed *Crotaphopeltis hotamboeia* from KwaZulu-Natal.

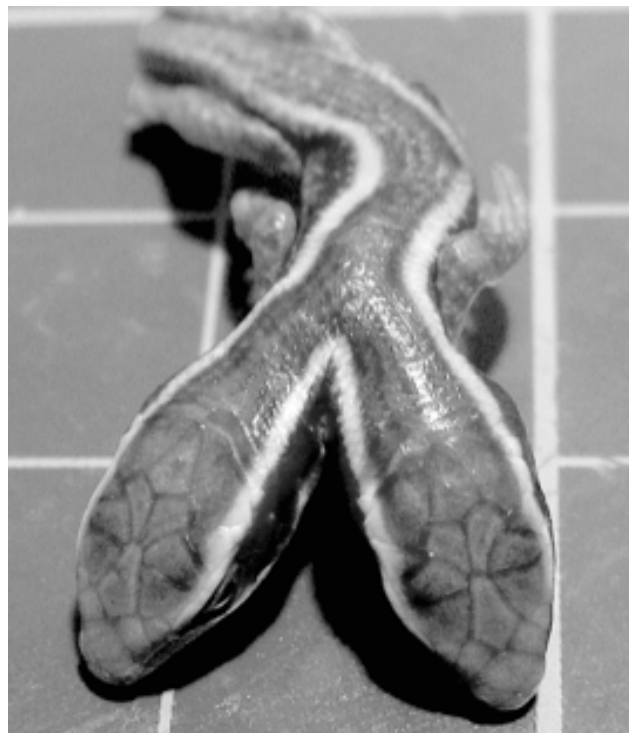

Figure 2. Two-headed Striped Skink neonate from Drummond, KwaZulu-Natal.

Scaleless mutations have been observed in some snakes, e.g. in *Pituophis melanoleucus catenifer* (Licht & Bennett, 1972), *Crotalus atrox* (Toni & Alibardi, 2007), *Nerodia sipedon* (Bennett & Licht, 1975), while various reptile internet forums mention or show photographs of examples in *Acanthophis antarcticus*, *Python regius*, *Python bivittatus*, and *Pantherophis guttatus* as well as Southern African examples in *Bitis arietans* and *Boaedon capensis*. These genetic mutations are

usually recessive but can become established through selective captive breeding. Galois & Ouellet (2007) list a number of abnormalities in reptiles from Canada.

This paper provides details of aberrant reptiles in Southern Africa, either observed personally or brought to my attention by others. Table 1 provides details of the nomenclatural authorities for the species names mentioned in this paper.

EXAMPLES OF ABERRANT SOUTHERN AFRICAN REPTILES

Pseudocordylus subviridis

Gordon Setaro collected a living *Pseudocordylus subviridis* near Little Switzerland Resort, Oliviershoek Pass, KwaZulu-Natal. On handling the lizard, it was noticed that this female individual felt noticeably different to others collected at the same time and place. Close examination showed that the scales on the back differed from the normal arrangement in *Pseudocordylus subviridis* (Fig. 3). In addition, the ventral scales were round (Fig. 4) rather than rectangular as is the usual case in *Pseudocordylus*.

The dorsal head shields (Fig. 5) appeared to be within the normal [range of] variation in *P. subviridis* although the scales on the nape were smaller and more granular than normal.

This lizard was held in captivity and later gave birth to young that were similar in all respects to normal *P. subviridis*. The specimen was preserved after being found dead some time later. While very distinctive compared to 'normal' *P. subviridis* at the same locality there seems little doubt that this specimen is merely an aberrant example of this species and not a representative of some un-described new taxon.




Figure 3. Dorsum comparison – Aberrant specimen on left.

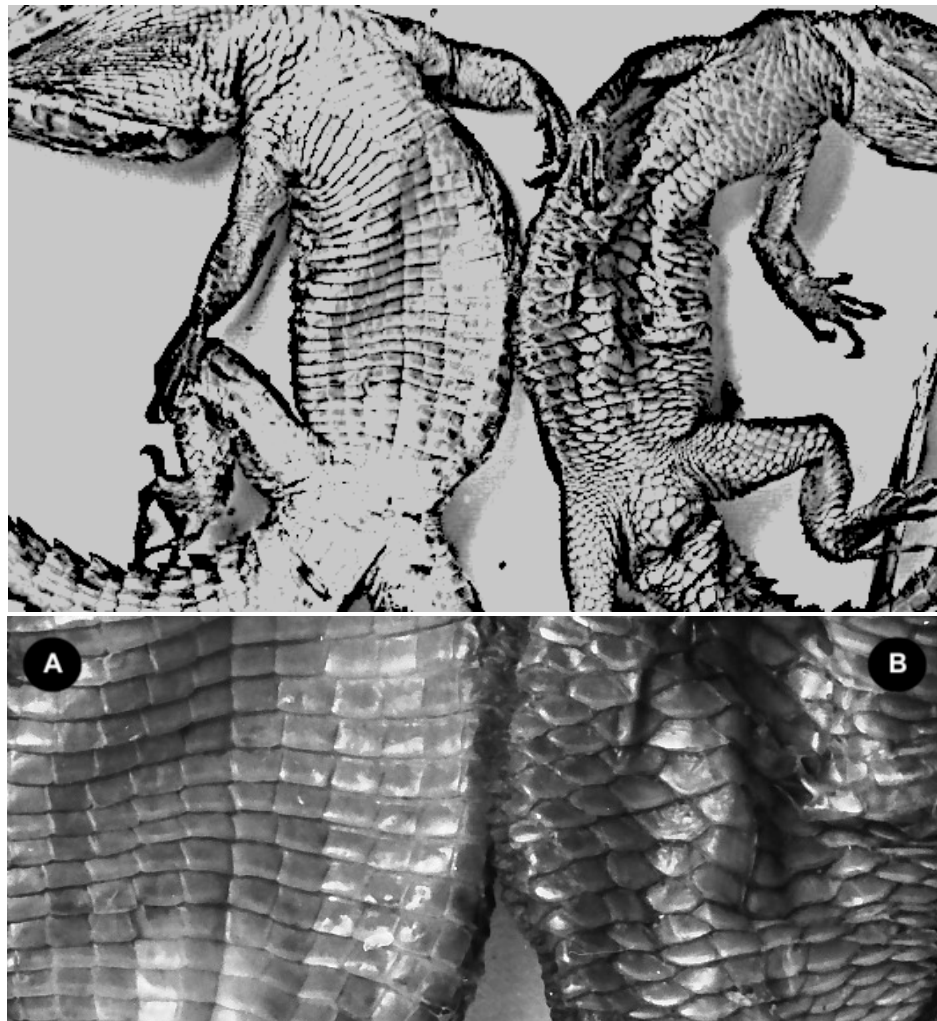


Figure 4. Ventral comparison with close up showing unusual specimen (B) on right

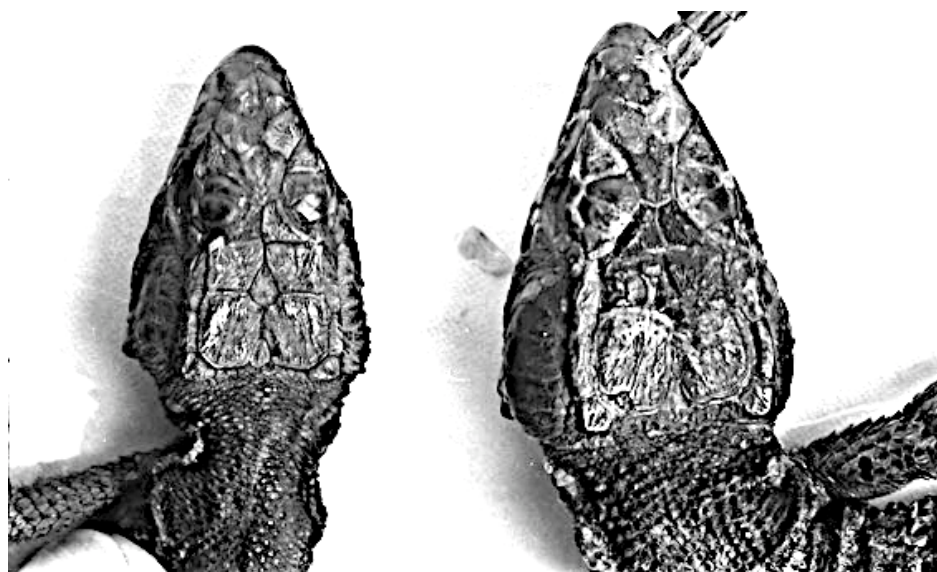


Figure 5. Dorsal aspect of head comparison – Aberrant specimen on left.

Causus rhombeatus

Following the incubation by the author of some Rhombic Night Adder (*Causus rhombeatus*) eggs, laid by a female captured in the vicinity of Durban, KwaZulu-Natal, one egg remained unhatched although still appearing to be in good condition. After a reasonable interval the egg was opened to see why it had not hatched. Inside the egg was a highly aberrant full-term foetus. The upper part of the head appearing normal (fig. 6) while the lower jaw was undeveloped (fig. 7). This could be a case of extreme micrognathia or possibly agnathia where the mandibles are underdeveloped or absent. The exposed roof of the mouth shows no signs of teeth or fangs (adontia or hypodontia) (Fig. 8).




Figure 6. Dorsal view of *Causus rhombeatus* foetus.



Figure 7. Ventral view of *Causus rhombeatus* foetus.

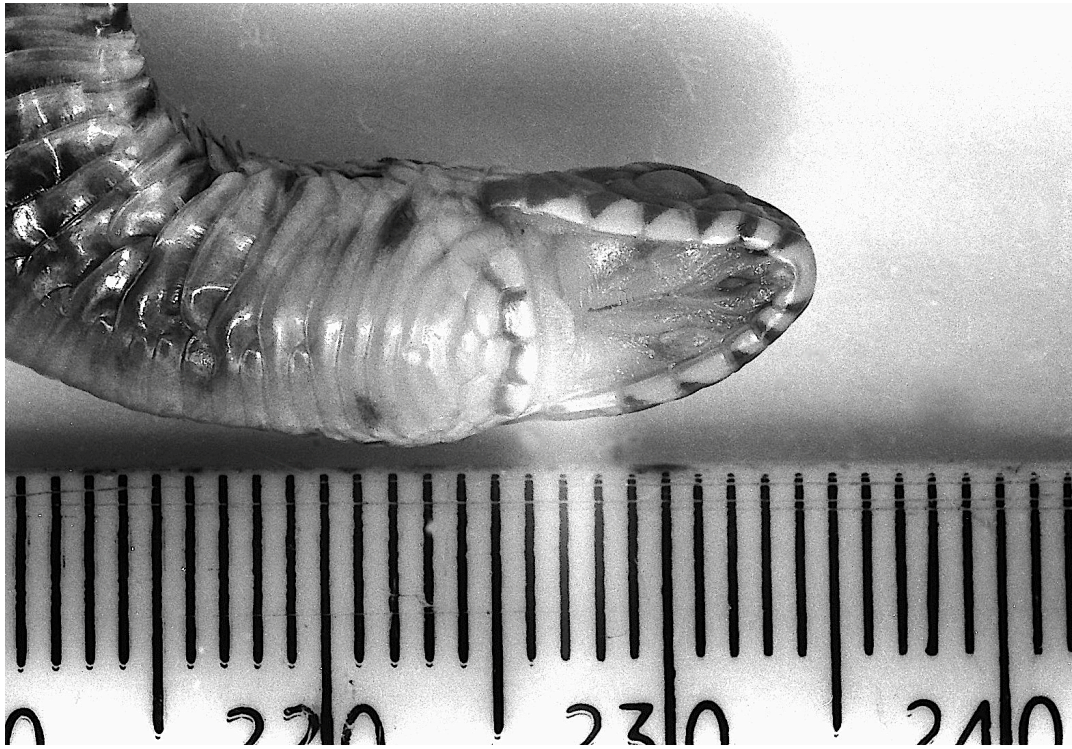

Figure 8. Closer view of of the underside of the head and anterior body

This peculiar developmental deformity appears to have never been reported before in the herpetological literature. At the time the photographs were taken the author did not have access to a microscope nor to X-Ray facilities and the specimen is no longer available for further study so the precise nature of the internal deformities remains unknown. The external appearance give the impression the hind body has been inverted within the body cavity close to the neck. The closest example found in the literature has the rear of the body and the tail protruding from the inverted portion of the body (Riches (1967, p. 15, fig. C). It is speculated that the development may have been interrupted at embryonic stage 18 (Zehr, 1962) before the development of the trunk coils. The divided ventrals suggest the presence of hemivertebrae where only one half of the affected vertebra develops correctly.

Boaedon capensis

Another developmental ‘monster’ was observed in a full-term foetus of brown house snake (*Boaedon capensis*) removed from an egg incubated by the author from eggs laid by a female found in the Durban area. This showed an undeveloped lower jaw (agnathia), unusually small eyes (microphthalmia) and fusion of loops of the body (kypholordosis) with fused ventrals (Fig. 9). These types of congenital defects have also been reported in neotropical crotalids by Sant’Anna et al (2013) while Pendlebury (1976, fig. 1, a & b) and Riches (1967, p. 15) illustrated fused body loops in *Crotalus v. viridis* and *Natrix maura* respectively.

While such deformities in snakes have been attributed to low incubation temperatures (e.g., Pendlebury, 1976) in this case it seems likely to be due to genetic mutation as other eggs in the clutch incubated in identical conditions developed normally.



Figure 9. Aberrant foetus of *Boaedon capensis*.

Two examples of the same species from two clutches bred in captivity by Deon Oosthuizen using parents from different localities are illustrated in (Figure 10). These show diprosopus heads with three and four eyes. Diprosopus (also known as craniofacial duplication) is partial duplication of the head caused by an excess of Sonic hedgehog (SHH) protein (Hu & Helms, 1999).



**Figure 10. Abnormal head development in artificially hatched *B. capensis*.
(Photographs by Deon Oosthuizen)**

Dendroaspis angusticeps

A hatchling Eastern Green Mamba, *Dendroaspis angusticeps*, was captured by the late Robert Hurst inside the Oppenheimer beach residence within coastal forest at La Lucia, KwaZulu-Natal in the early 1970s. The snake was kept in captivity for over five years by which time it had grown to over 1,5 metres. Although this snake was not preserved, a photograph taken when it was subadult clearly shows an aberrant inter-prefrontal triangular shield with its apex inserted between the paired prefrontals and the base abutting the frontal (Fig. 11). This was mentioned by Raw (1973) but never illustrated previously.



Figure 11. Aberrant inter-prefrontal in an eastern green mamba.

Tropidosaura montana natalensis

Also mentioned in Raw (1973) was a specimen of *Tropidosaura montana natalensis* collected at Winston Park, near Gillitts, KwaZulu-Natal, by Gordon Setaro. This had an aberrant row of small scales between the labials and the loreal region on both sides of the head (fig, 12). The normal arrangement has the labials in contact with the loreals.




Figure 12. *Tropidosaura montana natalensis* from Winston Park, KZN, showing the small scales (A) separating the supralabials from the loreals

Philothamnus spp.

Additional temporal shields that differ from the normal arrangement for the species are sometimes observed in species of African Green Snakes of the genus *Philothamnus*. An example of this variation in a *Philothamnus occidentalis* is provided (Fig. 13). In the species considered here, the usual temporal shield arrangement is 1 + 2 in *P. hoplogaster* and 2 + 2 in *P. occidentalis* and *P. semivariiegatus* (FitzSimons, 1962; Broadley, 1983). Other examples of such deviations from the normal arrangement are shown below under melanism.

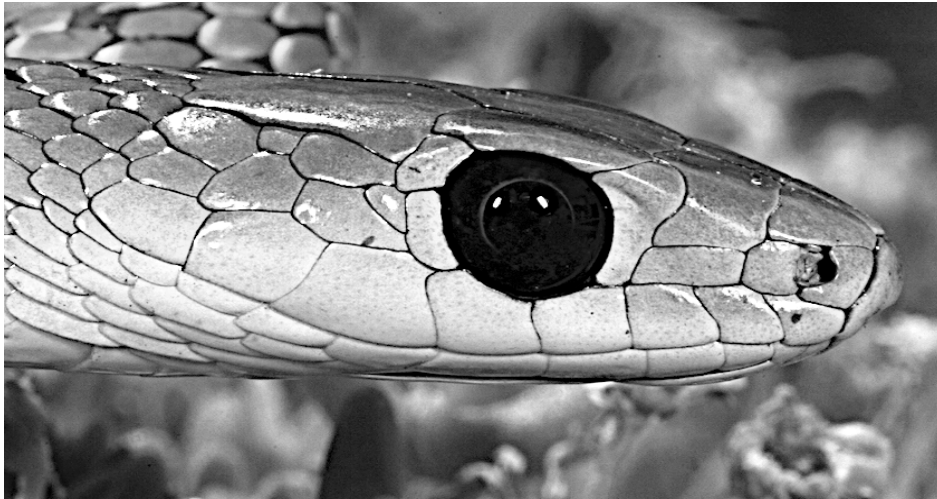

Figure 13. *Philothamnus occidentalis* showing an abnormal shield between the postocular and temporal shields. (photograph by Johan Marais)

Aberrant Colouration

Unusual colours are occasionally observed in reptiles, mainly but not always in snakes. This is apparently the result of genetic mutations causing over-expression of melanin (black pigment) or a reduction of melanin and other colour components. While many names have been devised for these mutations, the following are used here: ***melanism*** (where melanin dominates the other skin pigments), ***albinism*** (melanin suppressed to give an entirely white appearance with red eyes), ***amelanism*** where pinkish markings are present along with red eyes and ***leucism*** where the body is white with dark eyes. Sometimes these effects may be partial with parts of the animal retaining the normal colours and patterns. This is sometimes referred to as ***piebald***.

Amelanism

The following photographs show amelanism in a Rhombic Night Adder from Limpopo (fig. 14) and a Cape Dwarf Gecko (*Lygodactylus capensis*) found in Benoni, Gauteng (Fig. 15). Note the pinkish patterning and red eyes indicating that they are neither albino nor leucistic.



Figure 14. An amelanistic Rhombic Night Adder from Limpopo. (Photographer “Slangman”)



Figure 15. Amelanistic Cape Dwarf Gecko (Photograph by Chrisma Lotter).

Piebald (partial albinism)

An example of a piebald Cape Wolf Snake (*Lycophidion capense*) found at Nelspruit, Mpumalanga is shown below (Fig. 16).



Figure 16. A partial albino (piebald) Cape Wolf Snake (*Lycophidion c. capense*) from Nelspruit, Mpumalanga. (Anonymous)

Melanism

Melanism is occasionally reported in green snakes of the genus *Philothamnus*. The late Ray Parker, owner of the Durban Snake Park at the time, reported a melanistic Spotted Bush Snake (*P. semivariatus*) received by the park (Parker, pers. comm.).

An example of a melanistic Green Water Snake, *Philothamnus hoplogaster*, from Kloof, KwaZulu-Natal (Tyrone Ping, pers. comm.), is shown in Figure 17 below. Other melanistic examples follow. Figure 18 shows a melanistic *Philothamnus occidentalis* from Wilderness, near George, in the Western Cape (Tyrone Ping, pers. comm.).

This also shows abnormal temporal scales. The normal temporal formula for this species is 2+2 but this example has 1+2+1 on the right and 1+2+2 on the left. Broadley (1966: 419) in the original description of *occidentalis* gives the temporal counts as “2 +2 (rarely 1 + 1, 1 + 2, 2 + 1 or 2 + 3)”. In the same paper, Broadley (1966: 418) gives the counts for *P. natalensis* as “temporals 2+2 (1+2+2 on one side of 1 snake; 2+1+2 on both sides of 1 snake)”.



Figure 17. Melanism in a *Philothamnus hoplogaster*.
(Photograph by Tyrone Ping)

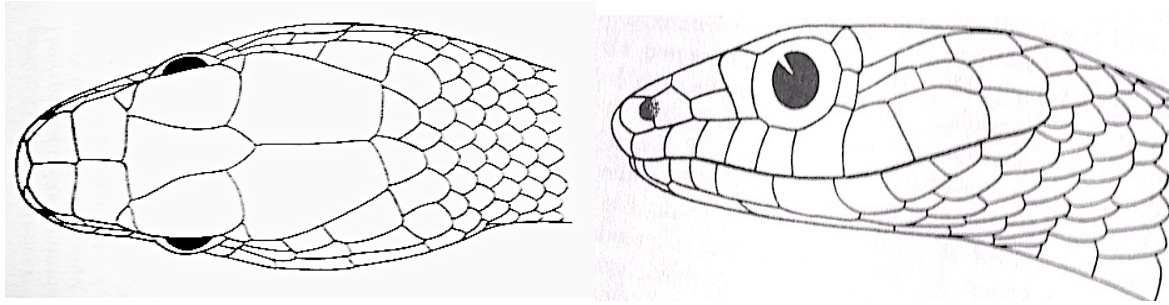


Figure 18. Melanism and aberrant shields on both sides of head in a *Philothamnus occidentalis*. (Photographs by Tyrone Ping)

A Zambian example of a melanistic Spotted Bush Snake (*P. semivariiegatus*) also showed odd head shields (an additional very small temporal behind the lower postocular and an enlarged (fused?) scale on the nape behind the parietals) is shown in Figure 19 below. The normal arrangement of the head shields is shown in Figure 20.



Figure 19. Melanistic Spotted Bush Snake showing extra temporal and enlarged scale behind parietals. (Photograph by Marcel van Driel)



**Figure 20. Normal arrangement of head shields in Spotted Bush Snakes.
(after FitzSimons, 1962)**

Xanthism

The Figure 21 shows an example of xanthism in a Variegated Slug-Eater (*Table*). In this case the eye remains dark while there is an overall yellowish colour. These aberrations are believed to be due to recessive mutations.



**Figure 21. Xanthic *Duberria variegata* from Mbazwane, KZN.
(Photographer David Maguire)**

ACKNOWLEDGEMENTS

The author is grateful for the kind assistance and cooperation of the following people: Eddie van Dijk took the X-ray radiograph; Gordon Setaro collected the *Pseudocordylus subviridis* and *Tropidosaura montana*; the late Robert Hurst collected the *Dendroaspis angusticeps*; Johan Marais provided the photograph of *Philothamnus occidentalis*; Marcel van Driel of the Zambian NGO Helping Hands in Snake Safety (HHISS) provided the photographs of *Philothamnus semivariatus*; David Maguire provided the photograph of the xanthic *Duberria variegata*; Chrisma Lotter provided the photograph of the amelanistic Cape Dwarf Gecko; a photographer who wishes to remain anonymous provided the photograph of the piebald Cape Wolf Snake and Tyrone Ping provided the photographs of the melanistic Western Green Snake and Green Water snake.

The Slangman photograph of an amelanistic Night Adder was downloaded on 2 July 2020 from <http://www.sareptiles.co.za/forum/viewtopic.php?f=154&t=10237> . The author took all the other photographs. I am grateful to David Bird for providing some of the references. Ortwin Bourquin, Harold DeLisle, Angelo Lambiris and Tyrone Ping kindly commented on earlier drafts of this article. I am grateful for the resulting improvements.

Table 1. Scientific Name and Authority

Scientific Name	Authority
<i>Acanthophis antarcticus</i>	(Shaw & Nodder, 1802)
<i>Amblyodipsas concolor</i>	(Smith, 1849)
<i>Bitis arietans</i>	(Merrem, 1820)
<i>Boaedon capensis</i>	Duméril, Bibron & Duméril 1854
<i>Causus rhombeatus</i>	(Lichtenstein, 1823)
<i>Crotalus atrox</i>	Baird & Girard, 1853
<i>Crotalus viridis</i>	(Rafinesque, 1818)
<i>Crotaphopeltis hotamboeia</i>	(Laurenti, 1768)
<i>Dendroaspis angusticeps</i>	(Smith, 1849)
<i>Duberria variegata</i>	(Peters, 1854)
<i>Eunectes notaeus</i>	Cope, 1862
<i>Lycophidion capense</i>	(Smith, 1831)
<i>Lygodactylus capensis</i>	(Smith, 1849)
<i>Macrelaps microlepidotus</i>	(Günther, 1860)
<i>Natrix maura</i>	(Linnaeus, 1758)
<i>Nerodia sipedon</i>	(Linnaeus, 1758)
<i>Pantherophis guttatus</i>	(Linnaeus, 1766)
<i>Philothamnus hoplogaster</i>	Günther, 1863
<i>Philothamnus occidentalis</i>	Broadley, 1966
<i>Philothamnus semivariatus</i>	(Smith, 1840)
<i>Pituophis melanoleucus catenifer</i>	(Blainville, 1835)
<i>Pseudocordylus subviridis</i>	(Smith, 1838)
<i>Python bivittatus</i>	(Kuhl, 1820)
<i>Python regius</i>	(Shaw, 1802)
<i>Stegonotus cucullatus</i>	(Duméril, Bibron & Duméril, 1854),
<i>Trachylepis striata</i>	(Peters, 1844)
<i>Tropidosaura montana natalensis</i>	Fitzsimons 1947

REFERENCES

- Bennett, A.F. & Licht, P. 1975.** Evaporative Water Loss in Scaleless Snakes. *Comparative Biochemistry and Physiology*, 52A: 213–215.
- Bourquin, O. 1970.** The Natal Purple-glossed Snake (*Choristocalamus concolor* A. Smith) – a new locality record. *Journal of the Herpetological Association of Africa*, 6: 10–11.
- Bourquin, O. 1988.** *Scelotes guentheri*: species account. pp. 105–106. In: Branch, WR. ed. South African Red Data Book - Reptiles and Amphibians. *South African National Scientific Programmes Report 151*.
- Branch, W.R. 1998.** *Field Guide to Snakes and Other Reptiles of Southern Africa*. 3rd Edition. Struik Publishers, Cape Town. 399pp.
- Broadley, D.G. 1975.** Dicephalism in African reptiles. *Journal of the Herpetological Association of Africa*, 13: 8–9.
- Broadley, D.G. 1983.** *FitzSimons' Snakes of Southern Africa*. Johannesburg, Delta Books. 376pp.
- Broadley, D.G. 1994.** The genus *Scelotes* Fitzinger (Reptilia: Scincidae) in Mozambique, Swaziland and Natal, South Africa. *Annals of the Natal Museum*, 35: 237–259. Scientific Reports.
- Brown, G.P., Madsen, T., Dubey, S. & Shine, R. 2017.** The causes and ecological correlates of head scale asymmetry and fragmentation in a tropical snake. *Scientific Reports* 7: 11363. DOI:10.1038/s41598-017-11768-y
- Duméril, A.M.C., Bibron, G. & Duméril, A. 1854.** *Erpétologie générale ou Histoire Naturelle complète des Reptiles*. Vol. 7 (partie 1). Paris, xvi + 780pp.
- FitzSimons, V.F.M. 1962.** *The Snakes of Southern Africa*. Cape Town, Purnell & Sons. 424pp.
- Galois, P. & Ouellet, M. 2007.** Health and disease in Canadian reptile populations. pp. 131–168. In: Seburn, C.N.L. & Bishop, C.A. editors. *Ecology, Conservation and Status of Reptiles in Canada*. *Herpetological Conservation*, Volume 2 Salt Lake City Society for the Study of Amphibians and Reptiles.
- Hu, D. & Helms, J.A. 1999.** The role of sonic hedgehog in normal and abnormal craniofacial morphogenesis. *Development* 126: 4873–4884.
- Kim, I.-H., Kim, J.-K. Fong, J.J. & Park, D. 2013.** Report of a Dicephalic Steppes Ratsnake (*Elaphe dione*) Collected in South Korea. *Asian Herpetological Research* 2013, 4(3): 182–186.
- Licht, P. & Bennett, A.F. 1972.** A Scaleless Snake: Tests of the role of Reptilian Scales in Water Loss and Heat Transfer. *Copeia* 1972 (4): 702–707.
- Mahabal, A. & Thakur, S. 2014.** Instances of aberrant colors and patterns among the Indian herpetofauna: a review. *Russian Journal of Herpetology*, 21 (2): 80–88.
- Pendlebury, G.B. 1976.** Congenital defects in the brood of a prairie rattlesnake. *Canadian Journal of Zoology*, 54, 2023–2025.
- Raw, L.R.G. 1971.** Another New Locality for *Choristocalamus concolor* in Natal. *Journal of the Herpetological Association of Africa*, 7: 41–42.
- Raw, L.R.G. 1973.** *Scelotes guentheri* Boulenger rediscovered? *Journal of the Herpetological Association of Africa*, 10: 11–12.
- Riches, R.J. 1967.** Notes on a clutch of eggs of the viperine snake (*Natrix maura*). *British Journal of Herpetology*, 4, 14–16.
- Sant'Anna, S.S., Grego, K.F., Lorigados, C.A.B., Fonseca-Pinto, A.C.B.C., Fernandes, W., Sá Rocha, L.C. & Catão-Dias J.L. 2013.** Malformations in Neotropical Viperids: Qualitative and Quantitative Analysis. *Journal of Comparative Pathology*, 149, (4), 503–508.

- Spadola, F. & Insacco, G. 2009.** Newborn dicephalic *Podarcis sicula*. *Acta Herpetologica*, 4: 99–101.
- Toni, M. & Alibardi, L. 2007.** Soft epidermis of a scaleless snake lacks beta-keratin. *European Journal of Histochemistry*, 51 (2) (Apr-Jun): 145–151.
- Wallach, V. 2007.** Axial bifurcation and duplication in snakes, Part I, A synopsis of authentic and anecdotal cases. *Bulletin of the Maryland Herpetological Society*, 43: 57–95.
- Zehr, D.R. 1962.** Stages in the Normal Development of the Common Garter Snake, *Thamnophis sirtalis sirtalis*. *Copeia* 1962, 2: 322-329.

Accepted for publication: 8 March 2021