



CODEN [USA]: IAJPBB

ISSN : 2349-7750

**INDO AMERICAN JOURNAL OF
PHARMACEUTICAL SCIENCES**

SJIF Impact Factor: 7.187

Available online at: <http://www.iajps.com>

A Case Report

**ENDOSCOPIC THIRD VENTRICULOSTOMY IN
OBSTRUCTIVE HYDROCEPHALUS: A CASE REPORT****¹Dr. Azra Alimein and ²Dr. Rohit Khurana**¹Department of Trauma Care Unit, R G Kar Medical College and Hospital, Kolkata,
West Bengal²Department of Neurosurgery, R G Kar Medical College and Hospital, Kolkata, West Bengal**Article Received:** January 2020**Accepted:** January 2021**Published:** February 2021**Abstract:**

The endoscopic third ventriculostomy (ETV) is a neuroendoscopic procedure that represents a more suitable alternative to the extracranial shunting in obstructive hydrocephalus. It consists of fenestrating the floor of the third ventricle and thus establishing a free flow of the cerebrospinal fluid from the ventricles to the site of resorption in the subarachnoid space. It offers a more physiological solution and a chance at a shunt-free life for patients with hydrocephalus. The main indication for the procedure is obstructive hydrocephalus, however, it can also be useful in patients with other forms of hydrocephalus.

Case Summary:

We present a treatment flow of a 20-year-old patient, diagnosed with an obstructive hydrocephalus due to supratentorial obstructing ventriculomegaly due to an intraventricular lesion that was successfully treated with an ETV.

Keywords:

Endoscopic third ventriculostomy, Obstructive hydrocephalus, Aqueductal stenosis

Corresponding author:**Dr. Azra Alimein,**

Department of Trauma Care Unit,

R G Kar Medical College And Hospital, Kolkata, West Bengal

QR code



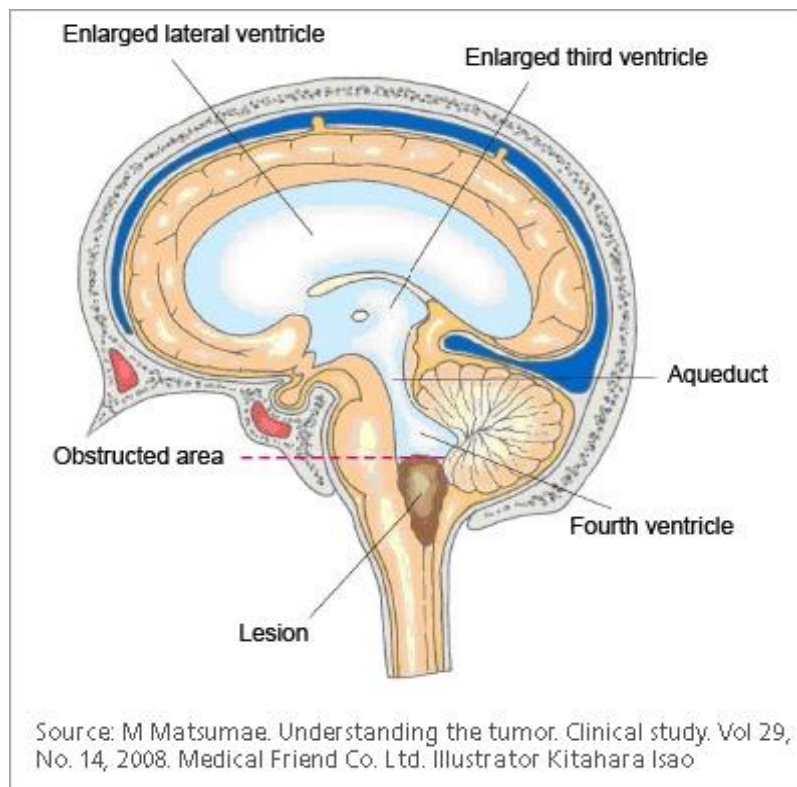
Please cite this article in press Azra Alimein et al, *Sexually Transmitted Infections In Sexually Abused Children., Indo Am. J. P. Sci, 2021; 08(02).*

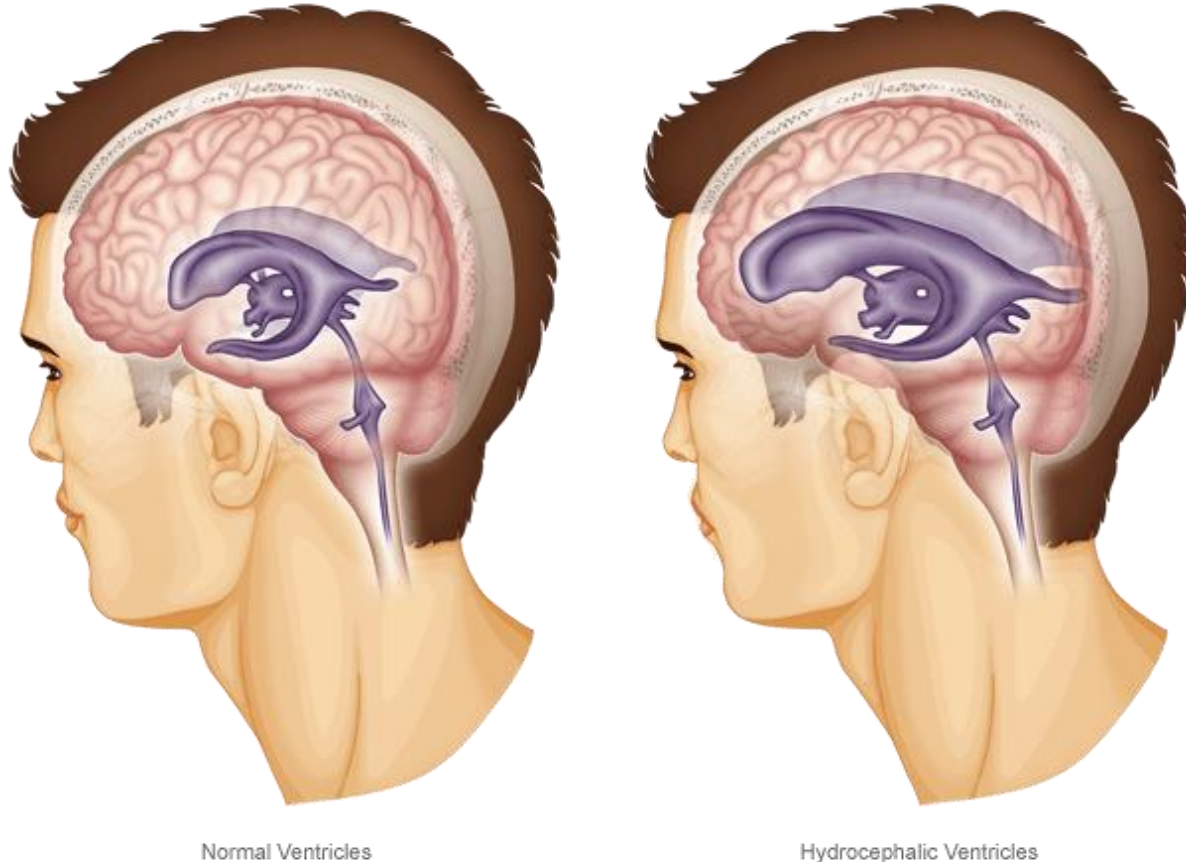
INTRODUCTION:

Hydrocephalus is a disorder of cerebrospinal fluid (CSF) physiology, resulting in an abnormal enlargement of brain ventricles due to excessive accumulation of CSF. The main causes are disturbance of CSF flow, subnormal resorption or, rarely, overproduction [1]. Hydrocephalus when occurs as a causal complication of another condition (haemorrhage, infection, tumour) it is called acquired or secondary. The most common site of this blockage is at the cerebral aqueduct, called aqueductal stenosis. Though this occurs more commonly in children, it can present in adulthood. Other locations of blockage can occur at the third or fourth ventricles. Patients can have progressive symptoms of headaches, memory difficulties, blurred vision, double vision and/or imbalance. Most commonly, people are born with such blockages, though patients can acquire these from infection or trauma.

Regarding the pathophysiological mechanism, we differentiate between obstructive and communicating hydrocephalus. Classically, the obstruction of the CSF flow within the ventricles is classified as obstructive or non-communicating hydrocephalus, whereas the obstruction of the CSF flow or its absorption in the

subarachnoid spaces is known as communicating hydrocephalus. Main causes include defective absorption, overproduction of the CSF or venous drainage insufficiency. In the acute form of obstructive hydrocephalus, especially in young patients, only minor ventriculomegaly may be present in spite of a significant rise in the intracranial pressure. With long standing CSF pressure on the brain parenchyma, the ventricular system dilates, compressing and thinning the overlying cortex. The primary point of obstruction in a non-communicating hydrocephalus may be proximal (at the level of the third ventricle or the aqueduct) or distal (at the level of the fourth ventricle, fourth ventricular outflow tracts or the foramen magnum). The most common causes for obstruction in the ventricular system are occlusion of cerebral aqueduct, tumours and colloid cysts. In cases of communicating hydrocephalus, the source of obstruction can reside in the basal cisterns or there can be a failure of CSF absorption through the arachnoid granulations. That is most often due to infections or subarachnoid haemorrhage. Some of congenital malformations with more complex mechanisms of hydrocephalus have both obstructive and communicating components.





Normal Ventricles

Hydrocephalic Ventricles

© Sophysa – Illustration: Philippe Plateaux

Symptoms of hydrocephalus are nonspecific and may not be related to aetiology. They are caused by raised intracranial pressure. Some infants and children with mild hydrocephalus may be asymptomatic. A classical adult presentation of raised ICP includes headache, vomiting and papilloedema, and the same clinical picture can be seen in children.

The best diagnostic technique for covering all of the imaging demands for hydrocephalus is magnetic resonance imaging (MRI). Not only it gives a detailed anatomical information, it may also show the CSF flow dynamics that demonstrates the site of obstruction. It can help us discover the underlying cause for hydrocephalus as it shows most of the intra-axial and extra-axial space occupying lesions. Important for surgery planning is also careful examination of the CSF pathways from the ventricles to the subarachnoid space with its CSF flow.

The most effective treatment is surgical drainage, which can be done by diverting the excess CSF extracranially (via shunts) or by redirecting the CSF flow to a more physiological site of resorption within

the brain system (ventriculostomy). Whereas the extracranial CSF diversion (shunt) has traditionally been the treatment for a communicating hydrocephalus, the endoscopic procedures have become the optimal treatment for purely obstructive type of hydrocephalus.

Since the 1990s, the endoscopic third ventriculostomy (ETV) has been the first-line procedure in treating the non-communicating hydrocephalus. The ETV is a surgical procedure, which encompasses the fenestration of the third ventricular floor with a ventriculoscope and it is often assisted with image guidance. The goal of the procedure is to divert the CSF flow to a more physiological site of resorption. That is achieved by establishing a free flow of the CSF from third ventricle into the interpeduncular cistern and onwards to the cortical subarachnoid space, where it is absorbed by the arachnoid villi. The CSF is thus diverted elsewhere in an attempt to bypass an obstruction and to relieve intracranial pressure. Compared to the VP shunt, the ETV represents a more physiological solution for hydrocephalus. It eliminates shunt-related complications and dependency, does not

involve the insertion of foreign material and overall has lower complication rates. In this report, we present a treatment flow of a 20-year-old boy, who was diagnosed with an obstructive hydrocephalus and has been successfully treated with the ETV.

CASE REPORT:

Chief complaints

A 20-year-old male patient was admitted in medicine department with complaint of dizziness, convulsions and occipital headache that had been getting worse in the weeks preceding the hospitalization.

History of Present Illness

The headache was the main symptom, it was ongoing and had been getting worse in the past weeks. The headache started six months prior to the visit with a frequency of one per month, then escalated to one per week and has been present every day in the last week. He described it as a dull non-spreading pain in the occipital region, with an intensity of 5/10. The episodes, which started a year back, lasted five to 15 minutes and usually disappeared after a short rest and since last six months it increased gradually exacerbating recently. He had no need for analgesics. Several times, he was also woken up during the night by the headaches and vomiting. He denied any history of nausea, flashing of light or scotoma. He also gave a history of of paresis of all the limbs 4 months back. There is a history of road traffic accident 5 years back which lead to head trauma but no hospitalization. There is also a history of fall from stairs 2 years back after feeling dizzy leading to unconsciousness.

History of Past Illness

The patient had no history of other illness. He had no known allergies.

Physical examination upon admission

At the admission, the physical examination was within normal limits except tremor and nail pitting was present. The neurological examination was within normal limits.

Laboratory examinations

Laboratory examinations were within the normal range. The haemostasis was normal, as was the blood count and the biochemistry test. The routine laboratory results were normal.

Imaging examinations

The MRI substantiated the diagnosis by showing hypointensive in the region of 4th ventricle and adjacent aqueduct with associated mild adjacent perifocal oedema which is highly suggestive of intraventricular ependymoma. It was obstructing aqueduct of Sylvius, causing extensive supratentorial obstructing ventriculomegaly with some reliable findings, such as enlarged third ventricle that was bulging into the sella tursica. Additionally, the periventricular hyperintensive area, effacement of cortical sulci, dilatation of lateral ventricles and intracranial hypertension with important narrowing of transverse sinuses were observed. There were no signs of a hyperdynamic CSF circulation on the MRI at the level of the aqueduct, suggesting a complete flow blockade by the tumour.

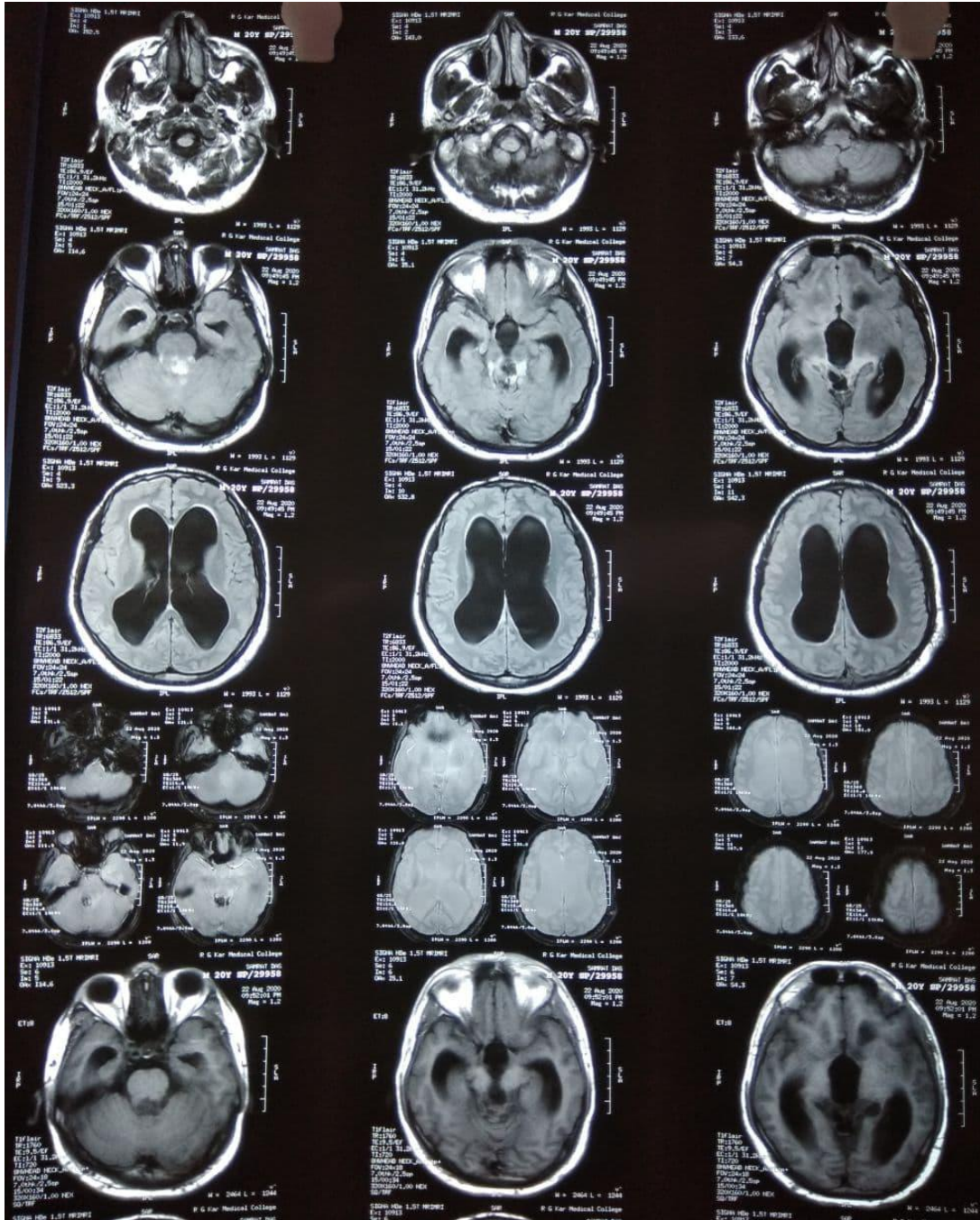


FIG-1

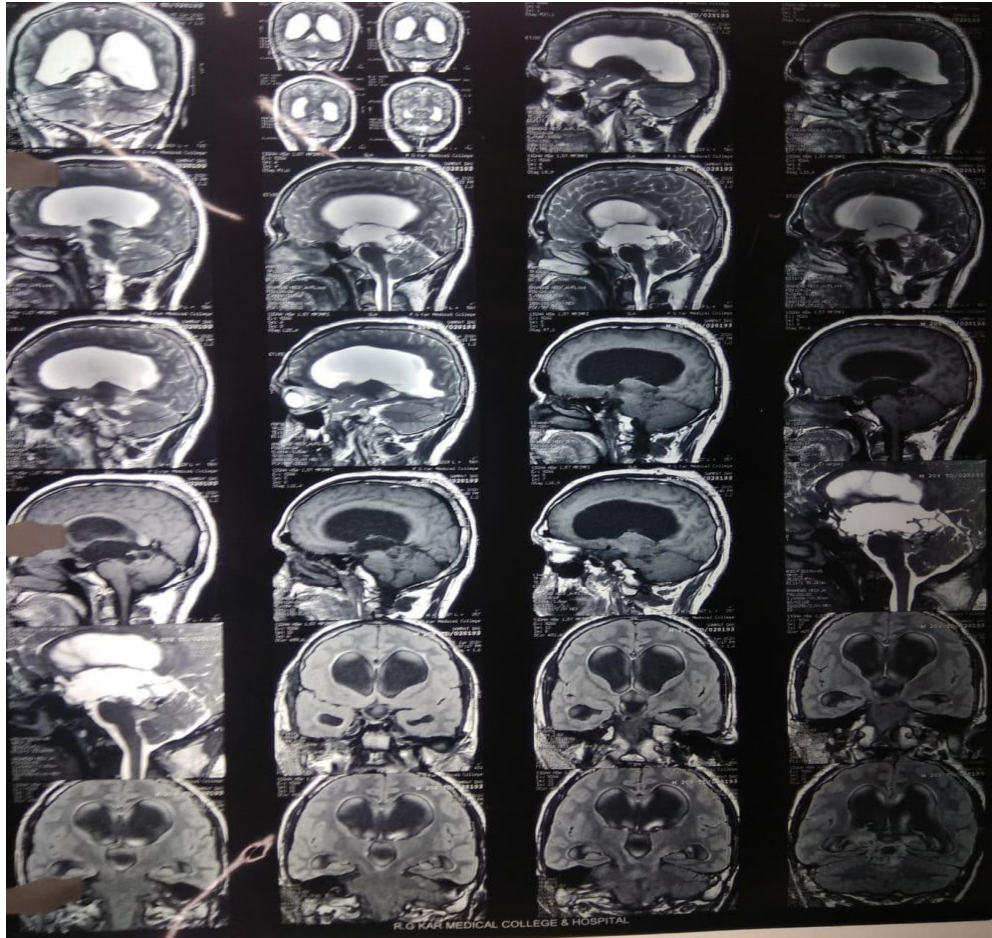


FIG-2

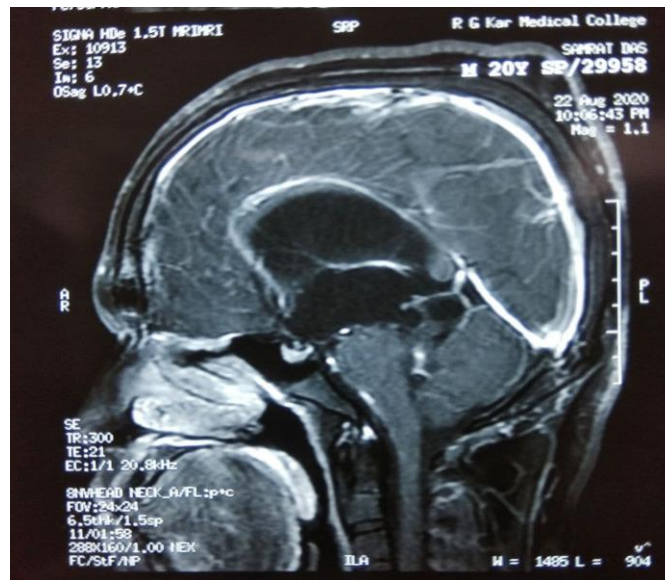


FIG.3

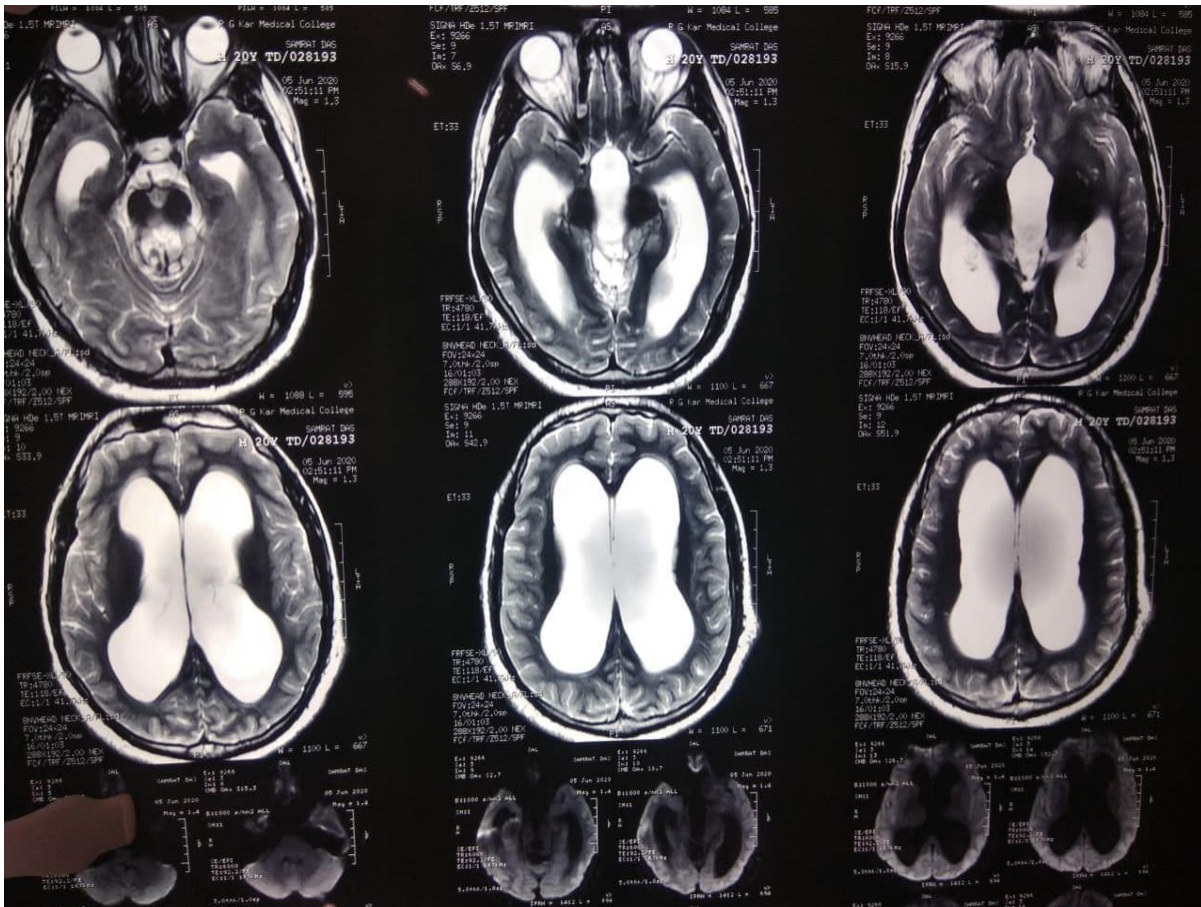


FIG.4

The T2-phases flair of the magnetic resonance imaging (sagittal, coronal and axial views) revealing a tumor in the region of 4th ventricle obstructing the aqueduct of Sylvius and causing extensive hydrocephalus. The third ventricle is bulging into the sella tursica. The tumor has not been progressing. The supratentorial ventricles are narrower.

Final diagnosis

The clinical symptoms and the final diagnosis were consistent with the diagnostic results. The main diagnosis results of obstructive hydrocephalus has been set.

Treatment

According to the MRI findings and clinical symptoms of raised intracranial pressure (headache, papilledema), neurosurgical treatment was recommended. Since the diagnosis of the obstruction unambiguous, it was decided to perform an ETV in order to relieve the symptoms of the obstructive hydrocephalus. The lumbar puncture was not performed in advance as it was contraindicated due to the risk of possible herniation after the CSF removal

and consequent neurological deterioration. The CSF sample collection was planned for the surgical stage of treatment.

In endoscopic third ventriculostomy, a small perforation is made in the thinned floor of the third ventricle, allowing movement of cerebrospinal fluid (CSF) out of the blocked ventricular system and into the interpenduncular cistern (a normal CSF space). Cerebrospinal fluid within the ventricle is thus diverted elsewhere in an attempt to bypass an obstruction in the aqueduct of Sylvius and thereby relieve pressure. The objective of this procedure, called an “intracranial CSF diversion,” is to normalize pressure on the brain without using a shunt. Endoscopic third ventriculostomy is not a cure for hydrocephalus, but rather an alternate treatment. The ultimate goal of endoscopic third ventriculostomy is to render a shunt unnecessary. Although endoscopic third ventriculostomy is ideally a one-time procedure, evidence suggests that some patients will require more than one surgery to maintain adequate opening and drainage.

The rest of the hospitalization was uneventful and the boy was discharged home after two days. In the following weeks, the patient was again hospitalized two more times for follow up without any episode of headache, nausea and vomiting. His physical and neurological examination were normal. Even though the CT showed smaller ventricles compared to the postoperative scans, there were no signs of hydrocephalus progression.

DISCUSSION:

The ETV is one of most commonly used neuroendoscopic procedures. It was primarily designed for use in patients older than two years with the blockage of aqueduct of Sylvius that presented with triventricular hydrocephalus, and those with bulging of the floor of the third ventricle. Over the past two decades, it has become a well-established procedure worldwide, not only for patients with purely obstructive aetiology but also for communicating and even normal pressure hydrocephalus. Indications for patients with normal pressure or communicating hydrocephalus have not been defined precisely and the basis of successful outcome is not yet clear. Some authors predict that the ETV might relieve periventricular tissue stress and improve blood flow, which is a hypothetical pathogenetically mechanism in normal pressure hydrocephalus. The main and most common indication for the ETV still remains the noncommunicating hydrocephalus caused by aqueductal stenosis, which may be idiopathic or secondary and congenital or acquired (late onset). Additionally, there are numerous other indications for the ETV, which may be somewhat subjective, offering the patient a chance at a shunt free life.

CONCLUSION:

The ETV effectively controls obstructive hydrocephalus in more than 75% of all cases and should be preferred to extracranial shunts as a primary treatment. The most important factor in the success of the procedure is the correct preoperative selection of patients. Additionally, as the success of the ETV is closely related to the knowledge of the third ventricle anatomical landmarks, special care should be dedicated to the anatomic localisation of the structures and possible peculiarities in this region.

Footnotes

Informed consent statement: Patient signed the informed consent.

Conflict-of-interest statement: The authors declare that they have no conflict of interest.

Manuscript source: Invited manuscript
Specialty type: Neurosurgery, research and experimental

REFERENCES:

1. Beni-Adani L, Biani N, Ben-Sirah L, Constantini S. The occurrence of obstructive vs absorptive hydrocephalus in newborns and infants: relevance to treatment choices. *Childs Nerv Syst.* 2006; 22:1543–1563. [[PubMed](#)] [[Google Scholar](#)]
2. Isaacs AM, Riva-Cambrin J, Yavin D, Hockley A, Pringsheim TM, Jette N, Lethembe BC, Lowerison M, Dronyk J, Hamilton MG. Age-specific global epidemiology of hydrocephalus: Systematic review, metanalysis and global birth surveillance. *PLoS One.* 2018;13:e0204926. [[PMC free article](#)] [[PubMed](#)] [[Google Scholar](#)]
3. Sakka L, Coll G, Chazal J. Anatomy and physiology of cerebrospinal fluid. *Eur Ann Otorhinolaryngol Head Neck Dis.* 2011;128:309–316. [[PubMed](#)] [[Google Scholar](#)]
4. Filis AK, Aghayev K, Vrionis FD. Cerebrospinal Fluid and Hydrocephalus: Physiology, Diagnosis, and Treatment. *Cancer Control.* 2017;24:6–8. [[PubMed](#)] [[Google Scholar](#)]
5. Rochette A, Malenfant Rancourt MP, Sola C, Prodhomme O, Saguintaah M, Schaub R, Molinari N, Capdevila X, Dadure C. Cerebrospinal fluid volume in neonates undergoing spinal anaesthesia: a descriptive magnetic resonance imaging study. *Br J Anaesth.* 2016; 117:214–219. [[PubMed](#)] [[Google Scholar](#)]
6. Tully HM, Dobyms WB. Infantile hydrocephalus: a review of epidemiology, classification and causes. *Eur J Med Genet.* 2014; 57: 359–368. [[PMC free article](#)] [[PubMed](#)] [[Google Scholar](#)]
7. Dinçer A, Özek MM. Radiologic evaluation of pediatric hydrocephalus. *Childs Nerv Syst.* 2011; 27:1543–1562. [[PubMed](#)] [[Google Scholar](#)]
8. Melot A, Curey-Lévêque S, Derrey S, Gérardin E, Borden A, Fréger P, Proust F. Endoscopic 3rd ventriculocisternostomy: procedural complications and long-term dysfunctions? *Neurochirurgie.* 2013; 59: 165–170. [[PubMed](#)] [[Google Scholar](#)]
9. Cataltepe O. Endoscopic third ventriculostomy: Indications, Surgical Technique and Potential Problems. *Turk Neurosurg.* 2002; 12:65–73. [[Google Scholar](#)]
10. Hellwig D, Grotenhuis JA, Tirakotai W, Riegel T, Schulte DM, Bauer BL, Bertalanffy H. Endoscopic third ventriculostomy for obstructive

- hydrocephalus. *Neurosurg Rev.* 2005; 28:1–34; discussion 35-8. [[PubMed](#)] [[Google Scholar](#)]
11. Feng Z, Li Q, Gu J, Shen W. Update on Endoscopic Third Ventriculostomy in Children. *Pediatr Neurosurg.* 2018; 53:367–370. [[PubMed](#)] [[Google Scholar](#)]
 12. Mugamba J, Stagno V. Indication for endoscopic third ventriculostomy. *World Neurosurg.* 2013; 79: S20.e19–S20.e23. [[PubMed](#)] [[Google Scholar](#)]
 13. Kahle KT, Kulkarni AV, Limbrick DD, Jr, Warf BC. Hydrocephalus in children. *Lancet.* 2016; 387:788–799. [[PubMed](#)] [[Google Scholar](#)]
 14. Kulkarni AV, Riva-Cambrin J, Holubkov R, Browd SR, Cochrane DD, Drake JM, Limbrick DD, Rozzelle CJ, Simon TD, Tamber MS, Wellons JC, 3rd, Whitehead WE, Kestle JR Hydrocephalus Clinical Research Network. Endoscopic third ventriculostomy in children: prospective, multicenter results from the Hydrocephalus Clinical Research Network. *J Neurosurg Pediatr.* 2016; 18:423–429. [[PubMed](#)] [[Google Scholar](#)]
 15. Buxton N, Turner B, Ramli N, Vloeberghs M. Changes in third ventricular size with neuroendoscopic third ventriculostomy: a blinded study. *J Neurol Neurosurg Psychiatry.* 2002;72: 385–387. [[PMC free article](#)] [[PubMed](#)] [[Google Scholar](#)]
 16. Kulkarni AV, Riva-Cambrin J, Browd SR. Use of the ETV Success Score to explain the variation in reported endoscopic third ventriculostomy success rates among published case series of childhood hydrocephalus. *J Neurosurg Pediatr.* 2011; 7: 143–146. [[PubMed](#)] [[Google Scholar](#)]
 17. Kulkarni AV, Drake JM, Kestle JR, Mallucci CL, Sgouros S, Constantini S Canadian Pediatric Neurosurgery Study Group. Predicting who will benefit from endoscopic third ventriculostomy compared with shunt insertion in childhood hydrocephalus using the ETV Success Score. *J Neurosurg Pediatr.* 2010; 6: 310–315. [[PubMed](#)] [[Google Scholar](#)]
 18. Rohde V, Gilsbach JM. Anomalies and variants of the endoscopic anatomy for third ventriculostomy. *Minim Invasive Neurosurg.* 2000; 43:111–117. [[PubMed](#)] [[Google Scholar](#)]