

ORIGINAL ARTICLE

Giant dermatofibrosarcoma protuberans vulvae: rare clinical presentation and literature review

Jelena Jeremic^{1,2}, Aleksandar Stefanovic^{2,3}, Katarina Jeremic^{2,3}, Marko Jovic^{1,2}, Igor Pilic³, Ana Cvetkovic⁴, Marina Stojanovic^{1,2}

¹Clinic for Burns, Plastic and Reconstructive Surgery, Clinical Center of Serbia, Belgrade, Serbia; ²School of Medicine, University of Belgrade, Belgrade, Serbia; ³Clinic for Obstetrics and Gynecology, Clinical Center of Serbia, Belgrade, Serbia; ⁴Institute for Oncology and Radiology of Serbia, Belgrade, Serbia.

Summary

Dermatofibrosarcoma protuberans (DFSP) is a rare, slow-growing fibro-cutaneous tumor of low to intermediate grade malignancy. It is characterized by local dermal and subcutaneous infiltration, but also with destructive infiltration of the surrounding tissues (muscle, fascia, and bone). The size of the tumor varies from small nodular to large neglected masses. Males and females are equally affected. The tumor is most often localized in the trunk and the proximal extremities. At a molecular level, more than 90% of all DFSP arise from the translocation of chromosomes 17 and 22. Clinically, it usually occurs in the form of flesh-colored or slightly yellow-brown skin tumor, irregular borders or multinodular appearance. The definitive diagnosis of DFSP is made by biopsy in combination with histological morphology and immunohistochemistry. The standard treatment for DFSP is surgical resection. Radiation treatment is an option for

primary inoperable tumors and prior multiple recurrences. There is no consensus about chemotherapy regimens. Imatinib - a tyrosine kinase inhibitor - is approved in Europe for the treatment of inoperable primary tumors, locally inoperable recurrent disease, and metastatic DFSP. The recommended dose is 400–600 mg/daily.

DFSP of the vulva is extremely rare, with less than 60 cases reported in the literature. Tumor behavior of DFSP of the vulva does not differ from other DFSP localizations. Spontaneous regressions are common while distant metastases are rare. Multidisciplinary approach requiring wide resection, margin assessment and reconstruction is the therapy of choice.

Key words: dermatofibrosarcoma, skin tumor, surgical treatment, therapy, vulva

Introduction

Dermatofibrosarcoma protuberans (DFSP) is a rare, slow-growing cutaneous tumor of fibroblastic origin first described in 1925 by Hoffmann [1]. Clinically, it is characterized by local dermal and subcutaneous infiltration, but also with destructive infiltration of the surrounding tissues (muscle, fascia, and bone). It rarely metastasizes with less than 5% of all patients developing distant metastases [2-6]. DFSP metastasizes haematogenously to the lung

(75%), while 25% develop regional lymph nodes metastasis. Metastases to brain, bones and heart are less common [7]. It was noted that increased cellularity and over 8 mitoses per 10 high-power fields (HPF) are associated with predisposition to metastasis. The most common way of infiltrating the subcutaneous tissue is a lacelike form-tumor cells around small groups of fat cells [8], or in the form of bundles parallel to the epidermis [9].

Corresponding author: Marina Stojanovic, MD, PhD. Clinic for Burns, Plastic and Reconstructive Surgery, Clinical Center of Serbia, Belgrade, Zvecanska 9, 11000 Belgrade, Serbia.
Tel: +381 641932758, Email: marinailicstojanovic@gmail.com
Received: 15/09/2018; Accepted: 21/10/2018

Epidemiology

An estimated incidence of DFSP is 3-5 cases per million persons [10,11]. Males and females are equally affected. This type of tumor most commonly affects young and middle aged people, predominately in their fourth decade. The tumor is most often localized in the trunk and the proximal extremities [12], but it can also occur elsewhere.

Molecular basis and clinical presentation

There are several histological subtypes of DFSP. Usually are low-grade lesions. However, 10% contain fibrosarcomatous components (FS-DFSP), which are more aggressive and have higher rate of local recurrences and metastases [13,14]. The characteristic of this form is loss of CD34 positivity and p53 overexpression (60-92%). DFSP is positive for vimentin, CD99 and CD34 but negative for FXIIIa [15]. Compared to 0-3 mitoses per 10 high-power fields (HPF) in the DFSP component, the sarcomatous component has 2-16 mitoses per 10 HPF [3]. The Bednar or pigmented variant, with melanin-containing cells is another infrequent form of DFSP.

At a molecular level, more than 90% of all DFSP arise from the translocation of chromosomes 17 and 22, resulting in a fusion between the collagen type Ia1 gene (COL1A1) and the platelet-derived growth factor β -chain gene (PDGFB) [16,17]. This rearrangement causes a continuous activation of platelet-derived growth factor receptor β (PDGFR β) protein tyrosine kinase, which promotes DFSP cell growth.

It is reported that an earlier trauma may be a possible etiological factor of DFSP. There are data on the association between tumors and previous scars, burns, vaccination scars, radiodermatitis, as well as tattoo [18,19].

Diagnosis and differential diagnosis

The diagnosis of this tumor is based on skin changes like flesh-colored or slightly yellow-brown skin tumor, irregular borders or multinodular appearance. It is very difficult to diagnose the tumor at the onset, due to absence of specific characteristics. Two groups of authors classified 3 different forms of non-protruding DFSP: morphea-like, atrophoderma-like and angioma-like [20,21]. Clinical suspicion must be pathologically confirmed before definitive surgery is performed. The definitive diagnosis of DFSP is made by incisional or less frequently excisional biopsy in combination with histological morphology and immunohistochemistry. The differential diagnosis is problematic because it is difficult to distinguish DFSP from other

fibrohistiocytic neoplasms, like fibrous histiocytoma, leiomyosarcoma, rare variants of spindle-cell malignant melanoma and benign neural tumors. Fluorescence in situ hybridization (FISH) or multiplex reverse transcriptase-polymerase chain reaction (RT-PCR) are useful tools to confirm a difficult DFSP diagnosis.

Staging

According to the American Musculoskeletal Tumor Society (MSTS) staging system, there are two stage of DFSP [22]. Stage IA: Low grade DFSP with no extension beyond the subcutaneous compartment which can be managed by a wide excision. Stage IB: Low grade DFSP with extension outside of an anatomic compartment, with involvement of underlying fascia or muscle.

Therapy

The standard treatment for DFSP is surgical resection. It is important to remove DFSP completely, with deep fascia excision to remove any infiltrating tumor cells. Incomplete excisions are relatively common, especially in "whoops" procedures. Local recurrences after surgical excision are relatively heterogeneous, ranging from 0 to 57% [4,6]. The most commonly mentioned surgical techniques are wide local excision (WLE), Mohs micrographic surgery (MMS) and surgery followed by three-dimensional complete circumferential and peripheral deep margin assessment (CCPDMA). The European Association of Dermato-Oncology (EADO) as well as the European Organization of Research and Treatment of Cancer (EORTC) recommend MMS as a treatment of choice of DFSP, because local recurrence rates after MMS (0-1.1%) are significantly lower than those for wide local excisions (WLE) (0-27%) [3, 5, 6, 11, 23-32]. The MMS technique implies an intraoperative overview of margins, and thus saves tissue. This technique is also desirable in situations where it is not desirable or it is not possible to exceed most of the tissue. DuBay et al. reported a 0% recurrence rate in 42 patients after a 4-year follow-up by using Mohs technique [23]. The disadvantages of MMS are that it is a technically demanding procedure, is time-consuming, and some authors have suggested that it is unreliable in detecting negative margins. However, WLE with a lateral safety margin of 2-5 cm, mostly 3 cm was advised in treatment centers where only standard histopathological procedures are available [32]. CCPDMA technique involves resection of tumors with margins that are less than 3 cm. The sample is then examined pathologically and in certain suspected situations it is supplemented by immunohistochemical analysis.

Chemotherapy and radiotherapy

In some circumstances, complete surgical removal of the tumor may not be possible. Local recurrence in the laying of positive surgical margins is still a burning problem. In such a situation, radiotherapy may be one of the therapeutic options. Radiation treatment is an option for primary inoperable tumors and prior multiple recurrences. An individual dose of 2 Gy 5 per week, and a total dose of 60 Gy (microscopic tumor) to 70 Gy (macroscopic tumor) may be given [32]. Uysal et al. investigated role of radiotherapy in the management of dermatofibrosarcoma protuberans. They included 28 patients of which 3 patients received definitive RT alone (patients were not liable to surgery due to critical tumor localization and comorbidities). They applied RT in dose of 63.21 ± 3.7 Gy (range 50-70) in 25-35 fractions. The size of tumor was 5.2 cm (range 2.1-8.4) and patients were followed up for a median of 80 months (24-120). Local recurrence occurred in 3 patients, 2 of them died of pulmonary metastases. Survival rates were statistically significant higher in wide excision+RT groups vs. limited excision+RT groups ($p < 0.05$) [33]. In circumstances with complete resection but with close surgical margins, there is no evidence of possible benefit of radiotherapy. Some authors point out that in such situations it is better to apply wide reexcision. On the other hand, there is evidence that RT may improve treatment outcomes in patients with close surgical margins.

There is no consensus about chemotherapy regimens. In the literature, the following combinations of drugs in the treatment are used: (1) low-dose methotrexate and weekly vinblastine [15], vincristine, actinomycin, and cyclophosphamide [32] and ifosfamide + Mesna, and liposomal doxorubicin [34].

Molecular therapy

From 2006, imatinib mesylate (Gleevec) is approved as a single agent for the treatment of DFSP, by U.S. Food and Drug Administration (FDA). Gleevec is indicated for the treatment of adult patients with unresectable, recurrent and/or metastatic DFSP. Recommended dose is 800 mg/day [35]. Imatinib (Glivec), a tyrosine kinase-inhibitor, is also approved in Europe for the treatment of inoperable primary tumors, locally inoperable recurrent disease, and metastatic DFSP. The recommended dose is 400–600 mg/daily [34]. Imatinib acts by blocking auto-phosphorylation of tyrosine kinases, thereby decreasing animate activity in DFSP cells and preventing their ability to propagate and grow. McArthur et al. [36] analyzed radiologic and clinical response to imatinib at 400 mg twice daily in eight patients with locally advanced DFSP and two patients with metastatic disease. They found that each of eight patients with locally advanced DFSP showed a clinical response to imatinib and four of these patients had complete clinical responses. The two patients with metastatic disease had fibrosarcomatous histology, one with no clinical response and the other had a partial response to imatinib but experienced disease progression after 7 months of therapy. It is suggested that imatinib therapy could start at a lower dose 400mg/day and, in case of no response, increase the dose to 400mg/twice a day [34]. The possible adverse events of imatinib therapy are: fluid retention/edema, anemia, fatigue, nausea, vomiting, skin toxicity, thrombocytopenia, neutropenia and diarrhea.

Case presentation

A 55-year-old (secundipara) woman was referred to the Clinic for Gynaecology and Obstet-

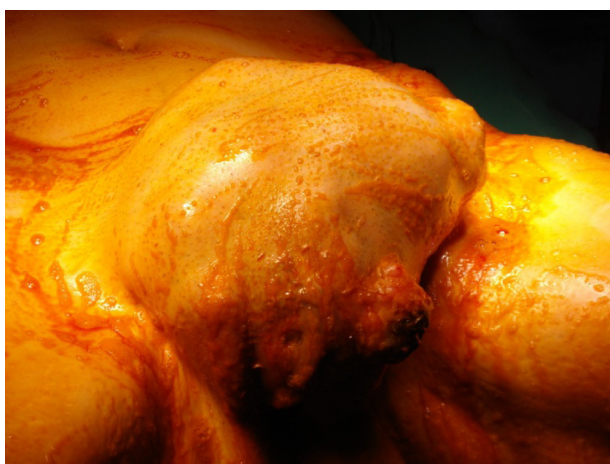

Figure 1. Clinical aspect of the DFSP of the vulva before surgery.

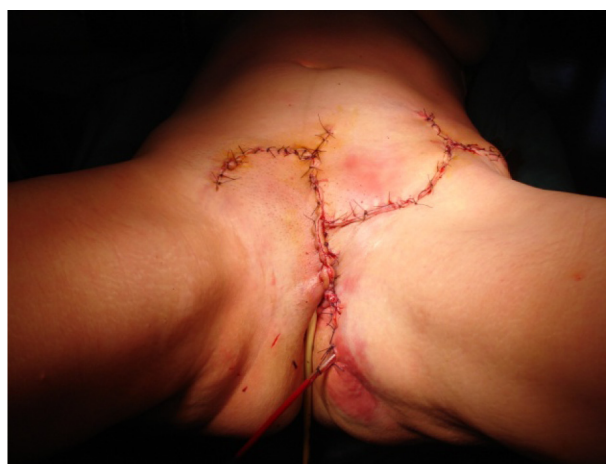

Figure 2. Postoperative view of soft tissue defect reconstruction with fasciocutaneous flaps.

rics due to a huge vulvar tumor that existed in 19 years. During this period the lesion was growing slowly. The patient had no miction or defecation problems. After the biopsy of the lesion histologic examination revealed DFSP.

Clinical examination revealed a neglected, huge non-tender nodular lesion 18x10x8 cm of solid texture, with ulceration of the vulva, located on the point of the biopsy. The tumor was located over the mons pubis, clitoris and upper half of the labia majora (Figure 1).

Preoperatively, the patient was examined by the team of gynecologist, oncologist, urologist, radiologist and plastic surgeon.

The MSCT (multi sliced computed tomography) of the abdomen and pelvis revealed the solid texture lesion dimensions 16x8.5x6 cm, located in the prepubic area, and without involvement of bone structures. There was no inguinal lymphadenopathy. The internal genitalia were clinically normal, and Pap smear revealed no abnormalities. The laboratory analyses were of normal findings. The chest x ray and abdomen/pelvis ultrasound revealed no evidence of metastasis.

The patient underwent radical tumor excision followed by soft tissue defect reconstruction. The excision was wide with margins of 3 cm of normal skin. The incision was made deep to the periosteum of pubic bone and deep muscle fascia of the anterior abdominal wall, with deliberation of the urethra 3 cm in length. The resection continued laterally to the inguinal region, with the excision of the infiltrated fascia and resection of mm.pyramidales (Figures 2-3). Pathological studies revealed free margins and reconstructive surgery was performed. The soft tissue defect was reconstructed with fasciocutaneous transposition flaps raised from the left side of the belly (Figure 4). The postoperative course went uneventful.

After the procedure, the histopathological findings were not helpful to decide the type of malignant mesenchymal tumor, or sarcoma. The immunohistochemistry performed was strongly positive for CD34 (Figure 5). There was no immunoreactivity for desmin, aktin, SMA alfa, CD 117, S 100 protein. The proliferative status was 45% Ki-67, and p53 60%. The last conclusion after the histomorphological examination and immunohistochemistry was dermatofibrosarcoma protuberans (DFSP) (Figures 4,5).

After hospital discharge the patient refused any further treatment and regular controls. One year and six months after the operation, the patient came in bad condition with signs of metastatic disease (chest wall and lung metastasis) and died after one week.

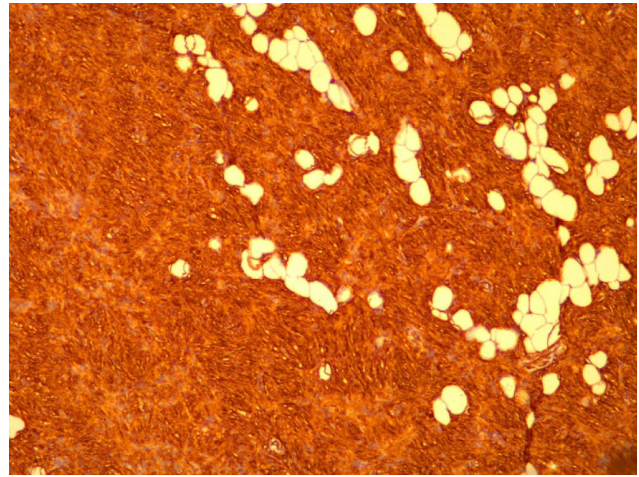


Figure 3. Cytoplasmic and membranous diffuse CD34 positivity (immunohistochemistry, x10).

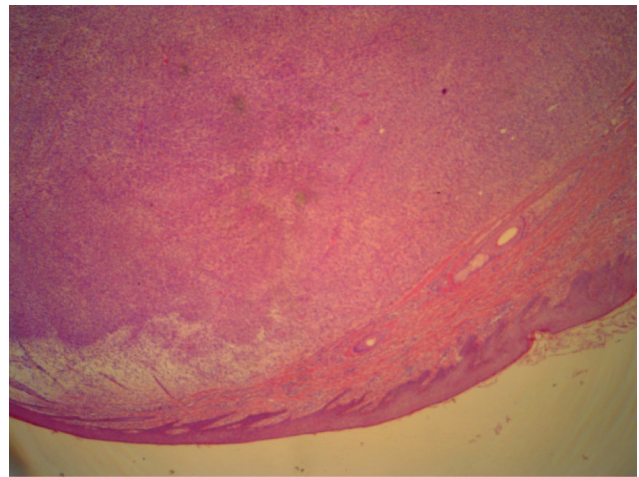


Figure 4. Nodular tumor infiltrating the deep dermis of the vulva with characteristic mesenchymal proliferation with dominant spindle cells.

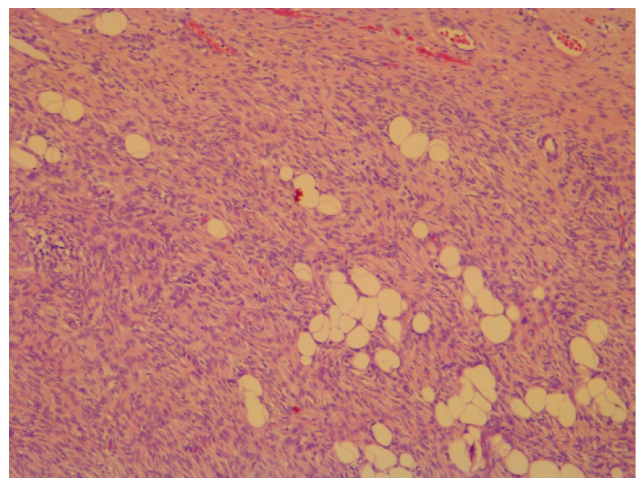


Figure 5. Tumor infiltrating the deeper dermis and subcutaneous adipose tissue. Characteristic honeycomb pattern with neoplastic cell infiltration between adipocytes in adipose tissue (H&E, x10).

Discussion

DFSP of the vulva is extremely rare, with less than 60 cases reported in the literature. Edelweiss et al. published the largest series of 13 cases for a period of 29 years (from 1978-2007). The oldest patient was 76 and the youngest 23 years old. The size of the tumor varied from small nodule masses from 1.2 cm to gigantic tumors - the largest described tumor was 15 cm in diameter [37]. Most reports describe that the origin of tumor was left labia majora, with or without involvement of mons pubis and clitoris [38,39]. In our case, we presented a patient with the largest neglected DFSP of the vulva described in the literature (18 cm).

The management of DFSP of the vulva includes a multidisciplinary approach: gynecologist, plastic surgeon and histopathologist. The treatment of choice is surgical excision with wide margins of 3 to 5 cm of normal skin [39]. In our case, the excision with wide margins 3 cm was performed very carefully, because of the very specific localization. The excision was made deep to the periosteum of pubic bone and deep muscle fascia of the anterior abdominal wall, with deliberation of the urethra 3 cm in length. The resection laterally was made to the inguinal region. In our case, reconstruction with fasciocutaneous flaps from the abdominal region was inevitable, due to large post-resection soft tissue defect. We did not performed either lymphadenectomy or chemotherapy, because the patient did not have any signs of metastatic disease. Follow up every 3 to 6 months for the first 3 years after surgery and yearly thereafter is advocated, since most recurrences commonly occur within the first 3 years of surgery [40,41].

Overall survival of the DFSP is 91-100%, while recurrence rates of 20-40% have been reported. Distant metastases are very rare and frequently appear with multiple local recurrences [40]. Our patient did not appear at regular controls and after 18 months she came with metastatic disease, and unfortunately died soon after.

Jahanseir et al. reported a series of 11 cases of primary tumor mass of the vulva. Clinical, morphological, immunohistochemical and molecular cytogenetic testing were performed. In 7 patients, a classical DFSP was diagnosed, one had myxoid DFSP and the other 3 fibrosarcomatous component of DFSP. Patients with classical tumor type had diffuse CD34 expression, the myxoid variant had reduced CD34 expression, whereas focal CD34 expression and p53 reactivity were enhanced in patients with fibrosarcomatous component. In 9 patients, the hybridization test was positive. Also, 9 patients were followed up for 1-108 months.

Distant metastases were not found, while in one patient local recurrence was observed, which certainly confirms the fact that the surgical approach but also the surgical technique which implies wide excision is very important for the further disease evolution [42].

The most common clinical presentation is a slowly growing vulvar mass, as in our reported case. Ghorbani et al. reported a series of 4 cases. In one patient, the tumor was localized in the left paraclitoral area, then right labium majus (1 case), left labium majus (1 case) and mons pubis (1 case). The size of the tumor was 1.2 to 5.0 cm. In the first patient the tumor was reoperated every 2-4 years for 20 years from primary operation, without distant metastases. The second patient was without signs of tumor recurrence 12 years after surgery and died of another reason, while the third patient was 6 months without signs of tumor recurrence. A fibrosarcomatous tumor variant was observed in the fourth patient. CD34 immunostaining was positive in 3 patients, while in 3 cases estrogen and progesterone receptor immunostains were negative [43]. In our case immunohistochemistry was strongly positive for CD34. There was no immunoreactivity for desmin, aktin, SMA alfa, CD 117 and S 100 protein. Ki-67 was 45% and p-53 60%.

In a review, Nguyen and al. presented 54 patients. Based on all cases, the most common localization of the tumor was labia major. Most of the patients were treated with wide excision, while 3 patients were operated by Mohs technique, which was shown to reduce the incidence of tumor recurrence [44].

Differential diagnosis of vulvar DFSP is similar to other localizations. It is most commonly suspected for cellular dermatofibroma, cellular leiomyoma, neurofibroma, low-grade leiomyosarcoma, fibrosarcoma, low-grade malignant schwannoma, desmoplastic melanoma, cellular neurofibroma, and low-grade malignant peripheral nerve sheet tumor. Wiszniewska et al. recently described the case of a 44-year-old woman who was primarily diagnosed as vulvar neurofibroma. Considering the absence of typical morphology and immunohistochemical findings, and with the presence of peripherally trapped fatty tissue cells, it was suspected that it could be DFSP, which was confirmed [45].

The behavior of DFSP of the vulva is not different from other DFSP localizations. Spontaneous local regressions are common while distant metastases are rare. It has been shown that DFSP with fibrosarcomatous component is more aggressive and has higher metastatic potential. The first case of vulvar DFSP with lung metastases was described in 1998 by Soergel [46]. Vathiotis et al. recently

reported a case of a 72-year-old woman who was hospitalized due to lung problems. She reported breast cancer and radical vulvectomy due to confirmed DFSP-FS. The tumor was primarily localized to the labia majus, excised and reexcised widely, with negative margins after 18 months. Lung CT showed multiple nodular metastases. FNAB and in situ hybridization test confirmed that it was DFSP. The patient was treated with imatinib 400 mg twice daily and responded well to that therapy [47].

Conclusion

DFSP presents an asymptomatic and usually nontender solid protuberant nodule or a multinodular well-circumscribed mass, characterized by local invasion and recurrence.

DFSP of the vulva is rare and surgery with free margins usually leads to severe functional damage,

requiring multidisciplinary approach regarding resection, margin assessment and reconstruction.

The differential diagnosis is problematic because it is difficult to distinguish DFSP from another fibrohistiocytic neoplasms, like fibrous histiocytoma and benign neural tumors. The role of the pathologist is essential to ensure negative microscopic margins and to avoid local recurrence. The lesion can be distinguished immunohistochemically due to its CD 34 positivity.

A complete oncological resection can be performed even in difficult cases with large and neglected lesions, minimizing the functional damage for the patient.

Conflict of interests

The authors declare no conflict of interests.

References

- Hoffman E. Ueber das knollentribende Fibrosarkom der Haut (fibrosarcoma protuberance). *Dermatol Z* 1925;43:1-286.
- Fields RC, Hameed M, Qin LX et al. Dermatofibrosarcoma protuberans (DFSP): predictors of recurrence and the use of systemic therapy. *Ann Surg Oncol* 2011;18:328-36.
- Fiore M, Miceli R, Mussi C et al. Dermatofibrosarcoma protuberans treated at a single institution: a surgical disease with a high cure rate. *J Clin Oncol* 2005;23:7669-75.
- Bowne WB, Antonescu CR, Leung DH et al. Dermatofibrosarcoma protuberans: a clinicopathologic analysis of patients treated and followed at a single institution. *Cancer* 2000;88:2711-20.
- Cai H, Wang Y, Wu J, Shi Y. Dermatofibrosarcoma protuberans: clinical diagnoses and treatment results of 260 cases in China. *J Surg Oncol* 2012;105:142-8.
- Kim BJ, Kim H, Jin US, Minn KW, Chang H. Wide local excision for dermatofibrosarcoma protuberans: a single-center series of 90 patients. *Biomed Res Int* 2015;2015: ID 642549, doi:10.1155/2015/642549.
- Stamatakis M, Fyllos A, Siafogianni A et al. Dermatofibrosarcoma protuberans: a rare entity and review of the literature. *JBUON* 2014;19:34-41.
- Weedon D. *Weedon's skin pathology* (3rd Edn). Churchill Livingstone Elsevier Ltd, London, United Kingdom: 2010 pp 833-5.
- Mckee PH, Brenn T, Calonje JE, Lazar A. *Pathology of the skin: with clinical correlations* (3rd Edn). Elsevier Mosby, Philadelphia: 2010, pp 1729-34.
- Rouhani P, Fletcher CD, Devesa SS, Toro JR. Cutaneous soft tissue sarcoma incidence patterns in the U.S.: an analysis of 12,114 cases. *Cancer* 2008;113:616-27.
- Monnier D, Vidal C, Martin L et al. Dermatofibrosarcoma protuberans: a population-based cancer registry descriptive study of 66 consecutive cases diagnosed between 1982 and 2002. *J Eur Acad Dermatol Venerol* 2006;20:1237-42.
- Harati K, Lange K, Goertz O et al. A single-institutional review of 68 patients with dermatofibrosarcoma protuberans: wide re-excision after inadequate previous surgery results in a high rate of local control. *World J Surg Oncol* 2017;15:5.
- Liang CA, Jambusaria-Pahlajani A, Karia PS, Elenitsas R, Zhang PD, Schmults CD. A systematic review of outcome data for dermatofibrosarcoma protuberans with and without fibrosarcomatous change. *J Am Acad Dermatol* 2014;71:781-6.
- Voth H, Landsberg J, Hinz T et al. Management of dermatofibrosarcoma protuberans with fibrosarcomatous transformation: an evidence-based review of the literature. *J Eur Acad Dermatol Venereol* 2011;25:1385-91.
- Llombart B, Serra-Guillen C, Monteagudo C, López Guerrero JA, Sanmartín O. Dermatofibrosarcoma protuberans: a comprehensive review and update on diagnosis and management. *Semin Diagn Pathol* 2013;30:13-28.
- Simon MP, Pedeutour F, Sirvent N et al. Deregulation of the platelet-derived growth factor B-chain gene via fusion with collagen gene COL1A1 in dermatofibrosarcoma protuberans and giant-cell fibroblastoma. *Nat Genet* 1997;15:95-8.
- Patel KU, Szabo SS, Hernandez VS et al. Dermatofibrosarcoma protuberans COL1A1-PDGFB fusion is identified in virtually all dermatofibrosarcoma protuberans cases when investigated by newly developed multiplex reverse transcription polymerase chain reaction and fluorescence in situ hybridization assays. *Hum Pathol* 2008;39:184-93.

18. Rademaker B, Angelillo M, Reiman H, Jackson I. Dermatofibrosarcoma protuberans: a review of 73 cases. *Eur J Plast Surg* 1990;13:251-5.
19. Baker P, O'Dowd G, Khan I. Dermatofibrosarcoma protuberans arising in a decorative tattoo. *Sarcoma* 2005;9:37-41.
20. Murphey M, Arcara L, Fanburg-Smith J. Imaging of musculoskeletal liposarcoma with radiologic-pathologic correlation. *RadioGraphics* 2005;25:1371-95.
21. Moureau-Zabotto L, Thomas L, Bui BN et al. Management of soft tissue sarcomas (STS) in first isolated local recurrence: a retrospective study of 83 cases. *Radiother Oncol* 2004;73:313-9.
22. Wunder JS, Healey JH, Davis AM, Brennan MF. A comparison of staging systems for localized extremity soft tissue sarcoma. *Cancer* 2000;88:2721-30.
23. DuBay D, Cimmino V, Lowe L, Johnson TM, Sondak VK. Low recurrence rate after surgery for dermatofibrosarcoma protuberans: a multidisciplinary approach from a single institution. *Cancer* 2004;100:1008-16.
24. Meguerditchian AN, Wang J, Lema B, Kraybill WG, Zeitouni NC, Kane 3rd JM. Wide excision or Mohs micrographic surgery for the treatment of primary dermatofibrosarcoma protuberans. *Am J Clin Oncol* 2010;33:300-3.
25. Loghdey MS, Varma S, Rajpara SM, Al-Rawi H, Perks G, Perkins W. Mohs micrographic surgery for dermatofibrosarcoma protuberans (DFSP): a single-centre series of 76 patients treated by frozen-section Mohs micrographic surgery with a review of the literature. *J Plast Reconstr Aesthet Surg* 2014;67:1315-21.
26. Tan WP, Barlow RJ, Robson A, Kurwa HA, McKenna J, Mallipeddi R. Dermatofibrosarcoma protuberans: 35 patients treated with Mohs micrographic surgery using paraffin sections. *Br J Dermatol* 2011;164:363-6.
27. Paradisi A, Abeni D, Ruscioni A et al. Dermatofibrosarcoma protuberans: wide local excision vs. Mohs micrographic surgery. *Cancer Treat Rev* 2008;34:728-36.
28. Farma JM, Ammori JB, Zager JS et al. Dermatofibrosarcoma protuberans: how wide should we resect? *Ann Surg Oncol* 2010;17:2112-8.
29. Chang CK, Jacobs IA, Salti GI. Outcomes of surgery for dermatofibrosarcoma protuberans. *Eur J Surg Oncol* 2004;30:341-5.
30. Kokkinos C, Sorkin T, Powell B. To Mohs or not to Mohs. *J Plast Reconstr Aesthet Surg* 2014;67:23-6.
31. Woo KJ, Bang SI, Mun GH, Oh KS, Pyon JK, Lim SY. Long-term outcomes of surgical treatment for dermatofibrosarcoma protuberans according to width of gross resection margin. *J Plast Reconstr Aesthet Surg* 2016;69:395-401.
32. Saiag P, Grob JJ, Lebbe C et al. Diagnosis and treatment of dermatofibrosarcoma protuberans. European consensus-based interdisciplinary guideline. *Eur J Cancer* 2015;51:2604-8.
33. Uysal B, Sager O, Gamsiz H et al. Evaluation of the role of radiotherapy in the management of dermatofibrosarcoma protuberans. *JBUON* 2013;18:268-73.
34. Malhotra B, Schuetze SM. Dermatofibrosarcoma protuberans treatment with platelet-derived growth factor receptor inhibitor: a review of clinical trial results. *Curr Opin Oncol* 2012;24:419-24.
35. FDA approves imatinib mesylate (Gleevec) as a single agent for the treatment of multiple indications 5/11/2009, www.fda.gov.
36. McArthur GA, Demetri GD, van Oosterom et al. Molecular and clinical analysis of locally advanced dermatofibrosarcoma protuberans treated with imatinib: Imatinib Target Exploration Consortium Study B2225. *J Clin Oncol* 2005;23:866-73.
37. Edelweiss M, Malpica A. Dermatofibrosarcoma protuberans of the vulva: a clinicopathologic and immunohistochemical study of 13 cases. *Am J Surg Pathol* 2010;34:393-400.
38. Panidis D, Rousso D, Achparaki A, Georgiadis H, Vlassis G. Recurrence of dermatofibrosarcoma protuberans of the vulva. A clinical, histological, and ultrastructural study. *Eur J Gynaecol Oncol* 1993;14:182-6.
39. Gloser HM J. Dermatofibrosarcoma protuberans. *J Am Acad Dermatol* 1996; 35:355-74.
40. Karlen RJ, Johnson K, Kashkari S. Dermatofibrosarcoma protuberans of the vulva. A case report. *J Reprod Med* 1996;41:267-9.
41. Moodley M, Moodley J. Dermatofibrosarcoma protuberans of the vulva: a case report and review of the literature. *Gynaecol Oncol* 2000;78:74-5.
42. Jahanseir K, Xing D, Greipp PT et al. PDGFP rearrangements in dermatomyosarcoma protuberance of the vulva. A study of 11 cases including myxoid and fibrosarcomatous variants. *Int J Gynecol Pathol* 2018;37:537-46.
43. Ghorbani RP, Malpica A, Ayala AG. Dermatofibrosarcoma Protuberans of the Vulva: Clinicopathologic and Immunohistochemical Analysis of Four Cases, One with Fibrosarcomatous Change, and Review of the Literature. *Int J Gynecol Pathol* 1999;18:366-73.
44. Nguyen AH, Detty SQ, Gonzaga MI, Huerter C. Clinical Features and Treatment of Dermatofibrosarcoma Protuberans Affecting the Vulva: A Literature Review. *Dermatol Surg* 2017;43:771-4.
45. Wiszniewska J, Roy A, Masand RP. Myxoid Dermatofibrosarcoma Protuberans of the Vulva: Case Report of a Rare Variant in an Unusual Location, With Unusual Morphologic and Immunohistochemical Features. *Am J Dermatopathol* 2016;38:226-30.
46. Soergel TM, Doering DL, O'Connor D. Metastatic dermatofibrosarcoma protuberans of the vulva. *Gynecol Oncol* 1998;71:320-4.
47. Vathiotis IA, Psychogiou E, Syrigos KN, Kotteas EA. Lung Metastasis From Fibrosarcomatous Dermatofibrosarcoma Protuberans of the Vulva: A Rare Case Report. *J Low Genit Tract Dis* 2018;22:85-7.