

The individual variability of the arterial "corona mortis"

*¹Zinovia Zorina, ¹Dan Croitoru, ²Eugen Cerevan

¹Department of Human Anatomy

Nicolae Testemitanu State University of Medicine and Pharmacy

²Division of Vascular Surgery, Timofei Mosneaga Republican Clinical Hospital
Chisinau, the Republic of Moldova

Authors' ORCID iDs, academic degrees and contributions are available at the end of the article

*Corresponding author: zinovia.zorina@usmf.md

Manuscript received June 09, 2020; revised manuscript July 21, 2020; published online February 22, 2021

Abstract

Background: "Corona mortis" is usually referred to in the majority of the bibliographical sources as an arterial anastomosis, formed after the connection between the pubian branch of the obturator artery and the obturator branch of the inferior epigastric artery. The metaphoric name for this anatomical variant describes the severity of the complications that may manifest after its lesion in case of a herniotomy or in the surgical interventions that are conducted on the acetabulum, with anterior surgical access pathways. The incidence of this anastomosis varies between 12-80%, its individual aspects and morphological characteristics were not mentioned in literature.

Material and methods: We have conducted a descriptive, retrospective study, based on which we studied the branches of the external iliac artery and the anterior trunk of the internal iliac artery on 197 angiographies, that were obtained from the database of the Vascular surgery section of Timofei Mosneaga Clinical Republican Hospital, Chisinau, the Republic of Moldova archive in order to determine the incidence of "corona mortis" and its individual variability based on gender, age and laterality.

Results: "Corona mortis" was identified in 39.08% cases, from which 30.96% were in the male gender and 8.12% in the female gender, the majority of patients being in the 61-70-year age group. The classical variant of "corona mortis" called *Lambda*, was identified in 70.13% of cases, the *circle* type – in 27.27% and the *laurel wreath* type – in 2.60%.

Conclusions: The knowledge of the uncommon anatomical variants of "corona mortis" is vital, because their lesion may lead to severe complications during surgical interventions in the pubic region.

Key words: "corona mortis", inferior epigastric artery, obturator artery.

Cite this article

Zorina Z, Croitoru D, Cerevan E. The individual variability of the arterial "corona mortis". *Mold Med J.* 2021;64(1):45-49. doi: 10.5281/zenodo.4527109.

Introduction

Annually, in the entire world, more than 2 million of hernioraphies are conducted as a result of inguino-femoral hernias [1].

Laparoscopically, this intervention can be made through the transabdominal preperitoneal access, where the surgeon should know in detail the anatomical particularities of the preperitoneal space and especially the dangerous zones that present vulnerabilities like "corona mortis".

The metaphorical name for this arterial branch, explains the severity of the surgical complications that may manifest after its lesion [2].

"Corona mortis" is usually referred to in the majority of the bibliographical sources as an arterial anastomosis, formed due to the connection between the pubian branch of the obturator artery and the obturator branch of the inferior epigastric artery, localized posterior from the superior branch of the pubic bone, at variable distances from the pubian symphysis [3-5].

Some authors consider "corona mortis" as an origin va-

riant of the obturator artery [6], others – as a variable vascular anastomosis (arterial or venous), where the connection branches and the topographical regions are different [7-10].

According to the studies that were conducted recently, the venous type of "corona mortis", if damaged during surgical interventions may lead to postoperative hematomas. In case of herniotomies, the arterial "corona mortis" can be damaged, causing minimal but persistent hemorrhage, that can lead to death [11-13].

At the same time, "corona mortis" also represents a danger in case of hip fractures, just as surgical interventions on the acetabulum, with anterior access [14].

In the literature, the incidence of the arterial anastomosis "corona mortis" varies between 12-80%. When it comes to the type (form) and its individual aspect, there is no information at the moment [15].

Because of this, the main goal of our study is to determine the incidence of the anatomical variants of arterial "corona mortis" and its individual variability depending on age, gender and laterality.

Material and methods

We have conducted a descriptive, retrospective study, and on its basis we studied the branches of the external iliac artery and the anterior trunk of the internal iliac artery on 197 angiographies, obtained from the database of Vascular surgery section from *Timofei Moşneaga* Clinical Republican Hospital, Chisinau, the Republic of Moldova archive. The inferior limb angiographies were made on all the patients in the study poll in order to identify and evaluate the peripheral occlusive syndrome. The femoral and iliac arterial systems were studied from 3 aspects: anterior, posterior and lateral.

The patients were grouped based on their gender and age (tab. 1).

Table 1

The repartition of the study poll based on gender and age

Age (years)	Male gender	Female gender
20-30	2	0
31-40	1	1
41-50	6	1
51-60	50	5
61-70	85	15
71-80	15	13
≥81	2	1
Total	161	36

The analysis of the angiographic records included the study of the origin of the internal and external iliac arteries, their branching, path and topographical relationship towards neighbouring blood vessels, just as the arterial anastomoses that are visible in the pubic region. We determined their morphological, topographical and individual particularities.

The criterion for the identification of "corona mortis" on angiographies constituted the arterial anastomosis between the internal and external iliac arterial systems, located posteriorly from the superior branch of the pubic bone in the Retzius space, it crosses the superior branch of the pubic bone, just as the anatomical variants that may pose a threat in case of herniotomies.

Using the *RadiAntDICOM Viewer 3.42. software* we evaluated the morphometry of the mentioned arteries, the obtained data was stored, processed and statistically analysed using the Microsoft Excel and Statistics 6.0 softwares.

Results

"Corona mortis" was identified on 77 angiographies (39.08% of cases), from which 61 (30.96%) were of the male gender and 16 (8.12%) of the female gender. Their repartition depending on the age category and gender was included in table 2.

Depending on the laterality, "corona mortis" was determined: bilaterally in 34 cases (27 – male gender, 7 – female gender); unilaterally on the right side – 16 cases (11 – male

Table 2

The repartition of the identified patients with "corona mortis" depending on gender and age

Age (years)	Male gender	Female gender
20-30	0 (0%)	0 (0%)**
31-40	1 (1.30%)	0 (0%)
41-50	3 (3.90%)	0 (0%)
51-60	17 (22.08%)	3 (3.90%)
61-70	35 (45.45%)	5 (6.49%)
71-80	5 (6.49%)	7 (9.09%)
≥81	0 (0%)	1 (1.30%)
Overall	61 (79.22%)	16 (20.78%)

**For this group there were no patients for the study poll.

gender, 5 – female gender); unilaterally on the left side – 27 cases (23 – male gender, 4 – female gender), this information may be found in table 3.

Table 3

The repartition of the identified patients with "corona mortis" depending on gender and laterality

Localization and gender	Number	%
MR	11	14.28%
ML	23	29.87%
MB	27	35.06%
FR	5	6.50%
FL	4	5.19%
FB	7	9.10%

*MR – male, right side; ML – male, left side; MB – male, bilateral; FR – female, right side; FL – female, left side; FB – female, bilateral.

The classical variant of "corona mortis", named *Lambda*, that is between the branch of the inferior epigastric artery and the oburator artery's branch was detected in 70.13% of the identified cases of "corona mortis". We named it *Lambda* because of the similarity between the angiographic image and the corresponding letter from the Greek alphabet. It has an ascendent pathway when it is located posteriorly from the superior branch of the pubic bone and a descendent pathway when it is located anteriorly.

Depending on the internal diameter of the anastomosing arteries (the internal diameter was measured in the point where the arteries are passing through the superior branch of the pubic bone) we differentiated between *Lambda major* (the internal diameter is greater than 3 mm), that was identified in 3 cases (3.90%) and *Lambda minor* (the internal diameter is not greater than 3 mm) – we identified this form in 51 cases (66.23%).

For example, we can see the angiographic images of a patient of male gender, that is 64 years old, and has a *Lambda major* type "corona mortis", unilaterally on the left side with an internal diameter of 3.62 mm (fig. 1) and a patient of female gender, that is 74 years old, for whom we have established bilaterally the *Lambda minor* type "corona mortis", its

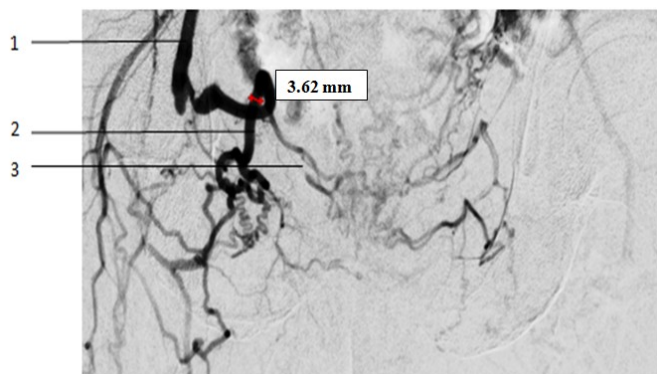


Fig. 1. *Lambda major* type, unilateral. 1. External iliac artery. 2. *Lambda major* type. 3. Poupart's ligament.

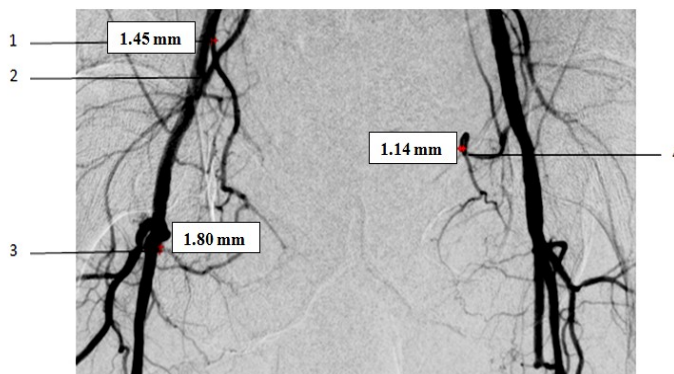


Fig. 3. Bilateral "*corona mortis*". Left side – *Closed circle* type, right side – *Lambda minor* type. 1. Superior origin spot. 2. External iliac artery. 3. Inferior origin spot. 4. *Lambda minor* type.

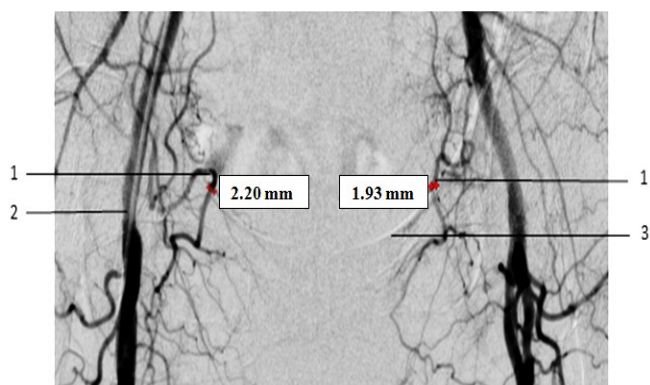


Fig. 2. Bilateral *Lambda minor* type. 1. *Lambda minor* type. 2. External iliac artery. 3. Poupart's ligament.

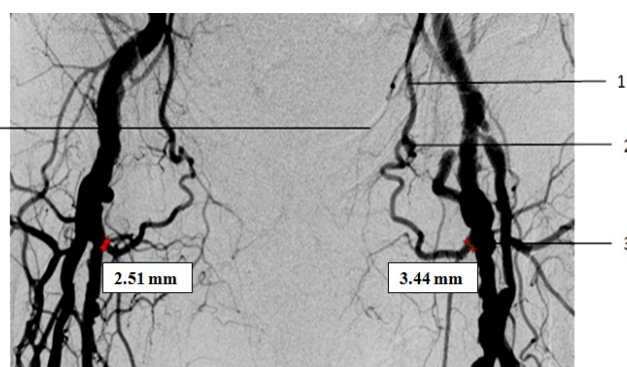


Fig. 4. Bilateral "*corona mortis*". Both sides – *Closed circle* type. 1. Inferior epigastric artery. 2. *Closed circle* type. 3. Inferior origin spot. 4. Poupart's ligament.

internal diameter constituted 2.20 mm on the left side and the one on the right side – 1.93 mm (fig. 2).

Circle type "*corona mortis*" was determined in 27.27% of cases, from which the *closed* type was identified in 7 cases (9.09%) and the *open* type in 14 cases (18.18%).

The name of this variant comes from the suggestive morphological pattern of the anastomotic or origin arterial branches. The *closed circle* type represents an arterial anastomosis that makes a connection between the external and internal iliac arterial systems, where both of the arterial origin spots are present. The *open circle* type represents an origin variant of a branch, that is not homologated in the anatomical nomenclature, that originates from the femoral or external iliac artery, this being the reason why we consider it as a distinct type of "*corona mortis*".

In Figure 3 we can observe an angiographic image of a male gender patient, that is 56 years old and has a *closed circle* type "*corona mortis*", the internal diameter of the anastomotic artery, superiorly, constituted 1.45 mm, inferiorly at the level of the femoral artery – 1.80 mm. At the same time, the same patient, had a *Lambda minor* type "*corona mortis*" with an internal diameter of 1.14 mm in the place where it was crossing the superior branch of the pubic bone (fig. 4).

Laurel wreath type "*corona mortis*" was identified only in 2 cases (2.60%). This representing an intersystemic anastomosis between the external iliac arteries.

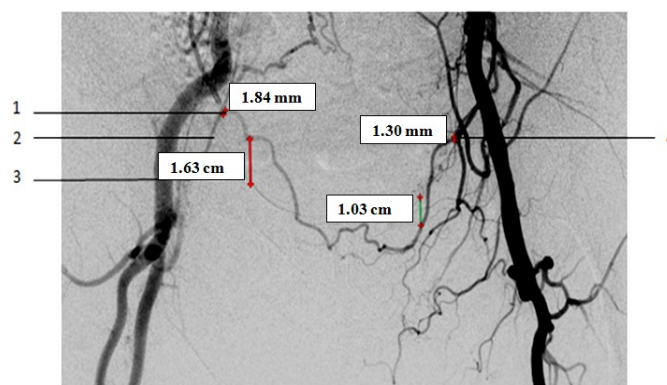


Fig. 5. *Laurel wreath* type. 1. Left origin spot. 2. Inferior epigastric artery. 3. Poupart's ligament. 4. Right origin spot.

In one of these cases, the anastomotic artery from the left side was located superiorly, at 1.63 cm distance from the Poupart's ligament, on the right side – 1.03 cm inferiorly from this ligament. On the left origin spot, the external iliac artery had an internal diameter of 1.84 mm, on the right side – 1.30 mm (fig. 5).

Laurel wreath type "*corona mortis*" doesn't correspond to the usual topography, but represents an anatomical variant that may pose a threat in case of herniotomies and other surgical interventions in this region because it is closely located towards the Poupart's ligament.

Discussion

"Corona mortis" was studied by some authors on cadaveric materials, others used angiographic records for this goal.

Rusu M, et al. [10] using the dissection method, studied 40 hemipelvises, obtaining an incidence of 65% for classical "corona mortis", Perandini S. [6], using an angiographic study poll of 300 hemipelvises determined an incidence of 30%.

Smith J. conducted an analysis of the anatomical studies that were made by other authors and mentioned a prevalence of 1-43% for this anatomical variant, for angiographic studies – up to 29% and for the endoscopic studies – 10-22% [16].

Though, the majority of authors don't consider the *open circle type "corona mortis"* as an anatomical variant of connection, but only as a variant of origin for the inferior epigastric artery, some of them mention it in the literature [5, 8, 9].

Talalwah WA. [3] relates that the *open circle type "corona mortis"* is nothing else but aberrant arteries that haven't involuted during the intrauterine development of the embryo, in which the vasculogenesis processes have continued.

We have to remark about different opinions that we confronted in the literature about the internal diameter of the anastomosing arteries, the majority of them relating about its importance, the value for this indicator was not greater than 1 mm [17, 18].

In the majority of cases, that were identified by us, the diameter of these arteries constituted 1.4-4 mm, though from the clinical aspect of view we have to consider that during the surgical interventions there are branches that have a smaller internal diameter [19].

Darmanis et al. [20] identified only 5 cases of "corona mortis", using the anterior pathway of access for the surgical interventions made on the pelvis, having 492 patients in the study poll. Letournel E. [21] encountered only one type of "corona mortis" in his practice, its branches had a sufficiently great diameter, because of which the necessity of applying a ligature on this branch was persistent.

Though, the literature regarding the clinical practice is controversial with the angiographic and cadaveric studies, the knowledge of the morphological, topographical and individual particularities of the "corona mortis" will lead to the avoidance of the surgical complications that regard the damage of this anatomical variant during surgical interventions in the pubic region.

Conclusions

1. The most frequent type of "corona mortis" is the classical one, *Lambda minor* – according to the conventional classification that was described in this study.

2. "Corona mortis" was situated bilaterally approximately in half of the patients with the identified anatomical variant on the angiographic records.

3. The uncommon types of "corona mortis" need to be known in order to avoid complications during the surgical interventions that regard the pubic region.

References

- Leroy I. Transabdominal preperitoneal approach (TAPP) [Internet]. WebSurg. 2001;1(3):243-246. [cited 2020 May 19]. Available from: <https://websurg.com/en/operative-technique/4249/ot02en194>
- Richard A, Quinn T, Fitzgibbons JR. Abdominal wall hernias. In: Mulholland M, Lillemoe K, Doherty G, et al. Greenfield's surgery: scientific principles and practice. 4th ed. Philadelphia: Lippincott Williams & Wilkins; 2006.
- Talalwah WA. A new concept and classification of "corona mortis" and its clinical significance. Chin J Traumatol. 2016;19(5):251-254. doi: 10.1016/j.cjtee.2016.06.004.
- Leite TF, Pires LA, Goke K, Silva JG, Chagas CA. Corona mortis: descrição anatômica e cirúrgica em 60 hemipelvises cadavéricas [Corona Mortis: anatomical and surgical description on 60 cadaveric hemipelvises]. Rev Col Bras Cir. 2017;44(6):553-559. doi: 10.1590/0100-69912017006001. Portuguese.
- Steinberg EL, Ben-Tov T, Aviram G, Steinberg Y, Rath E, Rosen G. Corona mortis anastomosis: a three-dimensional computerized tomographic angiographic study. Emerg Radiol. 2017;24(5):519-523. doi: 10.1007/s10140-017-1502-x.
- Perandini S, Perandini A, Puntel G, Puppini G, Montemezzi S. Corona mortis variant of the obturator artery: a systematic study of 300 hemipelvises by means of computed tomography angiography. Pol J Radiol. 2018;83:e640-e644. doi: 10.5114/pjr.2018.81441.
- Sanna B, Henry BM, Vikse J, et al. The prevalence and morphology of the corona mortis (Crown of death): a meta-analysis with implications in abdominal wall and pelvic surgery. Injury. 2018;49(2):302-308. doi: 10.1016/j.injury.2017.12.007.
- Kashyap S, Diwan Y, Mahajan S, Diwan D, Lal M, Chauhan R. The majority of Corona mortis are small calibre venous blood vessels: a cadaveric study of North Indians. Hip Pelvis. 2019;31(1):40-47. doi: 10.5371/hp.2019.31.1.40.
- Han Y, Liu P, Chen C, et al. A digital anatomical study of the corona mortis in females. Minim Invasive Ther Allied Technol. 2017;26(2):111-118. doi: 10.1080/13645706.2016.1236818.
- Rusu MC, Cergan R, Motoc AG, Folescu R, Pop E. Anatomical considerations on the corona mortis. Surg Radiol Anat. 2010;32(1):17-24. doi: 10.1007/s00276-009-0534-7.
- Nayak BD, Deepthinath R, Prasad AM, Shetty SD, Aithal AP. A South Indian cadaveric study on obturator neurovascular bundle with a special emphasis on high prevalence of "venous corona mortis". Injury. 2016;47(7):1452-1455. doi: 10.1016/j.injury.2016.04.032.
- Kinaci E, Ates M, Dirican A, Ozgor D. Low pressure is necessary to view and to protect corona mortis during totally extraperitoneal hernia repair. J Laparoendosc Adv Surg Tech. 2016;26(12):978-984. doi: 10.1089/lap.2016.0080.
- Yasuda T, Matsuda A, Miyashita M, et al. Life-threatening hemorrhage from the corona mortis after laparoscopic inguinal hernia repair: report of a case. Asian J Endosc Surg. 2018;11(2):169-172. doi: 10.1111/ases.12416.
- Yoon W, Kim JK, Jeong YY, Seo JJ, Park JG, Kang HK. Pelvic arterial hemorrhage in patients with pelvic fractures: detection with contrast-enhanced CT. Radiographics. 2004;24(6):1591-1606. doi: 10.1148/rg.246045028.
- Sarikcioglu L, Sindel M, Akyildiz F, Gur S. Anastomotic vessels in the retropubic region: corona mortis. Folia Morphol. 2003;62(3):179-182.
- Smith J, Gregorius J, Breazeale B, Watkins G. The corona mortis, a frequent vascular variant susceptible to blunt pelvic trauma: identification at routine multidetector CT. J Vasc Interv Radiol. 2009;20(4):455-460. doi: 10.1016/j.jvir.2009.01.007.
- Karakurt L, Karaca I, Yilmaz E, Burma O, Serin E. Corona mortis: incidence and location. Arch Orthop Trauma Surg. 2002;122(3):163-164. doi: 10.1007/s004020100341.

18. Lau H, Lee F. A prospective endoscopic study of retroperitoneal vascular anatomy in 121 patients undergoing endoscopic extraperitoneal inguinal hernioplasty. *Surg Endosc.* 2003;17(9):1376-1379. doi: 10.1007/s00464-003-8800-y.
19. Șcerbatiuc-Condur C, Rotaru M, Gurgăș R, Gagauz I, Gaftan V, Voșian M, Rojnovanu G. Conduita chirurgicală diferențiată a pacienților cu plăgi abdominale [Surgical differentiated management of patients with abdominal wounds]. *Arta Medica (Chisinau).* 2019;3(72):81-82. Romanian.
20. Darmanis S, Lewis A, Mansoor A, Bircher M. Corona mortis: an anatomical study with clinical implications in approaches to the pelvis and acetabulum. *Clin Anat.* 2007;20(4):433-439. doi: 10.1002/ca.20390.
21. Letournel E. The treatment of acetabular fractures through the ilioinguinal approach. *Clin Orthop Relat Res.* 1993;(292):62-76.

Authors' ORCID iDs and academic degrees

Zinovia Zorina, MD, Assistant Professor – <https://orcid.org/0000-0002-0749-6083>.

Dan Croitoru, MD, Undergraduate – <https://orcid.org/0000-0002-8915-0157>.

Eugen Cerevan, MD, Vascular Surgeon – <https://orcid.org/0000-0002-3221-7584>.

Authors' contribution

ZZ described the classical and uncommon types of "corona mortis"; DC has put into evidence the topographical, morphological and individual particularities of this anatomical variant; EC conducted the literature review.

Funding

The study was supported by *Nicolae Testemitanu* State University of Medicine and Pharmacy. The authors are independent and take responsibility for the integrity of the data and the accuracy of the data analysis.

Ethics approval and consent to participate

The research protocol was approved by the Research Ethics Committee of *Nicolae Testemitanu* State University of Medicine and Pharmacy (Protocol No 2 of 27.10.2016).

Conflict of Interests

The authors have no conflict of interests to declare.

