



CODEN [USA]: IAJPBB

ISSN : 2349-7750

**INDO AMERICAN JOURNAL OF
PHARMACEUTICAL SCIENCES**

SJIF Impact Factor: 7.187

Available online at: <http://www.iajps.com>

Research Article

**INCIDENCE OF FIRST PERMANENT MOLARS TYPE II
CLASS LESIONS AND THEIR CONNOTATION WITH PULP**Dr. Hania Khan¹, Dr. Safia Shahid², Dr. Sara Hanif³¹Punjab Dental Hospital, Lahore, ²Rawal Institute of Health Sciences, Islamabad, ³Ayub Medical College, Abbottabad.**Article Received:** November 2020 **Accepted:** December 2020 **Published:** January 2021**Abstract:**

Aim: The aim of the study was to determine the frequency of type II carious lesions in the first permanent molars and their possible relationship with the pulp in clinical and radiological examinations.

Methods: Two hundred forty-two patients were examined at the Dental department of Punjab Dental Hospital, Lahore for one-year duration from June 2019 to June 2020.

Results and Conclusion: This study showed that 62% of the respondents had a type II carious cavity. In the maxilla, unilateral class II carious lesions accounted for 19%, and bilateral 2.5%, while in the mandible, unilateral 36.4% and bilateral 4.1%, respectively. Class II carious lesions were more common in females and in mandibular molars. In terms of pulp exposure, there was a significant relationship between clinical and radiological examination.

Key words: Caries of the first-class II molars, Incidence

Corresponding author:**Dr. Hania Khan,**

Punjab Dental Hospital, Lahore.

QR code



Please cite this article in press Hania Khan et al, *Incidence Of First Permanent Molars Type Ii Class Lesions And Their Connotation With Pulp.*, *Indo Am. J. P. Sci.*, 2021; 08(1).

INTRODUCTION:

Tooth decay is an infectious, infectious disease that causes local dissolution and destruction of calcified tooth tissues [1-2]. These tissues gradually break down, leading to cavities. If caries is not treated in time, it can lead to infection, pain, tooth loss and, in severe cases, death. Although the incidence of tooth decay has been decreasing in developed countries, prevalence is still very high in developing countries. This high incidence is believed to be strongly related to eating habits and increased sugar consumption. Dental caries is the most common infectious disease in humans, affecting 97% of the population throughout its lifetime. Tooth decay is the most common childhood disease in the United States, at least five times more common than asthma [3-4]. The clinical picture of caries is very variable, initially appearing as a chalky white area that may transform into a large cavity over time. Despite recent research devoted to developing better caries detection methods, current clinical practice is still largely limited to conventional visual and viscosite tools, such as astute researchers and dental radiographs [5-6]. However, it has been found that these conventional methods for detecting cavitation defects have a low sensitivity for detecting early caries lesions. Dental radiographs are useful in detecting larger, advanced, and cavitating caries. They are insensitive to the detection of early tooth decay. Sometimes caries can be directly visible, and sometimes advanced methods are used to detect early caries lesions, such as Digital Fiber Imaging Transillumination (DIFOTI), Quantitative Light Induced Fluorescence (QLF), and Laser Induced

Fluorescence. Tooth decay can affect different areas of the tooth [7-8]. The most common places of caries occurrence are pits and furrows as well as proximal surfaces. These areas are more difficult to clean and therefore more prone to decay. The first molar is the first of the permanent teeth to erupt and decay earlier. Proximal caries may be silent and may take years to reach the pulp.

SUBJECTS AND METHODS:

The study included 242 adults (aged 16 to 70) visiting the Dental department of Punjab Dental Hospital, Lahore for one-year duration from June 2019 to June 2020. The examination was carried out on the dentist's chair with the use of a mirror and a probe after painful experience. Patient examination included sequential evaluation of all first molars. Class II lesions were first examined clinically and then the diseased teeth were radiographed. The data was recorded on a given proforma and analyzed. Patients with caries in all four first class II molars or molars with mesocclusion distal caries (MOD) were excluded.

RESULTS:

People of different sexes and ages with class II carious lesions were analyzed. The total number of respondents was 242, of which 132 (54.5%) were men and 110 (45.5%) were women. Of the 132 men, 38 had clinically exposed pulp, while 36 of 110 patients had pulp exposure in the clinical trial. The p-value was 0.508, indicating a non-significant relationship between gender and clinical pulp exposure. (Table 1)

TABLE 1: PULP EXPOSURE ON CLINICAL EXAMINATION IN MALES AND FEMALES

Gender	Pulp exposure on clinical examination		Total
	Yes	No	
Male	38	94	132
Female	36	74	110
Total	74	168	242

In 132 men, 38 had pulp exposure on radiograph and 94 had no pulp exposure on radiograph. Out of 110 patients, 36 had pulp exposed on radiographs. The p-value was 0.347, indicating a negligible relationship between sex and pulp exposure on radiographs. (Table 2)

TABLE 2: PULP EXPOSURE ON RADIOGRAPHIC EXAMINATION IN MALES AND FEMALES

Gender	Pulp exposure on radiographic examination		Total
	Yes	No	
Male	58	74	132
Female	55	55	110
Total	113	129	242

Patients were divided into 3 age groups. Group 1 ranged from 16 to 30 years old, group 2 ranged from 31 to 50 years old, and group 3 ranged from 51 to 70 years old. Of all patients (n = 242), 148 (61.2%) were in group 1. 79 (32.6%) were in group 2, and 15 (6.2%) were in group 3 (Fig. 1).

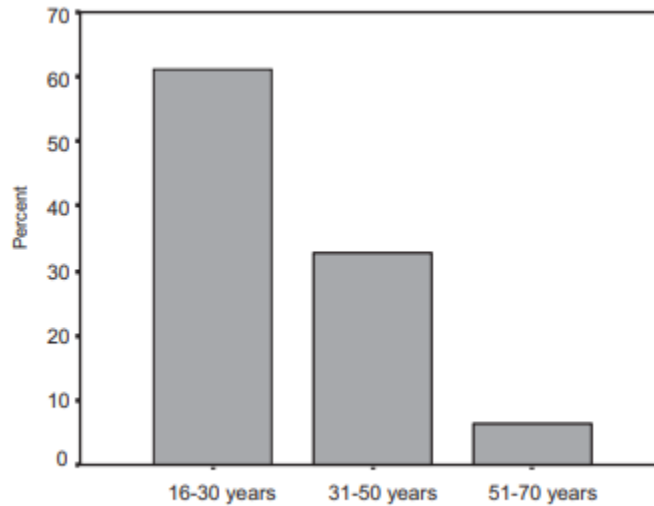


Fig 1: Age distribution of the patients

In group 1 (148 patients), 53 had clinical pulp exposure, while 95 had no clinical exposure. In group 2 (79 patients), 20 teeth were clinically exposed, 59 were not clinically exposed, while in group 3 (15 patients) 1 tooth was exposed, and 14 were healthy for clinical reasons. The p-value is 0.03, indicating a significant relationship between the patient's age group and clinical pulp exposure (Table 3).

TABLE 3: COMPARISON OF AGE GROUP OF THE PATIENT AND PULP EXPOSURE ON CLINICAL EXAMINATION

Age Group of the patients	Pulp exposure on on clinical examination		Total
	Yes	No	
16-30 years	53	95	148
31-50 years	20	59	79
51-70 years	1	14	15
Total	74	168	242

There was also a significant relationship between the age group of patients and the pulp exposure in radiographic examination (p-value = 0.005). In group 1 (148 patients), 79 teeth were radiographically irradiated and 69 were not. In group 2 (79 patients), 32 teeth were exposed and 47 were not radiographically exposed. Thirteen out of 15 patients had no pulp exposure in group 3 (Table 4).

TABLE 4: COMPARISON OF AGE GROUP OF THE PATIENT AND PULP EXPOSURE ON RADIOGRAPHIC EXAMINATION

Age Group of the patients	Pulp exposure on Radiographic examination		Total
	Yes	No	
16-30 years	79	69	148
31-50 years	32	47	79
51-70 years	2	13	15
Total	113	129	242

In our study, 92 patients had no class II caries in their first molars. In 46 (19%) patients' unilateral maxillary involvement was found. first molars, while 6 (2.5%) patients had class II lesions in both maxillary first molars. 36.4% (88 patients) had unilateral mandibular molar involvement, while 4.1% (10 patients) had class II lesions in both first mandibular molars. (Table 5)

TABLE 5: FREQUENCY OF CLASS II CARIOUS LESIONS

	Frequency	Percentage
No Class II Lesions	92	38
Class II lesions in unilateral Maxillary First Molars	46	19
Class II lesions in bilateral Maxillary First Molars	6	2.5
Class II lesions in unilateral Mandibular First Molars	88	36.4
Class II lesions in bilateral Mandibular First Molars	10	4.1
Total	242	100

Of the 74 teeth found in the clinical examination, 69 were also exposed in the radiological examination, while 5 had no evidence of radiological exposure. Of the 168 teeth, 124 teeth were not exposed by X-ray or clinical examination, while 44 of 168 teeth were radiographically but not clinically exposed. The p-value was 0.000, indicating a significant relationship (Table 6).

TABLE 6: ASSOCIATION OF PULP EXPOSURE CLINICALLY AND RADIOGRAPHICALLY

		Pulp exposure on clinical examination		Total
		Yes	No	
Pulp exposure on radiographic examination	Yes	69	44	113
	No	5	124	129
Total		74	168	242

DISCUSSION:

Dental caries is a multi-factorial disease that is influenced by many factors, including age, gender, diet, microorganisms, trace elements, saliva, genetic predisposition, and tooth morphology. The study showed that most of the patients admitted to this department had class II caries defects in the first molars. In most cases, the first molars of the mandible were involved [9-10]. This may be due to improper oral hygiene practices or the eruption of the first molar in the mandible earlier than in the maxilla. A study by Khan in India found that women are more prone to tooth decay than men. Lukacs and Largaespada in their studies showed that when the caries rate is determined by gender, women tend to have a higher prevalence rate than men. They explained the high prevalence of caries in women by one of three factors; 1) earlier eruption of teeth in girls, and thus longer exposure of girls' teeth to the carious environment of the oral cavity, 2) easier access of women to food and frequent snacking during food preparation, and 3) pregnancy [11-12]. This study also shows a higher percentage of tooth decay in women compared to men. The number of men attending the hospital was higher compared to women, but a higher percentage of class II carious lesions and pulp involvement was found in women. Tooth decay is a strongly age-related disease as found in the Simon Hilson study. The greatest number of cases occurred in the age group from 21 to 30 years. The present study also showed that the majority of patients in age group 1 (16–30 years) had a class II lesion in their first molars, and a fairly high proportion of these patients had clinically or radiographically detected pulp exposure. This is due to the fact that at an early age, the dentinal tubules and the pulp chamber are wider, and the pulp corners are higher. In addition, young people eat more sweets than the elderly [13]. This study also showed that most teeth with class II lesions were detected clinically and radiographically. This shows that there

is an increased association of pulp involvement with class II lesions. There may not be a real relationship between pulp exposure in clinical and radiographic examination. An X-ray image is a two-dimensional image of a three-dimensional object. The tooth appears exposed on a radiograph, it may not actually be exposed. However, in this study, a significant relationship was observed between radiographic and clinical pulp exposure. A detailed pain history was recorded to confirm clinical exposure. The degree of symmetry of the susceptibility to caries of different tooth surfaces, both between the upper and lower jaw, in the posterior sextants was also noted. Most authors, accepting the degree of left: right symmetry in an attack of caries, assumed that it is either the same site on the left side of the mouth as on the right side [14-15]. The concept is so well received that some caries survey systems only test one side of the mouth and then double the result to get a total DMFS. The fact that caries occurs on both sides of the same type of tooth suggests that in the case of decay or increase in caries, it occurs in increments of 2. However, in the presented studies, such a degree of proximal caries symmetry was not found.

CONCLUSIONS AND RECOMMENDATIONS:

In young adults, the incidence of type II carious lesions in the first permanent molar is high. It should be improved through appropriate dental health education and more emphasis on caries prevention. Caries detection is an inaccurate science, although there is a better understanding of the caries process. The pulp appears to be radiographically exposed, and vice versa. Therefore, the X-ray image itself should not be considered a tool for determining the condition of the pulp. It must be accompanied by a detailed and detailed history of the patient.

REFERENCES:

1. Berdouses, E. D., A. Agouropoulos, M. Sifakaki, P. Lagouvardos, and C. J. Oulis. "Restorative

- direct management of cavitated proximal carious lesions of permanent molars using elastic separators in children and adolescents." *Dental Research and Oral Health* 3, no. 4 (2020): 190-201.
2. Vacaru, Raluca-Paula, Silvia Per, Ioana-Andreea Stanciu, Aneta Munteanu, Daniela Miricescu, Alexandra Totan, MIHAELA TĂNASE, and Andreea Cristiana Didilescu. "Clinical and microbiological features of carious dentin in immature permanent molars." *ROMANIAN BIOTECHNOLOGICAL LETTERS* 26, no. 1 (2021): 2340-2346.
 3. Houchaimi, Amani, Nada El Osta, Jean-Claude Abou Chedid, Lana El Osta, and Nada Farhat Mchayleh. "Assessment of caries on the first permanent molars in a group of seven-to thirteen-year-old schoolchildren: Comparison of DMF and ICDAS systems." *International journal of dental hygiene* 18, no. 4 (2020): 362-368.
 4. Dall, Abdul Qadir Khan, Sarwat Batool Sarwanand, Suraj Arora, Saifullah Qureshi, and Muhammad Ahmed Bari. "Location of Pulp Chamber in Lower First Permanent Molars: In-Vitro Study."
 5. Verma, Purva, S. P. Dinesh, and Naveen M. Kumar. "PREVALENCE OF MISSING PERMANENT FIRST MOLARS IN PATIENTS SEEKING ORTHODONTIC TREATMENT." *European Journal of Molecular & Clinical Medicine* 7, no. 1 (2020): 1996-2002.
 6. Chen, Xiaoxian, Hongmei Zhang, Jie Zhong, Wenjuan Yan, Bichen Lin, Meili Ding, Shihua Xue, and Bin Xia. "Comparison of indirect pulp treatment and iRoot BP Plus pulpotomy in primary teeth with extremely deep caries: a prospective randomized trial." *Clinical Oral Investigations* (2020): 1-10.
 7. Almoznino, Galit, Ortal Kessler Baruch, Ron Kedem, Noam E. Protter, Boaz Shay, Nirit Yavnai, Dorit Zur, Eitan Mijiritsky, and Itzhak Abramovitz. "SOS Teeth: First priority teeth with advanced caries and its associations with metabolic syndrome among a national representative sample of young and middle-aged adults." *Journal of clinical medicine* 9, no. 10 (2020): 3170.
 8. Obadiah, Ivan, Deepa Gurunathan, and Vignesh Ravindran. "REQUIREMENTS OF BACK TO BACK CROWNS IN 2 TO 6 YEAR OLD CHILDREN IN MAXILLARY ARCH-AN OBSERVATIONAL STUDY." *European Journal of Molecular & Clinical Medicine* 7, no. 1 (2020): 1189-1196.
 9. Muller-Bolla, Michèle, Anaïs Garcia, Elody Aïem, and Sophie Doméjean. "Dentists' decisions for deep carious lesions management in primary teeth." *International Journal of Paediatric Dentistry* (2020).
 10. عجينه عبدالله نهى. "Clinical effectiveness of Embrace wetbond and Clinpro as pits and fissure sealants in young permanent molars, Randomized clinical trial." *CU Theses* (2020).
 11. Liberman, J., R. Franzon, L. F. Guimarães, L. Casagrande, A. N. Haas, and F. B. Araujo. "Survival of composite restorations after selective or total caries removal in primary teeth and predictors of failures: A 36-months randomized controlled trial." *Journal of Dentistry* 93 (2020): 103268.
 12. Valério, Rodrigo Alexandre, Rodrigo Galo, Daniel Galafassi, Silmara Aparecida Milori Corona, and Maria Cristina Borsatto. "Four-year clinical prospective follow-up of resin composite restoration after selective caries removal using Er: YAG laser." *Clinical oral investigations* 24, no. 7 (2020): 2271-2283.
 13. Naz, Neelum, Romana Noreen, Amara Nazir, Muhammad Javed Iqbal, and Sadiq Amin Ahmed Rana. "FREQUENCY OF POST-OPERATIVE SENSITIVITY IN PERMANENT POSTERIOR TEETH WITH CLASS I COMPOSITE RESTORATIONS." *Annals of Dental Specialty Vol* 8, no. 1 (2020): 1.
 14. Durmus, Basak, Berkant Sezer, Nihan Tugcu, Cansu Caliskan, Nural Bekiroglu, and Betul Kargul. "Two-Year Survival of High-Viscosity Glass Ionomer in Molar Incisor Hipomineralized-molars." *Medical Principles and Practice* (2020).
 15. Aïem, Elody, Clara Joseph, Anaïs Garcia, Violaine Smaïl-Faugeron, and Michèle Muller-Bolla. "Caries removal strategies for deep carious lesions in primary teeth: systematic review." *International Journal of Paediatric Dentistry* (2020).