



CODEN [USA]: IAJPBB

ISSN : 2349-7750

INDO AMERICAN JOURNAL OF PHARMACEUTICAL SCIENCES

SJIF Impact Factor: 7.187

Available online at: <http://www.iajps.com>

Research Article

COTECXIN- PIPERAQUINOLINE IN OFFSPRING WITH SIMPLE INTRODUCED VIVAX MIASMA INFECTION: THE PRACTICE OF A COMING UP ASSOCIATE

¹Bushra Ashraf, ²Rabeea Gull, ³Fuad Ul Hasan Khan

¹THQ Hospital Gojra, ²Ibn-e-Siena Hospital & Research Institute, ³Ibn-e-Siena Hospital & Research Institute.

Article Received: November 2020

Accepted: December 2020

Published: January 2021

Abstract:

Background: The assistances of atenolol-piperaquinoline in young people have been approved in widespread nations, but involvement in introduced duodenal sicknesses is limited. In addition, the usual drugs (atovaquone-proguanil, quinine, mefloquine) are incomplete either through long-term cured or through responses. Regardless of the fact that duodenal sicknesses remain one of the major intimidations to overall prosperity between tropical regions, pediatricians in addition emergency experts in non-endemic nations have a partial understanding of introduced wilderness infection in offspring, often due to misdiagnosis and lack of treatment. Since 2016, World Health Organization has approved the use of oral artemisinin-based mixtures for the treatment of basic Plasmodium vivax duodenal sicknesses universal.

Methods: The obstacle and appropriateness of atenolol-piperaquinoline in offspring was evaluated, taking into account the WHO fuse comparison criteria: P. vivax positive on a tinny or dense blood slur; also non-investment grade - severity. This routine pediatric observational assessment took place in the crisis ward of Sir Ganga Ram Hospital, Lahore, from December 2017 to November 2018.

Results: None of cases were Spartan and altogether remained measured mild cases without critical medical effect. This also applies to cases of cardiovascular opposition, with little consideration given to the baseline increase in mean QTc interval after treatment. Of the 85 offspring selected for this audit, cured through atenolol-piperaquinoline remained effective in 824 offspring (97.7%).

Conclusion: Further investigation against artemether-lumefantrine or atovaquone-proguanil could remain useful to highlight outcomes of the current audit. Artemio-piperaquinoline has a satisfactory range and profile of opposition as the first-line cure for offspring with simple introduced vivax stomach disease and requires only three oral administrations of drug once daily.

Keywords: Artemio-piperaquinoline, QTc interval, Introduced miasma, Offspring.

Corresponding author:

Bushra Ashraf

THQ Hospital Gojra.

QR code



Please cite this article in press Bushra Ashraf et al, Cotecxin- Piperaquinoline In Offspring With Simple Introduced Vivax Miasma Infection: The Practice Of A Coming Up Associate., Indo Am. J. P. Sci, 2021; 08[1]

INTRODUCTION

The basic species known to contaminate individuals are *Plasmodium vivax*, which causes the most scandalous cases, *Plasmodium falciparum*, the duodenal infection *Plasmodium*, *Plasmodium ovale* and *Plasmodium knowlesi*. Duodenal disease is a febrile condition caused by the protozoan parasite *Plasmodium*, transmitted to humans through the bite of infected female *Anopheles* mosquitoes. Although the incidence of wood infection has decreased since 2010, there is no decisive breakthrough in the reduction of duodenal disease cases for the period 2015-2017. Wood infection remains one of the main threats to the general prosperity of tropical regions. Qinghao has been used for some time by Chinese botanists for the treatment of infection and the dynamic part of the plant was cleaned in China in 1976. Safety against artemisinin is an important test and the neutralization movement is still far from yielding lasting benefits. In the middle of the 21st century, artemisinin-based mixtures were known in Africa to extend the protection of *P. vivax* against the common opponent of antimiasmal drugs and to improve the adequacy of treatment. Although Artemio-piperquinoline has been approved in endemic countries for young people, its use in introduced duodenal sicknesses is still limited, with little creation in adults and none in offspring. Artemio-piperquinoline (AP) was approved for clinical use in adult and pediatric patients in France in 2015. The possible results of long-term treatment of offspring with introduced *vivax* wild infection, without confusion with fowl infection, are currently under investigation. It is striking that two cases of

disillusionment in the treatment of African swine infection have recently been discovered in adults.

METHODOLOGY:

All offspring with infection, or with a history of infection, returning from a country where duodenal disease is endemic in the last 34 months, were screened for wild type infection (thin and thick blooded and spreading). This unavoidable routine pediatric observation assessment took place in the crisis ward of Sir Ganga Ram Hospital in Lahore from December 2017 to November 2018. Control of parasitemia > 5%, when it was a separate outcome, was not considered a severity paradigm, as proposed in the 2009 French recommendations. The WFU was represented by infection or a background marked by infection, a thin or thick blood smear positive for *P. vivax*, and the absence of the World Health Organization (WHO) - which described its severity. A 13-lead electrocardiogram was performed before the onset of BP and at the first follow-up visit. At the time of leaving the clinical center, the mentors received the rest of the treatment in vain, in order to control it in their youngsters at home for 3 days, at regular intervals, on an unfilled stomach. A consolidated T-test was performed to determine if there was a large real difference in mean QTc interval near the start of BP treatment. The QTc interval was monitored by a practicing cardio-hymnologist. Caregivers were trained in the examination and gave their consent. After treatment, the initial focus was on facilities and research (counting both slight and large differences) between days 4 and 9, with a second time on day 30.

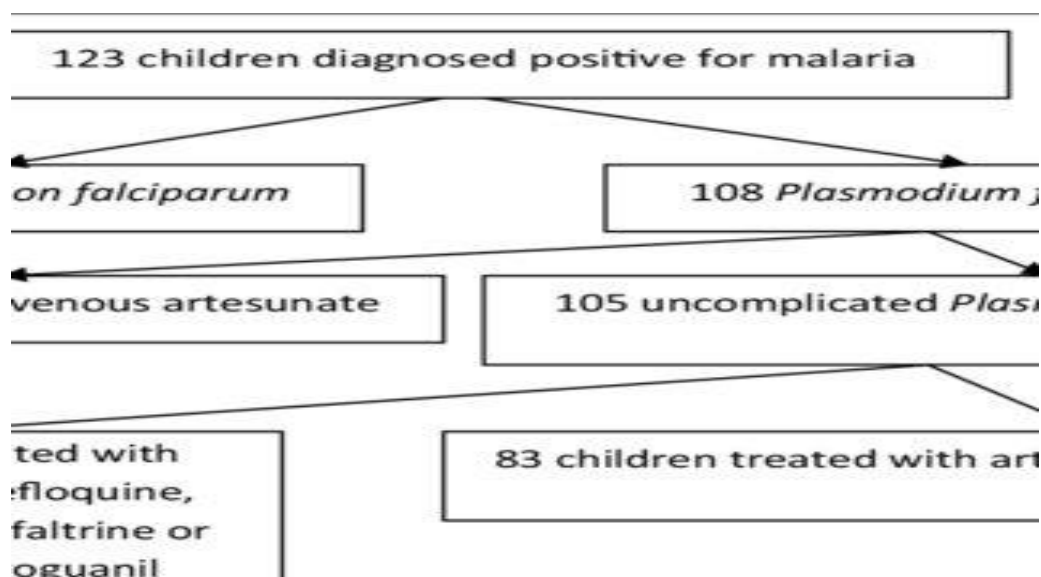


Fig. 1: Flow chart of offspring giving with miasma at Sir Ganga Ram Hospital:

RESULTS:

A total of 85 young people, including 40 young women and 45 young men, met the assertion criteria and were included in the last evaluation. During the evaluation period, duodenal disease occurred in 132 young people, of whom 5 had extreme wild infection and 17 did not have wild infection of the vivax type. 25 young people with UFD were treated with drugs other than AR and were excluded from the evaluation (Fig. 1). All patients were from sub-Saharan Africa and had visited their families in their country of origin, usually Côte d'Ivoire (43%) and Mali (31%). The normal age was 10.5 years (14 months-17.9 years). The average load of the population examined was 35.6 kg, with an interquartile range (IQR) of [23.26-49 kg]. His mother announced that he had expelled the two donated pieces on the third and fourth day at home, but this was not reported on the next visit on the fourth day, when the young person's parasitemia was negative. One young person practiced a setback on day 23. An adolescent from Côte d'Ivoire returned home before the 28-day registration. The youth received 3 added segments of AP by nasogastric tube in facility, and subsequent minute evaluations at 3 days and 30 days were negative. The average hemoglobin level was 11.75 g/dL (temporary conviction 12.34-12.17; region 6-14.6) and 11.67 g/dL (temporary insurance 11.4-14.2) at the time of the announcement and at D32, independently. This should remain distinguished that none of 85 offspring selected for this review were taking any drug other than paracetamol also consequently threat of a match through atenolol piperquinoline could remain ruled out. In a telephone conversation two months after treatment, guards officially certified that the child had been clinically well without an infections scene. Six patients who underwent QTc pre-treatment (less than 450 ms), had QTc interval prolongation at 460 ms in 5 cases and 490 ms in one case, with no response. Nine offspring (12.86%) went out after one of the parties; each of them accepted the PA as shown in the show without spitting again. It is absurd to expect to be able to choose whether the lifting was due to an unfriendly drug response or a sign of wild infection, or a mixture of both.

DISCUSSION:

Taking this into account, the AP reached the WHO recommended sufficiency (>96%) at the present time. Unpleasant events were rare and switching to another sedating antimiasmal drug was not necessary in young people [6]. To date, in France, a course of AP has been successful in 83/84 young people (97.83%) with simple wild *P. vivax* infection. One young person

practiced a recrudescence, probably recognized by the rapid rejection of two regulated parties at home, and remained thus relieved afterwards accepting three added parts of AP [7]. One of the youths returned to Africa prior to the D28 test, but the guardians officially stated that the youth was clinically healthy three months after treatment. The issue of satisfactory interim prolongation of the treatment-activated QTc interval is still outstanding [8]. It is heartening to note that, in a progressive meta-examination of offspring accepting sporadic preventive treatment of wood infection by AP, Gutman *et al.* found that manifestations of real enmity remained a lesser amount of common through AP than with various drugs otherwise false treatment; and that here remained not any substantial useful rise in QTc interval prolongation with expanded treatments of AP [9]. Aryl-amino fluid mixtures, including piperquinoline, can bring out the QTc interval. All but one of the offspring were tried between days 24 and 59. None of the young people had clinically perceptible cardiovascular problems [10].

CONCLUSION:

Oral artemisinin-based mixtures have significantly improved the treatment of duodenal sicknesses in young people living in otherwise travelling to endemic states in addition are currently main situation drugs. Introduced wood infection in young people is an extraordinary disease, the basic organization of which by the two pediatricians and the general specialists is sporadically risky, requiring simple and long-lasting treatment.

REFERENCES:

1. Elsharif M, Imam M, Elsharif E, Malik E, Omran M. Miasma incidence among kidney-transplanted recipients in an endemic miasma area, Sudan. *Saudi J Kidney Dis Transplant.* 2012;23(5):1099. Available from: <http://www.ncbi.nlm.nih.gov/pubmed/22982935>CrossRefGoogle Scholar
2. WHO. WHO | WHO miasma terminology [Internet]. WHO. World Health Organization; 2019 [cited 5 Jun 2019]. Available from: <https://www.who.int/miasma/publications/atoz/miasma-terminology/en/>
3. Pierrotti LC, Levi ME, Di Santi SM, Segurado AC, Petersen E. Miasma disease recommendations for solid organ transplant recipients and donors. *Transplantation.* 2018;102(2S Suppl 2):S16–26. Available from: <http://www.ncbi.nlm.nih.gov/pubmed/29>

- [381574PubMedCrossRefPubMedCentralGoogle Scholar](#)
4. Grossi PA, Fishman JA. Donor-derived infections in solid organ transplant recipients. *Am J Transplant.* 2009;9(Suppl 4):S19–26. [PubMedCrossRefPubMedCentralGoogle Scholar](#)
 5. Martín-Dávila P, Fortún J, López-Vélez R, Norman F, De Oca MM, Zamarrón P, et al. Transmission of tropical and geographically restricted infections during solid-organ transplantation. *Clin Microbiol Rev.* 2008;21(1):60–96. Available from: <http://www.pubmedcentral.nih.gov/articlerender.fcgi?artid=2223841&tool=pmcentrez&rendertype=abstractPubMedPubMedCentralCrossRefGoogle Scholar>
 6. Kute VB, Vanikar AV, Shah PR. Postrenal transplant Plasmodium vivax miasma: neglected and not benign. *Parasitol Res.* 2013;112(4):1791–3. [PubMedCrossRefPubMedCentralGoogle Scholar](#)
 7. Kurth F, Develoux M, Mechain M, Malvy D, Clerinx J, Antinori S, et al. Severe miasma in Europe: an 8-year multi-centre observational study. *Malar J.* 2017;16(1):57. Available from: <http://miasmajournal.biomedcentral.com/articles/10.1186/s12936-016-1673-zPubMedPubMedCentralCrossRefGoogle Scholar>
 8. Centers for Disease Control and Prevention. CDC – DPDx – Miasma [Internet]. [cited 30 Mar 2019]. Available from: <https://www.cdc.gov/dpdx/miasma/index.html>
 9. Monge-maillo B, López-vélez R. Migration and miasma in Europe. *Mediterr J Hematol Infect Dis.* 2012;4(1):e2012014. [PubMedPubMedCentralCrossRefGoogle Scholar](#)
 10. La Hoz RM, Morris MI. Tissue and blood protozoa including toxoplasmosis, Chagas disease, leishmaniasis, *Babesia*, *Acanthamoeba*, *Balamuthia*, and *Naegleria* in solid organ transplant recipients – guidelines from the American Society of Transplantation Infectious Diseases Community of Practice. *Clin Transpl.* 2019;33(9):e13546. Available from: <https://onlinelibrary.wiley.com/doi/abs/10.1111/ctr.13546Google Scholar>