



CODEN [USA]: IAJPBB

ISSN : 2349-7750

## INDO AMERICAN JOURNAL OF PHARMACEUTICAL SCIENCES

SJIF Impact Factor: 7.187

Available online at: <http://www.iajps.com>

Research Article

### A MULTIPLE READER REVIEW TO COMPARE MULTI- INSTITUTIONAL DIGITAL TOMOSYNTHESIS RESULTS DUAL ENERGY IMAGERY CONVENTIONAL CHEST X-RAYS FOR DIAGNOSIS AND TREATMENT OF PULMONARY NODULES

<sup>1</sup>Dr Ramsha Tanveer, <sup>2</sup>Dr Maryam Shabbir Abbasi, <sup>3</sup>Dr Amna Mir

<sup>1</sup>Pakistan Institute of Medical Sciences, Islamabad, <sup>2</sup>Pakistan Institute of Medical Sciences, Islamabad, <sup>3</sup>Holy Family Hospital Rawalpindi.

Article Received: November 2020    Accepted: December 2020    Published: January 2021

**Abstract:**

***Aim:** To lead a multi-institutional, multileader study to analyze the execution of advanced to synthesis, double energy (DE) imaging, also, traditional chest radiography for aspiratory knob identification also, the board.*

***Methods:** In this planned binational HIPAA-compliant survey, 167 subjects (46 subjects with routine findings) were enrolled in four foundations. Informed consent was obtained prior to enrollment. Subjects underwent computed tomography (CT) scan and imaging with the usual chest x-ray (postero-anterior and sidelong), DE imaging, and CT synthesis with a level imaging gadget. Our current research was conducted at Jinnah Hospital, Lahore from May 2019 to April 2020. Three experienced thoracic radiologists recognized areas of authentic pimples (n = 518, width 4-26 mm) with the CT and suggested using the Fleischer Society rules for the board case. Five different radiologists verified the buttons and demonstrated the case to the frames using images from traditional chest radiography, regular chest radiography in addition to DE imaging, CT synthesis, in addition, CT synthesis in addition to DE imaging. Affectability, specificity, and overall accuracy were estimated using the free response recipient work mark technique and the free response recipient work mark technique for button identification and frame case, separately. The results were also studied according to button measurement classifications (3-4 mm, .4 mm to 6 mm, .6 mm to 8 mm, and .8 mm to 20 mm).*

***Results:** The maximum division of injury limitation was higher for computed tomography than for conventional chest radiography in all button size classes (3.55 overlay for all buttons, P, 0.002; 96% certainty interval [CI]: 2.96, 4.16). Affectability at the case level was higher with computed tomographic synthesis than with conventional chest X-ray for all buttons (1.49 overlay, P, 0.002; 96% CI: 1.26, 1.74). Frame selection showed greater overall accuracy with tomographic synthesis than with conventional chest radiography, as shown by the area under the curve of the collector working mark (1.23 overlap, P, .002; 96% CI: 1.16, 1.35). There were no distinctions in the peculiarity measurements. ED imaging did not have a significant influence on button recognition when combined with a normal chest X-ray or CT scan synthesis.*

***Conclusion:** Tomo synthesis beat conventional chest x-ray placement and case management assurance; DE imaging revealed no vital contrasts with traditional chest x-raying or tome synthesis alone; These results indicate that implementation with a reach of peruser mastery is definitely probable.*

***Keywords:** Multi-Institutional Digital Tomosynthesis Results Dual Energy Imagery Conventional Chest X-Rays.*

**Corresponding author:****Dr. Ramsha Tanveer,***Pakistan Institute of Medical Sciences, Islamabad.*

QR code



*Please cite this article in press Ramsha Tanveer et al, A Multiple Reader Review To Compare Multi-Institutional Digital Tomosynthesis Results Dual Energy Imagery Conventional Chest X-Rays For Diagnosis And Treatment Of Pulmonary Nodules., Indo Am. J. P. Sci, 2021; 08(1).*

**INTRODUCTION:**

A variety of uses, including chest image counting, muscle imaging, urologic imagery (9) and chest imaging, were used for advanced tomosynthesis. Indeed, advanced CT chest synthesis is available now and is approved since 2006 by the United States Food and Drug Organization [1]. Initial clinical evidence has demonstrated that the position effect of pneumonic pimples will theoretically triple relative to normal chest X-rays by seasoned radiologists on the thoracic [2]. Dual-power (DE) picture was used in order to enhance the position of pumps as opposed to normal chest x-rays before advancement of tomosynthesis, minimizing ribs from visual interference and presenting evidence on instances of pimple calcification [3]. Overall, however, ED imagery has seen a more discreet increase in precision than has lately been shown in tomographic synthesis [4]. We explain in this article a study to examine the disclosure of these approaches by using a financially accessible gadget that is approved by the US. Administration of food and drugs. Important tests were used in order to analyze the precision of the orientation of the button in the case of tomosynthesis and standard chest X-rays, with and without ED imaging [5].

**METHODOLOGY:**

Image knowledge was obtained in four third-order destinations from subjects, three in the US and one in Sweden. The sample has been confirmed by the formal

survey bodies of each organization and informed consent from each subject has been obtained before registration. Our current research was conducted at Jinnah Hospital, Lahore from May 2019 to April 2020. The research was carried out under the Portability and Liability Act for Health Benefits. In order to doubt a lungs button or a number of indications that did not apply to the suction keys, the chosen subjects were or had recently been subjected to a reported CT scan. No subject has undergone a CT scan for the purposes of this investigation solely. Addendum E1 on the site documents the mode of consideration and prohibition, the study of the peoples' socio-economics, and the conduct of cases dismissed by the last examinee. 187 themes were decided and chosen for the survey. Of all, 156 participants met all the conditions for participation in the last study survey, 118 had one or more scanner-confirmed pneumonic pimples and 43 had no pimples. Radiographs were collected for forensic purposes after a CT examination, including post-aro-anterior and lateral tissue radiographs, a tissue and bone radiograph and computed tomography synthesis images. The commercial U.S. licensed gadget was used to collect all radiographic images. Administration of food and drugs. Subjects were located for evaluation of AP chest X-ray and then for evaluation of DE, high-power DE pictures, supplementing the father's conventional X-ray, were obtained with low energy (70 kVp) and high energy (120 kVp) Ray.

Figure 1:

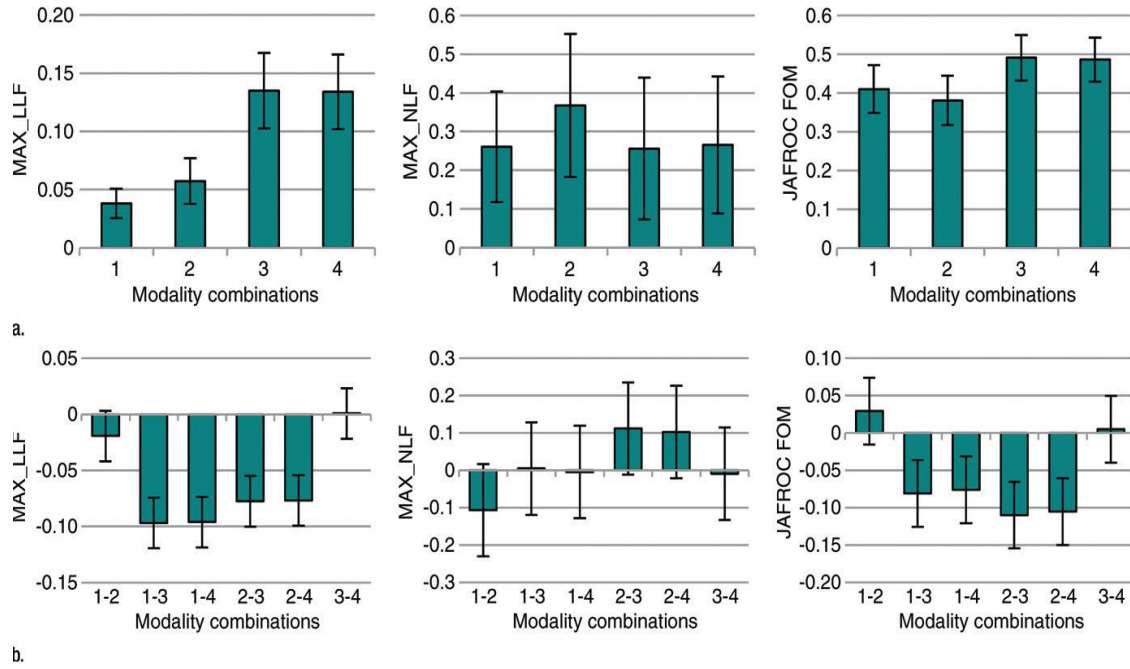


Figure 2:

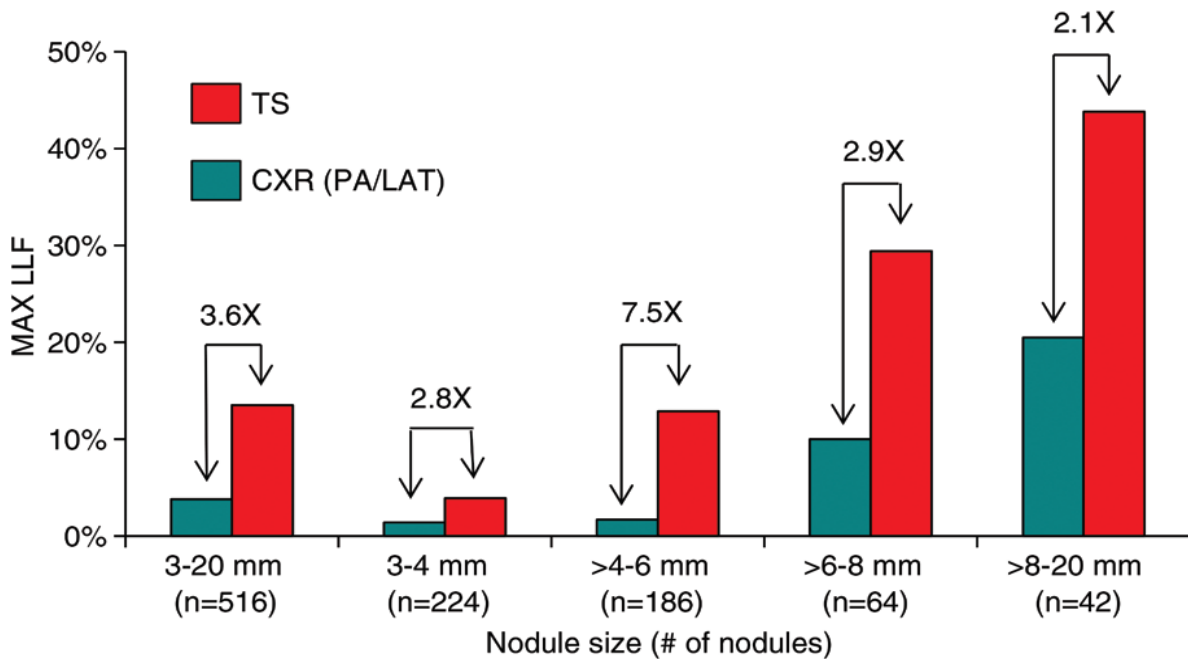
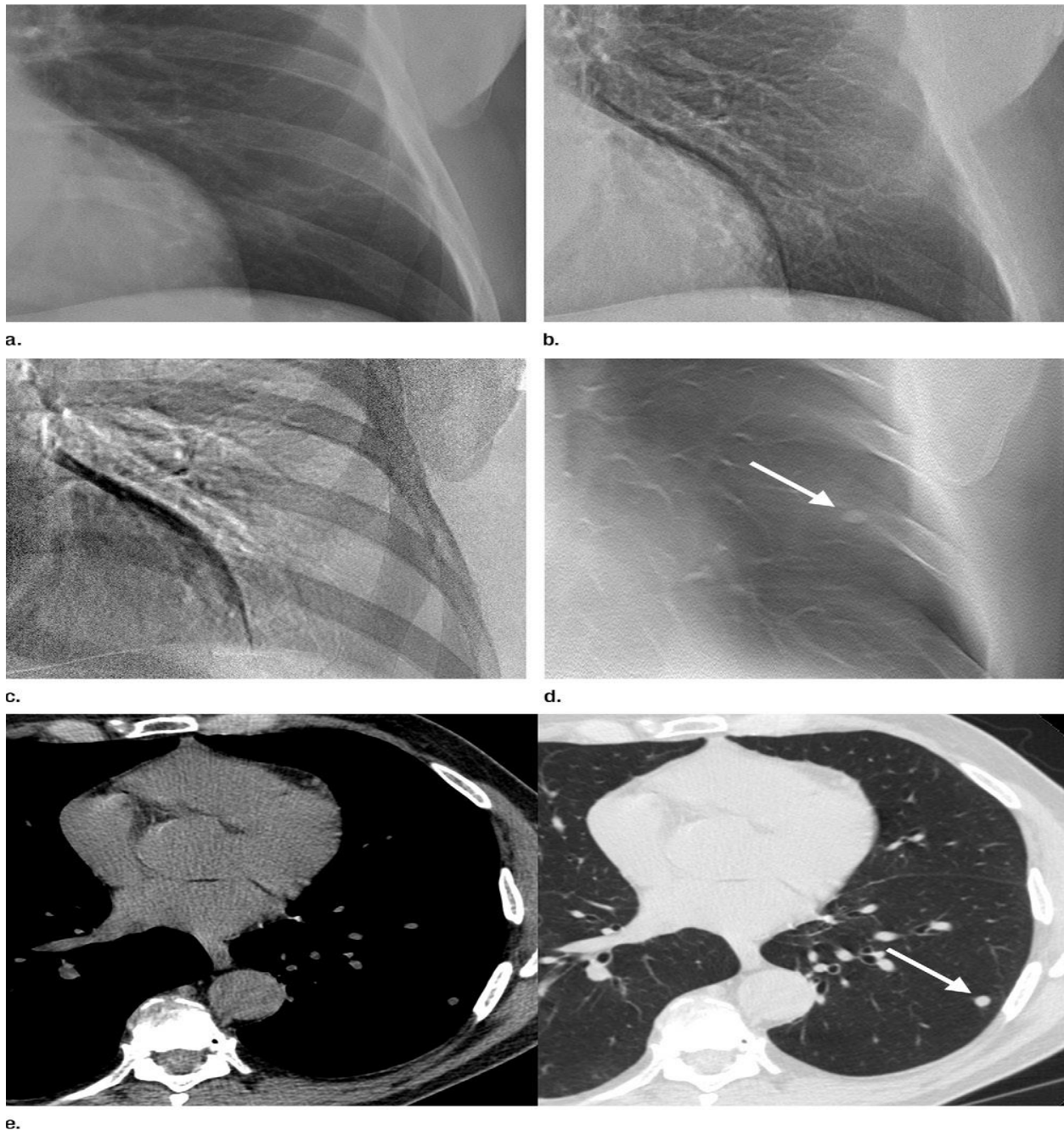


Figure 3:

**RESULTS:**

The number of apparent buttons in various width classifications for the truth table in CT pictures appears in Table 1. Of the 155 people, a total of 118 had at least one button, with the details index not showing 518. Considering the markings of the procedures considered in the photos, an average lesion limit mark of 0.408 (i.e., "true positive") per case was observed per pathological case and an average of

0.289 (i.e., "false positive") lesion limitation marks were observed, separately in the center of both care procedure combinations; There was no correlation between the ED elevation methods and the corresponding method without ED imaging, regardless of the method used (self-esteem was more remarkable than the Bonferroni correction, which was an incentive in all cases). For this reason, the results obtained will focus on the correlations between the CT



scan synthesis and the usual chest X-ray. The results for all buttons (3-27 mm) are summarized in Figure 1 and Table 2. The most extreme LLF was found to be 3.58 times higher ( $P = .001$ ), and the JAFROC FOM was 1.24 times higher ( $P = .001$ ) with CT synthesis than with the usual chest x-ray. Table 3 summarizes the results of the pain level tests as a function of button size. Per lesion has the best FOM in CT synthesis, which ranged from 2,14 times better ( $P,002$ ) with bumps larger than 8mm to 20mm to 7,50 times better

( $P, 0,002, P$ ) and pickles larger than 4mm to 6mm. The best FOM in all lesions was the traditional chest X-ray method. JAFROC FOM at button-level has been seen as a proportion of total accurate tomographic synthesis with buttons greater than 6 mm to 8 mm (1,16 times,  $P, 0,002$ ) and larger than 8 mm to 20 mm relative to traditional chest radiography (1.29 times,  $P, .002$ ). The affectability of the button position, which illustrates both the synthesis of the CT scan and the normal X-ray chest, is summarized in Figure 2.

Table 3 (continued)

## Summary of the Lesion-Level Results from FROC Data for Nodules in Different Size Ranges

Nodule Size Range and Modality	FOM values			Ratios of Lesion-Level Measures Derived from FROC Data								
	Maximum LLF	Maximum NLF	JAFROC	Maximum LLF			Maximum NLF			JAFROC		
				Conventional Chest Radiography	Conventional Chest Radiography	Tomosynthesis	Conventional Chest Radiography	Conventional Chest Radiography	Tomosynthesis	Conventional Chest Radiography	Conventional Chest Radiography	Tomosynthesis
				Plus DE Imaging	Plus DE Imaging	Plus DE Imaging	Plus DE Imaging	Plus DE Imaging	Plus DE Imaging	Plus DE Imaging	Plus DE Imaging	Plus DE Imaging
Tomosynthesis	0.438	0.124	0.685	2.14 (<.001)*	1.42	...	0.69	0.50	...	1.28 (<.001)*	1.24 (<.001)*	...
Tomosynthesis plus DE imaging	0.457	0.130	0.691	2.23 (<.001)*	1.48	1.04	0.73	0.53	1.05	1.29 (<.001)*	1.25 (<.001)*	1.01

Note.—Shown are the FOM values averaged over readers and the ratios of the FOM of the modality indicated by the row index, divided by that indicated by the column index. The  $P$  value display convention is the same as in Table 2.

\* Significant values (Individual comparison  $\alpha = .05/3 = .0033$ ).

Table 1:

## Summary Statistics for All Nodules Visible to the Truth Panel on CT Images

Size Range	No. of Normal Cases*	No. of Abnormal Cases	Maximum No. of Nodules per Abnormal Case	Mean No. of Nodules per Abnormal Case	Total No. of True Nodules
3–4 mm	67	91	12	2.5	224
>4 mm to 6 mm	83	75	10	2.5	186
>6 mm to 8 mm	112	46	4	1.4	64
>8 mm to 20 mm	123	35	3	1.2	42
3–20 mm	43	115	20	4.5	516

\* Case findings were considered "normal" for a given diameter range if there were no nodules of that size; however, the subject may have a nodule(s) of a different size.

Table 2:

## DISCUSSION:

In a randomized, monitored and provisionally scheduled study, consumers blinded to specific results of fact, this research was an interinstitutional and binational assessment of chest CT synthesis [6]. It involved a scheduled, all-embracing examination of the form and degree of clinical pimples, including

those not apparent in normal thorn X-rays (18,25) in a competent subject rather than just a presumptive pickle [7]. (18,25). Radiologists have also been included in this survey in more detailed planning than in other newly distributed studies, which have been used transcendentally by prepared chest radiologists [8]. Examining the effect from the use of the most sensitive

test (JAFROC FOM weighting) revealed that the involvement of thoracic radiologists and the absence of thoracic radiologists for any of the particular modalities was not in large contrast [9]. We have seen the usual outcome that prepared thoracic radiologists essentially beat non-thoracic radiologists just as measurement has been obtained in all modalities [10].

### CONCLUSION:

This analysis indicates that CT will enhance the detection of suction buttons and stress the choice of contrast plates in addition to standard chest X-rays as used in clinical radiology by experienced or untrained thoracic practitioners. These studies should expand the effects of past condensed compounds of which only radiologists have been used in the identification and diagramming of aspiration buttons in computed tomographic synthesis to recommend that a wide variety of clients have therapeutic significance.

### REFERENCES:

1. Quaia E, Baratella E, Cioffi V, et al. The value of digital tomosynthesis in the diagnosis of suspected pulmonary lesions on chest radiography: analysis of diagnostic accuracy and confidence. *Acad Radiol* 2010;17(10):1267–1274.
2. Jung HN, Chung MJ, Koo JH, Kim HC, Lee KS. Digital tomosynthesis of the chest: utility for detection of lung metastasis in patients with colorectal cancer. *Clin Radiol* 2012;67(3):232–238.
3. Yamada Y, Jinzaki M, Hasegawa I, et al. Fast scanning tomosynthesis for the detection of pulmonary nodules: diagnostic performance compared with chest radiography, using multidetector- row computed tomography as the reference. *Invest Radiol* 2011;46(8):471–477.
4. Quaia E, Baratella E, Cernic S, et al. Analysis of the impact of digital tomosynthesis on the radiological investigation of patients with suspected pulmonary lesions on chest radiography. *Eur Radiol* 2012;22(9):1912–1922.
5. Johnsson ÅA, Fagman E, Vikgren J, et al. Pulmonary nodule size evaluation with chest tomosynthesis. *Radiology* 2012;265(1):273–282.
6. Terzi A, Bertolaccini L, Viti A, et al. Lung cancer detection with digital chest tomosynthesis: baseline results from the observational study SOS. *J Thorac Oncol* 2013;8(6):685–692.
7. Quaia E, Baratella E, Poillucci G, Kus S, Cioffi V, Cova MA. Digital tomosynthesis as a problem-solving imaging technique to confirm or exclude potential thoracic lesions based on chest x-ray radiography. *Acad Radiol* 2013;20(5):546–553.
8. Lee G, Jeong YJ, Kim KI, et al. Comparison of chest digital tomosynthesis and chest radiography for detection of asbestos-related pleuropulmonary disease. *Clin Radiol* 2013;68(4):376–382.
9. Hwang HS, Chung MJ, Lee KS. Digital tomosynthesis of the chest: comparison of patient exposure dose and image quality between standard default setting and low dose setting. *Korean J Radiol* 2013;14(3):525–531.
10. Ishigaki T, Sakuma S, Ikeda M. One-shot dual-energy subtraction chest imaging with computed radiography: clinical evaluation of film images. *Radiology* 1988;168(1):67–72.