



Journal Homepage: - www.journalijar.com

INTERNATIONAL JOURNAL OF ADVANCED RESEARCH (IJAR)

Article DOI: 10.21474/IJAR01/11976

DOI URL: <http://dx.doi.org/10.21474/IJAR01/11976>



RESEARCH ARTICLE

OUTCOME OF SINGLE STAGE SPHINCTER SPARING SCARLESS (5S) PROCEDURE FOR RECTOVESTIBULAR FISTULA: A RETROSPECTIVE ANALYSIS

Muhammad Riaz-Ul-Haq¹, Muhammad Kashif Chishti², Arslan Raza Wasti³, Mazhar Jam⁴, Binish Naeem⁵ and Yasir Sultan⁶

1. Muhammad Riaz-ul-Haq, FCPS, FEBPS, Assistant Professor Paed. Surgery, AIMC and Jinnah Hospital Lahore.
2. Muhammad Kashif Chishti, FCPS, Professor of Paed. Surgery Children Complex Multan.
3. Arslan Raza Wasati, FCPS, HOD, Paed. Surgery, AIMC and Jinnah Hospital Lahore.
4. Mazhar Rafi, FCPS, Professor of Paed. Surgery, Sheikh Zayed Medical College Rahim Yar Khan.
5. Binish Naeem, PGR, Paed. Surgery, Jinnah Hospital Lahore.
6. Yasir Sultan, PGR, Paed. Surgery, Jinnah Hospital Lahore.

Manuscript Info

Manuscript History

Received: 01 September 2020

Final Accepted: 05 October 2020

Published: November 2020

Key words:-

Imperforate Anus, Rectovestibular
Fistula, Anorectal Malformation,
Female, Sphincter Sparing

Abstract

Background: Anorectal malformations (ARM) in girls comprise of a wide spectrum of disease ranging from imperforate anus to common cloaca, a complex malformation. Recto-vestibular fistula (RVF) is the commonest ARM in female patients. Many surgical procedures have been mentioned in the literature but trend is changing from staged to single stage procedure.

Objectives: To evaluate post operative results of Single Stage Sphincter Sparing Scarless (5S) procedure for RVF.

Methods: It is a retrospective case series of 24 patients with RVF who were admitted in the Department of Paediatric Surgery Jinnah Hospital Lahore and the Children Hospital and the Institute of Child Health Multan from October 2018 to September 2019, between 14 days and 4 years of age, underwent single stage sphincter sparing scarless procedure without any colostomy, anterior or posterior midline incision or division of sphincteric complex. Site of neo-anus was marked with the help of muscle stimulator and all surgeries were done under general anesthesia after meticulous gut preparation. Post operatively patients were kept nil per oral for 5 days to avoid wound contamination due to stool. Follow up was done for six months to evaluate outcome. Authors used a new name for single stage procedure.

Results: Mean age was 160 days, operative time 78 minutes and hospital stay 6.8 days. 9 (37.5%) patients were diagnosed with some other associated congenital anomalies like congenital heart disease (CHD), renal anomalies, hemisacrum, syndactyly, talipes equinovarus (TEV) and Down's syndrome. As a whole 13(24) presented with complication. 4(16.64%) patients presented with constipation, 3(12.5%) excoriation, 2(8.32%) anal stenosis, 2(8.32%) soiling, 1(4.16%) retraction of rectum and 1(4.16%) superficial wound infection. Patient with retraction was planned for re-do surgery, all others were managed conservatively.

Corresponding Author:- Muhammad Riaz-Ul-Haq

Address:- Muhammad Riaz-ul-Haq, Assistant Professor Paed. Surgery, AIMC and Jinnah Hospital Lahore.

Conclusion: Single stage sphincter sparing scarless (5S) procedure for recto-vestibular fistula is safe, simple and cost effective technique. Patient suffering is minimum, as there is no colostomy, so no multiple surgeries. Complications are minimum and comparable to staged procedure.

Copy Right, IJAR, 2020.. All rights reserved.

Introduction:-

Recto- vestibular fistula (RVF) is one of the commonest anorectal malformation (ARM) among the whole spectrum of the disease in female patients. In this anomaly rectum opens just behind the posterior wall of vagina in the vestibule in such a way that it gives impression of a common wall between vagina and rectum [1]. Most reports categorise RVF as a low anomaly; but Heinen has mentioned RVF as an intermediate anomaly [2]. Many operative techniques have been described for its correction including cutback, anal transpositioning [3], posterior sagittal anorectoplasty (PSARP), and anterior sagittal anorectoplasty (ASARP), in which the external anal sphincter is cut but puborectalis sling is not disturbed [4- 5]. There are some other techniques like neutral sagittal anorectoplasty (NSARP) and transfistula anorectoplasty (TFARP) [5]. Wang et al. mentioned modified ASARP with the use of endoscopic visualization to avoid damaging the external anal sphincter [6]. In spite of better understanding of the knowledge of embryology, the anatomy and the physiology of continence mechanism and minimum dissection for keeping mechanism of continence intact by sparing pelvic nerves and pulling the rectum through muscles of continence, management of RVF is challenging and has a number of complications [6]. The need for a covering colostomy during definite repair of RVF has a long debate in the literature. On one hand, one stage repair for RVF (without colostomy) has been accepted by many surgeons as a well recognized procedure in the management of RVF, especially in neonates where a single stage operation is with minimal complications.[7,8]. Some people are in favour of two stage repair (with colostomy) to minimize the wound related complications that may compromise the ultimate functional outcome [9]. According to some other surgeons three-stage operations are of immense disadvantage to the patients and their parents. The cost is remarkable and the rate of complications is considerable. A number of complications due to colostomy done during infancy have been discussed in the literature. [10]. The aim of present study was to evaluate the results of Single Stage Scarless Sphincter Sparing (5S) procedure for rectovestibular fistula in which perineal body, perineal skin and sphincters were kept intact with an aim to improve the cosmetic and functional outcome.

Methods:-

Authors 1st time introduced name of the procedure as **5S procedure** for RVF. A combined retrospective analysis was carried out at the Department of Paediatric Surgery Jinnah Hospital Lahore and the Children Hospital and the Institute of Child Health Multan. The medical records of 31 cases of female patients with anorectal malformations, admitted between October 2018 and September 2019, were reviewed retrospectively. Seven patients were excluded from the study who either underwent staged repair due to complex anorectal anomalies or very stenotic anal opening, massive distension of abdomen due to severe constipation or other severe congenital malformations. 24 patients in total with RVF from both hospitals between 14 days and 4 years were included in this study who underwent single stage sphincter sparing scarless (5S) procedure and were not operated before with respect to anorectal malformation. Detailed history and clinical examination was carried out including the perineum, buttocks, spine and other systems for associated anomalies. An informed written consent for primary single stage procedure was taken. Approval was taken from ethical committee. Routine investigations like complete blood count, serum electrolytes, renal function tests, bleeding and clotting profiles, blood grouping and cross matching, ultrasonography of abdomen especially KUB, and pelvic organs were carried out. Special investigations like Echocardiography and X-ray spine were also done. All the patients were prepared preoperatively. The rectal irrigation by normal saline was started 48 hours before surgery and continued till effluent came clear or light pale and clear fluids were started at the same time. All patients were kept NPO on intra venous (IV) fluids 6 hours before surgery while broad spectrum IV antibiotic with metronidazole were given 15 minutes before induction of anaesthesia.

Surgical technique for 5S Procedure:

Surgery was carried out under general anaesthesia a caudal block was given at the end. Urinary bladder was catheterized and lithotomy position was done. An expected anal site was determined by the anal dimple and a muscle stimulator was used to check the contractions of sphincters, and neoanal site was marked with the help of a

colored marker. Traction sutures were placed around the fistula in the vestibule. Dilute (0.001%) adrenaline solution was injected under the Mucosal layer of the fistula to separate it from the rectovaginal common wall and to decrease bleeding. A needle tip cautery was used to dissect the fistula, first of all posterior wall of rectum was dissected, then lateral and at the end two walls were created from common rectovaginal septum up to the cervix anteriorly and up to the sacral promontory posteriorly [Fig 2,3]. No incision was made over the perineum and perineum was kept intact. At the site for neo-anus which was previously marked with the help of muscle stimulator a vertical skin incision was given according to the available area depending upon age. Incision was deepened bluntly without cutting any muscle, through which mobilized rectum was pulled [Fig 4]. The narrow distal end of the rectum was trimmed and fixed to the deep muscle complex, with vicryl Anoplasty was carried out with with vicryl 4/0 [Fig 5]; the neoanus patency was checked with Hegars dilator according to age. The dissected site of RVF was closed in layers with vicryl interrupted stitches. Antibiotic lubricated gauze was packed in the rectum after surgery and was removed the very next day.

Figure 1:- Imperforate anus with rectovestivular fistula.

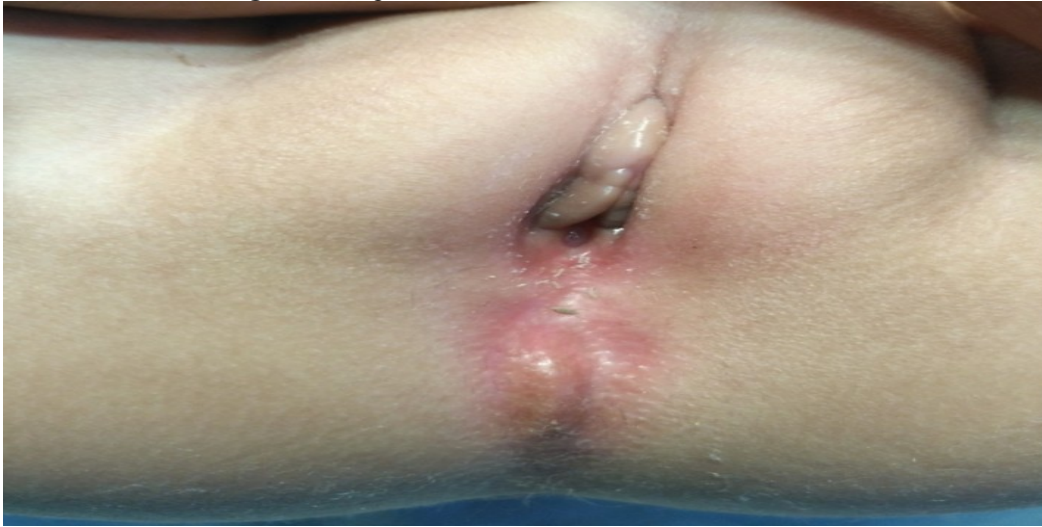

Figure 2:- Mobilization of fistula by putting sutures all around for traction.

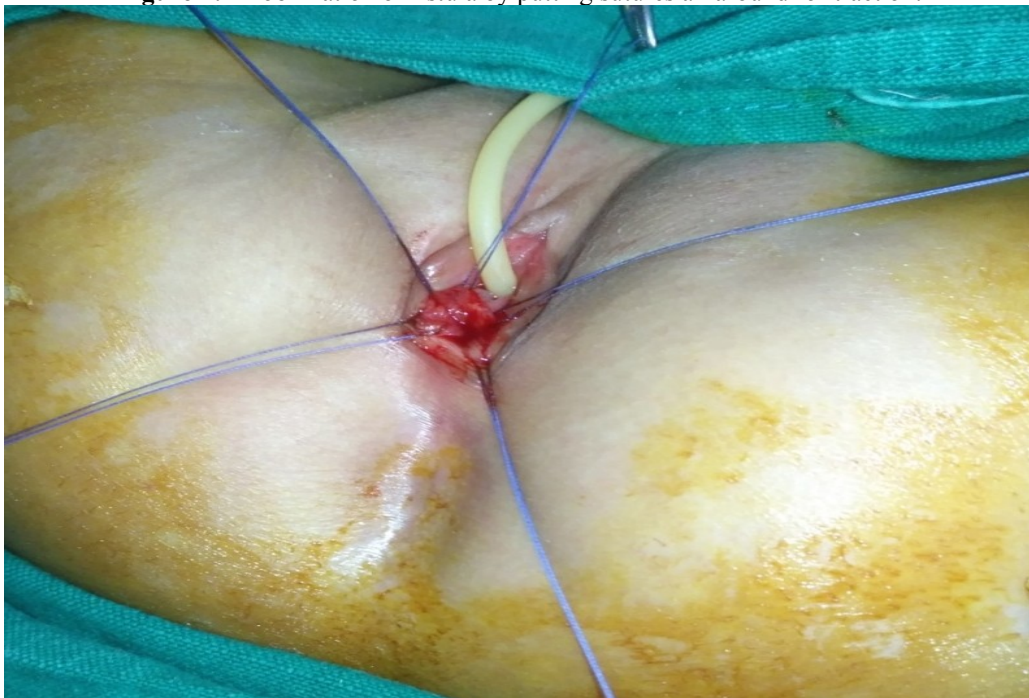

Figure 3:- Rectum was mobilized, and separated from vagina. Midline incision at proposed anus sit.

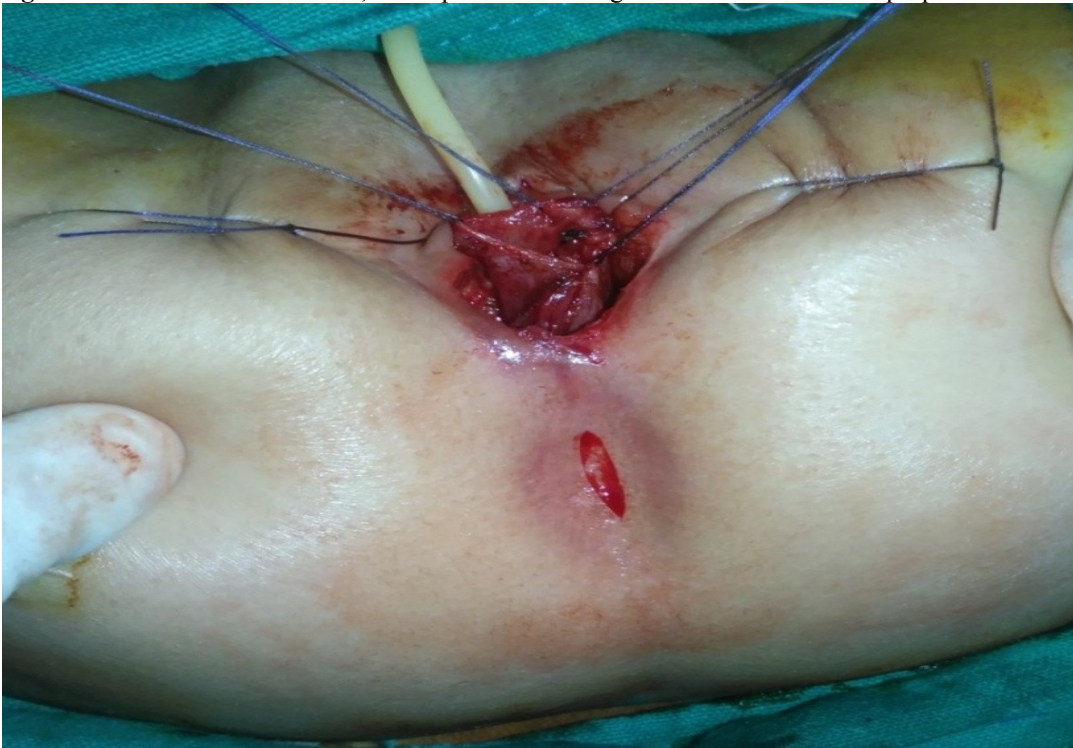


Figure 4:- Rectum was pulled through sphincteric complex and anoplasty done.

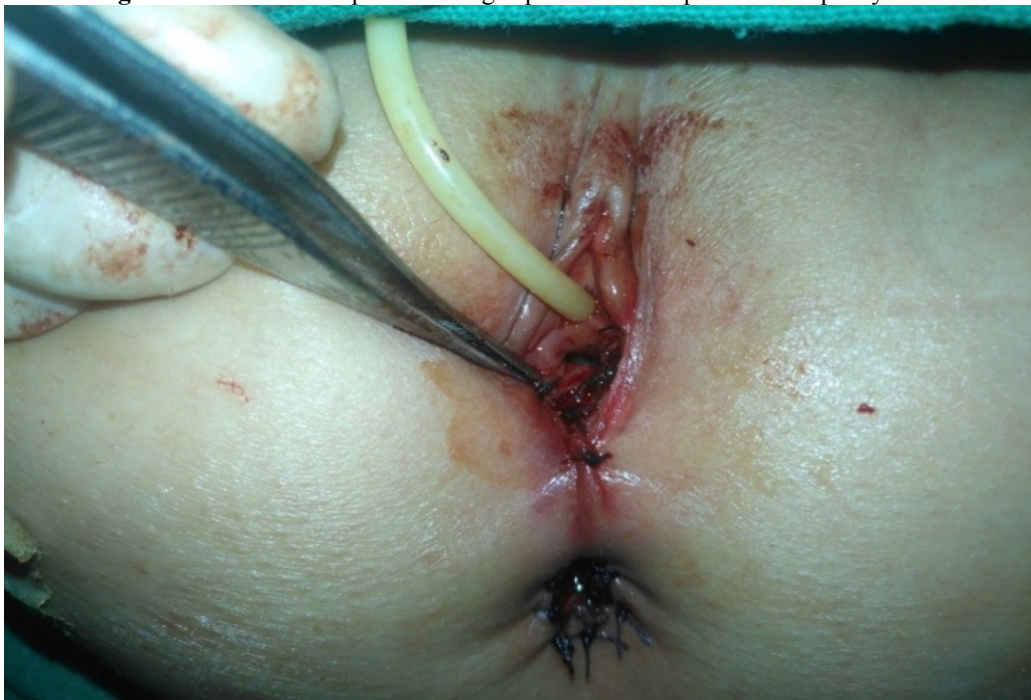
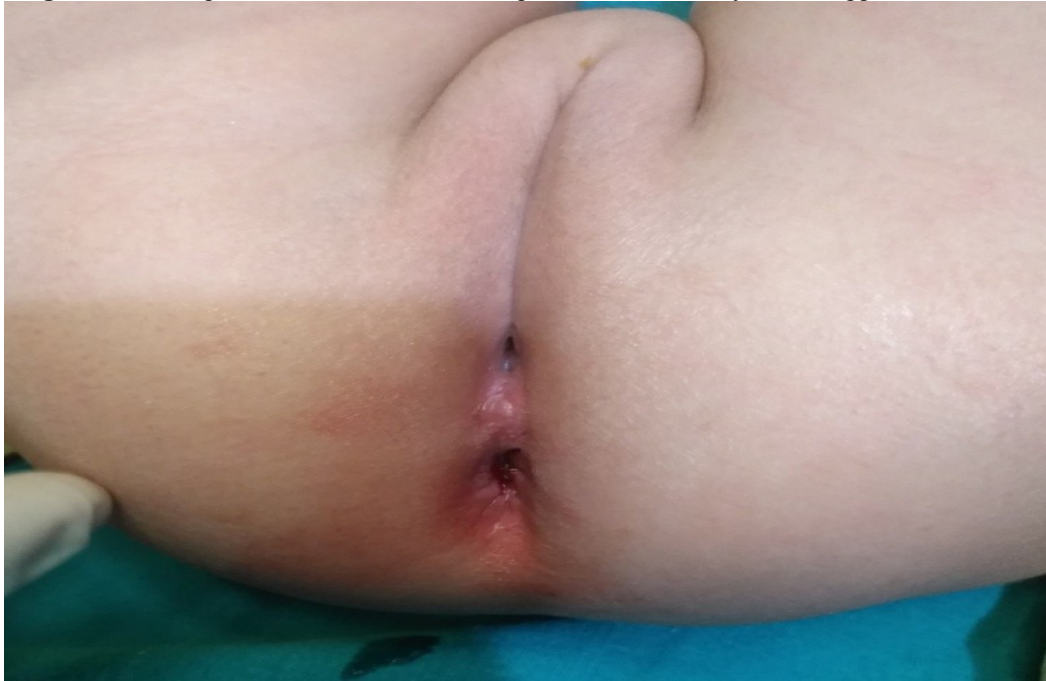
Figure 5:- Post operative view shows scarless perineum with nearly normal appearance of anus



Postoperative care:

We kept our all patients NPO for 5 days. Mothers were strictly forbidden to give any thing per oral. Intravenous antibiotics were continued for 5 days after surgery. On second postoperative day partial parenteral solution was started and continued till the patient started taking oral. Foley's catheter was removed on 5th post operative. The mothers were taught wound care to clean the newly constructed anal area with pyodine many times a day. Most of our patients were discharged on 6th or 7th post operative day until or unless some complication needed more care. 1st follow up was started on 14th post-operative day. Anal dilatation with Hegar's dilators was started and taught to the parents to dilate twice a day for one month, once a day for one month, twice a week for one month, once a week for one month, and then once a week for three months.

Patients were followed for six months, fortnightly twice and then monthly for 5 months. Patients were evaluated and observed for cosmetic appearance of perineum, location and size of anus and perianal excoriation. Continence was assessed by finger squeeze and anal contractions on perianal stimulation under 3 years while in toilet trained children voluntary bowel movements were assessed by feeling of urge, capacity to verbalize and hold the bowel movements. Statistical analysis was performed using SPSS Version 20. Quantitative data was shown as mean \pm standard deviation. Student t test was performed and bias was set at $p < 0.05$ with confidence rate of 95%.

Results:-

A total of 24 patients were included in this study from two hospitals after excluding 7 patients. Mean age at the time of surgery was 160 days (range, 14days to 4years). 9 patients (37.5%) had associated anomalies, 3(12.5%) had congenital heart disease (VSD=2, ASD=1), 1(4.16%) hemisacrum and syndactyly, 4(16.64%) renal anomalies (Single kidney 1, Mild hydronephrosis 2, VUR 1), and 1(4.16%) Down Syndrome and Right talipes equinovarus [Fig 6]. Mean operative time was 78 minutes (range 70-90). Patients were passing stool 3-6 times per day after operation. Postoperative hospital stay was 6-9 days (mean 6.8days). Most of the patients started passing stool 3-4 days after surgery. With regards to complications 1(4.16%) patient developed superficial wound infection in vestibular area but was successfully managed with local wound care, 2(8.32%), presented with soiling but improved after 4-5 months without any specific treatment, 3(12.5%) had multiple episodes of perianal excoriation in the beginning. They were all below six month of age. Local treatment was given for excoriation which settled with decreased number of stools. The most common postoperative complication seen in follow up was constipation in 4(16.64%) but managed easily with laxatives and occasional saline enema. 2(8.32%) patients presented with anal stenosis and managed with scheduled and proper dilatation, 1(4.16%) could not do dilatation and examination under anesthesia showed retraction of rectum, so was planned re-do surgery through posterior sagittal approach [Table 1]. Cosmetic

appearance of perineum , shape size and location were excellent in all patients [Fig 5]. Anal contractions on perianal stimulation and finger squeeze were also up to the mark in children below 3 years and most of the patients above three years were toilet trained with no evidence of incontinence.

Figure 6 Associated Anomalies

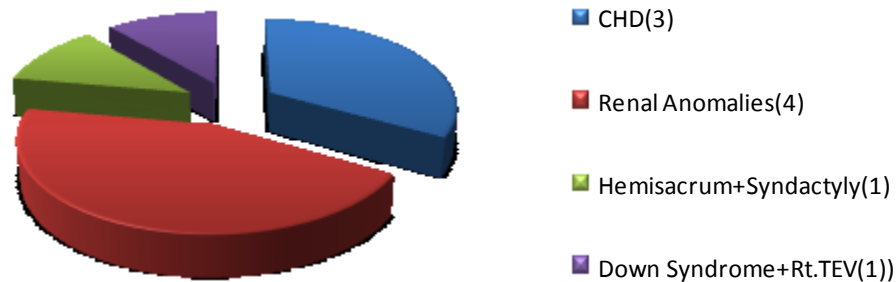


Table 1:- Complications n=24.

	Number	%age
Infection	1	(4.16%)
Anal Stenosis	2	(8.32%)
Retraction	1	(4.16%)
Soiling	2	(8.32%)
Excoriation	3	(12.48%)
Constipation	4	(16.64%)

Discussion:-

In anorectal malformations surgery continence is main concern that is why due to fear of wound infection and in result, loss of sphincteric complex with risk of future incontinence, traditionally ARMs were repaired with a protective colostomy. The role of a protective colostomy in prevention of wound infection is questionable [11]. Historical teaching to repair RVF by Pena is under cover of diverting colostomy [12]. The main benefits of doing anorectoplasty without a covering colostomy are the avoidance of stoma related complications and multi-staged surgeries [13]. Literature review shows that the somato-sensory input from the perianal area which helps in the mechanism of continence, is lost if not used for more than a few months in infancy. If early surgery is performed the perineal musculature is trained early, and neuronal networks may be formed which may increase the chances of normal or near normal anorectal functions [14]. Early restoration of gastro-intestinal continuity is very important to establish the coordinated defecation reflexes early [15]. As there is no skin incision in 5S procedure anterior or posterior to neo-anus, it has excellent cosmetic results and the chances of wound dehiscence and infection are minimum [7]. The mechanism of continence remains intact as skin in the midline, and all muscles of continence are kept intact without any incision. Cosmetically perineum looks scarless.

In present study age range was 14 days to 4 years, mean 160days. Most of the studies showed early repair in neonates or infancy, as Khan JG et al [16], mentioned mean age 2.79±2.9 months (range 1-12). We received most of the patients beyond neonatal age due to ignorance, illiteracy and poor social background. Our mean operative

time was 78 minutes (range 70-90). It is comparable to Akshay P et al [17]. Their mean operation time was 85 minute.

In a number of studies of single-stage sphincter sparing surgery, rate of wound infection ranged from 0% [18]) to 5.7%-10.6% [14]. In our series, the wound infection rate was 4.16% (1 case). It is the beauty of 5S procedure as there is no long incisions or skin cutting, so chances of infection are minimum.

3(12.48%) of our 24 patients suffered from anal stenosis, most of them did not follow instructions about dilatation in post operative period. In 2 of them dilatation was done under G/A and in one in OPD . Later on they did well after dilatation at home as advised according to Pena's schedule. Rate of anal stenosis mentioned by Khalifa M et al [9], was 10.9%. Nearly 40% patients of low variety anorectal malformations present with constipation as high variety patients have more chances of incontinence [2,20]. 4(16.64%) of our patients presented with constipation in follow up . All of them were managed with fiber diet and laxatives. In 25.68% of patients in Kumar et al series suffered from constipation and were treated by saline enema, stool softeners and dietary manipulation. They also did manual disimpaction in some patients [21]. Kuijper and Aronson mentioned constipation in 34% of patients who remained on regular stool softeners and/or enema [22]. In one of our 24 patients retraction of rectum occurred . We tried dilatation under G/A but failed ,so he was planned for re-do surgery through posterior sagittal approach. Rectal prolapse and retraction has been mentioned in literature as one of the complications of this procedure if rectum was not mobilized properly or not fixed with sphincter complex [23]. Excoriation and soiling , 3(12.48%) and 2(8.32%) respectively were also noted in our patients. 2 patients of excoriation were less than three months of age and due to bouts of diarrhea they got excoriation which settled after local antifungal and steroid treatment. Out of two with soiling, one also had excoriation. Both patients of soiling were having constipation. They settled with bowel management. Soiling and excoriation has also been mentioned by some other authors after single stage repair [24,25]. Some series reported that approximately 90% of patients with corrected RVF will develop normal continence by the age of 3 years and problem of soiling and excoriation settles down [26].

Conclusion:-

Single Stage Sphincter Sparing Scarless (5S) procedure is easy to perform, operative time is acceptable and has excellent cosmetic and functional results. Muscle stimulator should be used to mark the exact site of muscle contraction for the neo-anus. Separation of rectum from vagina is a delicate step anteriorly, must be performed with great care so that vagina is not injured. 5S procedure is single stage, cost effective and there are no much sufferings due to colostomy. It can be performed in neonates, infants and children with good results. Minor complications like constipation or anal stenosis are manageable without any re-do surgery.

Acknowledgement:-

Authors are thankful to all junior and senior staff who helped in completion of this article.

References:-

- 1-Wakhlu A, Pandey A, Prasad A, Kureel SN, Tandon RK, Wakhlu AK. Anterior sagittal anorectoplasty for anorectal malformations and perineal trauma in the female child. J Pediatr Surg 1996;31:1236-40.
2. Heinen FL. The surgical treatment of low anal defects and vestibular fistulas. Semin Pediatr Surg 1997;6:204-16
3. .3. Eltayeb A. The anterior sagittal anorectoplasty for the treatment of anovestibular fistula in newborn and children. Ann Pediatr Surg 2008;1:18-21.
4. Okada A, Kamata S, Imura K, Fukuzawa M, Kubota A, Yagi M, et al. Anterior sagittal anorectoplasty for recto-vestibular and anovestibular fistula. J Pediatr Surg 1992;27:85-8.
5. Elswaf MI, Hashish MS. Anterior sagittal anorectoplasty with external sphincter preservation for the treatment of recto-vestibular fistula: A new approach. J Indian Assoc Pediatr Surg 2018;23:4-9.
6. Wang C, Li L, Liu S, Chen Z, Diao M, Li X, et al. The management of anorectal malformation with congenital vestibular fistula: A single.stage modified anterior sagittal anorectoplasty.Pediatr Surg Int 2015;31:809.14.
7. Pratap A, Yadav RP, Shakya VC, Agrawal CS, Singh SN, Sen R. One-stage correction of recto-vestibular fistula by trans-fistula anorectoplasty (TFARP). World J Surg 2007;31:1894-7
8. Abdelmohsen SM, Osman MA, Abdul Raheem OA, Abdulmotaleb HM, Abdelmohsen BM Trans-sphincteric anorectoplasty for rectovestibular fistula, JCMRO, 2017; 1(1) :1-11

9. Khalifa M, Shreef K, Al Ekrashy MA, Gobran TA. One or Two Stages Procedure for Repair of Rectovestibular Fistula: Which is Safer? (A Single Institution Experience). *Afr J Paediatr Surg* 2017;14:27-31.
10. Loulah MA, Sultan TA, Zeina WO. Primary versus multistage repair of congenital rectovestibular fistula. *Menoufia Med J* 2015;28:813-7
11. Caroline F, Aronson DC. Anterior or posterior anorectoplasty without colostomy for low type anorectal malformation: how to get a better outcome? *J Pediatr Surg*. 2010; 45: 1505-8.
12. Pena A. Imperforate anus and cloacal malformations. In: Keith W Ashcraft, editor. *Pediatric Surgery*. 3rd ed. Philadelphia: W.B. Saunders Company; 2000; p. 473-92.
13. Pena A, Migotto-Krieger M, Levitt MA. Colostomy in anorectal malformations: a procedure with serious but preventable complications. *J Pediatr Surg*. 2006; 41:748–56.
14. Mitul AR, Ferdous KMN, Shahjahan M, Khan JG. Trans-fistula anorectoplasty (TFARP): our experience in the management of anorectovestibular fistula in neonates. *J Neonat Surg* 2012; 1: 36.
15. Dave S, Shi EC. Perineal skin bridge and levator muscle preservation in neutral sagittal anorectoplasty (NSARP) for vestibular fistula. *Pediatr Surg Int* 2005;21:711-4.
16. Khan JG, Ali MA, Yusuf MA, Islam MK, Rahaman MA, Hasina K et al. Transfistula Anorectoplasty (TFARP): Better Surgical Technique for the Management of Vestibular Fistula *J Shaheed Suhrawardy Med Coll*, 2012;4(1): 10-14
17. Akshay P, Yadav RP, Shekhar VC, Singh A, Sen R . One stage correction of Rectovestibular fistula by transfistula anorectoplasty. *J World surg* 2007; 31(9):1-3
18. Upadhyaya VD, Gangapadhyay AN, Pandey A, Kumar V, Sharma SP, Gopal SC, et al. Single-stage repair of rectovestibular fistula without opening the fourchette. *J Pediatr Surg* 2008; 43: 775-9.
19. Humam S. Alkhaffaf. Experience of Transfistula (TFARP) Repair for Congenital Recto-Vestibular Fistula. *Global Journal of HUMAN SOCIAL SCIENCE: I Surgeries and Cardiovascular System Volume 14 Issue 2 Versions 1.0 Year 2014*.
20. Rintala RJ, Lindahl HG, Rasanen M. Do children with repaired low anorectal malformations have normal bowel function? *J Pediatr Surg* 1997;32:823-6.
21. Kuijper CF, Aronson DC. Anterior or posterior sagittal anorectoplasty without colostomy for low-type anorectal malformation: How to get a better outcome? *J Pediatr Surg* 2010;45:1505-8.
22. Kumar B, Kandpal DK, Sharma SB, Agrawal LD, Jhamariya VN. Single-stage repair of vestibular and perineal fistulae without colostomy. *J Pediatr Surg* 2008;43:1848-52.
23. Wakhlu A, Kureel SN, Tandon RK, Wakhlu AK. Long-term results of anterior sagittal anorectoplasty for the treatment of vestibular fistula. *J Pediatr Surg* 2009;44:1913-9.
24. Radi Awad Elsherbini., et al. “Single Stage Repair of Rectovestibular Fistula in Neonates: Indications and Outcome”. *EC Paediatrics* 8.4 (2019): 268-274.
25. Holschneider AM. Secondary sagittal posterior anorectoplasty. *Prog Pediatr Surg* 1990;25:103-17.
26. Peña A, Hong A. Advances in the management of anorectal malformations. *Am J Surg* 2000;180:370-6.