

STUDY OF ANTI-INFLAMMATORY EFFECT OF CONCENTRATED JUICE AND GRANULES FROM *VACCINIUM OXYCOCCOS* FRUITS ON THE MODEL OF BACTERIAL CYSTITIS IN RATS

Kateryna Yatsyuk

Department of Organization and Economics of Pharmacy and Drug Technology¹
yatsina_katya@i.ua

Mariana Fedorovska

Department of Organization and Economics of Pharmacy and Drug Technology¹
maryana@fedorovska.com

Olga Antymis

Department of Human Anatomy¹
antimis2012@gmail.com

¹*Ivano-Frankivsk National Medical University*
2 Halytska str., Ivano-Frankivsk, Ukraine, 76018

Abstract

The fruits of marsh cranberries due to the content of phenolic compounds, in particular proanthocyanidins, are effective in the prevention and treatment of cystitis [1].

The aim of the research was to study the anti-inflammatory properties of condensed juice of *Vaccinium oxycoccos* fruits and granules «Cranberry» in a model of acute bacterial cystitis in rats.

Materials and methods. The anti-inflammatory properties of condensed juice from *Vaccinium oxycoccos* fruits and granules «Cranberry» were studied in a model of acute bacterial cystitis in rats, which was caused by three daily transurethral injection into the bladder of 0.3 ml of *E. coli* strain at a concentration of 10⁶ CFU/ml. «Canefron® H» was used as a reference drug. Tissues were studied histologically by assessing the structure of the bladder wall and the condition of blood vessels.

Results. Infection of animals with *E. coli* resulted in a significant increase in the desquamation of the transitional epithelium, edematous changes and narrowing of blood vessels in the tissues of the bladder wall. During treatment with the drug «Canefron® N» there was a decrease in cell infiltration and desquamation of cells, dilation of blood vessels. When animals used condensed juice from *Vaccinium oxycoccos* fruits and granules «Cranberry» in the histological picture of the walls of the bladder there was a decrease in desquamation, edema and cellular infiltration, the lumen of blood vessels was approaching normal.

Conclusions. The use of condensed juice from *Vaccinium oxycoccos* fruits and granules «Cranberry» was accompanied by a positive effect on the tissues of the walls and blood vessels of the bladder of rats (there was a decrease in desquamation of the superficial layers of the transitional epithelium and normalization of the histological picture of vascular entanglement, that was not inferior to the comparison drug «Canefron® N»).

Keywords: *Vaccinium oxycoccos*, condensed juice, granules, acute bacterial cystitis, anti-inflammatory properties.

DOI: 10.21303/2504-5679.2020.001505

1. Introduction

Urinary tract infections (UTI) are among the most common infectious diseases in the world, often occurring in relatively healthy people [2]. At the same time, there is a high rate of recurrence – in 30–40 % of patients who underwent UTI [3]. The main pathogens of UTI in 80 % of cases are *Escherichia coli* and in 15 % of cases *Proteus spp.*, *Pseudomonas aeruginosa*, *Staphylococcus aureus*, *S. typhimurium*, *Enterococcus faecalis* [4–10]. The basic drugs for the treatment of patients with UTI are antibiotics and uroantiseptics (derivatives of 8-oxyquinoline, 5-nitrofurantoin, etc.) [11, 12]. For the prevention of UTI, the European Association of Urologists recommends the daily use of *Vaccinium oxycoccos* with a content of proanthocyanidin A 36–72 mg per day [13–15]. To ensure a daily therapeutic dose, it is necessary to consume from 0.5 liters of fresh juice per day,

which causes some difficulties (unpleasant organoleptic properties, irritation of the gastrointestinal tract, the dependence of raw materials on the season) [16].

Given the above, it is important to develop dosage forms from the juice of *Vaccinium oxycoccos* fruits, such as condensed juice and granules based on it. These funds have a number of advantages, namely: they are characterized by a concentrated content of proanthocyanidins, easy to use, available regardless of the season of harvesting.

The aim of the research was to determine the anti-inflammatory properties of condensed juice from *Vaccinium oxycoccos* fruits and granules «Cranberry» in a model of acute bacterial cystitis in rats.

2. Materials and methods

An experiment to determine the anti-inflammatory properties of condensed juice and granules «Cranberry» [17–19] was conducted in May 2018 on the basis of the laboratory of practical pharmacy No. 3 of the Department of Organization and Economics of Pharmacy and Drug Technology and scientific laboratory of morphological analysis of Ivano-Frankivsk National University. All studies were conducted in accordance with EU Directive 2010/63/EU on the protection of animals used for scientific purposes [20], complied with the recommendations of ARRIVE [21], as confirmed by the expert opinion on ethics of Ivano-Frankivsk National Medical University on ethical principles in performance of candidate dissertations (protocol No. 113/20 from 12.03.2020).

The experiment was performed on 30 outbred white male rats weighing 200–250 g, which were divided into 5 groups of 6 animals [22]. The first group of animals (healthy rats) was used to determine the histological structure of the walls and blood vessels of the bladder in normal. Other experimental animals simulated acute bacterial inflammation of the bladder by three daily transurethral injections into the bladder of 0.3 ml of suspension of uropathogenic clinical strain of *E. coli* (isolate from a patient with recurrent cystitis) at a concentration of 10^6 CFU/ml. The process of infection of the rat with the pathogen is shown in **Fig. 1**. The second group of animals was left untreated. The third group was treated for acute cystitis by daily oral administration of the drug «Canefron® N», which has proven effectiveness in the treatment of infectious diseases of the urinary tract in the form of drops at the rate of 2 drops per day [23]. In the fourth group of animals, treatment was performed with condensed juice of *Vaccinium oxycoccos* fruit, administered to rats orally at the rate of 0.01 g per day. The fifth group was treated with «Cranberry» granules, administered orally to animals at a rate of 0.06 g per day. Doses of the studied drugs were calculated taking into account the quantitative content of proanthocyanidins [18, 19]. Animals before and after the experiment were kept in a specially equipped room, which is well ventilated, well lit, at a temperature of +20 °C–+22 °C, humidity did not exceed 50 %, without restrictions in drinking water. The animals lived in cages of the single-tier type with a front wall made of metal mesh. They were well equipped with natural and artificial lighting.

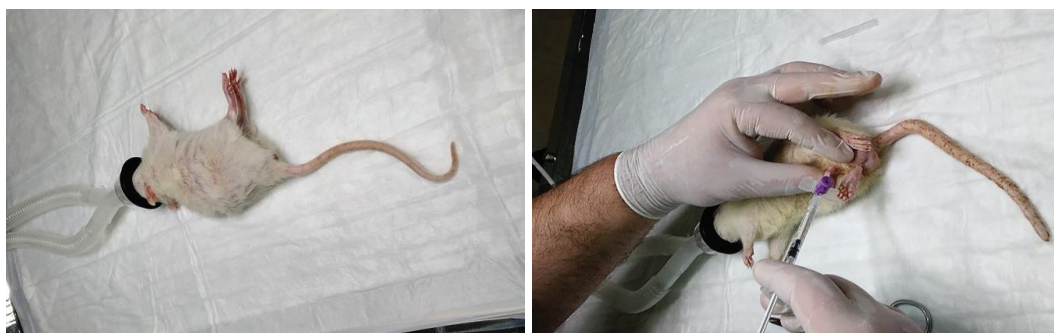

Fig. 1. Introduction of inhalation anesthesia and simulation of bacterial cystitis in rats by introduction of *Escherichia coli* into the bladder

Animals were removed from the experiment on the 14th day. Euthanasia was performed in accordance with bioethical standards (after previous thiopental-sodium anesthesia at the rate

of 60 mg·kg⁻¹ body weight of animals intraperitoneally). The collected material (bladder) was fixed for 14 days in a 10 % solution of neutral formalin (pH-7.0), and then carried out to paraffin blocks according to conventional methods [23]. Sections with a thickness of 5–8 μm were obtained, followed by staining with hematoxylin and eosin.

3. Research results

The main results of the research are presented in **Table 1**.

Fig. 2 shows the bladder wall of a healthy rat with a single physiological process of desquamation.

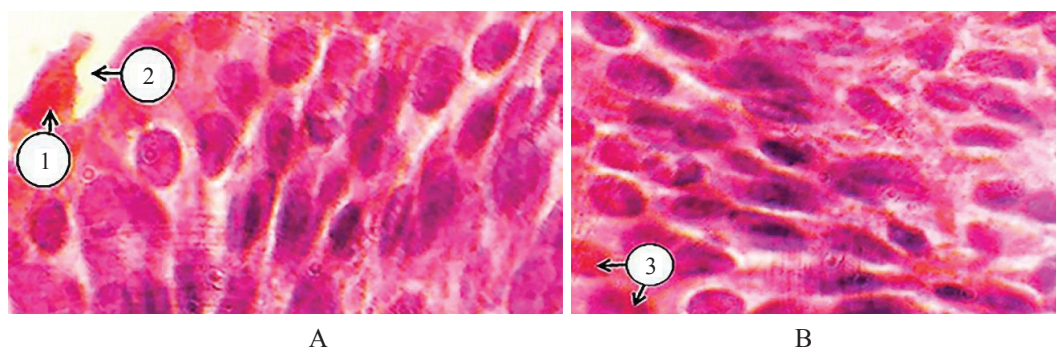


Fig. 2. Physiological desquamation (A) and umbrella cells in the transitional epithelium of the mucous membrane of the bladder wall of rats were normal (B). Hematoxylin and eosin staining. Photomicrograph. Magnification: eyepiece 20, lens 40. Designation: 1 – urotheliocyte, which will exfoliate; 2 – free area after desquamation of the cell; 3 – mononuclear umbrella cells

Table 1

Changes in bladder tissues observed during *Escherichia coli* infection and treatment with «Canefron® N», condensed fruit juice from *Vaccinium oxycoccos* and «Cranberry» granules

Group of animals	Examination of the bladder wall			Blood vessels
	Mucous membrane	Muscle membrane	Outer shell	
1	2	3	4	5
Healthy animals	Loose connective tissue, which contains fibrocytes, fibroblasts, lymphocytes, macrophages and mast cells between the bundles of collagen fibers. The process of single desquamation is physiological	Three-layer outer and inner layers – longitudinal smooth muscle fibers and the middle layer – circular	Constructed fibrous connective tissue with a small amount of elastic fibers. At the apex and most of the anterior and posterior walls of the bladder, the outer shell is serous and consists of flat polygonal mesothelial cells with intensely stained nuclei.	Blood vessels are normal
Animals with simulated bacterial inflammation without treatment	Significant increase in desquamation of the transitional epithelium, especially umbrella cells, urotheliocytes of the intermediate and basal layers. In some areas it is possible to note total desquamation of urotheliocytes of a transitional epithelium, the basal membrane is exposed. There are wedge-shaped ruptures of the urothelium, which in some places reach the intermediate and basal layer	Significant edematous changes, characterized by an increase in the size of the nuclei and enlightenment of the cytoplasm. Significant expansion and enlightenment of the intercellular space due to its edema and defibering of connective tissue fibers	Significant cellular infiltration is noted	The lumen of the arterioles is narrowed, the walls are swollen. Dilatation of venules with a thinned wall is observed

Continuation of the Table 1

1	2	3	4	5
Animals with simulated bacterial inflammation after treatment with the drug «Canefron® N»	Umbrella cells and cells of the intermediate layer are mainly subjected to desquamation. Basal layer cells without changes. There are shallow wedge-shaped ruptures of the urothelium, which in some places reach the intermediate layer	In smooth myocytes there are insignificant edematous changes and expansion of intercellular space. In some areas of the muscular membrane, a significant decrease in the size of the connective tissue intercellular space, which may be caused by diffuse fibrosis of the wall	There is a decrease in cellular infiltration	The lumen of the arteries is narrowed, the wall is swollen. The veins of the veins are thinned
Animals with desimulated bacterial inflammation after treatment with concentrated <i>Vaccinium oxycoccos</i> fruit juice	Umbrella cells are mainly desquamated. Areas with a normal urothelium are also detected	Histologically close to normal, but some smooth myositis is edematously altered, increased in size	There is a decrease in cellular infiltration	The walls and lumen of the arteries and arterioles are normal. Veins are normal, in venules thinning of covers is observed
Animals with simulated bacterial inflammation after treatment with «Cranberry» granules	The transitional epithelium is three-layered with a single desquamation of umbrella cells. The intermediate and main layers of the transitional epithelium are histologically almost unchanged	Smooth myocytes of normal shape and size, in some histopreparations it is possible to observe residual hypostasis and expansion of intercellular space	Constructed fibrous connective tissue with a small amount of elastic fibers	Blood vessels are normal

When infected with bacteria on histological specimens there is a significant increase in desquamation of the transitional epithelium (**Fig. 3**).

When infected with bacteria and treatment with the drug «Canefron® N» on histological preparations, desquamation of only the transitional epithelium is observed. Umbrella cells and cells of the intermediate layer are mainly subjected to desquamation (**Fig. 4**).

When infected with bacteria and treated with condensed juice of *Vaccinium oxycoccos* histologically observed desquamation of the surface layers of the transitional epithelium. Cells of the basal and intermediate layers were without changes (**Fig. 5**).

When infected with bacteria and treatment with granules of *Vaccinium oxycoccos*, the mucous membrane approaches normal (**Fig. 6**).

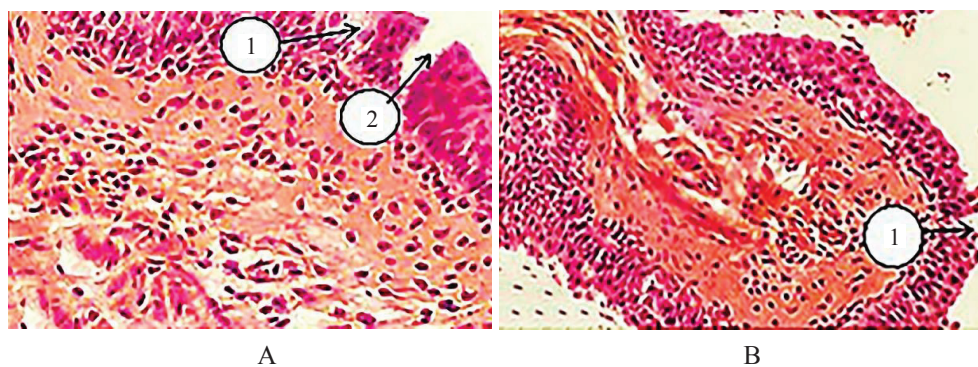


Fig. 3. Desquamation of all layers of the transitional epithelium with the formation of wedge-shaped gaps when infected with bacteria. Hematoxylin and eosin staining. Photomicrograph. Magnification: A – eyepiece 10, lens 20; B – eyepiece 10, lens 4. Designation: 1 – desquamation of urotheliocytes with exposure of the basement membrane; 2 – formation of wedge-shaped gaps

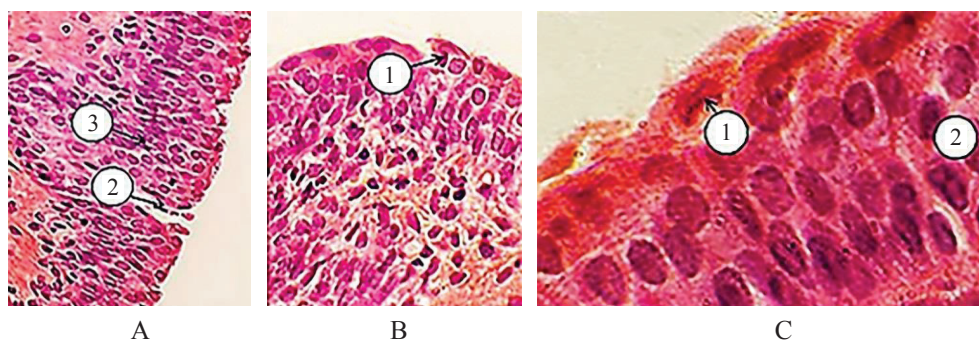


Fig. 4. Histostructure of the transitional epithelium of the bladder wall when infected with bacteria and treatment with «Canefron® N». Hematoxylin and eosin staining. Microphotographs. Magnification: A, B – eyepiece 10, lens 20, C – eyepiece 20, lens 40. Designation: 1 – desquamation of umbrella cells, 2 – formation of surface wedge-shaped gaps, 3 – desquamation of cells of the intermediate layer

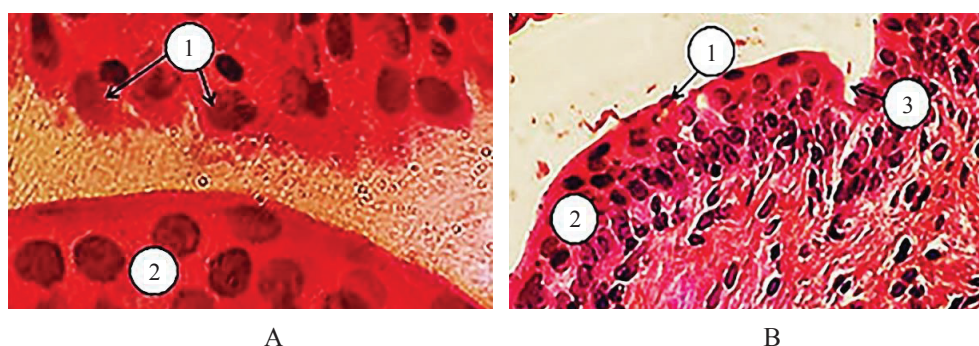


Fig. 5. Histostructure of the bladder wall when infected with bacteria and treatment with condensed juice *Vaccinium oxycoccos* fruit. Hematoxylin and eosin staining. Photomicrograph. Magnification: A – eyepiece 20, lens 40, B – eyepiece 10, lens 20. Designation: 1 – desquamation of umbrella cells, 2 – unchanged transitional epithelium, 3 – formation of superficial wedge-shaped gaps

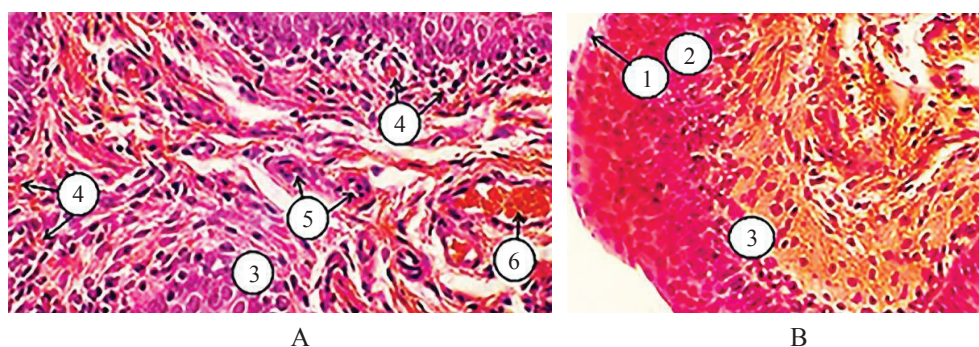


Fig. 6. Histostructure of the bladder wall when infected with bacteria and treatment with granules «Cranberry». Hematoxylin and eosin staining. Photomicrograph. Larger: A, B – eyepiece 10, lens 20. Designation: 1 – single desquamation of umbrella cells, 2 – unchanged intermediate layer, 3 – unchanged main layer, 4 – capillaries of the suburethral hemomicrocirculatory tract, 5 – arterioles, 6 – venules

4. Discussion of the research results

Numerous clinical studies have demonstrated statistically significant efficacy of *Vaccinium oxycoccos* juice in the form of concentrates, cocktails and capsules for the prevention of recurrence of urinary tract infections in women [24–26]. These facts indicate the feasibility of studying the anti-inflammatory effect of condensed juice from *Vaccinium oxycoccos* fruits and granules «Cranberry» in a model of bacterial cystitis in rats. When analyzing the results of the study, it was found that when

infected with *Escherichia coli* bacteria on histological preparations there is a significant increase in desquamation of the transitional epithelium, edema, cell infiltration, narrowing of blood vessels. In the treatment of animals with the drug «Canefron® N» umbrella cells and cells of the intermediate layer are subjected to desquamation. Also in the transitional epithelium there are shallow wedge-shaped ruptures of the urothelium, which in some places reach the intermediate layer. When infected with bacteria and treated with condensed juice *Vaccinium oxycoccos* histologically observed desquamation of the surface layers of the transitional epithelium. It should be noted that along with areas of transitional epithelium, in which pathological changes are observed, areas with normal urothelium, as well as areas with superficial wedge-shaped ruptures of the urothelium are found. When infected with *Escherichia coli* bacteria and treatment with *Vaccinium oxycoccos* granules, the mucous membrane approaches normal. The transitional epithelium is three-layered with a single desquamation of umbrella cells.

In animals introduction the drug «Canefron® N» in the vascular plexuses in the bladder wall there is a mosaic of histological picture: along with normal arterial vessels can be found spasmodic walls with edema. In the treatment of condensed juice with *Vaccinium oxycoccos* fruit in the vessels of all plexuses of the bladder wall there is a polymorphism of changes: unchanged arterial and slightly dilated and thinned venous vessels. At the same time at use of granules with condensed juice normalization of a histologic picture of vascular plexuses in a wall of a bladder is noted.

Thus, it is established that the positive effect on the tissues of the bladder wall, namely: reduction of desquamation of the superficial layers of the transitional epithelium and normalization of the histological picture of vascular plexuses in the bladder wall, after treatment of animals with condensed juice and granules of *Vaccinium oxycoccos* does not yield the effect of the comparison drug «Canefron® N».

Study limitations. The study did not investigate the effect of the studied drugs on the blood of animals.

Prospects for further research. The obtained results confirm the prospects of conducting clinical studies of the influence of the developed drugs on the course of cystitis in humans.

5. Conclusions

1. It is established that the use of condensed juice from *Vaccinium oxycoccos* fruits or granules «Cranberry» causes a weakening of the desquamation of the surface layers of the transitional epithelium of the bladder wall, reducing edema of blood vessels and bringing the lumen of arterioles and venules to normal in rats, with simulated, the introduction of *E. coli*, cystitis.

2. It is established that the obtained positive effect on the tissues of the walls and blood vessels of the bladder is not inferior to the effect of the comparison drug «Canefron® N».

Conflict of interests

The authors declare that they have no conflicts of interest.

References

- [1] Liutikova, M. N., Botirov, E. Kh. (2015). Khimicheskii sostav i prakticheskoe primeneniye iagod brusniki i kliukvy. *Khimiia rastitelnogo syria*, 2, 5–27. Available at: <https://cyberleninka.ru/article/n/himicheskii-sostav-i-prakticheskoe-primeneniye-yagod-brusniki-i-klyukvy/viewer>
- [2] Unifikovanyi klinichniy protokol medychnoi dopomohy. Diahnostyka ta likuvannya infektsii sechovydilnoi systemy (2011). Available at: https://www.dec.gov.ua/wp-content/uploads/2019/11/816dod1_2.pdf
- [3] Yatsiuk, K. M., Feodorovska, M. I., Kutsyk, R. V. (2018). The investigation of the cranberry (*Vaccinium oxycoccos* L.) concentrated juice antimicrobial activity. *Farmatsevtichniy Zhurnal*, 1, 84–92. doi: <http://doi.org/10.32352/0367-3057.1.17.11>
- [4] Davidson, E., Zimmermann, B. F., Jungfer, E., Chrubasik-Hausmann, S. (2013). Prevention of Urinary Tract Infections with *Vaccinium* Products. *Phytotherapy Research*, 28 (3), 465–470. doi: <http://doi.org/10.1002/ptr.5047>
- [5] LaPlante, K. L., Sarkisian, S. A., Woodmansee, S., Rowley, D. C., Seeram, N. P. (2012). Effects of Cranberry Extracts on Growth and Biofilm Production of *Escherichia coli* and *Staphylococcus* species. *Phytotherapy Research*, 26 (9), 1371–1374. doi: <http://doi.org/10.1002/ptr.4592>
- [6] Kirillov, V. I., Bogdanova, N. A., Morozov, S. L. (2018). Non-antibacterial alternative measures for urinary tract infection in children. Part 1. Suppression of the microbial initiation of the inflammation. *Rossiyskiy Vestnik Perinatologii i Pediatrii* (Russian Bulletin of Perinatology and Pediatrics), 63 (1), 106–112. doi: <http://doi.org/10.21508/1027-4065-2018-63-1-106-112>

- [7] Ulrey, R. K., Barksdale, S. M., Zhou, W., van Hoek, M. L. (2014). Cranberry proanthocyanidins have anti-biofilm properties against *Pseudomonas aeruginosa*. *BMC Complementary and Alternative Medicine*, 14 (1), 414–499. doi: <http://doi.org/10.1186/1472-6882-14-499>
- [8] Gupta, K., Chou, M. Y., Howell, A., Wobbe, C., Grady, R., Stapleton, A. E. (2007). Cranberry Products Inhibit Adherence of P-Fimbriated *Escherichia Coli* to Primary Cultured Bladder and Vaginal Epithelial Cells. *Journal of Urology*, 177 (6), 2357–2360. doi: <http://doi.org/10.1016/j.juro.2007.01.114>
- [9] Rane, H. S., Bernardo, S. M., Howell, A. B., Lee, S. A. (2013). Cranberry-derived proanthocyanidins prevent formation of *Candida albicans* biofilms in artificial urine through biofilm- and adherence-specific mechanisms. *Journal of Antimicrobial Chemotherapy*, 69 (2), 428–436. doi: <http://doi.org/10.1093/jac/dkt398>
- [10] LaPlante, K. L., Sarkisian, S. A., Woodmansee, S., Rowley, D. C., Seeram, N. P. (2012). Effects of Cranberry Extracts on Growth and Biofilm Production of *Escherichia coli* and *Staphylococcus* species. *Phytotherapy Research*, 26 (9), 1371–1374. doi: <http://doi.org/10.1002/ptr.4592>
- [11] Unifikovanyi klinichniy protokol medychnoi dopomohy. Hostryi neuskładnenyi tsystyt u zhinok (2011). Nakaz MOZ Ukrainy No. 816. 23.11.2011. Available at: http://search.ligazakon.ua/l_doc2.nsf/link1/MOZ23600.html
- [12] Hryhorenko, V. M., Romashchenko, O. V., Biloholovska, V. V., Volkov, S. S. (2016). Stratehiia likuvannia neuskładnenykh infektsii nyzhnykh sechovyvidnykh shliakhiv. *Novosti medytsyni y farmatsyy v Ukrainy*, 11 (585), 9–14. Available at: <http://www.mif-ua.com/archive/article/43685>
- [13] Nastanova Yevropeiskoi asotsiatsii urolohiv iz likuvannia infektsii sechovykh shliakhiv (EAU, 2012/2013). Available at: <http://www.mif-ua.com/archive/article/36615>
- [14] Medved, V. I., Islamova, E. V., Kirilchuk, M. E. (2015). Ekstrakt iagod kliukvy v profilaktike i lechenii infektsii mochevyvodiaschikh putei u beremennykh. *Zdorove zhenschiny*, 1 (97), 36–40. Available at: http://nbuv.gov.ua/UJRN/Zdzh_2015_1_8
- [15] Safronova, I. V., Goldina, I. A., Gaidul, K. V. (2015). Biologicheski aktivnye komponenty kliukvy i ikh primenenie v meditsine. *Innovatsii i prodovolstvennaia bezopasnost*, 1 (7), 6–18.
- [16] Yatsiuk, K. M., Fedorovska, M. I., Kovalska, N. P. (2015). Zhuravlyna bolotna (*Oxycoccus palustris* pers.L.) yak dzherelo dlia oderzhannia likarskykh zasobiv. *Fitoterapiia chasopys*, 2, 26–28.
- [17] Yatsiuk, K. M., Fedorovska, M. I., Barna, O. M. (2015). Granules composition and technology development based on condensed cranberry juice for urological use K. M. *The Pharma Innovation Journal*, 4 (8), 29–30. Available at: <http://www.thepharmajournal.com/archives/?year=2015&vol=4&issue=8&ArticleId=662>
- [18] Yatsiuk, K. M., Fedorovska, M. I. (2016). Pat. No. 116426 UA. Zasib dlia zastosuvannia v urolohii. MPK: A61K 9/20, A61K 36/00. No. u 201610598; declared: 20.10.2016; published: 25.05.2017, Biul. No. 10, 4.
- [19] Yatsiuk, K. M., Fedorovskaya, M. I., Marchyshyn, S. M., Budniak, L. I., Slobodianiuk, L. V. (2019). Obtaining and standardization of condensed juice from cranberries marsh fruits. *Medical and Clinical Chemistry*, 2, 55–60. doi: <http://doi.org/10.11603/mcch.2410-681x.2019.v.i2.10294>
- [20] Directive 2010/63/EU Legislation for the protection of animals used for scientific purposes. Available at: http://ec.europa.eu/environment/chemicals/lab_animals/legislation_en.htm
- [21] ARRIVE guidelines. Available at: <https://www.nc3rs.org.uk/arrive-guidelines>
- [22] Kirpatovskiy, V. I., Mudraya, I. S., Grekov, E. A., Kabanova, I. V., Golovanov S.A., Drojjeva, V. V. et. al. (2013). Influence of the experimental metabolic syndrome on the function of the urinary bladder in rats. *Ekspirimentalnaia i klinicheskaia urologiia*, 1, 8–13. Available at: https://ecuro.ru/sites/default/files/ECU_8-13%20kirpatovskiy.pdf
- [23] Amdii, R. E., Al-Shukri, S. H., Kuzmin, I. V., Sorokin, N. V., Chaplitskii, E. A., Skvortsov, M. V. et. al. (2016). Use of Kanefron in treatment of acute uncomplicated cystitis in women. *Urologicheskie Vedomosti*, 6 (2), 16. doi: <http://doi.org/10.17816/uroved6216-22>
- [24] Davidson, E., Zimmermann, B. F., Jungfer, E., Chrubasik-Hausmann, S. (2013). Prevention of Urinary Tract Infections with Vaccinium Products. *Phytotherapy Research*, 28 (3), 465–470. doi: <http://doi.org/10.1002/ptr.5047>
- [25] Guay, D. R. P. (2009). Cranberry and Urinary Tract Infections. *Drugs*, 69 (7), 775–807. doi: <http://doi.org/10.2165/00003495-200969070-00002>
- [26] Howell, A. B. (2007). Bioactive compounds in cranberries and their role in prevention of urinary tract infections. *Molecular Nutrition & Food Research*, 51 (6), 732–737. doi: <http://doi.org/10.1002/mnfr.200700038>

Received date 14.08.2020

Accepted date 05.11.2020

Published date 30.11.2020

© The Author(s) 2020

This is an open access article under the CC BY license

(<http://creativecommons.org/licenses/by/4.0/>).