

DISTRIBUTION OF STRONGYLOIDES STERCORALIS AMONG DOGS OF DIFFERENT HOUSING GROUPS IN KYIV AND KYIV REGION, CLINICAL MANIFESTATIONS AND DIAGNOSTIC METHODS

Sofia Dashchenko

Department of pharmacology, parasitology and tropical veterinary medicine¹
dashchenko.sofiia@gmail.com

Natalia Soroka

Department of pharmacology, parasitology and tropical veterinary medicine¹
5278823@ukr.net

Olena Semenko

Department of pharmacology, parasitology and tropical veterinary medicine¹
eleora@ukr.net

¹National University of Life and Environmental Sciences of Ukraine
15 Heroiv Oborony str., Kyiv, Ukraine, 03041

Abstract

Strongyloidiasis in dogs, despite its uncertain zoonotic status, is potentially danger for dogs owners. It is considered that strongyloidiasis characteristic for tropical and subtropical regions, but in recent years it is increasingly found in non-endemic countries.

The aim. To determine the extent of the invasion, clinical signs and diagnostic methods of strongyloidiasis in dogs of different groups in Kyiv and Kyiv region.

Materials and methods. A total of 364 dogs were studied (130 animals lived in shelters (Group 1) and 234 in homes (Group 2). Diagnosis of strongyloidiasis was performed by native smear and Baerman methods. Additionally, the sensitivity of the modified string test was tested. Samples of venous blood were taken from dogs with confirmed strongyloidiasis for haematological and biochemical analysis.

Results. A study found that the extent of invasion (EI) in shelters and home dogs was 3.0 ± 0.36 % (4/130; Group 1) and 2.5 ± 0.25 % (6/234; Group 2) respectively.

It was found that three repetitions of the Baerman method test increased its efficiency to 90.5 %. The sensitivity of the modified string test was 100 %.

Clinical manifestations included disorders of the respiratory (20 %: 2/10) and digestive systems (80 %: 8/10), weight loss (70 %: 7/10). Blood tests did not reveal changes specific to strongyloidiasis, eosinophilia was observed in only one dog in the acute stage of the disease.

Conclusions. The results of our studies indicate the presence of strongyloidiasis in dogs in Kyiv and Kyiv region and probability of the spread of the pathogen in the environment. Symptoms in dogs with strongyloidiasis were nonspecific and cannot be used for diagnosis. A modified string test and Baerman method has demonstrated high efficacy and may be recommended to clarify the diagnosis of a chronic invasion.

Keywords: Strongyloides stercoralis, strongyloidiasis in dogs, Kyiv and Kyiv region, extent of invasion, clinical manifestation, modified of the string test, non-endemic.

DOI: 10.21303/2504-5679.2020.001423

1. Introduction

Strongyloides stercoralis (Bavay, 1876) is a nematode of the order *Rhabditida*, which has a complex developmental cycle, uncertain zoonotic status, and a cosmopolitan distribution [1]. Based on morphological identity, in literature considered that it multi-host parasite and infects dogs, cats, primates and humans [1, 2]. Studies by Jaleta T. G. et al. have identified a genetically distinct subspecies (B) that is unique to dogs and a common subspecies (A) for humans

and dogs [3]. Similar results were obtained by Nagayasu et al. in Myanmar and Beknazarova in Australia [4, 5].

Susceptible animals are infected by percutaneous and oral routes [1]. Strongyloidiasis in dogs is more common in puppies and young dogs up to one year old [6, 7]. According to research by G. A. Schad, it was found that the immunity of a healthy adult dog is able to stop the excessive reproduction of the pathogen *S. stercoralis* in its body [8]. Most publications indicate that the symptoms of strongyloidiasis in dogs include dermatological manifestations, signs of lung damage (shortness of breath, cough, wheezing, mucus secretion) and gastrointestinal lesions [1, 6]. In dogs with immunosuppression in addition to the symptoms described above, there may be hematocesis, hematomesis [9]. The chronic course of the invasion is accompanied by weight loss, loss of appetite, stunted growth and development of puppies and young dogs. An asymptomatic course of strongyloidiasis is often observed. In the event of hyperinfection, the death of puppies or young dogs with weakened immunity is possible [9, 10]. Due to the ability to autoinvasion, the pathogen can persist for a long time in the host and cause chronic invasion [1].

Diagnosis of strongyloidiasis is based on the detection of larvae of the pathogen in the feces of dogs. Standard diagnostic methods such as a native smear and flotation are of low efficiency [1]. The number of larvae that are excreted in the feces of chronically ill dogs is usually quite small and the periods of their release are irregular, which complicates the diagnosis of strongyloidiasis [11, 12]. These features require the use of “cumulative” techniques, in particular the Baerman method or cultural methods. A string test has been used successfully to diagnose strongyloidiasis in humans [13]. Prior to that, there was only one publication in the literature on the use of string test in dogs for the diagnosis of giardiasis [14].

Cases of *S. stercoralis* in non-endemic regions have been reported by a number of researchers. A. Cvetkovikj [15], K. J. Dillard [6] and M. Cervone [9] reported about single cases in Macedonia, Finland and France, respectively. M. Eydal [12] found strongyloidiasis in dogs imported to Iceland from Europe and the United States and in kennels. S. A. Zanzani [16] found larvae of *S. stercoralis* in feces of dogs collected on the streets of Milan. Mention of the detection of strongyloidiasis in Greece among domestic, shepherd and shelter dogs is in the work of D. Kostopoulou [17]. In Serbia, strongyloidiasis was detected by G. Štrkolcová [18] in a study of dogs from gypsy settlements and shelters. There are also reports of foci of strongyloidosis in dog kennels and pet stores [19, 20]. The reports on the detection of strongyloidiasis in Ukraine concerned the south-east territories and the territory of Ukraine in general [21, 22].

There is no information in the literature on the spread of the disease among dogs from shelter and those kept at home. In this regard, we conducted a comparative analysis of the extent of the invasion, clinical signs, methods of diagnosis of strongyloidiasis in dogs of different groups in Kyiv and Kyiv region.

The aim of the study was to determine extent of the invasion, clinical signs and diagnostic methods of strongyloidiasis in dogs of different groups in Kyiv and Kyiv region.

2. Materials and methods

A total of 364 dogs from Kyiv and Kyiv region were studied. Of these, 130 animals lived in shelters and 234 in homes. The study included dogs aged from 3 months to 10 years, different breeds and both sexes. The distribution by breeds of the studied home dogs is shown in the **Fig. 1**.

Anamnesis vitae and anamnesis morbis were collected for the study, which included information on housing conditions, age of dogs, records of the previous visits, clinical manifestations of the disease and time of their occurrence. Based on the information on keeping, two groups were formed: the first group of dogs from shelters (Group 1) and the second group of home dogs (Group 2).

Dogs of the Group 1 were kept in animal shelters in Kyiv and Kyiv region. Upon admission to the shelters, the animals were examined by a veterinarian and provided deworming. At the time of the study, the animals in the first shelter were kept in mesh enclosures, one of the walls of which is made of wood and turns into a covered hut. The wooden floor is raised above the ground. In each enclosure from 1 to 8 dogs were kept united by sex and age. Another shelter is a home-type shelter.

The rooms are converted into cages with tiled floors, the walls are painted with wet impermeable paint, the partitions between the compartments are plastic. Faeces in one of the shelters were cleaned daily, in another once a week.

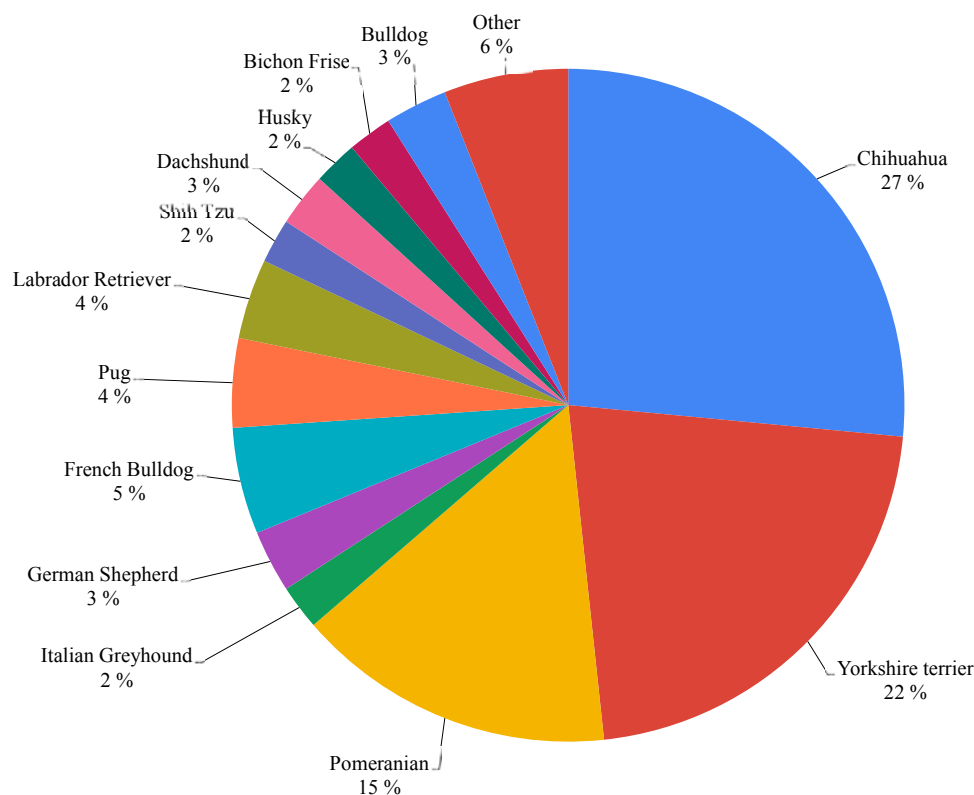


Fig. 1. Distribution by breeds of the studied home dogs

Home dogs (Group 2) live in houses, apartments, kennels and enclosures with the possibility of walking them on the street or in the yard.

Feces were collected while walking the dogs from the ground, from the floor in enclosures or rectally. Diagnosis of strongyloidiasis was performed coproscopically, using native smear and Baerman methods. Identification of larvae of the first stage was carried out on parasitic atlases based on the typical morphology (presence of rhabditiform esophagus and pronounced genital primordium) [23, 24]. In the case of a negative test, if domestic animals showed characteristic symptoms, a modified string test [25] was performed to confirm the diagnosis. Additionally, the sensitivity of the modified string test was tested on 4 animals with a confirmed diagnosis.

Samples of venous blood were taken from 2 dogs of the Group 1 and 5 dogs of the Group 2 with confirmed strongyloidiasis for complete blood count (CBC) and biochemical blood analysis. Blood sampling for the study was performed on an empty stomach, from the subcutaneous veins of the extremities. Biochemical blood test was performed using a semi-automatic biochemical analyzer Rayto RT-1904C, for complete blood count using an automatic hematology analyzer Mindray bc-5000vet. A white blood cell differential was examined manually in blood smears stained by Leucodif 200 (Erba, Czech Republic). Results of the biochemical blood analysis are expressed as mean (M) and standard deviation of the mean (m).

Extent of invasion was determined by the formula:

$$E = \frac{Np}{n} \times 100 \%,$$

where Np – the number of infected animals; n – the total number of animals.

All procedures were conducted according to the guidelines for animal experimentation (CIOMS, 1985) [26] and the shelter's administration and dog's owners were informed of the results.

3. Results

A study of shelter's dogs found that the extent of invasion was $3.0 \pm 0.36\%$ (4/130; Group 1), while the EI of invasion among dogs kept in homes was $2.5 \pm 0.25\%$ (6/234; Group 2).

Higher extent of invasion was observed in home dogs under the age of one year and amounted to $66.6 \pm 1.8\%$ (4/6; Group 2). However, in shelter's dogs the highest extent of invasion was in the age category 1–3 years ($100 \pm 4.8\%$, 4/4; Group 1). The age distribution is shown in **Fig. 2**. The highest rate of the invasion was observed in males of both groups – $3.7 \pm 0.08\%$ against $1.3 \pm 0.27\%$ in females (**Fig. 3**).

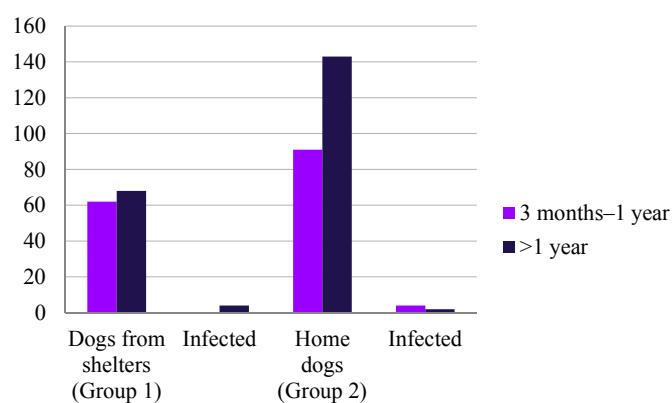


Fig. 2. Distribution of the studied dogs by age

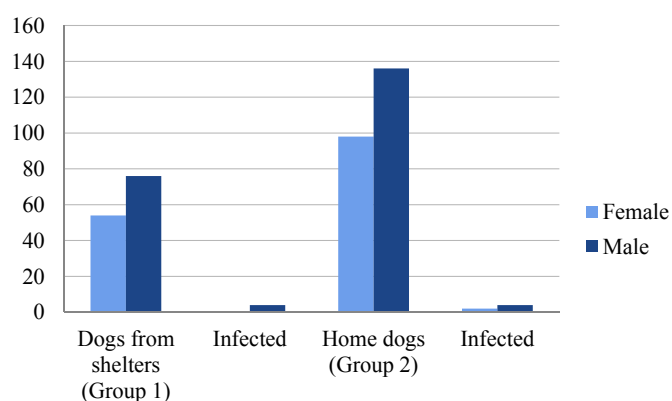


Fig. 3. Representation of studied dogs in terms of sexes

Mono- (n=50; 56.8 %) and polyinvasion (n=38; 43.2 %) in particular trichurosis, toxocarosis, hookworm and isosporosis were observed in 88 dogs of Group 1. Polyinvasion of *A. caninum*, *T. vulpis*, *S. stercoralis* was detected in three of them (3.4 %). Data of helminth infestation of dogs from shelters are shown in **Table 1**.

In order to establish the effectiveness of coproscopic diagnostic methods, a comparative evaluation of the effectiveness of the native smear and the Baerman method was performed. Additionally, a sensitivity study of the modified string test was performed. Only 3 out of 10 sick animals (30 %) was detected by native smear, while Baerman's method showed a sensitivity to 82 %, and when the study was repeated three times, its sensitivity increased to 90.5 %. Most of the sick dogs detected by the native smear belonged to the owners and showed clinical manifestations characteristic of the acute phase of the disease. The sensitivity of the modified string test was 100 % (4/4).

In the anamnesis of patients with strongyloidiasis of dogs of Group 1 (n=4) the excretion of soft faeces with the remains of undigested food (n=4) and reduced body weight (n=2) were noted.

Both chronic and acute clinical pictures were observed in dogs of Group 2. In sick dogs at the time of the study there were soft feces (n= 3), diarrhea with mucus (n=1), weight loss (n=5), cough and shortness of breath (n=2). One dog had no clinical manifestations at the time of the study, but limb skin lesions and cough have been reported in the past. The distribution of clinical signs by groups is shown in Fig. 4.

Table 1
Mono- and polyinvasion of dogs from shelters

Parasites	Dogs younger than one year	Dogs older than one year
<i>T. canis</i>	19	4
<i>A. caninum</i>	12	7
<i>A. caninum, T. canis</i>	10	4
<i>T. vulpis</i>	–	4
<i>T. canis, T. vulpis</i>	–	2
<i>A. caninum, T. canis, T. vulpis</i>	–	5
<i>A. caninum, T. vulpis</i>	–	14
<i>A. caninum, T. vulpis, S. stercoralis</i>	–	3
<i>Cystoisospora spp.</i>	4	–

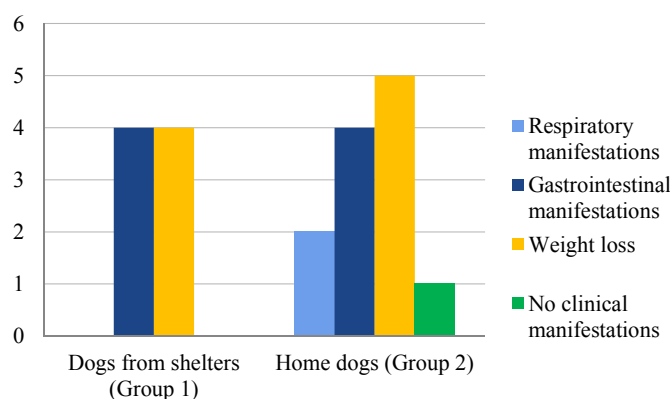


Fig. 4. Distribution of clinical signs by groups of studied dogs.

According to the results of biochemical blood analysis in one dog from the shelter (Group 1) recorded hypoproteinemia (total protein 34.2 g/l) with a decrease in the albumin fraction (albumin 19.60 g/l). In dog (Group 1) affected by *A. caninum, T. vulpis, S. stercoralis* were observed hypoproteinemia (total protein 24.3 g/l) with severe hypoalbuminemia (albumin 15.6 g/l), hypomagnesemia (magnesium 0.6 mmol/l), decreased cholesterol content (cholesterol 1.6 mmol/l). Biochemical blood analysis revealed hypoproteinemia (protein 37±1.22 g/l) and moderate hypoalbuminemia (albumin 20.3±1.22 g/l) in four owner's dogs (Group 2). One young (6 months) owner's dog had hyperproteinemia (protein 77.4 g/l) with an increase in the albumin fraction (albumin 42.1 g/l), as well as an increase of urea concentration (urea 10.3 mmol/l) and the potassium level (potassium 4.0 mmol/l), phosphorus (phosphorus 0.98 mmol/l) and magnesium (magnesium 0.7 mmol/l).

According to the results of complete blood count in one dog Group 2 revealed neutrophilia (neutrophils 78 %). Anemia (erythrocytes $3.2 \times 10^{12}/l$), leukocytosis (leukocytes $19.3 \times 10^9/l$), neutrophilia (segmented neutrophils 70 %) with a shift of the Group 1 nucleus to the left (band neutrophils 8 %), eosinophilia (eosinophils 10 %) were observed in dogs with polyinvasion (*A. caninum, T. vulpis, S. stercoralis*). Eosinophilia and neutrophilia with an increased number of band neutro-

phils were observed in two home dogs with signs of respiratory lesions. Anemia (erythrocytes $4.69 \pm 0.24 \times 10^{12}/l$) was observed in three dogs of owners. Erythrocytosis (erythrocytes $10.5 \times 10^{12}/l$) and eosinophilia (eosinophils 15 %) were found in one dog (Group 2) with prolonged diarrhea.

4. Discussion

In this article we describe the prevalence of strongyloidiasis among dogs of different forms of keeping in Kyiv and Kyiv region, which belong to the temperate continental climate and are not endemic regions. In our previous publications, we have reported sporadic (isolated) cases of strongyloidiasis in domestic dogs [28] and the detection of strongyloidiasis in one of the private kennels of chihuahua dogs [19], but the comparison of EI among dogs of different forms of keeping held for the first time. Prior to that, the report on the detection of strongyloidiasis in Ukraine concerned the southeast with the steppe climate and the territory of Ukraine in general without comparing the extent of the invasion among different groups of animals [21, 22].

Strongyloidiasis in dogs is considered to be characteristic for subtropical and tropical climates, although with the improvement of international transport links it is recognized that it has acquired a cosmopolitan status [1]. In Europe, strongyloidiasis in dogs has been found in Greece (subtropical climate) [17], Italy (temperate climate) [16], sporadically in Finland (temperate continental climate) [6] and Iceland (marine subarctic climate) [11]. It is believed that in atypical climatic conditions, cases of strongyloidiasis are sporadic [6, 11] but in our research 2.5 % of studied home dogs was invaded.

Cvetkovikj A. and Dillard K. J. indicate that dogs with strongyloidiasis are more likely to be imported from abroad [6, 15]. However, researchers do not report the possibility of infecting dogs in the environment. Fact of detection dogs with strongyloidiasis in shelters indicates possibility of their infection in nature, which indicates the potential of free spread of the pathogen in the conditions of Kiev and Kiev region.

In temperate climates in the case of humans described the formation of foci of invasion in places with neglect of sanitary and hygienic standards and cramped conditions of living: boarding schools, hospices, mental hospitals. Similar can be observed in dogs on the basis of shelters and kennels [7, 28]. According to studies by Itoh N., a high extent of invasion of strongyloidiasis was observed in dogs kept in conditions of limited walking and high crowding (domestic dogs and dogs in pet stores) [20]. In dogs who grew with free access to the street, the extent of the invasion of strongyloidiasis was much lower due to the avoidance of the possibility of circulation of the pathogen in a crowding population, which can include dogs of the shelters. This is confirmed by our research, because it was in the experimental group of dogs from shelter we observed the highest extent of invasion. Similar results are described in the article by Paradies P. [28], but in this study, the EI in dogs from shelters was higher and in domestic dogs lower than described by us. Higher EI in groups of dogs kept in homes in our case may be associated with neglect of antiparasitic treatments, or with their irregular conduct. Detection *S. stercoralis* in dogs from shelters and other parasites also indicates that antiparasitic measures in shelters are inadequate.

The symptoms we registered in dogs with strongyloidiasis analogical to those described in the literature [1, 28]. They are nonspecific and cannot be used for a definitive diagnosis. In examined dogs from shelters, the symptoms may also be related to poor feeding. The results of biochemical and general clinical blood tests are similar to those described in the literature [10, 28]. Changes in the biochemical and hematological profile of patients with strongyloidiasis in dogs are also nonspecific and reflect changes in the body caused by parasitic pathogens such as impaired absorption of nutrients, dehydration due to diarrhea, tissue damage during larval migration, and the impact of malnutrition. However, a small number of studied samples does not give a complete picture and further research is needed.

Due to the low efficiency of conventional diagnostic methods such a native smear and flotation [7, 12] and the non-specificity of clinical manifestations in dogs, the use of special research methods such as the Baerman method and the string test are extremely necessary. Prior to that, there was only one publication in the literature on the use of string test in dogs for the diagnosis of giardiasis [18]. Given the successful use of string test in humans for the diagnosis of strongyloidia-

sis, its use in dogs is an interesting alternative in the absence of a “gold standard” for diagnosis. In our study, the string test showed 100 % efficacy, indicating its viability in the diagnosis of strongyloidiasis in dogs, but requires further research in larger experimental groups.

Study limitations. Although our detection of strongyloidiasis in dogs in Kiev and Kiev region is important, a small sample of animals does not provide a clear epidemiological picture of this region. Our research also has a number of other limitations. The first is that due to the small number of animals in which blood was collected, it is impossible to give an unambiguous conclusion about changes in blood parameters in strongyloidiasis. In addition, the animals in which the blood was collected lived in different conditions and we cannot distinguish between the effects of *S. stercoralis* parasitism and effects of housing conditions. It is necessary in the future to conduct research in infected dogs in the same conditions. Second, a small number of animals involved in testing the effectiveness of a string test can distort the results, and further research that included more naturally infected dogs needed. There is also the problem of undiagnosed animals due to the existing limitations in the effectiveness of the Berman method, which we used in the study.

Prospects for further research. The use of serological or PCR research methods in the future may help to identify the true epidemiological situation in Kiev and Ukraine as a whole. Studies of broader groups of dogs throughout Ukraine are needed to clarify the epidemiological situation among dogs. Also promising are studies using PCR techniques to clarify the presence of *S. stercoralis* subspecies that can infect both dogs and humans in Ukraine.

5. Conclusion

We studied the prevalence of strongyloidiasis in dogs in Kyiv and Kyiv region.

It was found that the highest extent of invasion was observed in dogs kept in the shelter (3.0 ± 0.36 %, 4/130; Group 1). The extent of the invasion among home dogs was lower and amounted to 2.5 ± 0.25 % (6/234; Group 2). Detection of strongyloidiasis in shelters dogs may indicate of their infection outside the shelter and spreading parasite in the environment. The overall extent of invasion of strongyloidiasis in tested dogs was 2.7 ± 0.8 %, which belongs to the category of “endemic” (1–5 %) prevalence according to the classification (proposed) by Pires and Dreyer [29]. It was found that the highest extent of infestation in home dogs (Group 2) was observed in the age group up to one year. Conversely, in dogs from shelters (Group 1), a higher extent of invasion was observed in the age group from one to three years. In both groups huger extent of invasion was in males.

A study of the effectiveness of coproscopic diagnostic methods has shown that the Baerman method has the highest efficiency. It was found that three repetitions of the test increase the efficiency of diagnosis of strongyloidiasis to 90.5 %. A modified string test has demonstrated high efficacy and may be recommended to clarify the diagnosis of a chronic invasion.

Clinical manifestations in sick dogs included disorders of the respiratory (20 %: 2/10; all groups) and digestive systems (80 %: 8/10; all groups), weight loss (70 %: 7/10; all groups). All symptoms are nonspecific and cannot be used for diagnosis. Blood tests did not reveal changes specific to strongyloidiasis, eosinophilia was observed in only one dog in the acute stage of the disease.

The results of our studies indicate the presence of strongyloidiasis in dogs in Kyiv and Kyiv region and the possibility of infection of dogs and the spread of the pathogen in the environment.

Conflict of interest

The authors declare that they have no conflicts of interest.

References

- [1] Thamsborg, S. M., Ketzis, J., Horii, Y., Matthews, J. B. (2016). Strongyloides spp. infections of veterinary importance. *Parasitology*, 144 (3), 274–284. doi: <http://doi.org/10.1017/s0031182016001116>
- [2] Barnes, A. N., Davaasuren, A., Baasandagva, U., Gray, G. C. (2017). A systematic review of zoonotic enteric parasitic diseases among nomadic and pastoral people. *PLOS ONE*, 12 (11), e0188809. doi: <http://doi.org/10.1371/journal.pone.0188809>
- [3] Jaleta, T. G., Zhou, S., Bemm, F. M., Schär, F., Khieu, V., Muth, S. et. al. (2017). Different but overlapping populations of *Strongyloides stercoralis* in dogs and humans – Dogs as a possible source for zoonotic strongyloidiasis. *PLOS Neglected Tropical Diseases*, 11 (8), e0005752. doi: <http://doi.org/10.1371/journal.pntd.0005752>

- [4] Nagayasu, E., Aung, M. P. P. T. H. H., Hortiwakul, T., Hino, A., Tanaka, T., Higashiarakawa, M. et. al. (2017). A possible origin population of pathogenic intestinal nematodes, *Strongyloides stercoralis*, unveiled by molecular phylogeny. *Scientific Reports*, 7 (1). doi: <http://doi.org/10.1038/s41598-017-05049-x>
- [5] Beknazarova, M., Barratt, J. L. N., Bradbury, R. S., Lane, M., Whiley, H., Ross, K. (2019). Detection of classic and cryptic *Strongyloides* genotypes by deep amplicon sequencing: A preliminary survey of dog and human specimens collected from remote Australian communities. *PLOS Neglected Tropical Diseases*, 13 (8), e0007241. doi: <http://doi.org/10.1371/journal.pntd.0007241>
- [6] Dillard, K. J., Saari, S. A., Anttila, M. (2007). *Strongyloides stercoralis* infection in a Finnish kennel. *Acta Veterinaria Scandinavica*, 49 (1), 37. doi: <http://doi.org/10.1186/1751-0147-49-37>
- [7] Júnior, A. F., Gonçalves-Pires, M. R. F., Silva, D. A. O., Gonçalves, A. L. R., Costa-Cruz, J. M. (2006). Parasitological and serological diagnosis of *Strongyloides stercoralis* in domesticated dogs from southeastern Brazil. *Veterinary Parasitology*, 136 (2), 137–145. doi: <http://doi.org/10.1016/j.vetpar.2005.10.022>
- [8] Schad, G. A., Thompson, F., Talham, G., Holt, D., Nolan, T. J., Ashton, F. T. et. al. (1997). Barren Female *Strongyloides stercoralis* from Occult Chronic Infections are Rejuvenated by Transfer to Parasite-Naive Recipient Hosts and Give Rise to an Autoinfective Burst. *The Journal of Parasitology*, 83 (5), 785–791. doi: <http://doi.org/10.2307/3284268>
- [9] Cervone, M., Giannelli, A., Otranto, D., Perrucci, S. (2016). *Strongyloides stercoralis* hyperinfection in an immunosuppressed dog from France. *Revue Vétérinaire Clinique*, 51 (2), 55–59. doi: <http://doi.org/10.1016/j.anicom.2016.05.001>
- [10] Graham, J. A., Sato, M., Moore, A. R., McGrew, A. K., Ballweber, L. R., Byas, A. D., Dowers, K. L. (2019). Disseminated *Strongyloides stercoralis* infection in a dog following long-term treatment with budesonide. *Journal of the American Veterinary Medical Association*, 254 (8), 974–978. doi: <http://doi.org/10.2460/javma.254.8.974>
- [11] Eydal, M., Skirnisson, K. (2016). *Strongyloides stercoralis* found in imported dogs, household dogs and kennel dogs in Iceland. *Icelandic Agricultural Sciences*, 29, 39–51. doi: <http://doi.org/10.16886/ias.2016.04>
- [12] Requena-Méndez, A., Chiodini, P., Bisoffi, Z., Buonfrate, D., Gotuzzo, E., Muñoz, J. (2013). The Laboratory Diagnosis and Follow Up of Strongyloidiasis: A Systematic Review. *PLoS Neglected Tropical Diseases*, 7 (1), e2002. doi: <http://doi.org/10.1371/journal.pntd.0002002>
- [13] Goka, A. K. J., Rolston, D. D. K., Mathan, V. I., Farthing, M. J. G. (1990). Diagnosis of *Strongyloides* and hookworm infections: comparison of faecal and duodenal fluid microscopy. *Transactions of the Royal Society of Tropical Medicine and Hygiene*, 84 (6), 829–831. doi: [http://doi.org/10.1016/0035-9203\(90\)90098-y](http://doi.org/10.1016/0035-9203(90)90098-y)
- [14] Hall, E. J., Rutgers, H. C., Batt, R. M. (1988). Evaluation of the peroral string test in the diagnosis of canine giardiasis. *Journal of Small Animal Practice*, 29 (3), 177–183. doi: <http://doi.org/10.1111/j.1748-5827.1988.tb02275.x>
- [15] Cvetkovikj, A., Rashikj, L., Celeska, I., Petrov, E. A., Angelovski, B., Cvetkovikj, I. et. al. (2018). First Case of *Strongyloides stercoralis* Infection in a Dog in the Republic of Macedonia. *Macedonian Veterinary Review*, 41 (1), 95–98. doi: <http://doi.org/10.1515/macvetrev-2017-0032>
- [16] Zanzani, S. A., Di Cerbo, A. R., Gazzonis, A. L., Genchi, M., Rinaldi, L., Musella, V. et. al. (2014). Canine Fecal Contamination in a Metropolitan Area (Milan, North-Western Italy): Prevalence of Intestinal Parasites and Evaluation of Health Risks. *The Scientific World Journal*, 2014, 1–6. doi: <http://doi.org/10.1155/2014/132361>
- [17] Kostopoulou, D., Claerebout, E., Arvanitis, D., Ligda, P., Voutzourakis, N., Casaert, S., Sotiraki, S. (2017). Abundance, zoonotic potential and risk factors of intestinal parasitism amongst dog and cat populations: The scenario of Crete, Greece. *Parasites & Vectors*, 10 (1). doi: <http://doi.org/10.1186/s13071-017-1989-8>
- [18] Štrkolcová, G., Goldová, M., Bocková, E., Mojžišová, J. (2017). The roundworm *Strongyloides stercoralis* in children, dogs, and soil inside and outside a segregated settlement in Eastern Slovakia: frequent but hardly detectable parasite. *Parasitology Research*, 116 (3), 891–900. doi: <http://doi.org/10.1007/s00436-016-5362-1>
- [19] Dashchenko, S. O. (2019). Distribution of canine strongyloidiasis under conditions of a private kennel. *Ukrainian Journal of Veterinary Sciences*, 10 (4), 101–107. doi: <http://doi.org/10.31548/ujvs2019.04.013>
- [20] Itoh, N., Muraoka, N., Aoki, M., Itagaki, T. (2003). Prevalence of *Strongyloides* spp. Infection in Household Dogs. *Journal of the Japanese Association for Infectious Diseases*, 77 (6), 430–435. doi: <http://doi.org/10.11150/kansenshogakuzasshi1970.77.430>
- [21] Korniyushin, V. V., Malyshko, E. I., Malega, O. M. (2013). Domestic dogs and cats as the reservoir of natural nidi and zoonotic helminthoses under present conditions in Ukraine. *Veterinarna Medicina*, 97, 383–387.
- [22] Boyko, O. O., Faly, L. I., Brygadyrenko, V. V. (2011). Parasites diversity in carnivorous animals in the territory of Dnipropetrovsk. *Regulatory Mechanisms in Biosystems*, 2 (2), 3–7. doi: <http://doi.org/10.15421/021121>
- [23] Bowman, D. D. (2013). *Georgis' Parasitology For Veterinarians*. Saunders, 496.
- [24] Foreyt, B. (2013). *Veterinary Parasitology Reference Manual*. Hoboken: Wiley, 256.
- [25] Dashchenko, S. O., Soroka, N. M., Galat, M. V., Semenko, O. V. (2020). Pat. No. 142234 UA. A method for diagnosing strongyloidiasis in dogs using a modified string test.

- [26] International Guiding Principles for Biomedical Research Involving Animals (1985). Geneva: CIOMS, 28. Available at: <https://cioms.ch/publications/product/international-guiding-principles-for-biomedical-research-involving-animals-2/>
- [27] Soroka, N. M., Dashchenko, S. O. (2017). Clinical cases of strongyloidosis of dogs in Kiev. Actual problems of veterinary parasitology at the present stage. Vitebsk, 116–120. Available at: <http://repo.vsavm.by/handle/123456789/3866>
- [28] Paradies, P., Iarussi, F., Sasanelli, M., Capogna, A., Lia, R. P., Zucca, D. et. al. (2017). Occurrence of strongyloidiasis in privately owned and sheltered dogs: clinical presentation and treatment outcome. Parasites & Vectors, 10 (1). doi: <http://doi.org/10.1186/s13071-017-2275-5>
- [29] Pires, M. L., Dreyer, G. (1993). Revendo a importância do Strongyloides stercoralis. Revista do Hospital das Clinicas, 48, 175–182.

Received date 03.08.2020

Accepted date 14.09.2020

Published date 30.09.2020

© The Author(s) 2020

This is an open access article under the CC BY license

(<http://creativecommons.org/licenses/by/4.0>).

INTENSITY OF INVASION IN EMERIOSIS OF RABBITS IN DIFFERENT METHODS OF KEEPING

Oksana Shkromada

*Department of therapy, pharmacology, clinical diagnostics and chemistry¹
oshkromada@gmail.com*

Tetiana Nedzheria

*Department of therapy, pharmacology, clinical diagnostics and chemistry¹
tatyannedzheria@ukr.net*

¹*Sumy National Agrarian University
160 Herasyma Kondratieva str., Sumy, Ukraine, 40021*

Abstract

One of the important problems in raising rabbits is eimeriosis, regardless of the method of maintenance. The disease affects animals of all ages, causing weight loss, feed conversion, morbidity and death.

The aim. Study of the prevalence and diagnosis of rabbit eimeriosis by different housing technology to improve methods of disease control.

Methods. The experiment was conducted during 2017–2019 in farms with different capacities in four regions of Dnipro, Zaporizhia, Kharkiv and Sumy. A total of 20 farms for keeping rabbits of different breeds were surveyed.

Results. Studies of rabbit farms on business and private ones found that the most common infestation was with the following species of eimeria: *Eimeria perforans*, *E. magna*, *E. media*, *E. irresidua*, *E. piriformis* and *E. intestinalis*. It is proved that the extensiveness of rabbit infestation when kept in farms in metal cages, under the conditions of sanitary and hygienic regime and timely disinvasion of premises, was in the range of 42–15 % in autumn-winter period, and 19–6 % in spring-summer. According to the survey of homestead farms, rabbits kept in wooden cages on deep litter, the level of invasion in the autumn-winter period was 100–56 % and in the spring-summer – 70–29 %.

Conclusions. Keeping rabbits in metal cages in compliance with sanitary and hygienic standards and timely disinvasion reduces the level of extensiveness of the invasion.

Keywords: eimeriosis of rabbits, biological cycle of eimerias, intensity of invasion, methods of keeping rabbits.

DOI: 10.21303/2504-5679.2020.001419

1. Introduction

The rabbit industry in Ukraine is just beginning to gain momentum due to the rapid growth and dietary properties of meat. Rabbits are an alternative commodity to fill meat stocks, as well