

Jarosz Piotr M., Oszczydlowski Pawel, Pytka Michalina, Nowaczek Justyna, Jodłowska-Jędrych Barbara. Current prospects of urine cytology in diagnosis and follow-up urinary tract malignancies - the short review. *Journal of Education, Health and Sport*. 2020;10(9):763-769. eISSN 2391-8306. DOI <http://dx.doi.org/10.12775/JEHS.2020.10.09.092>
<https://apcz.umk.pl/czasopisma/index.php/JEHS/article/view/JEHS.2020.10.09.092>
<https://zenodo.org/record/4051874>

The journal has had 5 points in Ministry of Science and Higher Education parametric evaluation. § 8. 2) and § 12. 1. 2) 22.02.2019.

© The Authors 2020;

This article is published with open access at License Open Journal Systems of Nicolaus Copernicus University in Torun, Poland

Open Access. This article is distributed under the terms of the Creative Commons Attribution Noncommercial License which permits any noncommercial use, distribution, and reproduction in any medium, provided the original author (s) and source are credited. This is an open access article licensed under the terms of the Creative Commons Attribution Non commercial license Share alike. (<http://creativecommons.org/licenses/by-nc-sa/4.0/>) which permits unrestricted, non commercial use, distribution and reproduction in any medium, provided the work is properly cited.

The authors declare that there is no conflict of interests regarding the publication of this paper.

Received: 22.09.2020. Revised: 24.09.2020. Accepted: 26.09.2020.

Current prospects of urine cytology in diagnosis and follow-up urinary tract malignancies - the short review

Piotr M. Jarosz¹, Paweł Oszczydlowski¹, Michalina Pytka¹, Justyna Nowaczek¹,
Barbara Jodłowska-Jędrych¹

¹ Chair and Department of Histology and Embryology with Experimental Cytology Unit, Medical University of Lublin, Radziwiłłowska Street 11, 20-080 Lublin, Poland

Piotr M. Jarosz; pjarosz196@gmail.com; ORCID: 0000-0003-0489-2600;
Paweł Oszczydlowski; pawelosz99@gmail.com; ORCID 0000-0001-7406-550X;
Michalina Pytka; michalinapytka@gmail.com; ORCID: 0000-0002-4813-9357;
Justyna Nowaczek; justyna Faustynanowaczek@gmail.com; ORCID: 0000-0001-7622-2345;
Barbara Jodłowska-Jędrych; barbara.jodlowska-jedrych@umlub.pl;
ORCID: 0000-0003-3483-8752

Summary:

Introduction and purpose: Cytology of urine sediment is a diagnostic tool used to screen for urinary tract lesions in two cases: surveillance of patients with a history of urothelial malignancies and patients with unexplained, new onset haematuria. Since 2015 histopathological laboratories have been able to report urine cytology according to The Paris System (TPS). Current studies suggest usefulness of urinary cytology in follow-up of urinary tract malignancies, especially urinary bladder cancer, which is the 13th most deadly throughout the world being responsible for 200 000 deaths in 2018 among neoplasms.

Objective: To review currently available data on PubMed about usefulness urine cytology reporting in follow-up and diagnosis of urinary tract malignancies.

A brief description of the state of knowledge: Advantages of urine cytology examination contain non-invasiveness, high specificity, lower cost than cystoscopy and enable immunohistochemistry performance as well. Implementation of The Paris System for reporting urine cytology has created an universally acceptable and globally used report system. Reporting according to TPS significantly reduced the number of cases described as atypical changes.

Conclusions: Urinary cytology is used to supplement endoscopic evaluation of the urinary tract in the screening and the surveillance of urothelial carcinoma. The Paris System for reporting urinary cytology has clarified the diagnostic categories of urine sediment examination. Cystoscopy and urine cytology are the standard tools for monitoring urinary tract malignancies.

Key words: urinary tract; urinary bladder cancer; urine cytology; The Paris System; immunohistochemistry

Introduction:

Cytology of urine sediment is a diagnostic tool known in medicine for over than 70 years, since dr. George Papanicolaou has suggested its usefulness in detection of urinary tract malignancies [1]. Since then, the histopathologic recommendations of reporting urine cytology (UC) have been changing. None of reporting systems for UC has gained universal acceptance for lacking well-defined criteria; thus, many of urinary tract specimen assessments were reported in different ways and misdiagnoses were made as well [2,3]. Cytopathologists have reported UC according to The Paris System (TPS), since reporting guidelines in 2015 were defined [3]. The major advantage of TPS over previous recommendations is applying universal, evidenced based, cytological assessment criteria, that describe findings in urine sediment, especially atypical urothelial cells (AUC). Previously, this diagnostic category was problematic and aroused controversy between cytopathology laboratories [4]. The application of TPS has lowered the number of AUC diagnoses. [2,5] Some studies show that it may have increased the number of subsequent diagnoses of high-grade urothelial carcinoma in AUC cases [2]. Implementing TPS has raised the diagnostic specificity of urine cytology but it may has decreased diagnostic sensitivity as well [5]. The examination of urine sediment is typically used to screen for urinary tract lesions in two cases: surveillance of patients with a history of urothelial malignancies and patients with unexplained, new onset haematuria [2].

Urinary bladder cancer is in the 10th place among occurring cancers worldwide. 90% of those cancers are urothelial-cell-origin. The remaining 5-10% are usually squamous cell cancers, associated with schistosomiasis infections in less-developed countries. GLOBOCAN data informs about 550 000 new cases of bladder cancer in 2018. The incidence of bladder cancer among women and men is highest in Southern Europe. Risk factors include tobacco and chemical exposure. Urinary bladder cancer is 4 times more frequent in men, but the incidence of this disease rises among females. Some studies suggest that bladder cancer may be associated with genetic mutations. Among neoplasms, bladder cancer is the 13th most deadly throughout the world being responsible for 200 000 deaths in 2018. Mortality is highest in Africa and the Middle-East, regions where cancer is frequently associated with

schistosomiasis. Due to improvement in early diagnosis and treatment, mortality is decreasing in the majority of countries [6].

Objective: The aim of this review was to present currently available knowledge on online database PubMed about usefulness urine cytology reporting in follow-up and diagnosis of urinary tract malignancies.

2. State of knowledge

2.1 The follow up of urinary bladder cancer

Urine cytology is used to supplement endoscopic evaluation of the urinary tract in the screening and surveillance of urothelial carcinoma. The initial evaluation of patients with high recurrence rate of bladder cancer contains: cystoscopy, clinical assessment of renal function, and imaging of the urinary tract, preferably with computed tomography (CT) or urography [7]. Cystoscopy and biopsy combination is a gold standard which allows to definitive diagnosis, staging, and implementing primary treatment [7,8].

Urinary sediment cytology is a preliminary test, which is founded on an assessment of the urinary tract. The key role of urine cytology as an initial diagnostic tool has been burdened due to an increased risk of pre-laboratory mistake. Difficulty in elicitation of reliable results may be caused by: inflammation, menstruation, nocturnal urine, urinary stones [3,9]. Despite of the higher cost and invasiveness, cystoscopy with biopsy keep on a gold standard in follow up of urinary bladder cancer patients due to higher sensitivity and specificity compared to cytology [9,10,11].

2.2 The Paris System of urine cytology reporting

The Paris System (TPS) is a platform that standardises urine cytology reports. One of the goals of TPS' authors was to create a universally acceptable and globally used report system. Diagnostic categories TPS contain: (1) nondiagnostic or unsatisfactory; (2) negative for high-grade urothelial carcinoma (NHGUC); (3) atypical urothelial cells (AUC); (4) suspicious for high-grade urothelial carcinoma (SHGUC); (5) high-grade urothelial carcinoma (HGUC); (6) low-grade urothelial neoplasm (LGUN); (7) other: primary and secondary malignancies and miscellaneous lesions [1].

The diagnostic algorithm of The Paris System is shown in figure 1. If the specimen is covered in lubricant or inflammatory cells, it is deemed an unsatisfactory specimen. The main goal of urine cytology reporting according to TPS is assessment of the lack or the grade of cellular atypia. If the sample contains cells with mild degree of cytological atypia and elements of fibrovascular core, radiology or endoscopy should be performed. No aberration is classified as negative for high-grade urothelial carcinoma (NHGUC). NHGUC category

represents the majority of specimens. The most common type of cells in this category are superficial urothelial cells followed by intermediate and basal urothelial cells [1,3]. Changes associated with urolithiasis, treatment related changes and polyomavirus cytopathic changes are included into NHGUC as well [1]. AUC category has aroused controversy, before TPS was implemented. Now, the criteria of cellular atypia include one major criterion and one minor criterium. The major or required criterion is the presence increased nuclear-cytoplasmic (N/C) ratio (>0.5) of non-superficial cells. The minor criteria, of which one is required, include: (1) irregular nuclear membranes, (2) mild nuclear hyperchromasia, and (3) coarse chromatin [1,3]. Suspicious for High-Grade Urothelial Carcinoma category includes cases with atypia beyond AUC category criteria. The major criteria for classifying the specimen as SHGUC are non-superficial and non-degenerated urothelial cells with an increased N/C ratio (>0.7) with hyperchromasia of the nucleus. The minor criteria include coarse chromatin and irregular nuclear membranes. High-grade urothelial carcinoma (HGUC) in TPS is defined if specimen includes from 5 to 10 severely abnormal urothelial cells with N/C ratio above 0,7 with moderate or severe hyperchromasia, coarse chromatin and irregular nuclear membrane. The necessary morphologic features to classify specimens as low-grade urothelial neoplasm (LGUN) is the presence of fibrovascular cores. They can be seen in any kind of low-grade papillary lesion including papillomas, papillary urothelial neoplasia of low malignant potential, and low-grade urothelial cancer as well [1,3].

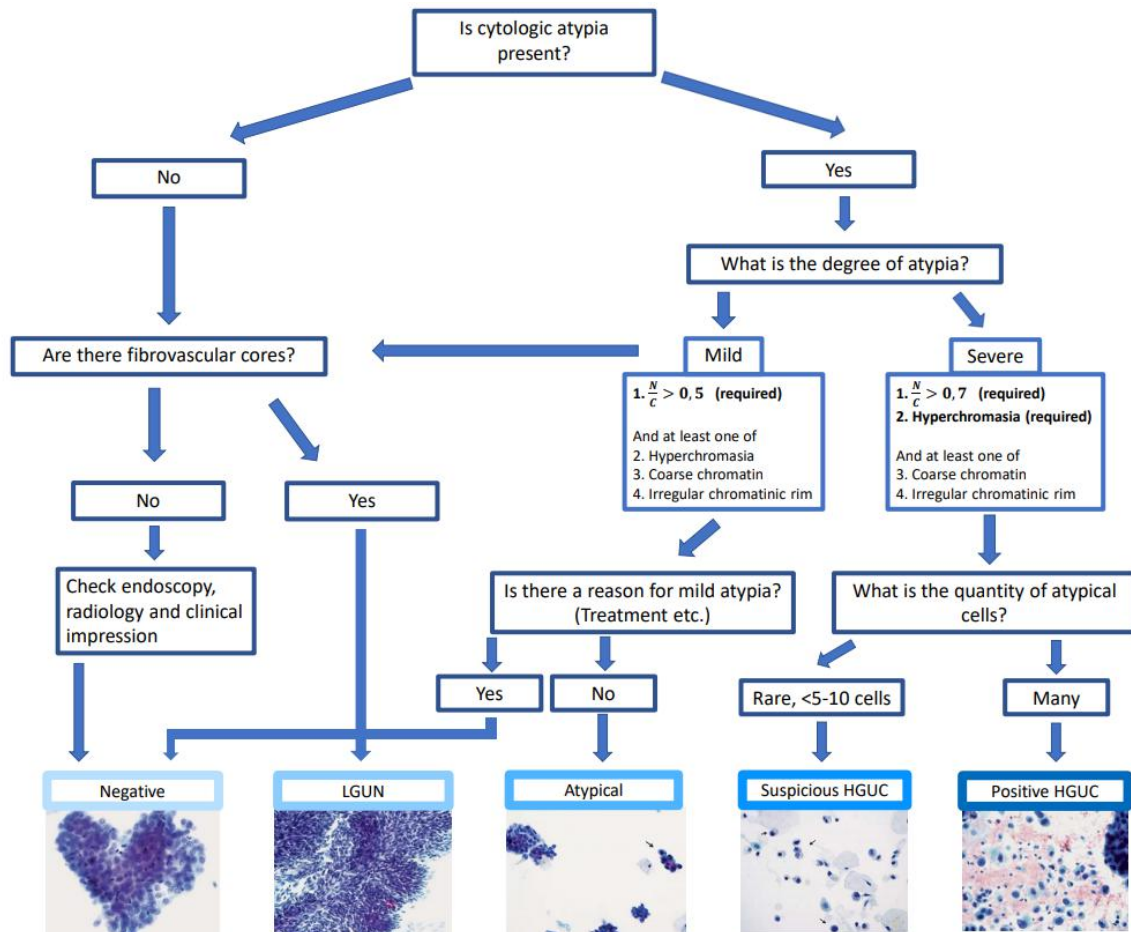


Fig. 1 Algorithmic approach of The Paris System to the diagnosis in the Urinary Tract
Based on Barkan et al, 2016 [1]

2.3 Urinary immunocytology

Discovery of the first monoclonal antibody contributes to understanding immunological pathogenesis a wide variety of diseases and since then, immunohistochemistry has become routine management in many laboratories [12]. Evidence-based knowledge suggests that urinary immunocytology - combination of 2 approaches: cytology and immunohistochemistry as an adjunct, may attain potential role. This approach seems to bear the potential to fortify the diagnostic power of urine cytology in the screening and surveillance of urothelial carcinoma [13,14]. Böhm et al. [14] mentioned that some immunohistochemical markers have already been used in urinary immunocytology. Including cytokeratin stains (cytokeratin-20 and cytokeratin fragments), Ki-67, fibroblast growth factor (FGF) and its receptor (FGFR), p53 and nuclear matrix proteins were enumerated [13-16]. We focused on nuclear matrix protein 22 (NMP-22) and cytokeratin -20 (CK-20). Raised urinary levels of NMP and expression of CK-20 are non-invasive methods of surveillance for urinary bladder cancer [13].

Srivastava et al analysed sensitivity and specificity of variety combinations of urine cytology, CK-20 expression and NMP-22 level. This study revealed the specificity and sensitivity of mentioned combinations were improved than urinary cytology alone [13]. It seems, both examination of urinary cytology combined with NMP-22 level measurement or with CK-20 immunohistochemistry may improve usefulness of these diagnostic tools. In Srivastava et al study, sensitivity and specificity increased from approximately 76% to 88 % when the combination of cytology and NMP was performed [13, 16]. CK20 is an important biomarker that may be useful in recognition transitional cell carcinoma in urinary cytology smears, especially for detection of urothelial carcinoma in atypical cytology. [15]

Overexpression of p16 and Ki-67 was observed in high grade urothelial cancer, because of interference between high-risk human papillomavirus types and Rb gene product. The use of double p16 / Ki-67 staining in urine cytology increased the detectability of invasive cancer, while HGUC or AUC were primarily diagnosed [17].

2.4 Diagnostic value of urine cytology reported according to The Paris System

The AUC category raised many controversies for lacking well-defined criteria [1,2,3]. The priority of implementing TPS was to improve diagnostic sensitivity and specificity, and minimize the category of "cellular atypia " in particular [1-3,18]. Current studies indicate TPS usefulness as a diagnostic tool, especially in follow-up of urinary bladder patients [18-20]. Precise criteria of TPS revealed forced diagnostic value of urinary cytology. Reporting according to TPS significantly reduced the number of cases described as atypical changes. Frequency of detecting SHGUC and HGUC changes were slightly increased. Precise criteria of TPS revealed force of both [21]. The literature suggests that TPS implementation eliminates more of unnecessary indeterminate diagnoses, whereas positive predictive value of diagnosing the malignant category is preserved [22]. In addition, current studies suggest usefulness of immunohistochemistry and cytology combination to identify TPS categories [17]. Further studies should determine legitimacy and the clinical relevance of this hypothesis.

Conclusions:

The urine cytology is a simple, low-cost diagnostic tool, which enables microscopic assessment of urine sediment to screen for urinary tract lesions in two cases: surveillance of patients with a history of urothelial malignancies and patients with unexplained, new onset haematuria. In the absence of a formal reporting system, most cytologic assessments were diagnosed as general categories such as benign, indeterminate, and malignant. The Paris System for reporting urinary cytology has clarified the diagnostic category of urinary sediment examination. Universally acceptable and globally used report system was created; thus, the major of the goals of TPS was achieved. In addition, immunocytology shed a light on new prospects in urine cytology; thus, future generations may better define each category to create the best possible system to accurately diagnose and guide management of urinary tract neoplasms. It is worth underlining that cystoscopy combined with biopsy still constitute the gold standard in follow-up in patients monitored due to risk of urinary tract malignancies.

References:

1. Barkan GA, Wojcik EM, Nayar R, et al. The Paris System for Reporting Urinary Cytology: The Quest to Develop a Standardized Terminology. *Adv Anat Pathol*. 2016;23(4):193-201.
2. Hassan M, Solanki S, Kassouf W, et al. Impact of Implementing the Paris System for Reporting Urine Cytology in the Performance of Urine Cytology: A Correlative Study of 124 Cases. *Am J Clin Pathol*. 2016;146(3):384-390.
3. VandenBussche CJ. A review of the Paris system for reporting urinary cytology. *Cytopathology*. 2016;27(3):153-156.
4. Brimo F, Auger M. The atypical urothelial cell category in the Paris System: Strengthening the Achilles' heel. *Cancer Cytopathol*. 2016;124(5):305-306.
5. Stanzione N, Ahmed T, Fung PC, et al. The continual impact of the Paris System on urine cytology, a 3-year experience. *Cytopathology*. 2020;31(1):35-40.
6. Saginala K, Barsouk A, Aluru JS, Rawla P, Padala SA, Barsouk A. Epidemiology of Bladder Cancer. *Med Sci (Basel)*. 2020;8(1):15. Published 2020 Mar 13.
7. Katharine C, Harry R. Holt, Stephanie C. Hodges, Bladder Cancer: Diagnosis and Treatment, *Am Fam Physician*. 2017 Oct 15;96(8):507-514
8. Mohamed Ismat Abdulmajed, et al. What are the currently available and in development molecular markers for bladder cancer? Will they prove to be useful in the future? *Turk J Urol*. 2014 Dec; 40(4): 228–232.
9. Touijer AK, Dalbagni G. Role of voided urine cytology in diagnosing primary urethral carcinoma. *Urology* 2004 Jan;63(1):33-5.
10. EAU Guidelines. Edn. presented at the EAU Annual Congress Amsterdam 2020. ISBN 978-94-92671-07-3. EAU Guidelines Office, Arnhem, The Netherlands

11. Shahrokh F Shariat, Jose A Karam, Yair Lotan, Pierre I Karakiewicz, Critical Evaluation of Urinary Markers for Bladder Cancer Detection and Monitoring, *Rev Urol*. 2008 Spring; 10(2): 120–135.
12. G. Köhler, C. Milstein; Continuous cultures of fused cells secreting antibody of predefined specificity; *Nature*, 256 (1975), pp. 495-497
13. Srivastava R, Arora VK, Aggarwal S, Bhatia A, Singh N, Agrawal V. Cytokeratin-20 immunocytochemistry in voided urine cytology and its comparison with nuclear matrix protein-22 and urine cytology in the detection of urothelial carcinoma. *Diagn Cytopathol*. 2012;40(9):755-759.
14. Böhm M, Schostak M, Hakenberg OW. Urinary immunocytology--promise or nonseller? A review with an opinion. *Urol Oncol*. 2014;32(4):383-390.
15. Bhatia A, Dey P, Kumar Y, et al. Expression of cytokeratin 20 in urine cytology smears: a potential marker for the detection of urothelial carcinoma. *Cytopathology*. 2007;18(2):84-86.
16. Lekili M, Sener E, Demir MA, Temeltas G, Muezzinoglu T, Buyuksu C. Comparison of nuclear matrix protein-22 with voided urine cytology in the diagnosis of transitional cell carcinoma of the bladder. *Urol Res* 2004; 32: 124–128.
17. Piaton, E. , Advenier, A. , Carré, C. , Decaussin-Petrucci, M. , Mège-Lechevallier, F. , Hutin, K. , Nennig, C. , Colombel, M. and Ruffion, A. (2017), p16/Ki-67 dual labeling and urinary cytology results according to the New Paris System for Reporting Urinary Cytology: Impact of extended follow-up. *Cancer Cytopathology*, 125: 552-562.
18. Singh HK, Bubendorf L, Mihatsch MJ, Drachenberg CB, Nিকেleit V. Urine cytology findings of polyomavirus infections. *Adv Exp Med Biol*. 2006;577:201-212.
19. Barkan, G. A., Wojcik, E. M., Nayar, R., Savic-Prince, S., Quek, M. L., Kurtycz, D. F. I., & Rosenthal, D. L. (2016). The Paris System for Reporting Urinary Cytology: The Quest to Develop a Standardized Terminology. *Acta Cytologica*, 60(3), 185-197.
20. Zheng X, Si Q, Du D, et al. The Paris System for urine cytology in upper tract urothelial specimens: A comparative analysis with biopsy and surgical resection. *Cytopathology*. 2018;29:184–188.
21. Vanda F. et al. Implementation of the Paris System for Reporting Urinary Cytology results in lower atypical diagnostic rates Torous, *Journal of the American Society of Cytopathology* , Volume 6 , Issue 5 , 205 – 210
22. Cowan ML, VandenBussche CJ. The Paris System for Reporting Urinary Cytology: early review of the literature reveals successes and rare shortcomings. *J Am Soc Cytopathol*. 2018;7(4):185-194.