

## MULTIPLE ESOPHAGEAL LEIOMYOMAS: CASE REPORT

Željko Djaković<sup>1</sup>, Dinko Stančić-Rokotov<sup>1</sup>, Ivka Djaković<sup>2</sup>

### ABSTRACT

**Background:** Primary intramural benign tumors of the esophagus are rare. Leiomyomas are the most common benign esophageal neoplasms. Multiple esophageal leiomyomas are very rare, with only a few reports on more than ten coexisting lesions.

**Case study:** A male patient presented with progressing dysphagia and a tumor of the esophageal wall, over 10 cm in length, confirmed by magnetic resonance imaging and endoscopic ultrasound examination. There were no changes of the esophageal mucosa. Multiple fine needle aspirations were performed with inconclusive finding. Surgical exploration through right thoracotomy revealed multiple extramucosal tumors from 5 to 25 millimeters in size. A total of 16 tumors were removed by enucleation without opening the esophageal mucosa. Postoperative period was uneventful.

**Conclusion:** Exact preoperative diagnosis of esophageal submucosal tumors may be difficult to establish without open biopsy. Removal by enucleation is the treatment of choice.

### Keywords:

multiple leiomyomas, diagnostic imaging, dysphagia, esophageal tumor

### INTRODUCTION

Primary intramural benign tumors of the esophagus account for 2% of all esophageal tumors. Leiomyomas are the most common benign esophageal neoplasms. Incidence in autopsy is from 0.005 to 5%. Multiple esophageal leiomyomas are extremely rare. There are only a few reports on more than ten coexisting lesions. [1,2]

### CASE STUDY

A 62-year-old male patient presented with progressing dysphagia and a tumor of the esophageal wall, over 10 cm in length, confirmed by magnetic resonance imaging (Figure 1) and endoscopic ultrasound examination. There were no changes of the esophageal mucosa. Multiple fine needle aspirations were performed with inconclusive finding. After complete diagnostic work-up the diagnosis of a solitary process was established. However, surgical exploration through right thoracotomy revealed

multiple extramucosal tumors from 5 to 25 millimeters in size (Figure 2.A/B). A total of 16 tumors (Figure 2.C) were removed by enucleation without opening the esophageal mucosa. Histopathological diagnosis was Leiomyomatosis oesophagi. Patient was discharged on the seventh postoperative day. Postoperative period was uneventful. There were no swallowing problems since the release. No signs of extramural compression were found at esophagoscopy 40 days after surgery.

### DISCUSSION

Diagnostic algorithm for esophageal submucosal tumors includes computed tomography or magnetic resonance imaging, esophagoscopy, endoscopic ultrasound and needle biopsy [3-5]. Leiomyomas should be considered whenever there is no mucosal involvement. Surgery should be performed if symptoms are present, the tumor grows during follow-up, or coexisting malignancy is suspected [1,4]. Surgical options include esophagectomy or extramucosal enucleation [2]. Multiple leiomyomatosis can mimic malignant disease and sometimes diagnosis is established at the operation.

### CONCLUSION

Although multiple esophageal leiomyomas are extremely rare they should be taken in to consideration, especially if there is no mucosal involvement. Exact preoperative diagnosis may be difficult to establish without open biopsy. Removal by enucleation is the treatment of choice.

### CONFLICT OF INTEREST:

**The authors declare that there is no conflict of interest.**

**The patient gave his informed consent prior to his inclusion in case report.**

### REFERENCES

1. Iwaya T, Maesawa C, Uesugi N. et al. Coexistence of esophageal superficial carcinoma and multiple leiomyomas: A case report. *World J Gastroenterol.* 2006;12(28):4588-92.
2. Prenzel KL, Schäfer E, Stippel D, Beckurts KT, Hölscher AH. Multiple giant leiomyomas of the esophagus and stomach. *Dis Esophagus.* 2006;19(6):504-8.

<sup>1</sup>University Hospital Centre Zagreb, Zagreb, Croatia

<sup>2</sup>University Hospital Centre Sestre milosrdnice, Zagreb, Croatia

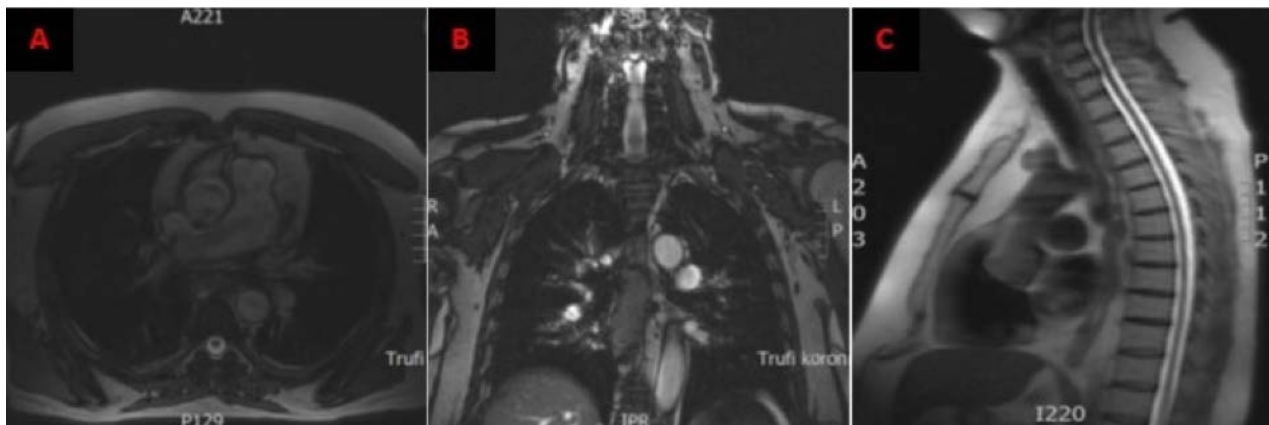**Corresponding author:** Ivka Djaković, University Hospital Centre Sestre milosrdnice, Vinogradska cesta 29, 10000 Zagreb, Croatia

**e-mail:** ivkadj@yahoo.com

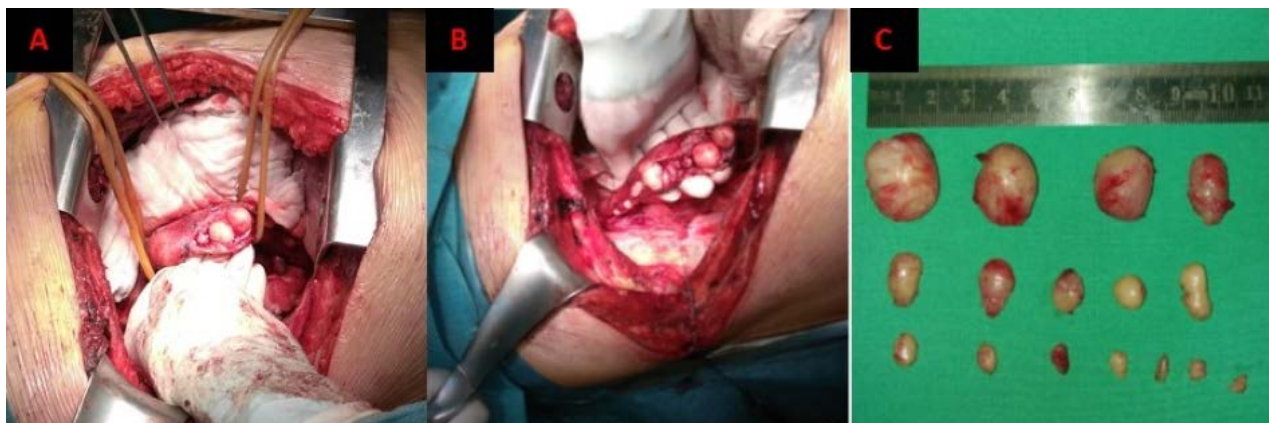
**DOI:** 10.5281/zenodo.4010891

3. Harada A, Maehata Y, Esaki M. Diffuse esophageal leiomyomatosis diagnosed by endoscopic ultrasonography and endoscopic mucosal cutting biopsy. *Dig Endosc.* 2017;29(3):395-396.
4. Okugawa Y, Mohri Y, Toiyama Y et al. Multiple solitary leiomyomas in the esophagus: report of a case. *Surg Today.* 2011;41(4):563-7.
5. Memisoglu E, Agarwal B, Akduman I, Prather C, Collins B, Civelek AC. Multimodality diagnostic imaging of diffuse esophageal leiomyomatosis. *J Comput Assist Tomogr.* 2006;30(1):100-4.

## FIGURES



**Figure 1.** MRI showing a tumor of the esophagus over 10 cm in length.



**Figure 2.**

- A, B) Opening of the muscular layer of the esophagus revealed multiple solid leiomyomas  
 C) A total of 16 enucleated tumors measuring from 5 to 25 mm.