

## ORIGINAL RESEARCHES

DOI: 10.5281/zenodo.3958423  
UDC: 616.613-003.7-089.878



## Percutaneous nephrolithotomy – effective method in contemporary treatment of renal lithiasis. Clinical implementation experience

<sup>1</sup>Pavel Banov, <sup>1</sup>Andrei Galescu, <sup>2</sup>Ilie Ceban, <sup>1</sup>Emil Ceban

<sup>1</sup>Department of Urology and Surgical Nephrology, Nicolae Testemitanu State University of Medicine and Pharmacy

<sup>2</sup>Section of Urology, Timofei Mosneaga Republican Clinical Hospital  
Chisinau, the Republic of Moldova

Authors' ORCID iDs, academic degrees and contributions are available at the end of the article

\*Corresponding author: pavel.banov@usmf.md

Manuscript received May 25, 2020; revised manuscript July 23, 2020; published online August 26, 2020

### Abstract

**Background:** Percutaneous nephrolithotomy (PNL) is the minimally invasive treatment elected for large kidney calculi (>2cm), staghorn calculi, inferior calyceal lithiasis, hard consistency calculi (calcium oxalate monohydrate or cystine) and lithiasis at the level of a malformed kidney. The aim was to analyse the results, which were obtained in the clinic for one year from the implementation of the method in patients with urolithiasis treated by PNL. **Material and methods:** The transversal descriptive study was performed in the group of 43 patients with urolithiasis, subjected to PNL treatment, throughout 2019.

**Results:** The mean age of kidney stone patients treated by PNL was 55±7 years, among them 29 (67.5%) women and 14 (32.5%) men. The anatomical distribution of nephrolithiasis was: right kidney – 21(48.9%) patients, left kidney – 22 (51.1%) patients. The post-operative period in most cases was 5 days. Most of the operated calculi had the following dimensions: 2-2.5 cm in 18 (41.86%) patients, 2.6-4 cm in 16 (37.2%) patients and over 4.5 cm in 9 (20.93%) patients. Postoperative complications were detected and distributed according to Clavien-Dindo scale (CDS). The majority of detected complications were minor (CDS grade 1) in 31 (72%) patients, CDS 2 in 7 (14%) patients and CDS 3b in 6 (14%) patients. Patients with CDS complications grade 4 and 5 were not detected. In 3 (7%) patients the procedure was of “tube-less” type and in 1 (2.3%) patient with double-pointed canal.

**Conclusions:** The success of PNL intervention depends on multiple factors, such as calculus composition, dimension and location in the urinary tract, the patient's body mass index, as well as collecting system anatomy. PNL is a safe and effective procedure with a 90-100% stone-free rate and minor complications.

**Key words:** percutaneous nephrolithotomy, renal lithiasis, complications, Clavien-Dindo scale.

### Cite this article

Banov P, Galescu A, Ceban I, Ceban E. Percutaneous nephrolithiasis – effective method in contemporary treatment of renal lithiasis. Clinical implementation experience. *Mold Med J.* 2020;63(3):5-11. doi: 10.5281/zenodo.3958423.

### Introduction

Renal lithiasis is a complex pathology based on: disorder of metabolism in the human body, a series of lithogenic substances, disorder of their transportation through intestine, kidneys and urinary tract, pathological changes in the physical-chemical and biological characteristics of urine, creation of favourable conditions for the formation of crystals and kidney calculi [1, 2, 3].

The renal lithiasis occupies one of the leading places in the structure of urological diseases in all regions of the world and is found in about 1-12% of the general population. It is well known that urolithiasis mainly affects people of productive age, being very rare in the elderly and children, with a frequency of over 70% in patients aged 20-50 years, which leads to the loss of work capacity. The 8.9% of men and 3.2% of women suffer from urolithiasis during lifetime according to some authors' data [4, 5, 6].

Currently, in highly developed countries 400 thousand people out of 10 million suffer from urolithiasis. There are 85000 of new cases annually, out of which 62000 are recurrent [6]. The global prevalence is estimated between 1-5%, in developed countries 2-13% (with a very large variation from country to country), in developing countries 0.5-1% [7]. The general probability of the population to develop calculi differs in different parts of the world: 1-5% in Asia, 5-9% in Europe, 13% in North America. The annual incidence of urolithiasis is about 0.1-0.4% of the population (Romania, the Republic of Moldova) [8, 9, 10].

Lithiasis reduces the average life expectancy from 5 to 20% of patients, but recurrences are detected in 50-67% of cases [4].

The implementation of percutaneous nephrolithotomy (PNL) in the treatment of renal lithiasis reduced the need

for open surgery, hospitalization time, postoperative pain and its complications, as well as convalescence period minimization [11, 12, 13].

**Percutaneous nephrolithotomy** is a minimally invasive surgery that involves the extraction of renal calculi through a minimal incision, about 2 cm on the skin, with direct kidney approach. PNL is the elective treatment for various forms of renal lithiasis, including staghorn calculi, inferior calyceal lithiasis, hard consistency calculi (calcium oxalate, monohydrate or cystine). This type of intervention offers the benefit of avoiding a large skin incision compared to open surgery, which involves multiple postoperative complications, difficult physical recovery, and also skin scars [14].

**Brief history.** In the last 3 decades of the last century, the treatment of reno-ureteral lithiasis was the subject of special transformations, introduction of minimally invasive endoscopic methods: percutaneous nephrolithotomy (PNL) and retrograde ureteroscopy (URS) with rigid or flexible instruments. In 1941, an obstructive renal calculus was extracted through classic nephrostomy tract by Rupel and Brown [15]. Goodwin and Casey communicated the first time about the performance of percutaneous pyelostomy via extrarenal pelvic percutaneous puncture in a pregnant woman with hydronephrosis, in 1955 [16]. More than 20 years passed from this audacious intervention until the first percutaneous nephrostomy (PCN) for kidney stone percutaneous extraction was performed by Fernstrom and Johanson in 1976. In 1979, Marberger and Alken introduced ultrasonic lithotripsy in the endoscopic treatment of renal lithiasis, the method was afterwards popularized in the USA by Segura and Clayman. Marberger and Miller operated percutaneously on a congenital hydronephrosis, in 1983, introducing Sachse urethrotome through the previously made percutaneous nephrostomy and incised endoscopically the stenotic pyelo-ureteral junction (PUJ), an operation called “pyelolysis”, later popularized by A. D. Smith in the USA, under the name of “endopyelotomy” [17].

The onset in 1980 and extracorporeal shock wave lithotripsy (ESWL) unanimous acceptance shortly after PNL reduced its therapeutic indications. However, PNL maintains its election indication for voluminous pelvic or calyceal calculi, staghorn calculi of any type, or those located in pyelocaliceal cavities, where they cannot be eliminated spontaneously or after ESWL (calyx stem stenoses, calyceal diverticula, stenoses or vicious insertions of JPU etc.) [18].

The first percutaneous nephrolithotomy in Romania in the treatment of renal lithiasis was implemented by Prof. Dr. Radu Boja on January 26, 1986. He practiced it successfully, having accumulated until 2015 over 7.000 cases, thus becoming one of the European leaders in the field [19]. In the Republic of Moldova this method was introduced in 2017.

The aim of the paper is to analyse the results, which were obtained in the clinic for the period of one year from the implementation of the method in patients with urolithiasis treated by PNL.

## Material and methods

The transversal descriptive study was performed within the Department of Urology and Surgical Nephrology of *Nicolae Testemitanu* State University of Medicine and Pharmacy, in *Timofei Mosneaga* Republican Clinical Hospital, in the group of 43 patients diagnosed with urolithiasis, which were subjected to PNL intervention in 2019. Patients underwent a transversal retrospective study (extraction of data from patients' medical records). The patients included in the study were divided into groups, according to age, sex, location and size of the calculi. Prior to the intervention, all the patients underwent a complex clinical evaluation, which included: laboratory examination, imaging examination (computed tomography (CT), ultrasonography (USG)).

In our clinic the indications for PNL were: calyceal calculi with calyceal infundibular stenosis impossible to handle by ESWL or ureteroscopy (URS), renal lithiasis with congenital or acquired stenosis of pyelo-ureteral junction, bulky pelvic calculus (over 2 cm) or multiple lithiasis, staghorn calculus as monotherapy or in combination with ESWL, the extraction of residual stones after open surgery or ESWL, stones that are difficult to disintegrate by ESWL, stone embedded in the pyelo-ureteral junction and stationed over 4 weeks, with hypofunctional kidney, but with acceptable parenchymal index on ultrasound examination.

Descriptive statistics was applied. The results of the study are presented in the form of absolute and relative values. Epi Info™ version 7 software (Centers for Disease Control and Prevention, Atlanta, GA, United States of America) was used for statistical processing.

## Results

The demographic data of the patients with urolithiasis are presented in table 1. The mean age of the patients with urolithiasis treated by PNL was  $55.3 \pm 7$  years, 29 (67.5%) women and 14 (32.5%) men.

Renal calculi anatomical distribution: right kidney – 19 (44.2%) patients, left kidney – 12 (27.9%) patients, bilateral lithiasis was detected in 12 (27.9%) patients. There were according to localization of calculi in the kidney: in renal pelvis – 18 (41.8%) patients, in renal calyx – 16 (37.2%) patients, staghorn calculi – in 9 (21%) patients.

The size of the renal calculi varied from 2 cm up to massive staghorn calculi (> 4.5 cm). Most of the operated calculi had the following dimensions: 2-2.5 cm in 18 (41.86%) patients, 2.6-4 cm in 16 (37.2%) patients and over 4.5 cm in 9 (20.93 %) patients.

The hospitalization period of patients with urolithiasis treated by PNL averaged 5.6 days. The post-operative period in most cases constituted 5 days.

The postoperative complications in patients after PNL are shown in Figure 1. Postoperative complications were stratified according to Clavien-Dindo scale (CDS) [20]. The majority of detected complications were minor (CDS grade 1) in 31 (72%) patients, CDS 2 in 7 (14%) patients and CDS 3b in 6 (14%) patients. Patients with complications of 4-5

Table 1

Demographic data of the patients with urolithiasis

Index	Patients (n=43)
Gender:	
Men, n (%)	14 (32.5%)
Women, n (%)	29 (67.5%)
Age, years (CI 95%)	55.3 (25-78)
Age group:	
18-30 years, n (%)	5 (11.6%)
31-60 years, n (%)	30 (69.8%)
60 years and more, n (%)	8 (18.6%)
Concomitant pathologies:	
Diabetes mellitus, n (%)	5 (11.6%)
Obesity (BMI>30), n (%)	9 (20.9%)
CVS pathologies, n (%)	14 (32.6%)
Urologic status:	
Urinary infection/ chronic pyelonephritis, n (%)	41 (95.3%)
Staghorn lithiasis, n (%)	32 (74.4%)
Multiple lithiasis, n (%)	35 (81.4)
Calculus localization:	
Unilateral, n (%)	31 (72.1%)
On the left, n (%)	12 (27.9%)
On the right, n (%)	19 (44.2%)
Bilateral, n (%)	12 (27.9%)
Calculi dimensions	
2-2.5 cm, n (%)	18 (41.9%)
2.6-4.5 cm, n (%)	16 (37.2%)
> 4.5 cm	9 (20.9%)
Antecedent urolithiasis treatment:	
ESWL, n (%)	7 (16.3%)
Pyelolithotomy, n (%)	9 (20.9%)

Note: CI – Confidence Interval, ESWL – Extracorporeal Shock Wave Lithotripsy, BMI – Body Mass Index, CVS – cardio-vascular system.

grade CDS were not detected. In 3 (7%) patients the procedure was of “tube-less” type and in 1 (2.3%) patient with double tract kidney access.

Clinical case. Abdominal CT of the female patient subse-

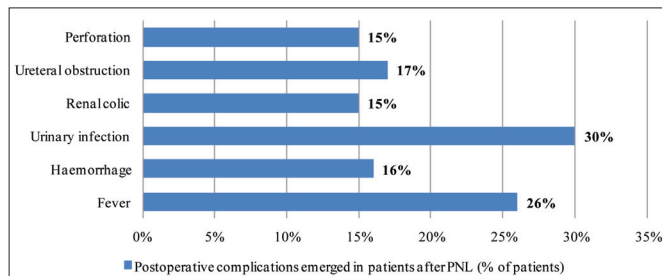


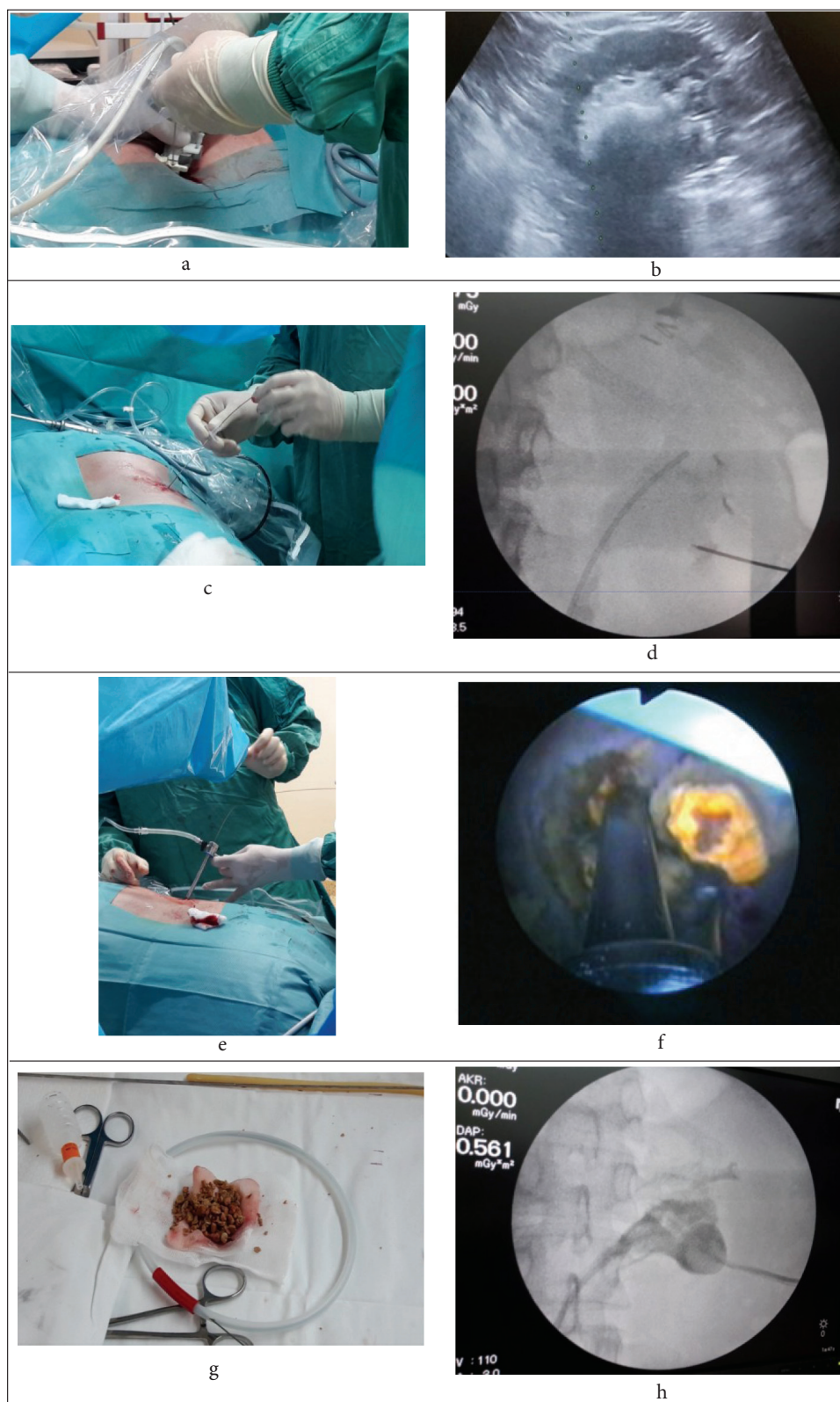
Fig. 1. Postoperative complications emerged in patients after PNL

quently operated on by PNL is shown in figure 2. The stages of the intervention are shown in figure 3. The first stage of PNL procedure is cystoscopy, ureter catheterization by a simple ureteral catheter through which contrast substance was injected which delimited the inferior calyceal area and allowed correct puncture of the chosen calyx under imaging control (fig. 3d. *Puncture of the inferior calyx, imaging visualization*). Once the posterior-inferior calyx punctured, the verification of the puncture correctness is confirmed by the leakage of urine from the puncture needle (fig. 3c. *Placement of the puncture needle, control of urine eliminated through the needle*). The puncture of the pyelocaliceal system can also be done ultrasound-guided, after which the contrast substance can be injected and pyelocaliceal system visualized (fig. 3a. *US-guided kidney puncture*, fig. 3b. *renal USG, staghorn calculus, right kidney, US-guided caliceal puncture trajectory*). In this situation the procedure is much easier if the pyelocaliceal system is dilated. A hydrophilic guide is inserted through the puncture needle which must be flexible enough to allow it to advance to the level of the ureter. The guide is placed and the puncture needle is removed. Alken telescopic metal dilators (dilation path) are successively introduced on the guide, Amplatz sheath is positioned on the last dilator, a working sheath that will ensure the access of the nephroscope in the renal cavities (fig. 3e). After the formation of the path, the nephroscope is inserted and forceps are introduced through working canal with the help of which calculi are extracted as a single piece or calculi fragments (fig. 3f. *Litextraction of calculus fragments*). Calculi fragmentation is done with the help of ballistic type lithotripter. At the end of the procedure, the nephrostomy is mounted with the tip in the pelvis, anchored to the skin

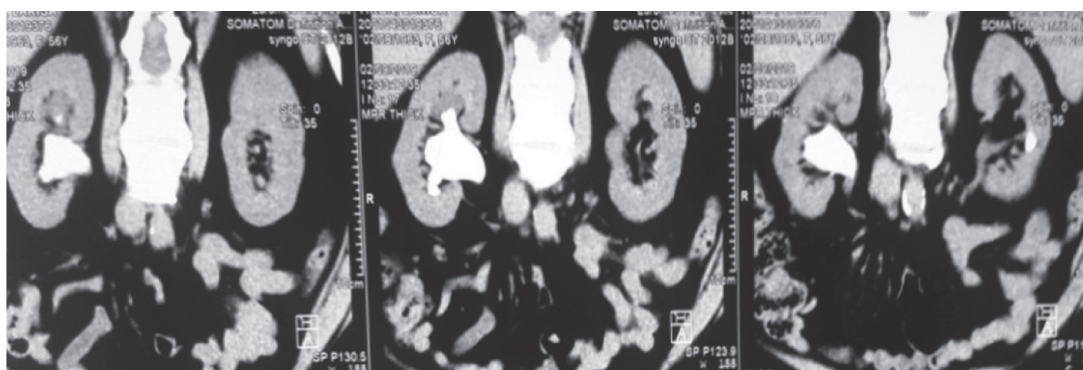

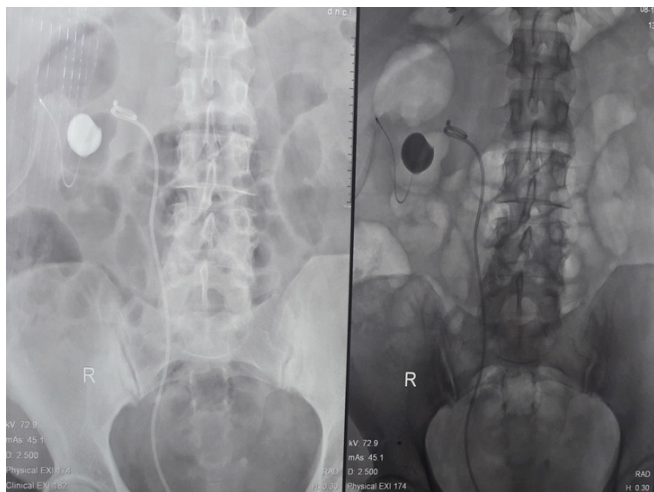
Fig. 2. Abdominal CT, renal staghorn stone on the right





**Fig. 3. Percutaneous nephrolithotomy steps**

- a. Echo-guided kidney puncture.
- b. Renal USG, right kidney staghorn calculus, echo-guided calyceal puncture trajectory.
- c. Puncture needle placement, control of urine excretion through needle.
- d. Inferior calyceal puncture, imaging visualization.
- e. Path dilation with the help of Alken or Amplatz types of telescopic dilators, nephroscope placement.
- f. Lithoextraction of stone fragments.
- g. Fragments of extracted stone.
- h. Placement of the nephrostomy tube in the pyelocaliceal system.



**Fig. 4.** KUB X-ray, postoperative control highlights the absence of suspected opacities in the kidney

and adapted to a collecting bag (fig. 3h. *The placement of the nephrostomy tube in the pyelocaliceal system*).

The kidney-ureter-bladder abdominal roentgenography (KUB) was performed first day postoperatively to confirm the complete calculi fragments elimination (fig. 4) – “total stone-free”. Postoperative evolution was favorable. Foley tube was removed on the 2nd postoperative day, but the nephrostomy tube on the 4th postoperative day after a day of nephrostomy tube clamping, lack of urine extravasation and other signs of urinary passage disorder.

The patient was discharged on the 5th day postoperatively. The ureteral stent was removed one month postoperatively in outpatient conditions.

### Discussions

The obtained data demonstrate that percutaneous nephrolithotomy is effective in the treatment of renal lithiasis, with a comparable efficacy index. The surgical treatment by PNL offers a high rate of “stone free”, and realizes such objectives as complete removal of calculi and renal parenchyma preservation. However, analyzing the results of the method in terms of postoperative complications and recovery time, compared to similar parameters obtained in case of open surgery, we find out that the indications for nephrolithiasis open surgery decreased significantly and are currently practiced in a limited number of cases [21].

PNL replaced open surgery performed in case of large and complex stones, inclusively in children. Although PNL is considered a relatively invasive technique compared to other minimally invasive techniques currently available, the evidence shows that its use in recent years is increasing [22, 23].

Among the factors that increase PNL introduction in practice are: the increasing incidence of nephrolithiasis, the high degree of safety and efficiency of the method. The argument is valid, especially, for calculi larger than 2 cm, staghorn calculi, which are resistant to fragmentation and the calculi from the kidneys with pathological anatomy [24].

Stress and systemic inflammatory syndrome persist both

in the patients treated by PNL and in those treated by open surgery, but without any obvious impact on renal function. However, the extent of stress and systemic inflammatory syndrome is lower in the patients treated with PNL, demonstrating the benefits of the method. Postoperative recovery in the PNL group is faster than in the open surgery group [25]. Therefore, PNL is a safe and feasible procedure with a lesser effect on renal function [26].

The results of the study evaluated PNL effectiveness compared to open surgery in the treatment of complex staghorn calculi. Thus, we found out that PNL is a valuable treatment option for this type of calculi, with a “stone-free” condition rate similar to that of open surgery. PNL has the advantages of reduced morbidity, shorter operating time, shorter hospitalization period and faster return to work [27].

Post-operative complications are an important indicator for determining the success and quality of surgical outcomes. The European Association of Urology recommends the use of Clavien-Dindo classification stratifying complications after urological procedures [28, 29].

The reason for using this standardized and well-defined classification is to eliminate the subjective interpretation of serious adverse events and to underestimate their severity, which leads to complications. For these reasons, we also used this classification. Thus, in our study, the rates of found complications were minimal [30].

At the same time, the obtained results are similar to the researches results of specialists in the field, according to them the implementation, development and improvement of equipment and endourological methods have an important role in improving treatment outcomes, reducing intra- and postoperative complications in patients with renal lithiasis [20].

### Conclusions

Percutaneous nephrolithotomy is the first-choice treatment method. The indications for other methods are more limited, usually addressed to “non-standard” patients. PNL is used in the treatment of staghorn lithiasis as an effective, less aggressive method compared to anatomic nephrolithotomy. Parenchymal loss is less significant than after classic open surgery. The advantages of the method consist in the minimum traumatism, morbidity and hospitalization duration decrease, postoperative complications rate decrease. PNL is also very useful in urological emergencies because there are certain groups of patients who need drainage of the kidney collecting system (obstructive anuria with urosepsis and severe biomolecular imbalance), but the momentary resolution of the calculus is not indicated. The success of PNL depends on many factors, such as calculi composition, size, number, location, body mass index and the anatomy of the kidney collection system. All the above-mentioned variables were carefully taken into consideration in order to maximize the success of PNL intervention. The total stone-free success rate is about 90% after primary PNL and 90-100% after a secondary procedure such as ESWL.

## References

- Ceban E. Particularitățile managementului contemporan la pacienții cu pielonefrită cronică calculoasă [Contemporary management features in patients with chronic calculous pyelonephritis]. *Curierul medical (Chisinau)*. 2013;56(1):12-19. Romanian.
- Tiktinskii OL, Aleksandrov VP. Mochekamennaia bolezni' [Urolithiasis]. Saint Petersburg: Piter; 2000. 384 p. [Russian].
- Moe O. Kidney stones: pathophysiology and medical management. *Lancet*. 2006;367(9507):333-344. doi: 10.1016/S0140-6736(06)68071-9.
- Ceban E. Tratatamentul multimodal al nefrolitiazii complicate [Multimodal treatment of complicated nephrolithiasis]. Chișinău: Medicina; 2013. 206 p. Romanian.
- Banov P, Ceban E. The efficacy of metaphylaxis in the treatment of recurrent urolithiasis. *J Med Life*. 2017;10(3):188-193.
- Turk C, Knoll T, Petrik A, et al. Guidelines on urolithiasis. Arnheim: European Association of Urology; 2015. 102 p.
- Morris D, Wei J, Taub D, et al. Temporal trends in the use of percutaneous nephrolithotomy. *J Urol*. 2006;175(5):1731-1736. doi: 10.1016/S0022-5347(05)00994-8.
- [Ministry of Health of the Republic of Moldova]. Urolitiazia la adult: Protocol clinic național [Urolithiasis in adults: National clinical protocol]. Chișinău: The Ministry; 2011. 56 p. (PCN-88). Romanian.
- Geavlete P, Georgescu D, Muțescu R. Litiazia urinară: Noțiuni generale [Urinary stones: General notions]. In: Sinescu I, Gluck G, editors. *Tratat de Urologie [Treatise on Urology]*. Bucharest: Editura Medicală; 2009. p. 1025-1089. Romanian.
- Stamatelou K, Francis M, Jones C, et al. Time trends in reported prevalence of kidney stones in the United States: 1976-1994. *Kidney Int*. 2003;63(5):1817-1823. doi: 10.1046/j.1523-1755.2003.00917.x.11.
- Bumbu G, Bumbu GA, Berechet M, et al. Urologie: ghid ilustrat de tehnici chirurgicale [Urology: illustrated guide to surgical techniques]. Vol. 1, 2. Bucharest: Editura Medicală; 2013. Romanian.
- Preminger G, Assimos D, Lingeman J, et al. AUA guideline on management of staghorn calculi: diagnosis and treatment recommendations. *J Urol*. 2005;173(6):1991-2000. doi: 10.1097/01.ju.0000161171.67806.2a.
- Falahatkar S, Khosropanah I, Roshani A, et al. Tubeless percutaneous nephrolithotomy for staghorn stones. *J Endourol*. 2008;22(7):1447-1451. doi: 10.1089/end.2007.0285.
- Güven S, İstanbulluoğlu O, Gül U, et al. Successful percutaneous nephrolithotomy in children: multicenter study on current status of its use, efficacy and complications using Clavien classification. *J Urol*. 2011;185(4):1419-1424. doi: 10.1016/j.juro.2010.11.055.
- Rupel E, Brown R. Nephroscopy with removal of stone following nephrostomy for obstructive calculous anuria. *J Urol*. 1941;46(2):177-182.
- Goodwin WE, Casey WC, Wolf W. Percutaneous trocar (needle) nephrostomy in hydronephrosis. *J Am Med Assoc*. 1955;157(11):891-894.
- Stoller M, Meng M. Urinary stone disease. Totowa: Humana Press Inc; 2007. 694 p.
- Srisubata A, Potisat S, Lojanapiwat B, et al. Extracorporeal shock wave lithotripsy (ESWL) vs percutaneous nephrolithotomy (PCNL) or retrograde intrarenal surgery (RIRS) for kidney stones. *Cochrane Database Syst Rev*. 2009;(4):CD007044. doi: 10.1002/14651858.CD007044.pub2.
- Boja R. Chirurgia percutanată reno-ureterală [Percutaneous reno-ureteral surgery]. Constanța: Leda, Muntenia; 2000. 277 p. Romanian.
- Yoon P, Chalasani V, Woo H. Use of Clavien-Dindo classification in reporting and grading complications after urological surgical procedures: analysis of 2010 to 2012. *J Urol*. 2013;190(4):1271-1274. doi: 10.1016/j.juro.2013.04.025.
- Honeck P, Wendt-Nordahl G, Krombach P, et al. Does open stone surgery still play a role in the treatment of urolithiasis? Data of a primary urolithiasis center. *J Endourol*. 2009;23(7):1209-1212. doi: 10.1089/end.2009.0027.
- Skolarikos A, de la Rosette J. Prevention and treatment of complications following percutaneous nephrolithotomy. *Curr Opin Urol*. 2008;18(2):229-234. doi: 10.1097/MOU.0b013e3282f46afc.
- Bayrak O, Seckiner I, Erturhan S, Duzgun I, et al. Comparative analyses of percutaneous nephrolithotomy versus open surgery in pediatric urinary stone disease. *Pediatr Surg Int*. 2012;28(10):1025-1029. doi: 10.1007/s00383-012-3130-6.
- Skolarikos A, Alivizatos G, de la Rosette J. Percutaneous nephrolithotomy and its legacy. *Eur Urol*. 2005;47(1):22-28. doi: 10.1016/j.euro.2004.08.009.
- Ceban E, Banov P, Galescu A, Botnari V. Oxidative stress and antioxidant status in patients with complicated urolithiasis. *J Med Life*. 2016;9(3):259-262.
- Shen P, Wei W, Yang X, et al. The influence of percutaneous nephrolithotomy on human systemic stress response, SIRS and renal function. *Urol Res*. 2010;38(5):403-408. doi: 10.1007/s00240-010-0259-4.
- Basiri A, Karrami H, Moghaddam S, et al. Percutaneous nephrolithotomy in patients with or without a history of open nephrolithotomy. *J Endourol*. 2003;17(4):213-216. doi: 10.1089/089277903765444320.
- Resorlu B, Unsul A, Ziypak T, et al. Comparison of retrograde intrarenal surgery, shockwave lithotripsy, and percutaneous nephrolithotomy for treatment of medium-sized radiolucent renal stones. *World J Urol*. 2013;31(6):1581-1586. doi:10.1007/s00345-012-0991-1.
- Mitropoulos D, Artibani W, Graefen M, et al. Reporting and grading of complications after urologic surgical procedures: an ad hoc EAU guidelines panel assessment and recommendations. *Actas Urol Esp*. 2013;37(1):1-11. doi: 10.1016/j.acuro.2012.02.002.
- Dindo D, Demartines N, Clavien P. Classification of surgical complications: a new proposal with evaluation in a cohort of 6336 patients and results of a survey. *Ann Surg*. 2004;240(2):205-213. doi: 10.1097/01.sla.0000133083.54934.ae.

## Authors' ORCID iDs and academic degrees

Pavel Banov, MD, PhD, Assistant Professor – <https://orcid.org/0000-0002-6904-0743>.

Andrei Galescu, MD, PhD, Assistant Professor – <https://orcid.org/0000-0002-7953-2450>.

Ilie Ceban, MD, Undergraduate – <https://orcid.org/0000-0002-4875-1239>.

Emil Ceban, MD, PhD, Professor – <https://orcid.org/0000-0002-1583-2884>.

## Authors' contribution

PB and IC acquired, interpreted the data, drafted the first manuscript, AG performed most of the analyzed interventions, EC designed the trial and revised the manuscript critically. All the authors revised and approved the final version of the manuscript.

## Funding

The study was supported by *Nicolae Testemitanu* State University of Medicine and Pharmacy. The authors are independent and take responsibility for the integrity of the data and accuracy of the data analysis.

## Ethics approval and consent to participate

The protocol No 6 (of March 3, 2020) was approved by the Research Ethic Board of *Nicolae Testemitanu* State University of Medicine and Pharmacy. Written informed consent was obtained from all participants of the study.

## Conflict of Interests

The authors have no conflict of interests to declare.