



CODEN [USA]: IAJPBB

ISSN: 2349-7750

**INDO AMERICAN JOURNAL OF  
PHARMACEUTICAL SCIENCES**Available online at: <http://www.iajps.com>

Research Article

**VIRAL INFECTIONS IN THE ACQUIRED  
IMMUNODEFICIENCY SYNDROME**<sup>1</sup>Dr Saba Islam, <sup>2</sup>Dr. Komal Zaheer, <sup>3</sup>Dr Aiman Nawal<sup>1</sup>DHQ Sahiwal<sup>2</sup>Fatima Jinnah Medical College Lahore<sup>3</sup>LGH Lahore**Article Received:** April 2020**Accepted:** May 2020**Published:** June 2020**Abstract:**

*The accompanying correspondence is a tripartite summary of the work of the viral disease in (AIDS). The main segment describes the effect of astute viral contamination in AIDS; it discusses foreach infection, clinical introduction and determination, research facility demonstration methodologies (through emphasis on electron microscopy) and corrective mediations undertaken till now. Our current research was conducted at LGH Lahore from January 2019 to December 2019. The following section examines existing hypotheses about the pathogenesis of AIDS and designates symptomatic and remedial ways of treating the disorder itself. The final segment lists the ultrastructural features of cells of AIDS cases, several of which were wrongly distinguished as etiological operators.*

**Key words:** *Viral Infections, HIV Syndrome.*

**Corresponding author:**

**Dr. Saba Islam,**  
DHQ Sahiwal

QR code



Please cite this article in press Saba Islam et al., *Viral Infections In The Acquired Immunodeficiency Syndrome.*, Indo Am. J. P. Sci, 2020; 07(06).

**INTRODUCTION:**

Infections present an interesting situation in the pathogenesis of (AIDS), addressing not only the essential etiological specialist of the disease, but also a significant reason for the corresponding artistic contamination [1]. Antiviral treatment is therefore of paramount importance for the palliative treatment and eventual cure of AIDS [2]. Due to the significant lack of cellular resistance that encapsulates persistent AIDS, the infections usually dispensed or kept under control in the immunocompetent host become overwhelming. We are moving towards a time when the treatment of viral operators will be as typical as that of microscopic organisms [3]. As an ever-increasing number of operators are seen as key players in the fight against viral diseases, accurate and recognizable evidence of causal infections is gradually proving to be fundamental. A few drugs that have been shown to be antivirally viable in hospitalized patients without immunodeficiency have been used with some success in people with AIDS [4]. Although continuous supportive treatment is generally necessary in these patients to prevent the recurrence of viral disease, in many cases an improvement in quality of life and prolongation of life has been achieved. For this reason, the infectious diseases encountered in AIDS cases, their clinical introduction, conclusion and treatment are discussed [5].

**MATERIALS AND METHODS:**

Our current research was conducted at LGH Lahore from January 2019 to December 2019. The following section examines existing hypotheses about the pathogenesis of AIDS and designates symptomatic and remedial ways of treating the disorder itself. The final segment lists the ultrastructural features of cells of AIDS cases, several of which were wrongly distinguished as etiological operators. General strategies for disconnection of infections and conclusion of viral diseases by research facilities have been described (Suing, 1982; Malherbe and Strickland-Chumley, 1985; Rothchild and Cohen, 1988; White and Fener, 1989). Techniques for locating and proving differentiation of infections by electron microscopy have been disseminated (Miller, 1986; Duane and Anderson, 1988). Strategies for infection fixation and distinctive evidence of AIDS-related infections will be briefly presented here.

**Example of Preparation:** Many of the infections transmitted by AIDS patients, including hepatitis B contagion and human immunodeficiency virus infection itself, are equipped to infect immunocompetent individuals. As will be discussed below, the tissue transmission of these infections is surprisingly different; HIV has been separated from natural fluids from various destinations as well as from white blood cells. Thus, all examples of supposed AIDS patients must remain cured with extraordinary care. Gloves must be worn systematically during all manipulations before becoming obsessed. The examples would be handled in the biohazard hood if probable; otherwise, in the quiet corner gone from traffic in addition on some permeable plastic paper. Extraordinary measures should remain taken to avoid the production of pressurized canned products. Entirely disposable products should remain autoclaved previously disposal and all devices and media should be purified. Effective antiseptics remain 12% Clorox or 78% ethanol (FDA, 1987). The test drop remains sited on a parafilm, and a membrane frame covered with carbon and formvar is allowed to remain on the drop for 5 to 10 minutes. The frame remains then depleted through fluted paper and moved to the drop of 3% glutaraldehyde in a 0.2 M phosphate cradle, pH 8.7, for 3-7 min; this is then washed in contact with four drops of refined water, also depleted again. Without the current obsession step, the sample holder of matrix and magnifying instrument must be properly sanitized following the examination. Negative recoloring is cultivated by placing the washed and depleted matrix on a drop of aqueous uranyl acetic acid derivative or a 2 % phosphate state for 35 to 60 seconds and depleting it. Underneath not any circumstances should the example remain assorted with the negative staining and sprayed onto grid. Tissue tests Biopsies for ultrafine separation would be handled regularly (e.g., in 3% glutaraldehyde, 3% osmium tetroxide, in addition a 4% uranyl acetic acid derivative trailed through an implant) (Hayat, 1982). Quick installation techniques in less than 2 hours were described. Improvement of tissue culture Sometimes a little concentration of infection blocks representation by one of the recently discussed strategies. Allowing one or two rounds of infection repetition in tissue culture might intensify the number of viruses to the distinguishable level in electron magnification instrument. Miller (1987) discusses cell lines suitable for immunization.

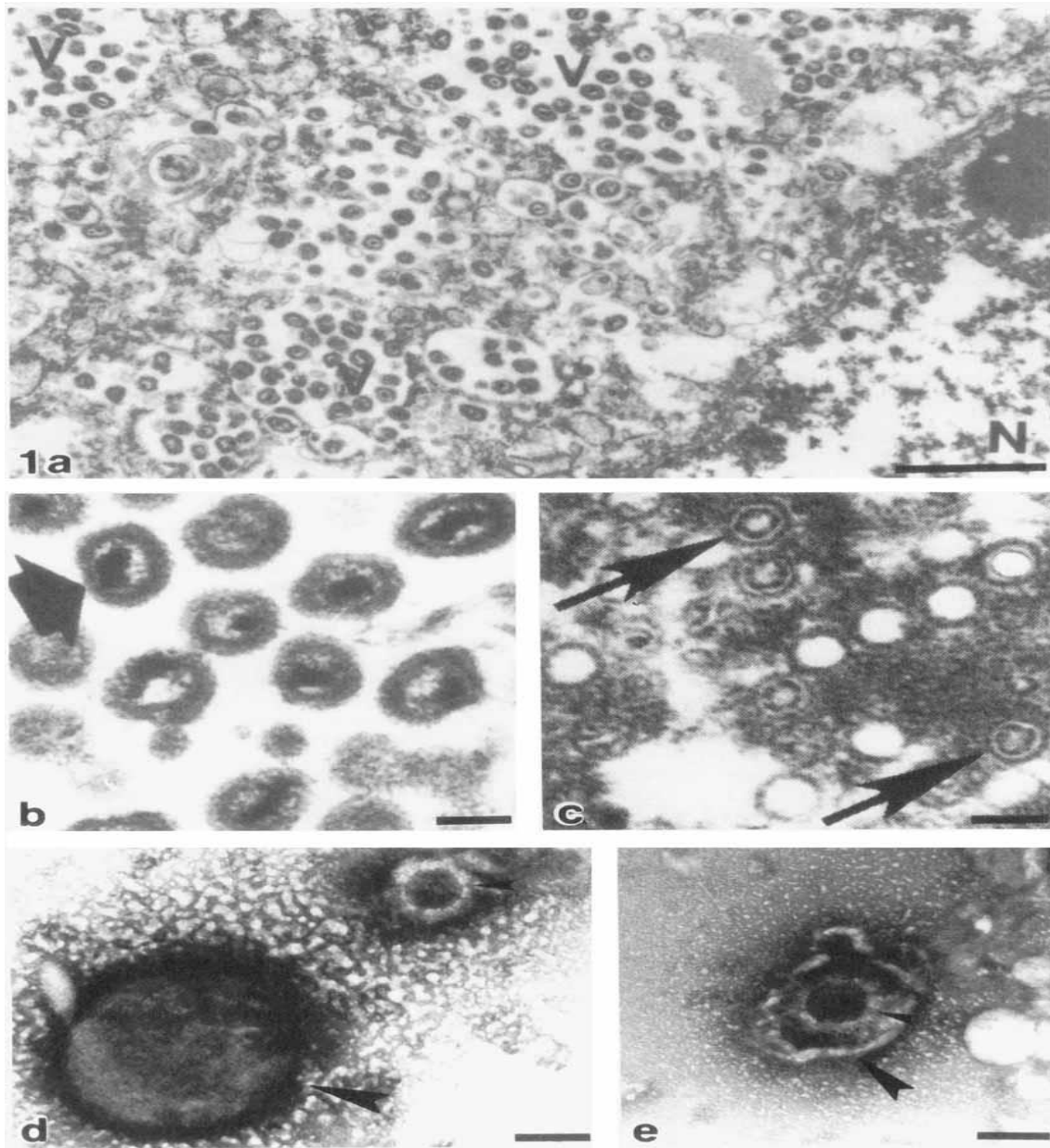
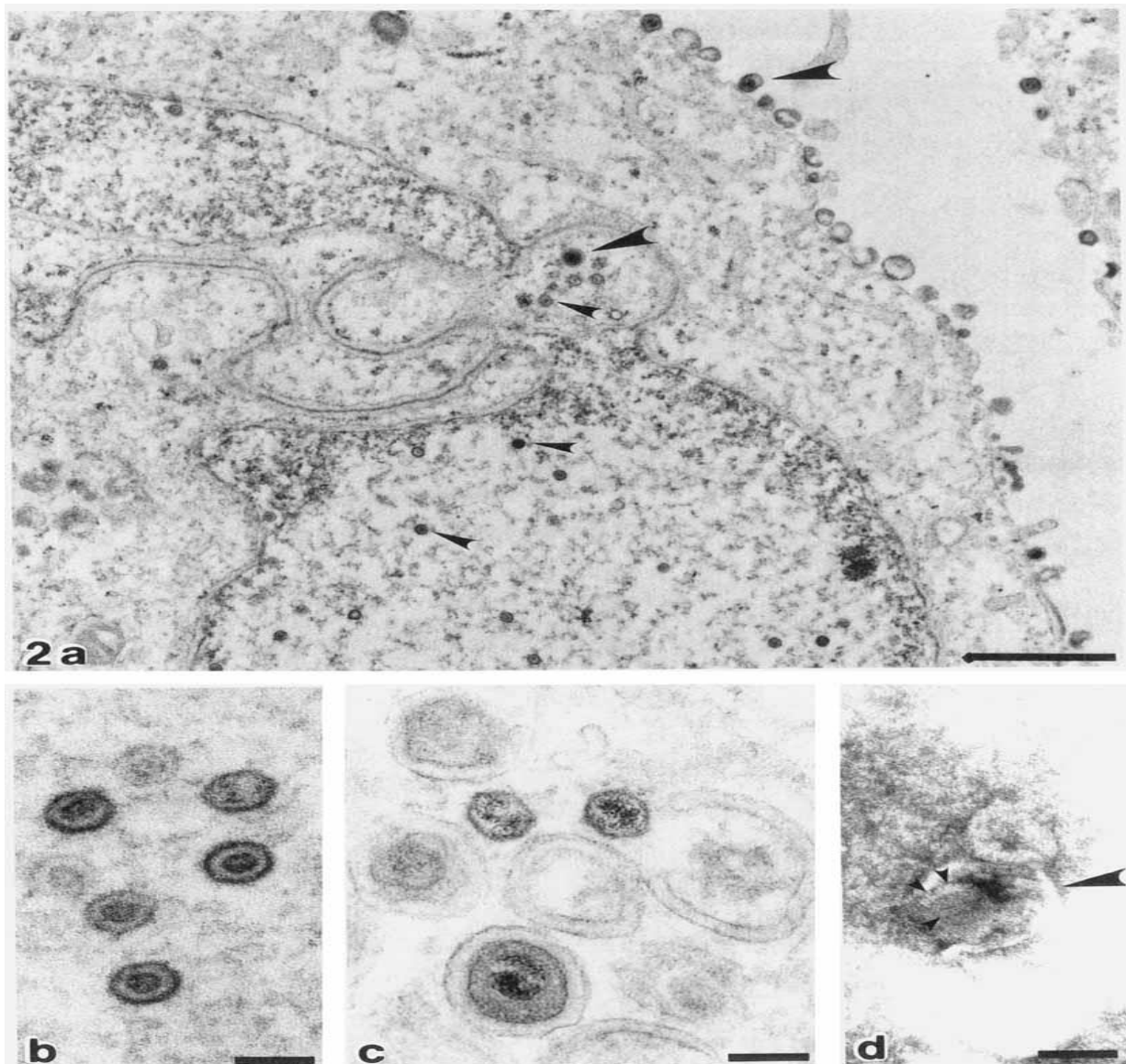


Figure 1:



**Figure 2:**

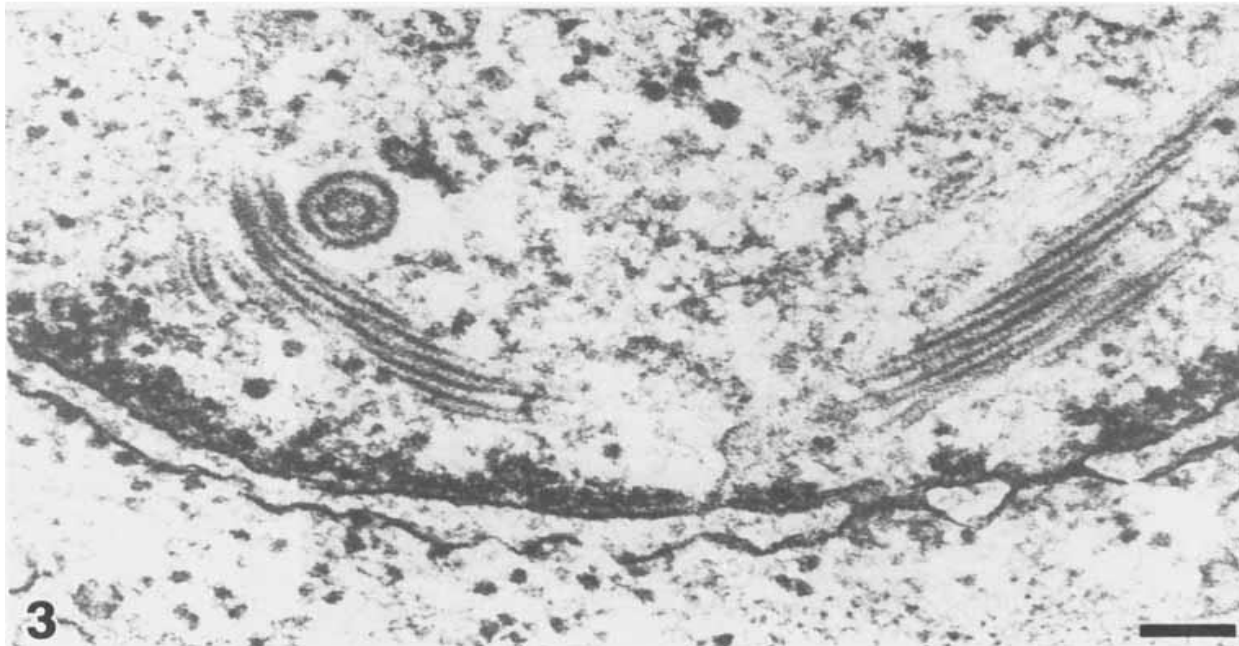
### RESULTS AND DISCUSSION:

Cytomegalovirus contamination, which remains regularly an indicative in typical subjects, remains recurrent and extreme in AIDS cases (Quinan et al., 1988). Undoubtedly, the majority of the literature on infectious diseases in AIDS cases concerns CMV; examinations after death show that 35-42% of those cases are infested. The sites of contamination are lungs, the focal sensory system, the retina, the gastrointestinal system (GO tract, reticuloendothelial framework, kidneys also adrenals (Guard et al., 1985; Jensen et al., 1987; Rodrigues et al., 1987; Snider et al., 1984; Tucker et al., 1985). The infection was disconnected from blood, salivation, pee, semen, uterine secretions, breast milk and CSF (Drew et al., 1982; Edwards et al., 1986; El-Mikki et al., 1986; Quinan et al., 1983; Stagno et al., 1981). Interstitial CMV pneumonia is an important reason of illness and death in AIDS

cases (Machar et al., 1984) [6]. Most often, CMV in addition *Pneumocystis carinii* are found together, and CMV were found in speculated cases of *P. carinii* pneumonia that remained negative for protozoan (Barbour, 1985; Gorelik et al., 1987 Bronchoscopic lavage were effective in beginning conclusion of occasional CMV pneumonia (Golden et al., 1980). Distinct herpes simplex also herpes zoster, CMV is not neurotropic and does not conservatively reason neurological illness in immunocompetent persons (Duchovny et al., 1980) [7]. In immunocompromised hosts, though, this may produce encephalomyelitis or demyelination short of irritation of focal and peripheral sensory systems. The constituent by which demyelination happens is unclear [8]. The thesis of CMV as an etiological factor in Koch's disease is not short of logical inconsistency. Dötzt and Berman (1984) designated SK cases through positive neutralizing agent titers

against HSV without being hostile to CMV antibodies. HBV manifested in the tissues of SK as did CMV (Siddiqui, 1980) [9]. In any case, the majority of indication collected to date suggests that CMV has an impact on the etiology of KS. CMV was inconsistently considered as the causal aspect in

non-neoplastic skin illness. In one instance, infection manifested itself in surprising purpuric skin sores in an AIDS case (Penney and Hicks, 1986). The writers of our current research focused on significance of recognizing such wounds from famous wounds found in poxvirus diseases [10].



**Figure 3:**

### CONCLUSION:

The significance of considerate viral procedures in AIDS cases cannot be overemphasized. At present, viral illnesses account for the significant share of illness and death practiced by those cases. The rate of viral illness in AIDS patients remains regularly quick and needs rapid and accurate symptomatic methodologies. The treatment of viral diseases in AIDS cases, although presently distant from pleasant, has some advantages and remains under serious consideration. Later, clarification of the pathogenesis of AIDS and definitive triumph of illness will in any case rest to some extent on a sympathetic of the viral components. This remains anticipated that insightful modalities described above will do much work in this understanding.

### REFERENCES:

1. Twu S-J, Huang Y-F, Lai A-C, Ming N, Su I-J. Update and projection on HIV/AIDS in Taiwan. *AIDS Educ Prev.* 2004;16(Supplement A):53–63. doi:10.1521/aeap.16.3.5.53.35530.2.
2. Taiwan Centers for Disease Control and Prevention. [Surveillance of HIV]. In <http://www.cdc.gov.tw>. [Accessed 3 February in 2017].
3. Hodge WG, Seiff SR, Margolis TP. Ocular opportunistic infection incidences among patients who are HIV positive compared to patients who are HIV negative. *Ophthalmology.* 1998;105:895–900. doi:10.1016/S0161-6420(98)95033-3.4.
3. Cunningham ET Jr, Margolis TP. Ocular manifestations of HIV infection. *N Engl J Med.* 1998;339(4):236–244. doi:10.1056/NEJM199807233390406.5.
4. Rodrigues ML, Rodrigues MDLV, Figueiredo JFDC, DeFreitas JAH. Ocular problems in Brazilian patients with AIDS before and in highly active antiretroviral therapy (HAART) era. *Braz J Infect Dis.* 2007;11:199–202.6.
5. Goldberg DE, Smith LM, Angelilli A, et al. HIV-associated retinopathy in the HAART era. *Retina.* 2005;25:633–649.7.
6. Bekele S1, Gelaw Y, Tessema FO. Ocular manifestation of HIV/AIDS and correlation with CD4+ cells count among adult HIV/AIDS patients in Jimma town, Ethiopia: a cross-sectional study. *BMC Ophthalmol.* 2013 May 27;13:20. doi:10.1186/1471-2415-13-20.8.
7. Lai TY, Wong RL, Luk FO, et al. Ophthalmic manifestations and risk factors for mortality of HIV patients in the post-highly active antiretroviral therapy era. *Clin Experiment Ophthalmol.* 2011;39:99–104. doi:10.1111/j.1442-9071.2010.02400.x.9.

8. Ausayakhun S, Watananikorn S, Ittipunkul N, et al. Epidemiology of the ocular complications of HIV infection in Chiang Mai. *J Med Assoc Thai.* 2003;86:399–406.10.
9. Gharai S, Venkatesh P, Garg S, Sharma SK, Vohra R. Ophthalmic manifestations of HIV infections in India in the era of HAART: analysis of 100 consecutive patients evaluated at a tertiary eye care center in India. *Ophthalmic Epidemiol.* 2008;15:264–271. doi:10.1080/09286580802077716.