

Original Research Article

Surgical Treatment of Gangrene of the Urine Bladder, Review of Three Cases

Ivchev J.^{1,2*} and Ivchev Lj.¹**Abstract**

¹Department of Urology, General City Hospital "8th September", Skopje, R of North Macedonia

²Faculty of Medical Sciences, University "Goce Delcev"- Stip, R of North Macedonia

*Corresponding Author's E-mail: jovanivchev@yahoo.com

Gangrene of the urine bladder is a very rare life threatening acute urology disease that requires extremely fast diagnoses followed by urgent and radical surgical treatment. Fronstein once noticed that gangrene of the urine bladder is so rare that it should be described each appearance as a separate case. The first such case was described in 1650 by Willis (Carson, 1925). Two etiology factors have so far been described mostly for the occurrence of the vesical gangrene. The first is the gangrenous cystitis that occurs in untreated acute cystitis in patients with reduced immunity or in female who developed gangrenous cystitis post-partum (Prabhat et al., 2019), and the second factor is described as a complication after embolization of the hypogastric artery or complication during pelvic thrombophlebitis (Sieber, 1994). In majority of cases described, surgical treatment consisted of partial or total cystectomy and temporary urinary derivation (Stirling and Hopkins, 1934). The aims of the study was to analyze the diagnostic methods, operative and post-operative treatment and follow-up of the patients with gangrene of the urine bladder treated at our urology department. The results obtained was compared with the existing data in the world literature and relevant scientific papers and determine the justification for second surgical intervention in order perform definitive urinary derivation with ileal conduit. Three consecutive cases of vesical gangrene have been treated in the past 18 months at the Urology Department at the General City Hospital "8th September" – Skopje, R of North Macedonia. All three were admitted as acute abdomen with septic condition and treated at the Emergency Center. Two of them were treated due to complete vesical gangrene and the third was treated first as acute abdomen caused by fibrotic obstruction of the sygma as a complication after radiation therapy received for cervical cancer. The third case was treated for vesical gangrene developed eight months after the first surgery as a complication due to persistent recto-vesico-vaginal fistula. The intraoperative finding revealed acute phlegmonoso-gangrenous peritonitis caused by complete gangrene and perforation of the urine bladder in two cases, and partial vesical gangrene with vesico-recto-vaginal fistula developed eight months after partial resection and colostomy in the third case. Emergency surgery with radical cystectomy and ureterocutaneostomy was performed on the patients with complete gangrene and perforation of the urine bladder. The third patient was treated as complication of persistent urinary infection due to recto-vesico-vaginal fistula and performed radical cystectomy with ileal conduit as permanent urinary derivation. Six months after the emergency surgery urinary diversion with ileal conduit was performed in one of the patients due to complete stenosis of the ureterocutaneostomy and acute obstructive renal failure with metabolic acidosis. The two years' post operative follow up showed good health with normal function of the ileostoma in both patients and normal function of the ureterocutaneostoma in one patient with normal values of the electrolytes and blood degradation products. Urine bladder gangrene is rare but extremely urgent life threatening condition which requires radical surgical treatment during the first 24 hours from its appearance. Acute occlusion of one of the hypogastric arteries with thromb embolus, as a complication of pelvic phlebothrombosis, according to our experience is the most common cause for its appearance. Long presence of vesico-rectal or vesico-vagino-rectal fistula could also result with partial necrosis of the urine bladder wall. But unlike the acute occlusion of the hypogastric artery, it has chronic symptoms and signs. Urgent radical cystectomy with bilateral ureterocutaneostomy in the first stage and urinary diversion with ileal conduit in second stage is so far the most convenient surgical solution for these acute urinary conditions

Keywords: Urine bladder gangrene, vesico-vagino-rectal fistula, pelvic phlebothrombosis, chronic cystitis, post partal cystitis.

INTRODUCTION

Gangrene of the urine bladder is a very rare life threatening acute urology disease that requires extremely fast diagnoses followed by urgent and radical surgical treatment. Fronstein once noticed that gangrene of the urine bladder is so rare that should be described each appearance as a separate case. The first such case was described 1650 by Willis (Carson, 1925). Two etiology factors have so far been described mostly for the occurrence of the vesical gangrene. The first is the gangrenous cystitis that occurs in untreated acute cystitis in patients with reduced immunity or in female who developed gangrenous cystitis post-partum (Prabhat et al., 2019), and the second factor is described as a complication after embolization of the hypogastric artery or complication during pelvic thrombophlebitis (Sieber, 1994). In the majority of cases described, surgical treatment consisted of partial or total cystectomy and temporary urinary derivation (Stirling and Hopkins, 1934).

Aims

- Analysis of the diagnosis, operative and post-operative treatment and follow-up of the patients with gangrene of the urine bladder treated at our urology department.
- Comparative analysis of the results obtained with the existing data in the world literature and relevant scientific papers regarding surgical method used for the treatment of such cases.
- Determining the justification for second surgical intervention and performing definitive urinary derivation with ileal conduit.

MATERIAL AND METHODS

Three consecutive cases of vesical gangrene have been treated in the past 18 months at the Urology Department at the General City Hospital "8th September" – Skopje, R of North Macedonia. All three were admitted as acute abdomen with septic condition and treated at the Emergency Center. Two of them were treated due to complete vesical gangrene and the third was treated first as acute abdomen caused by fibrotic obstruction of the sygma as a complication after radiation therapy received for cervical cancer. The third case was treated for vesical gangrene developed eight months after the first surgery as a complication due to persistent recto-vesico-vaginal fistula. The patient had also ren arcuatus with bilateral uretero-hydronephrosis 2-3 degree.

RESULTS

Clinical examination, RTG of abdomen, ultrasound, CT of

abdomen, pelvic CT angiography and complete laboratory analyses were used for diagnosis and indication for urgent surgical treatment of the patients with the signs of sepsis and acute abdomen. The intraoperative finding revealed acute phlegmonoso-gangrenous peritonitis caused by complete gangrene and perforation of the urine bladder in two cases, and partial vesical gangrene with vesico-recto-vaginal fistula developed eight months after partial resection and colostomy in the third case. Emergency surgery with radical cystectomy and ureterocutaneostomy was performed on the patients with complete gangrene and perforation of the urine bladder. The third patient was treated as complication of persistent urinary infection due to recto-vesico-vaginal fistula and performed radical cystectomy with ileal conduit as permanent urinary derivation. Six months after the emergency surgery urinary derivation with ileal conduit was performed in one of the patients due to complete stenosis of the ureterocutaneostomy and acute obstructive renal failure with metabolic acidosis. The pathohistological findings confirmed presence of gangrene of the urine bladder wall and phlegmona of the lower part of the peritoneum. The two years' post operative follow up shows good health with normal function of the ileostoma in both patients and normal function of the ureterocutaneostoma in one patient with normal values of the electrolytes and blood degradation products.

DISCUSSION

In the current literature, the etiologic factors for the occurrence of urine bladder gangrene include: urinary infections, urinary retention, colovesical fistulas (Raza et al., 1999), pelvic thrombophlebitis and recently more often iatrogenic causes such as pelvic radiation, pelvic surgery and the use of chemotherapeutic agents. In our cases the reason for vesical gangrene in two patients was acute and total occlusion of the a.iliaca interna s hypogastrica with thrombotic embolus. In first case it occurred as a result of pelvic thrombophlebitis due to hypercoagulability of the blood and cardiac arrhythmia (Figure 1,2,3).

In the second patient thrombembolia of the hypogastric artery occurred one week after the hip implant surgery, complicated with phlebothrombosis of the right leg and pelvis (Figure 4,5).

Unlike the first two cases in the third patient the vesical gangrene was caused by a prolonged bladder infection caused by the appearance of a vesico-recto-vaginal fistula. The patient also had ren arcuatus with bilateral uretero-hydronephrosis (Figure 6,7).

The clinical manifestation according to our described cases could be divided in two categories: acute and

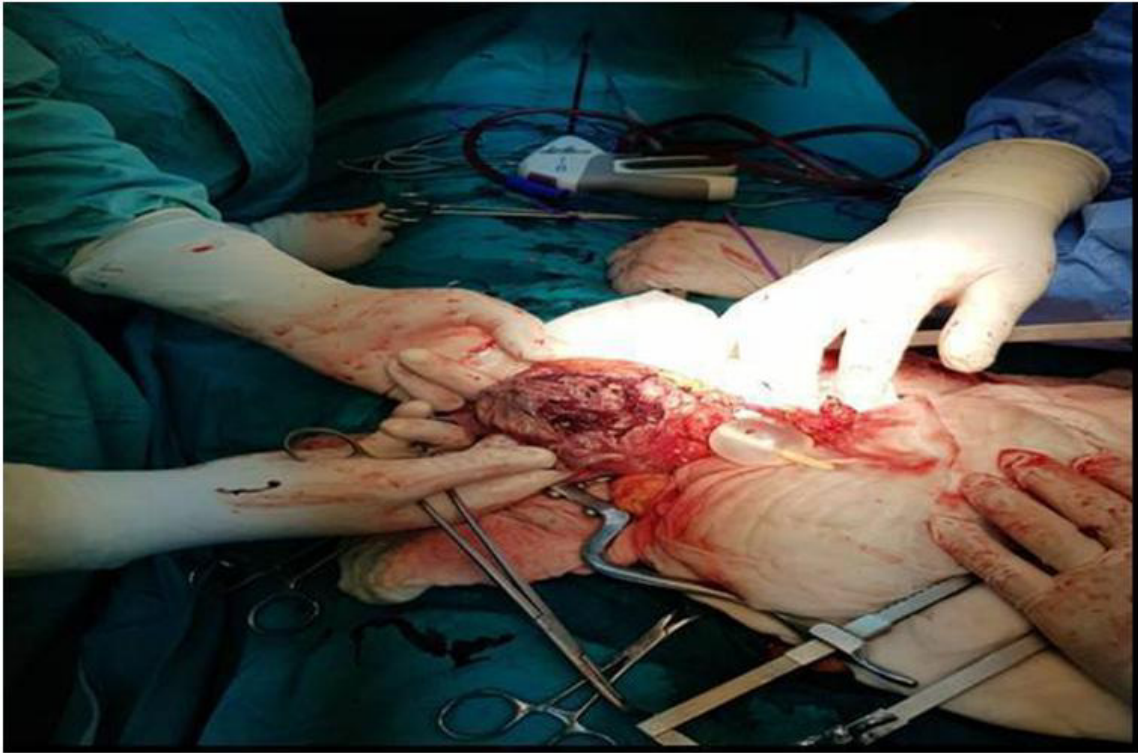


Figure 1. Complete gangrene and perforation of the urine bladder wall

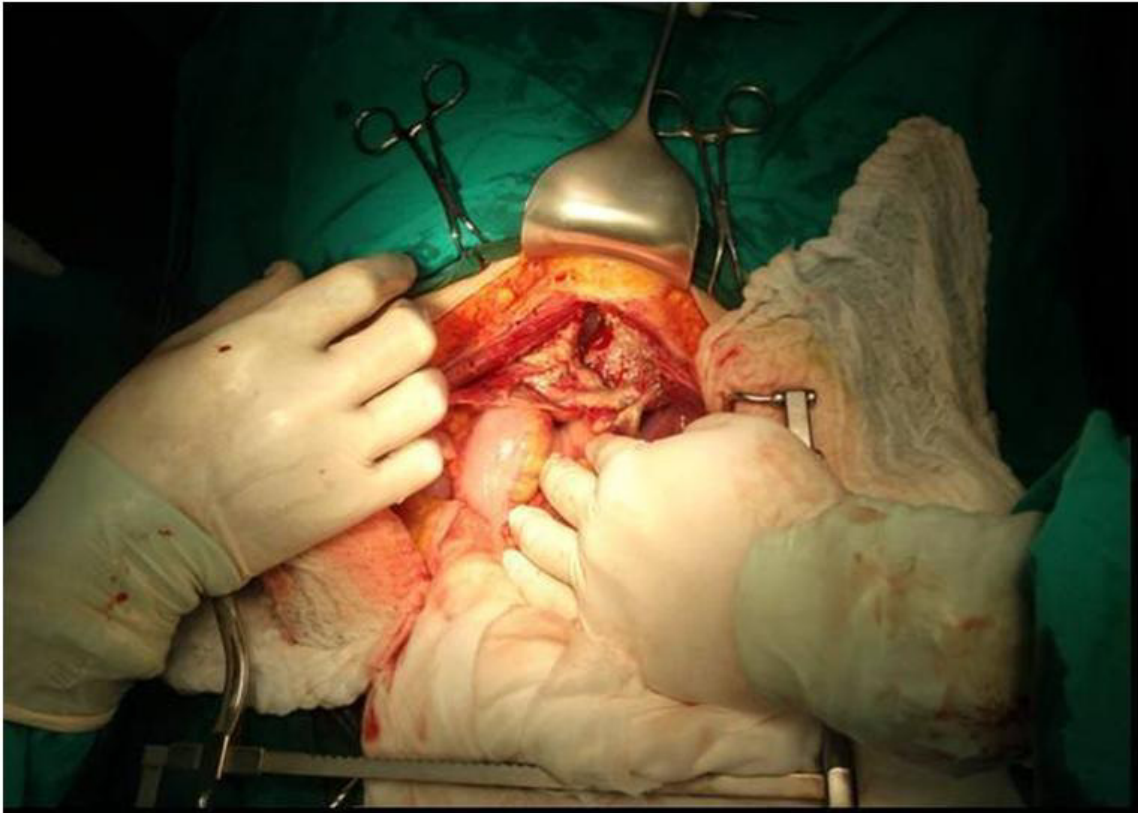


Figure 2. Perforation of the front wall

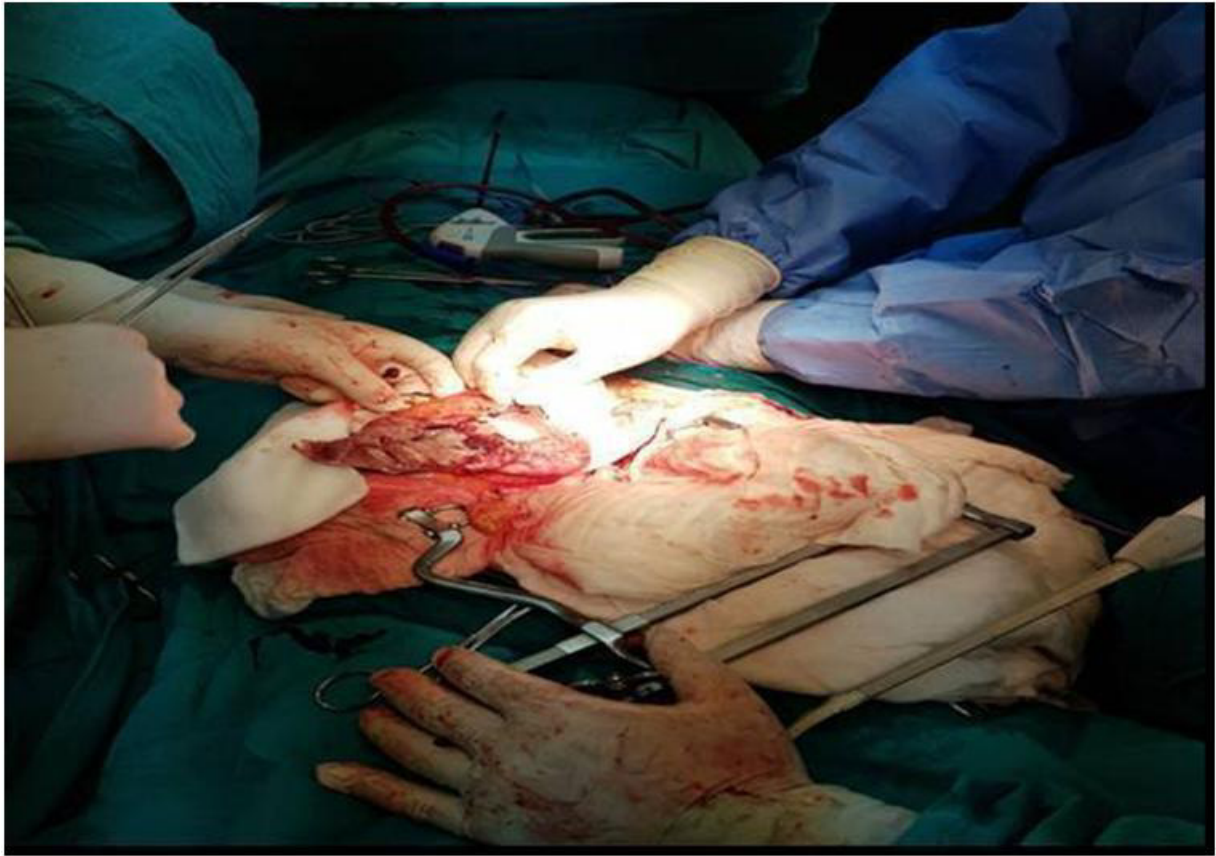


Figure 3. Gangrene of the front and upper wall with phlegmonoso-gangrenous peritonitis

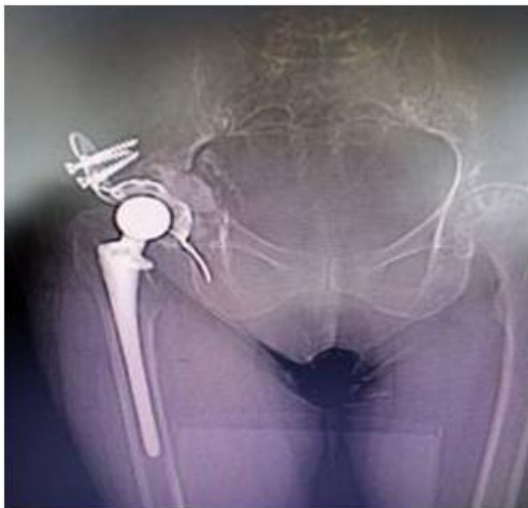

Figure 4. Right hip implant one week

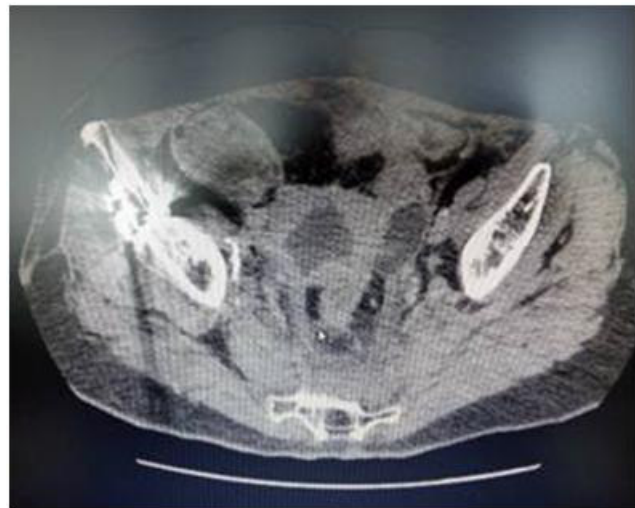


Figure 5. Gangrene of the right vesical wall before the appearance of the UB gangrene

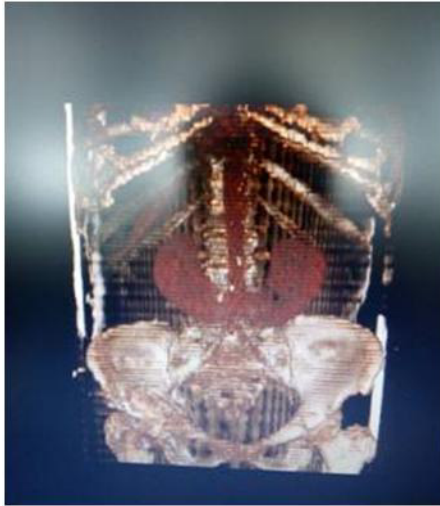

Figure 6. Ren Arcuatus in patient with colovesical fistula

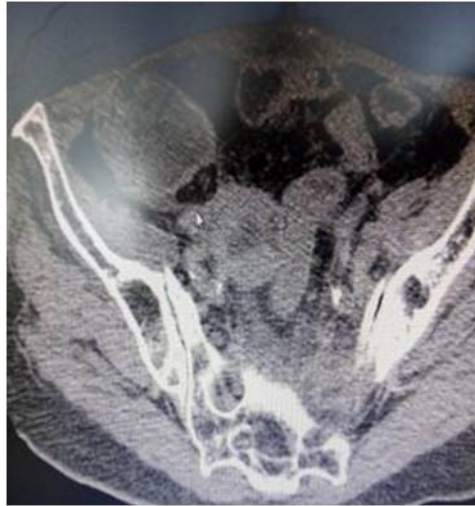

Figure 7. Colovesical fistula with gangrene of the left upper vesical wall

chronic signs and symptoms. Acute symptoms included: abdominal pain, fever, tachycardia, tachypnea, anuria, signs of ileus, laboratory signs of sepsis (high level of urea, creatinin, potassium, hepatal enzymes, hypoalbuminemia, hypoglobulinemia, leucocytemia, and high level of CRP and D-dimers). RTG of abdomen showed signs of ileus, ultrasound examination showed free liquid in the abdominal cavity and CT revealed perforation of the urine bladder. Chronic symptoms manifested in the patient with vesico-vagino-rectal fistula included: continuous subfebril condition, constant suprapubic pain, constant leakage of infected urine through the vagina and rectum and secondary anemia. Retrograde vesiculography and CT urography showed presence of vesico-vagino-rectal fistula and bilateral hydronephrosis II and III stage.

CONCLUSION

Urine bladder gangrene is rare but extremely urgent life threatening condition which requires radical surgical treatment during the first 24 hours from its appearance. Acute occlusion of one of the hypogastric arteries with thromb embolus as a complication of pelvic phlebothrombosis, according to our experience is the most common cause for its appearance. Hence urgent CT of the pelvis and abdomen and pelvic CT angiography are crucial diagnostic methods for differentiation from other causes for clinical manifestation of acute abdomen. Long presence of vesico-rectal or vesico-vagino-rectal fistula could also result with partial necrosis of the urine bladder wall, but unlike the acute occlusion of the hypogastric artery it has chronic symptoms and signs. CT

urography and retrograde urethrocytography are necessary for confirmation of the persistence of the fistulas and perforation of the urine bladder. The urgent patients with clinical symptoms and signs of acute abdomen, should be treated in two stages. The first stage should consist of radical cystectomy with bilateral ureterocutaneostomy as temporary urinary derivation. The second stage should be performed at least 2-3 months after the first surgery, where urinary diversion with ileal conduit should be performed due to the frequent occurrence of stenosis of the ureterocutaneostomas, as permanent treatment.

REFERENCES

- Carson WJ (1925). Gangrene of the Bladder. *J Urol*; 205
- Charra B, Hachimi A, Sodki M, et al. (2008). Urinary peritonitis caused by gangrenous cystitis. *Signa Vitae* ;3:32–33
- Cristol DS, Green LF (1945). Gangrenous cystitis. *Surgery*. 18: 343
- Engel WJ, McCormack LJ (1956). Acite necrotizing angiitis of the bladder. *J Urol*; 79:230
- Martinez MT (1991). Colovesical fistula secondary to vesical gangrene in a diabetic patient. *J Urol* ;146:1115–17
- Prabhat J, Dhoj JB, Kumar JB (2019). Case report of gangrenous cystitis in a post-partum female. *Arch Urol Research*
- Raza A, Balsitis M, Hosie KB (1999). Gangrenous cystitis: a rare cause of colovesical fistula. *Postgrad Med J*; 75:34.
- Sieber PR (1994). Bladder necrosis secondary to pelvic artery embolization: case report and literature review. *J Urol* ;151:422
- Splann Jr, FF, Walker WH (1969). Gangrene of the bladder. *J Urol*: 102:429
- Stirling WC, Hopkins GA (1933). Gangrene of the bladder. *J Urol*: 31:517
- Stirling WC, Hopkins GA (1934). Gangrene of the bladder. Review of two hundred and seven cases: report of two personal cases. *J Urol* ;31:517