



Journal Homepage: - www.journalijar.com

INTERNATIONAL JOURNAL OF ADVANCED RESEARCH (IJAR)

Article DOI: 10.21474/IJAR01/10614

DOI URL: <http://dx.doi.org/10.21474/IJAR01/10614>



RESEARCH ARTICLE

MANAGEMENT OF SUB CONDYLAR FRACTURES BY RETRO-MANDIBULAR APPROACH AND ASSESSMENT OF POST-OPERATIVE COMPLICATIONS: A PROSPECTIVE STUDY

Dr. Muhammad Mumtaz¹, Dr. Farhat Kazmi², Dr. Nasir Muneer Otaibi³ and Dr. Noaf Fawaz Alfawaz⁴

1. Specialist Oral and Maxillofacial Surgeon, Department of Dentistry, King Salman bin Abdul Aziz Hospital, Ministry of Health, Kingdom of Saudi Arabia.
2. Associate Professor of Oral Pathology, Princess Nourah Bint Abdur Rehman University, Riyadh, Saudi Arabia.
3. Specialist oral and Maxillofacial Surgeon, Department of Dentistry, Salman bin Abdul Aziz Hospital, Ministry of Health, Kingdom of Saudi Arabia.
4. King Saud University, Riyadh Kingdom of Saudi Arabia.

Manuscript Info

Manuscript History

Received: 05 January 2020

Final Accepted: 07 February 2020

Published: March 2020

Key words:-

RSA (Road Side Accident), SCF (Sub-Condyle Fracture), OC (Occlusion), RMI (Retro Mandibular Incision), INO (Inter Incisal Opening.)

Abstract

Maxillofacial injuries are common during trauma and sub-condylar fractures are considered one of the most challenging fractures to manage due to esthetic and functional concern.

Purpose: Assessment of facial nerve damage and stability of occlusion by retro-mandibular approach. This was a Prospective cross-sectional study at a secondary care hospital, Ministry of Health, Riyadh, Saudi Arabia during from August 2017 to July 2019.

Patients and Methods: Fourteen patients with sub condylar fracture were operated with open reduction and internal fixation through retro mandibular approach. Inclusion criteria were patients above fifteen years old with disturbed occlusion and displaced fractured sub-condyle.

Results: Efficacy was assessed based on occlusion stability and status of the facial nerve postoperatively All Patients with sub condylar fractures (n=14) were operated with retro-mandibular approach. Fourteen patients aged sixteen years and above including 12(85.7%) males and 2(14.3%) females, with left side 7 (42.9%), right side 7 (42.9%) and bilateral 2 (14.3%) involvement. The significant etiological factor was road traffic accident 8 (57.1%) followed by history of fall 2(14.3%). Immediate postoperative findings showed facial nerve weakness in 2(14.3%) patients [buccal branch 1(7.1%); marginal mandibular branch 1(7.1%)] and both fully recovered after three months. Postoperative occlusion was normal in 12 (85.7%) patients while it was temporarily disturbed in 2(14.3%) patients and it significantly improved by the final follow-up visit.

Conclusion: On the basis of our clinical findings, we recommend the retro mandibular approach as it provides good visibility with less facial nerve damage risk.

Copy Right, IJAR, 2020,. All rights reserved.

Introduction:-

Trauma of the oral and maxillofacial region can result in considerable facial deformity and it simultaneously affects function and aesthetics of the face. Various facial bones may be affected including NOE complex, zygomatico-

Corresponding Author:- Dr. Muhammad Mumtaz

Address:- Specialist Oral and Maxillofacial Surgeon, Department of dentistry, King Salman bin Abdul Aziz Hospital, Ministry of Health, Kingdom of Saudi Arabia.

maxillary complex, sub condyle, angle and body of the mandible. Sub condylar fractures are specifically difficult to treat surgically due to the close proximity of the facial nerve.² The ideal management of sub-condylar fracture has been a debatable subject for the longest time, and it varies from surgeon to surgeon and among multiple maxillofacial centres. Discussions regarding sub-condylar fractures begin from the type of reduction to the incision required for ORIF.³ Abundant articles are already available in the literature about the approach of sub condylar fractures including preauricular, retromandibular, submandibular, and post auricular. Each surgical approach carries its own advantages and disadvantages which mainly includes risk of facial nerve damage and extra-oral scar.^{3,4} Regardless of the proposed approach, the consensus is that the objective of sub condylar fracture management is restoration of function and aesthetics. The function refers to reestablishment of normal occlusion whereas aesthetic stands for preventing facial asymmetry.⁵ The retromandibular approach (RM) provides sufficient exposure to fix sub condylar fractures.⁶ Modified retro mandibular incision is a more rational trans-masseteric approach to fix these fractures. The risk of facial nerve damage cannot be overlooked, but as per literature the retro mandibular trans parotid approach carries less chance of injuring any branch of the facial nerve.⁷ Moreover, utilizing the RM approach yielded significant improvement of both function and aesthetic with minimal complications such as infections, plate fracture and keloid formation.⁸

The pre-auricular approach has been recommended in cases where there is anteromedial displacement of the dislocated or displaced condyle, however, facial nerve weakness along with clicking sound of the ipsilateral joint are more frequent with such method.⁹ Once the fracture site is accessible with any approach, application of titanium plates has made fixation more convenient for patients due to the early restoration of the function as a result of load sharing plates.¹⁰ Biochemical testing revealed that Y plates are more suitable in sub condylar fractures. Many potential complications associated with ORIF of sub condyle fracture have been reported in the literature including extra oral scar, facial nerve damage, plate fracture, deviation of the jaw, dislocation of the condylar head and aseptic necrosis of the condylar segments.¹¹

The aim of this prospective study was to evaluate the retromandibular approach in management of sub condylar fracture and its postoperative effect on the terminal branches of the facial nerve and stability of occlusion.

Methodology:-

The design of this investigation was a prospective cross-sectional study conducted in a Ministry of Health affiliated hospital in the city of Riyadh, Saudi Arabia during the period from August 2017 to July 2019.. Approval of the Hospital's Ethical Review committee was obtained. The sample included all patients above fifteen years old with radiographic evidence of sub condylar fracture along with clinical findings of disturbed occlusion. Excluded were patients less than fifteen years old as these patients were preferably managed with closed reduction or conservatively. Maxillofacial computed tomography (CT) was requested for all patients preoperatively and post-operatively to examine the anatomical reduction. Peri-operatively, the occlusion was maintained through the use of arch bars and elastics. Elastics were removed immediately after fixation of the fracture while upper and lower arch bars were removed after one month. RM approach was modified according to the site of the fracture and in case of bilateral fracture both sides were exposed to fix the fractures. Patients were discharged within three to five days postoperatively, and were periodically followed up after one week, two weeks, one month and three months for the assessment of post-operative complications including the stability of occlusion and any disturbance of the facial nerve.

Results:-

Data Collection:

The sample included fourteen patients that met our inclusion criteria. Following clinical and radiographic examination, all patients required ORIF through retro-mandibular approach (Fig1). The patients had a mean age of 20.7 (age range from 16-41 years), participants from 16 to 20 years had the highest incidence of sub condylar fractures compared to other age groups (Fig2). Moreover, younger males constituted a higher proportion as compared to females. Among the fourteen patients, 7 (42.9%) involved the left side, 7 (42.9%) involved the right side, and 2 (14.3%) were bilateral. Road side accidents were the major cause of trauma with 8 patients (57%), followed by 2 patients (14%) with history of falls (Fig3). The data was entered and analyzed using Statistical Package of Social Science (SPSS version 23) and outcome variables were described using descriptive statistics (Fig 4, Fig 5).

Occlusion:

Normal occlusion was achieved in all patients after completing their follow up period, although 2 patients (14.3%) were unable to occlude their teeth passively due to tenderness at the fractures site which was resolved by their second post-operative follow up visit. These two patients had undergone immobilization by elastics for two weeks to prevent any occlusal discrepancy later on. Restricted mouth opening was experienced by 9 patients (64.2%) during their first follow up visit which was fully resolved after completing their follow up period (Fig4).

Facial Nerve injury:

The incidence of permanent facial nerve injury, as stratified by postoperative findings was nil (0%) in all of the cases (Fig3). However, two patients showed transient facial nerve weakness for two weeks postoperatively, one involving the marginal mandibular branch while the other affecting the buccal branch, both were recovered completely by their final follow up visit (Fig5). These patients were evaluated through subjective assessments using the visual analogue scale.

Mean follow up period was 3.72 (3.25) months. No post-operative infection noted ($\geq 99\%$ success rate), satisfactory occlusion along with normal anatomical reduction of the fracture site were achieved in 12 patients ($\geq 85.7\%$) from the first follow up visit. Moreover, temporary facial nerve weakness was observed in ($\geq 14.3\%$) of patients, involving the marginal mandibular and buccal branches ($\geq 7.1\%$) each, both completely recovered by the final postoperative visit. For all patients, functional outcome improved up to 100% regardless of fracture type ($p < 0.001$).

Discussion:-

Many published studies discuss the management and postoperative complications of sub condylar fractures.¹² Conservative approach has long been considered the treatment of choice for sub condylar fracture, however with evolving technology ORIF has been adopted by many surgeons. Operating sub condylar fractures can be performed by various methods, most commonly the retromandibular and preauricular approaches.¹³ According to a study by Yang and Patil, 48 patients were treated to evaluate postoperative complications including the status of facial nerve and stability of occlusion. Even though they achieved satisfactory results by the final postoperative visit, a significant number of patients initially experienced weakness of the facial nerve whereas stability of occlusion was maintained in all patients for the whole follow up period.¹⁴ This study is in line with our findings as we also reported weakness of the facial nerve in two patients where one was operated through trans-parotid approach and the other through trans-masseter.

Preauricular approach is also frequently used for condylar and sub condylar fractures. Zhou and Ren conducted a study utilizing this approach and concluded that there were no long-term complications and all the patients were satisfied with their postoperative appearance. Their study included 38 high neck, 26 low bases, and 35 diacapitular condylar fractures with no permanent facial nerve injury reported in any of the cases. Our study attained similar results with a different approach. In another study by Nogmain et al., fifteen patients were treated with RM approach, they reported facial nerve paraesthesia in very few patients which resolved completely after short period of time.¹⁵ This is in accordance with our study as we also have not reported any persistent complication by the final postoperative visit. Moreover, a study conducted by Spinzia et al., utilized both retromandibular and preauricular approaches to fix the fractures. They inspected functionality of the facial nerve, occlusion, TMJ and skin scarring. Regardless of the type of approach used, they concluded that 88% of patients did not experience any the facial nerve dysfunction, along with 80% success rate of satisfactory occlusion. This is similar to our outcome as we concluded significant success rate of both the facial nerve function and stability of occlusion.

In light of the latest research and advances in technology, many surgeons advocate open reduction to fix sub condylar fractures. Multiple classifications have been established earlier on the type of sub condylar fractures and their management whether open or closed reduction. There are few absolute indications to go for open reduction and internal fixation.¹⁶ once it has been determined to utilize open reduction, a new discussion always commences in many maxillofacial centers regarding which approach to be employed. In our study, all cases were operated through the modified retro mandibular approach as shown in (fig8) which is in line with the recommendations of klatt study.¹⁷ Satisfactory results have been accomplished through such approach and not a single patient experienced permanent effect on occlusion or the facial nerve as depicted in (fig4) and (fig5) respectively.

Conclusion and Recommendations:-

We believe that the retro mandibular incision is one of the most effective approaches for the fixation of sub condylar fractures. In comparison to the preauricular incision, the retro mandibular incision offers the following merits: it avoids the risk of damaging the upper trunk of facial nerve, the incision is barely visible on the face, it grants a wide exposure of the operating field to control bleeding and better visualize the fracture site for fixation. Since ORIF does not necessitate immobilization anymore, patients can conveniently return to their daily life practice earlier. We also suggest that further studies regarding treatment methodologies must be conducted with a larger sample size.

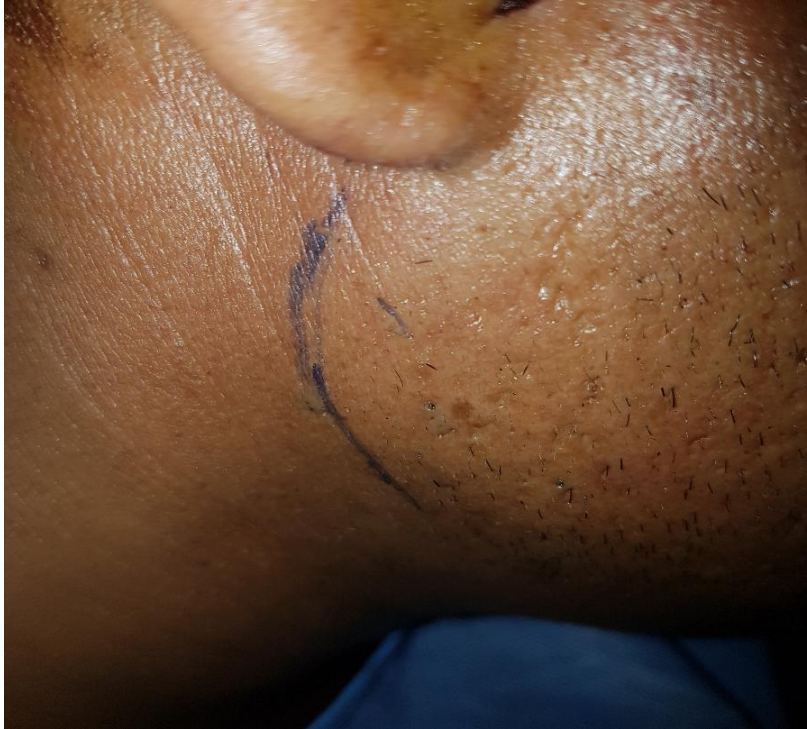

Fig1:- Retromandibular incision marking.

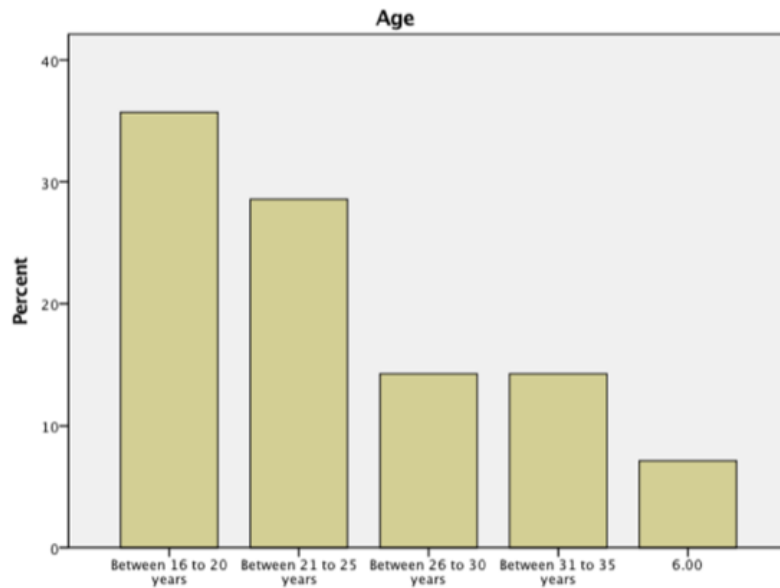


Figure 2: This figure shows percentages of different age groups presented with subcondyle fractures

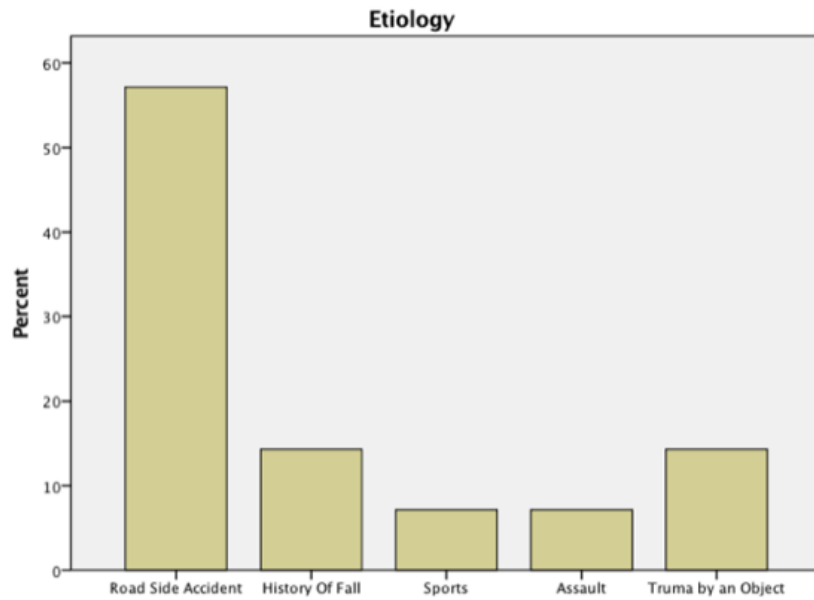


Figure3: This figure shows different etiological factors resulting in subcondyle fractures

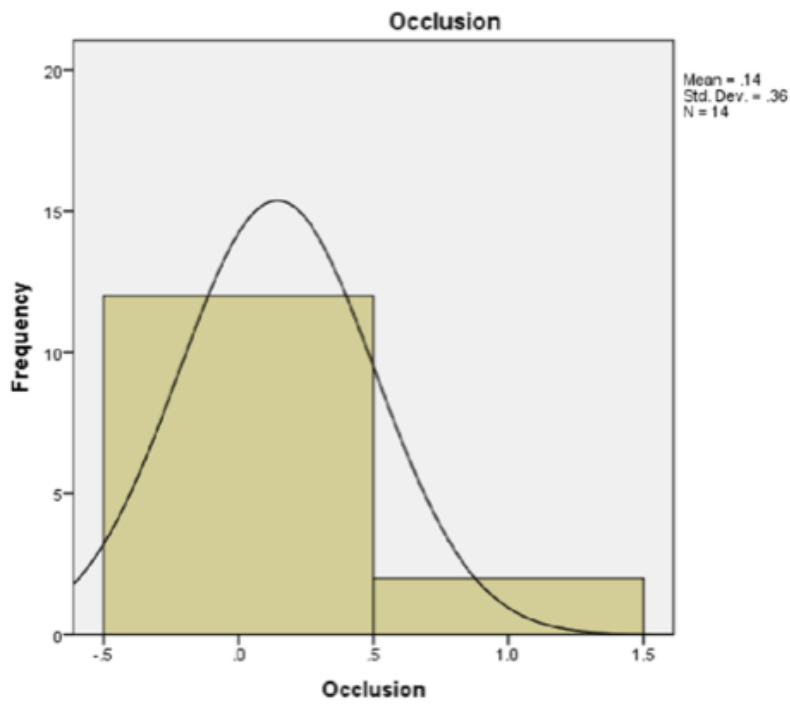


Figure 4: This figure shows status of occlusion post operatively

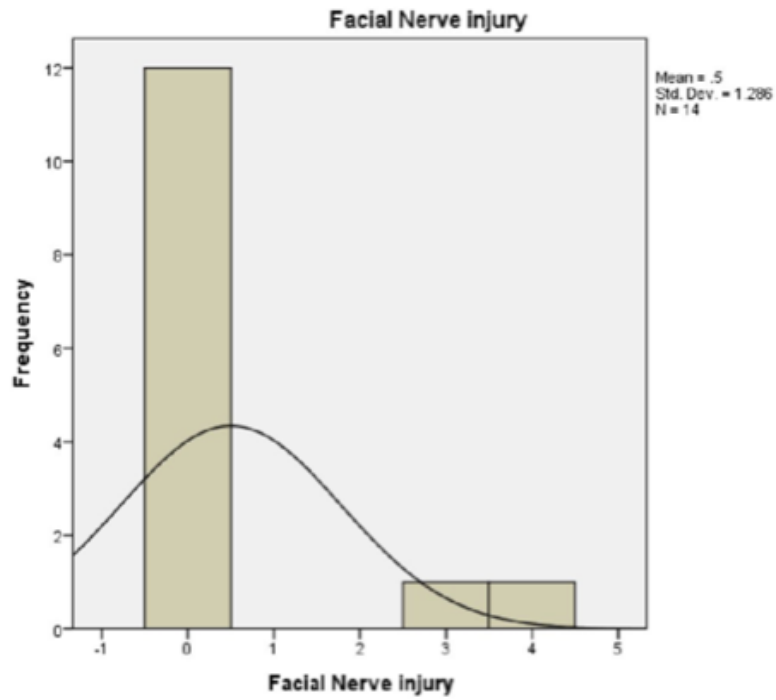

Figure 5: This figure shows status of facial nerve injury post operatively

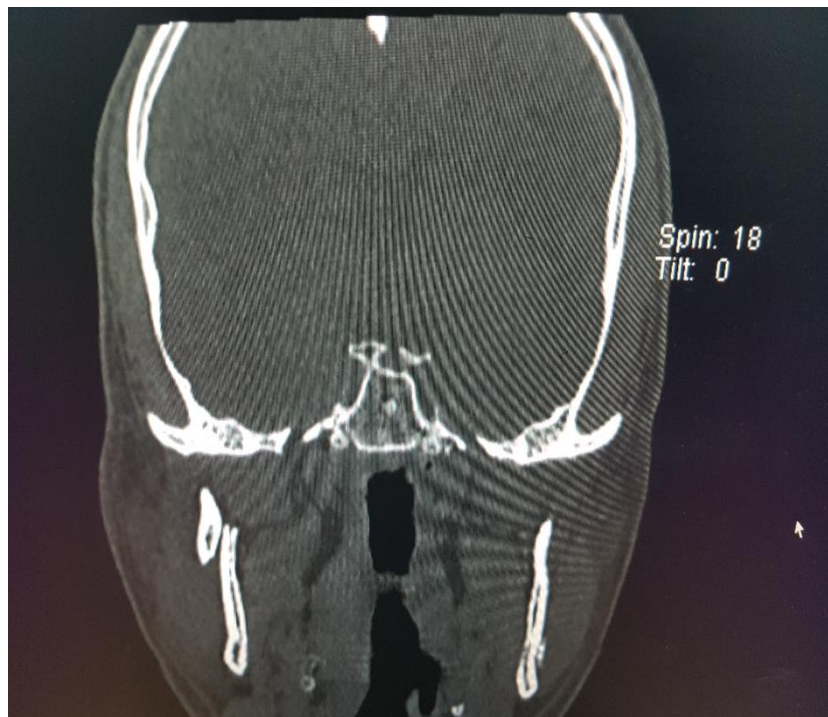


Fig 6:- Coronal view of CT scan showing right mandibular sub-condylar fracture.

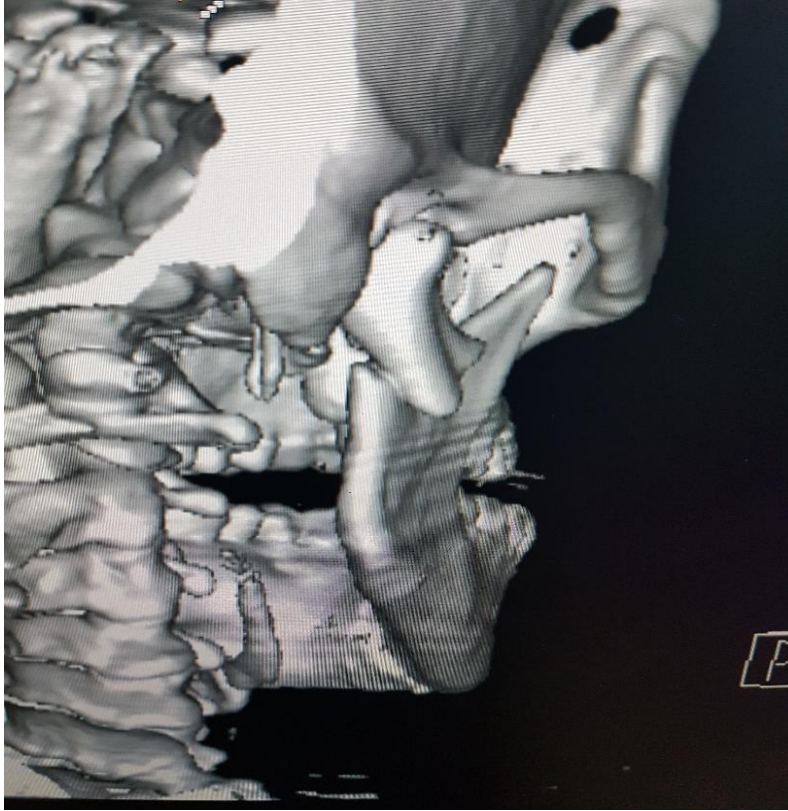

Fig 7:- 3D CT scan showing right mandibular sub-condylar fracture.

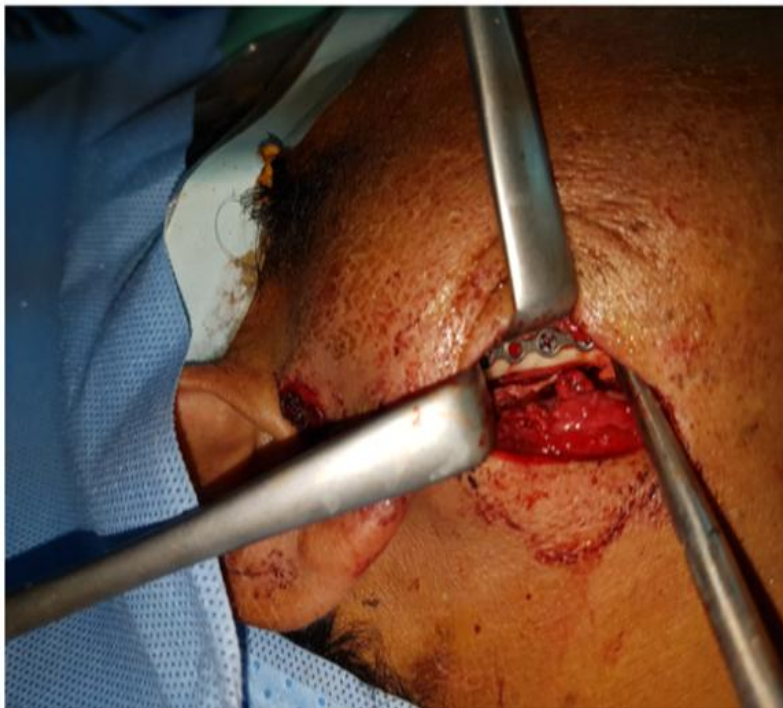

Fig 8:- ORIF of the right sub-condylar fracture.

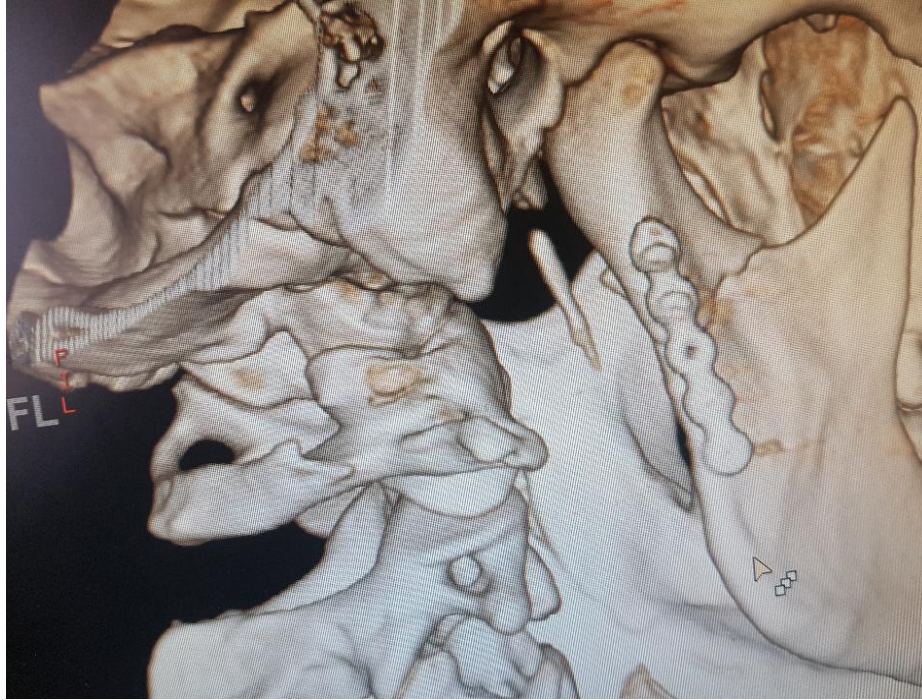


Fig 9:- 3D Ct showing ORIF for right sub-condyle fracture.

References:-

1. Mumtaz M, Warraich RA, Bhatti MUD, Ali S. Comparative Study of Evaluation of Results of Orbital Floor Reconstruction with Calvarial Bone Graft Vs Sialastic Implant. *Annals of King Edward Medical University*. 2010;16(4):270-5.
2. Khan I, Singh S, Faisal M, Ahmad SA, Cybil D. The retromandibular approach for treating sub-condylar fractures of mandible. *International Journal of Oral and Maxillofacial Surgery*. 2013;42(10):1205-6.
3. Rashid A, Mumtaz M, Asif J, Azeem M. Mandibular condyle fracture- effect of treatment on occlusal relationship. *Pakistan Oral & Dental Journal*. 2014;34(1):30-3.
4. Kang DH. Surgical management of a mandible subcondylar fracture. . *Archives of Plastic Surgery*. 2012;39(4):284-90.
5. Shiju M, Rastogi S, Gupta P, Kukreja S, Thomas R, Bhugra AK, et al. Fractures of the mandibular condyle - Open versus closed - A treatment dilemma. . *Journal of Cranio-Maxillo-Facial Surgery*. 2015;43(4):448-51.
6. Biglioli F, Colletti G. Transmasseter Approach to Condylar Fractures by Mini-Retromandibular Access. *Journal of Oral and Maxillofacial Surgery*. 2009;67(11):2418-24.
7. Salgarelli AC, Anesi A, Bellini P, Pollastri G, Tanza D, Barberini S, et al. How to improve retromandibular transmasseteric anteroparotid approach for mandibular condylar fractures: Our clinical experience. *International Journal of Oral and Maxillofacial Surgery*. 2013;42(4):464-9.
8. Bhutia O, Kumar L, Jose A, Roychoudhury A, Trikha A. Evaluation of facial nerve following open reduction and internal fixation of subcondylar fracture through retromandibular transparotid approach. *British Journal of Oral and Maxillofacial Surgery*. 2014;52(3):236-40.
9. Mohan AP, Kumar KAJ, Venkatesh V, Kumar BP, Patil K. Comparison of preauricular approach versus retromandibular approach in management of condylar fractures. *Journal of Maxillofacial and Oral Surgery*. 2012;11(4):435-41.
10. Filho TSC, Rodrigues DC, Lauria A, Moreira RWF, Consani S. Development plates for stable internal fixation: Study of mechanical resistance in simulated fractures of the mandibular condyle. *Journal of Cranio-Maxillo-Facial Surgery: Official Publication of the European Association for Cranio-Maxillo-Facial Surgery*. 2015;43(1):158-61.
11. Valiati R, Ibrahim D, Abreu MER, Heitz C, Oliveira RBd, Pagnoncelli RM, et al. The treatment of condylar fractures: To open or not to open? A critical review of this controversy. *International Journal of Medical Sciences*. 2008;5(6):313-8.
12. Assael LA. A devotion to trauma. *Journal of Oral and Maxillofacial surgery*. 2003;61(4):415-6.

13. Zhou J-H, Ren C-Q. A preauricular long-corniform approach for open reduction and internal fixation of mandibular condylar fractures. *Journal of Cranio-Maxillo-Facial Surgery*. 2013;41(5):359-66.
14. Yang L, Patil PM. The retromandibular transparotid approach to mandibular subcondylar fractures. *International Journal of Oral and Maxillofacial Surgery*. 2012;41(4):494-9.
15. N, Tetsu T, Kensuke Y, Ikuya M, Takeshi K, Noriaki Y, et al. Clinical comparison between the retromandibular approach for reduction and fixation and endoscope-assisted open reduction and internal fixation for mandibular condyle fractures. *The Journal of Craniofacial Surgery*. 2012;23(6):1815-8.
16. Spinzia A, Patrone R, Belli E, Orabona GDA, Ungari C, Filiaci F, et al. Open reduction and internal fixation of extracapsular mandibular condyle fractures: a long-term clinical and radiological follow-up of 25 patients. *BMC Surgery*. 2014;14(1):68-78.
17. Klatt J, Pohlenz P, Blessmann M, Blake F, Eichhorn W, Schmelzle R, et al. Clinical follow up examination of surgically treated fracture of the condylar process using transparotid approach. *Journal of Oral Maxillofac Surgery*. 2010;68(3):611-17.