



ELSEVIER

Available online at www.sciencedirect.com

ScienceDirect

The Surgeon, Journal of the Royal Colleges
of Surgeons of Edinburgh and Irelandwww.thesurgeon.net

Tissue engineered extracellular matrices (ECMs) in urology: Evolution and future directions

N.F. Davis ^{a,*}, E.M. Cunnane ^{b,c}, F.J. O'Brien ^c, J.J. Mulvihill ^b, M.T. Walsh ^b

^a Department of Urology and Transplant Surgery, Beaumont Hospital, Dublin, Ireland

^b School of Engineering, Bernal Institute, Health Research Institute, University of Limerick, Limerick, Ireland

^c Tissue Engineering Research Group, Department of Anatomy, Royal College of Surgeons in Ireland, Dublin 2, Ireland

ARTICLE INFO

Article history:

Received 25 May 2017

Accepted 18 July 2017

Available online 12 August 2017

Keywords:

Tissue engineering

Regenerative medicine

Reconstructive urology

Extracellular matrix

Stem cells

Biomedical engineering

ABSTRACT

Autologous gastrointestinal tissue has remained the gold-standard reconstructive biomaterial in urology for >100 years. Mucus-secreting epithelium is associated with lifelong metabolic and neuromechanical complications when implanted into the urinary tract. Therefore, the availability of biocompatible tissue-engineered biomaterials such as extracellular matrix (ECM) scaffolds may provide an attractive alternative for urologists. ECMs are decellularised, biodegradable membranes that have shown promise for repairing defective urinary tract segments *in vitro* and *in vivo* by inducing a host-derived tissue remodelling response after implantation. In urology, porcine small intestinal submucosa (SIS) and porcine urinary bladder matrix (UBM) are commonly selected as ECMs for tissue regeneration. Both ECMs support ingrowth of native tissue and differentiation of multi-layered urothelial and smooth muscle cells layers while providing mechanical support *in vivo*. In their native acellular state, ECM scaffolds can repair small urinary tract defects. Larger urinary tract segments can be repaired when ECMs are manipulated by seeding them with various cell types prior to *in vivo* implantation. In the present review, we evaluate and summarise the clinical potential of tissue engineered ECMs in reconstructive urology with emphasis on their long-term outcomes in urological clinical trials.

© 2017 Royal College of Surgeons of Edinburgh (Scottish charity number SC005317) and Royal College of Surgeons in Ireland. Published by Elsevier Ltd. All rights reserved.

Introduction

More than 400 million people worldwide suffer from congenital and acquired anomalies of the urinary tract that may

necessitate surgical intervention. Surgical repair for end stage upper and lower urinary tract defects often necessitates autologous, vascularised, mucus-secreting gastrointestinal tissue to either replace the diseased organ or to augment inadequate tissue.¹ Postoperatively, the compliance of the

Abbreviations: ECM, extracellular matrix; SIS, small intestinal submucosa; UBM, urinary bladder matrix; PTFE, polytetrafluoroethylene; 3D, three-dimensional; ESRD, end-stage renal disease; ADSCs, adipose derived stem cells; SMC, smooth muscle cell; VECM, vascular extracellular matrix; PGA, polyglycolic acid; PGA/PLA, polyglycolide/polylactide; BAMG, bladder acellular matrix graft; ADM, acellular dermal matrix.

* Corresponding author. Department of Urology and Transplant Surgery, Beaumont Hospital, Dublin 9, Co Dublin, Ireland. Fax: +353 1 809 3962.

E-mail address: nialldavis@rcsi.ie (N.F. Davis).

<http://dx.doi.org/10.1016/j.surge.2017.07.002>

1479-666X/© 2017 Royal College of Surgeons of Edinburgh (Scottish charity number SC005317) and Royal College of Surgeons in Ireland. Published by Elsevier Ltd. All rights reserved.

bowel is often sufficient to restore the basic shape, structure and function of the urinary tract, however lifelong post-operative complications are common.^{1,2} Long-term comorbidities that result from interposition of gastrointestinal tissue in the urinary tract are classified as metabolic or neuromechanical and their incidence approaches 100% due to the mucus-secreting nature of the bowel epithelium.³

Tissue engineering in urology focuses on developing alternative strategies for reconstructing injured, diseased and congenitally absent cells, tissues and organs within the urinary tract.⁴ Throughout the twentieth century synthetic scaffold biomaterials were investigated in reconstructive urology as alternatives to gastrointestinal tissue. In the 1950s non-biodegradable synthetic materials like polytetrafluoroethylene (PTFE), silicone, rubber, polyvinyl, and polypropylene were applied but were found to rapidly encrust with prolonged urinary contact.⁵ Additionally, these materials were susceptible to bacterial colonisation and foreign body reactions.⁶ The debilitating comorbidities associated with autologous gastrointestinal tissue and synthetic biomaterials may be mitigated by the availability of tissue-engineered readily available, porcine derived extracellular matrix (ECM) scaffolds.

Tissue engineered extracellular matrices (ECMs)

ECMs are decellularised, biocompatible, biodegradable biomaterials usually derived from porcine organs.^{7,8} They are prepared by mechanical, chemical and enzymatic treatments to yield tissue that is minimally immunogenic but retains its basic structural elements.⁹ Collagen, glycosaminoglycans, fibronectin, laminins and other intrinsic growth factors are retained after the preparation process to allow for host derived cellular attachment, growth and differentiation.⁴ Appropriately prepared urological ECMs aim to provide a biologically active tissue/organ substitute that can effectively integrate into host tissue, maintain urinary tract compliance and functionally replace a defective urinary tract segment after a pre-established duration.¹⁰ An integrated tissue-engineered ECM should restore or preserve the normal function of the urinary tract structure it is augmenting or replacing.³ Furthermore, it should be biocompatible to minimise rejection and inflammatory reactions.

Urological ECMs

In urology, porcine small intestinal submucosa (SIS) and porcine urinary bladder matrix (UBM) are selected as the more favourable ECMs for tissue reconstruction.^{8,11} Their harvesting sites differ; however both can be utilised as interposition grafts within the urinary tract as they support ingrowth of native tissue, proliferation and differentiation of multi-layered urothelial and smooth cells layers while maintaining a robust connective tissue layer to provide mechanical support to the urinary tract.¹² SIS is harvested from porcine small bowel and contains significant amounts of collagen type I with lesser amounts of collagen types III, IV, V and VI.⁴ UBM is harvested from the porcine urinary bladder and contains an intact basement membrane layer with large quantities of collagen type VII.¹³

Manipulating tissue-engineered ECMs

Currently, there are two techniques for manipulating biodegradable ECM scaffolds after their preparation process. These approaches are referred to as **unseeded** and **seeded** techniques. The unseeded method involves the use of a bare ECM scaffold *in vivo* to provide a framework for ingrowth and regeneration of native tissue. In general, unseeded ECMs are reserved for reconstructing smaller (i.e. ≤ 1 cm) urinary tract segments¹⁴ (Fig. 1). The seeded method requires the *in vitro* culture and expansion of various cell types on an ECM scaffold to create a composite tissue for grafting *in vivo* (Fig. 2).^{11,15,16} Seeded cells function in a paracrine manner once implanted and recruit endogenous cells to regenerate the native tissue across the scaffold (Fig. 3).^{17,18} Structural, functional and biological properties of cell-seeded ECM scaffolds should be accurately characterised *in vitro* to confirm that the ECMs mechanical and physiological properties are similar to the intended urinary tract segment that is being replaced.^{9,19–21}

Urinary tract applications of tissue-engineered ECMs

Repairing defective urinary tract structures with ECM scaffolds has been widely reported with many successes and failures described. Unseeded ECM scaffolds are effective for repairing small urinary tract defects through the release of stimulatory growth factors. Cell seeded or composite ECMs are more robust than unseeded ECMs and are therefore capable of repairing larger urinary tract segments and structures.^{22,23} At the turn of the millennium most studies on urological ECMs were described in animal models. Recently, phase 1 and phase 2 human clinical trials are becoming more prevalent with some encouraging short- and intermediate-term follow-up results.^{22,24} Recent progress in whole organ tissue-engineering strategies in urology is an exciting development that may be clinically translatable soon.²

Kidney

Renal transplantation is the definitive treatment option for patients with end-stage renal disease (ESRD).²⁵ However, only a minority of patients with ESRD receive kidney transplants due to a global shortage of deceased donor organs.²⁶ Researchers are currently developing three-dimensional (3D) cell culture techniques to construct tissue-engineered kidney ECMs *in vitro* as potential alternatives to renal allografts.^{2,27,28} Preliminary studies have demonstrated the feasibility of decellularising and recellularising renal ECMs in rat models.²⁹ However, development of an intricate and sophisticated vascular network has limited clinical progression.^{30,31} Vascular endothelial cell-seeding techniques have recently been pioneered to address this limitation by coating the decellularised vasculature of porcine kidney ECMs with an endothelial lining. Pre-seeding with a precursor to a vascular endothelium enhances vascular patency of the implanted scaffold *in vivo*.^{28,32} Challenges such as difficulties in expanding sufficient quantities of cell lines *in vitro* and thrombosis *in vivo* are 2 areas that need to be addressed to

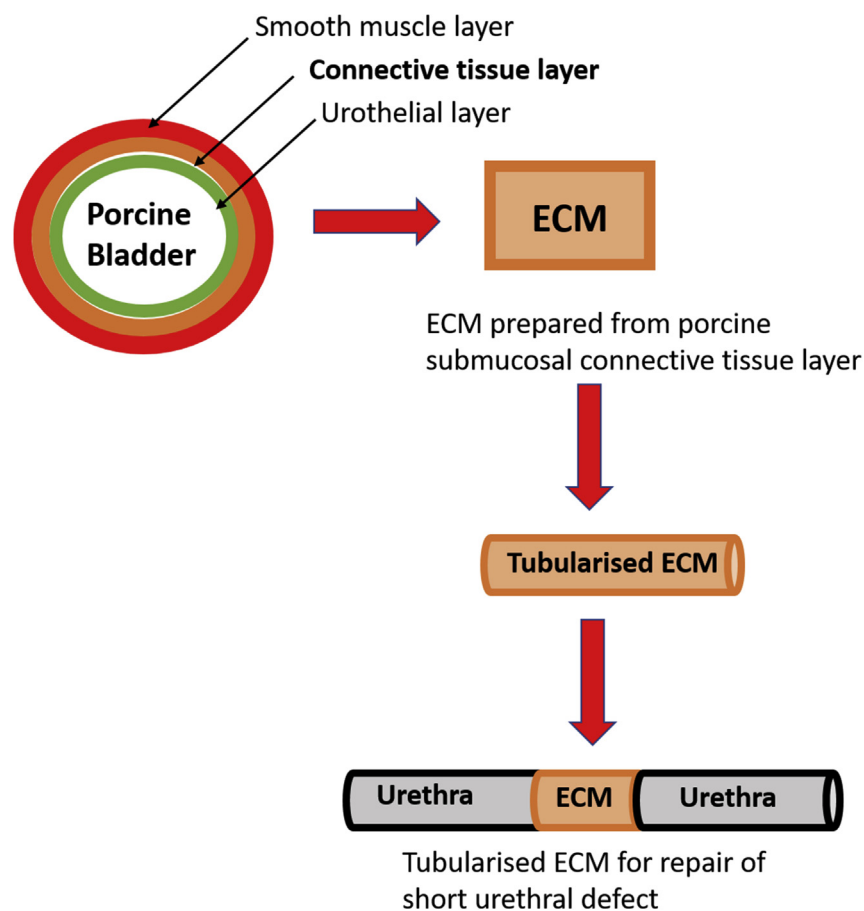


Fig. 1 – Preparation of unseeded tubularised ECM for repair of short urethral defect. During the preparation process decellularisation of porcine tissue is performed by physical, chemical and enzymatic treatments. After the ECM is decellularised it is sterilized by exposure to radiation and/or ethylene oxide and implanted *in vivo* to repair short urinary tract defects.

ensure the feasibility of these approaches in the near future.^{32–35}

Ureter

Reconstruction of long ureteral segments may necessitate autologous ileum to restore the mechanism for draining urine from the kidney to the urinary bladder.³⁶ Early studies on porcine ureters reported encouraging histopathological outcomes when SIS was utilised to replace a 7 cm ureteral segment after two thirds of the periphery of the upper third of the left ureter was excised.³⁷ Vascularised segments of collagen and smooth muscle were found in the 8 porcine models at autopsy after 7 weeks. There was no macroscopic or microscopic features of anastomotic strictures, ureteral stenosis or inflammation. The control group was the contralateral ureter where a Davis ureterotomy was performed. There was no evidence of epithelial regeneration at 7-weeks in the control group and all porcine models had radiological evidence of ureteral stenosis. Subsequently, porcine SIS was utilised to replace a 2 cm ureteral deficit (encompassing half the circumference) in 9 porcine models.³⁸ Again, there were no macroscopic or microscopic features of stenosis at autopsy after 9 weeks. Histopathology demonstrated regenerated

urothelial and smooth musculature at the site of the implanted SIS. Discouraging findings were described in other studies where complete circumferential ureteral defects were replaced. Shalhav et al. reported a 100% failure rate when acellular SIS replaced the ureter in 6 Yucatan mini pigs after 12-weeks.³⁹

More recently, Zhao et al. investigated the cell seeded approach by isolating adipose derived stem cells (ADSCs) from rabbits and stimulating the cell line to differentiate into a smooth muscle cell (SMC) phenotype.⁴⁰ SMCs were then seeded onto a vascular extracellular matrix (VECM) and implanted into rabbit models to replace a 3 cm full circumferential ureteral defect. Histopathology demonstrated an organised smooth muscle layer with a stratified differentiated urothelium and no evidence of ureteral stricture disease after 16 weeks' follow-up.⁴⁰ The success of this recent novel approach is attributable to an abundant cell source and improved implantation techniques.^{36,41}

Bladder

The urinary bladder can be compromised by neoplastic diseases and debilitating medical conditions such as bladder exstrophy, spinal cord injury, myelomeningocele, multiple

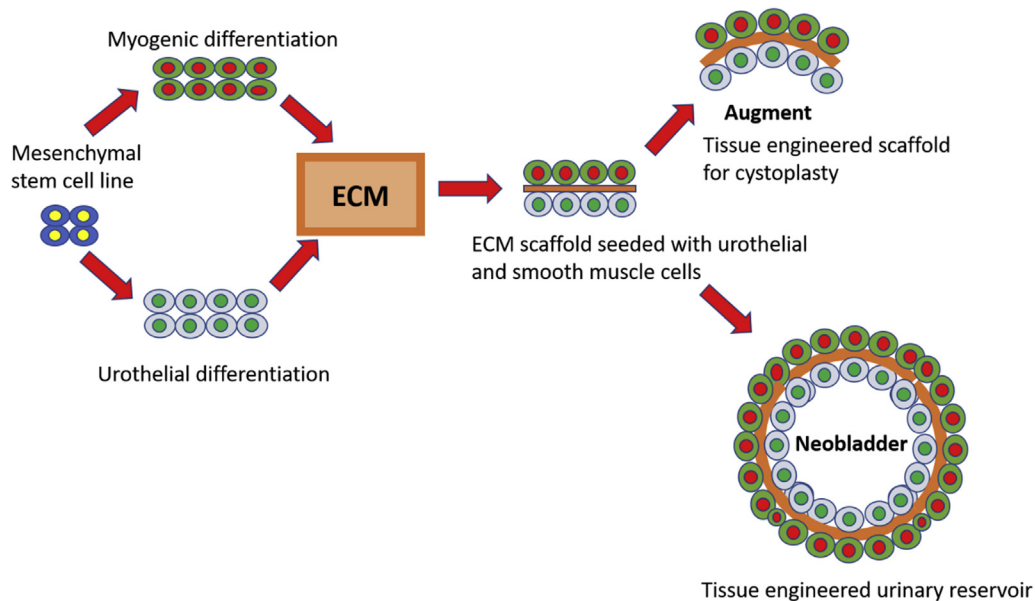


Fig. 2 – Construction of cell-seeded ECM. In the cell-seeded approach, donor cells are harvested and expanded *in vitro* in large quantities. Exposing a mesenchymal stem cell line to a physiological urinary tract environment allows stem cells to differentiate into urothelial and/or smooth muscle cell lines. Differentiated cells are then cultured onto a decellularised ECM and expanded again for a period of weeks. The differentiated cell-seed ECM can then be implanted *in vivo* to repair larger urinary tract defects.

sclerosis and interstitial cystitis. Bladder augmentation with a tissue engineering approach has been described in 22 patients to date in 3 different clinical trials.^{22,24,42} Cell-seeded ECM scaffolds cultured in conjunction with biodegradable synthetic materials did show early promise for augmenting or replacing the urinary bladder as exemplified in a phase 2 clinical trial study by Atala et al. in 2006.²² Native urothelial and smooth muscle cells were cultured onto ECM scaffolds or a composite scaffold composed of collagen and polyglycolic acid (PGA) in paediatric patients requiring augmentation cystoplasty for myelomeningocele ($n = 7$). The tissue-

engineered scaffolds were implanted with or without an omental wrap and no postoperative complications were noted after 46 months. Furthermore, postoperative cystograms and urodynamic studies demonstrated an increase in bladder capacity and compliance values that were 1.58-fold–2.79-fold improved compared to baseline values. Mean bladder leak point pressure at capacity decreased postoperatively by 56% (67–37.5 cm H₂O).²²

Notably, one other recent phase 2 clinical trial by Joseph et al. was unable to replicate these encouraging results when an autologous cell seeded polyglycolide/poly lactide (PGA/PLA)




Fig. 3 – Cell-seeded ECMs over time. Viability/cytotoxicity fluorescence assays with three-dimensional confocal microscopy illustrating viable and proliferating urothelial (UCs) and smooth muscle (SMCs) cell lines on urinary bladder matrix (UBM) after 6, 10, and 14 days of dynamic culture (A, B, and C, respectively).¹² The cell-seeded scaffolds are stained with calcein and ethidiumhomodimer-1 (Ethd-1; Molecular Probes, Eugene, OR, USA). Calcein is actively converted to calcein-AM in viable cells, which appear green under a fluorescence microscope. Ethd-1 accumulates in dead cells and on the ECM scaffold, which appears red.¹²

composite scaffold was utilised for augmentation cystoplasty in patients with spina bifida ($n = 10$).⁴² There was no improvement in bladder capacity on urodynamics after 1-year or 3-years and serious adverse events occurred in 4 patients with 5 patients requiring re-operation in the form of a conventional ileocystoplasty.⁴² Such findings demonstrate that further prospective studies are needed to demonstrate the clinical effectiveness of tissue-engineering for reconstructing the urinary bladder.

Most recently, urologists have developed a PGA urinary conduit scaffold as an alternative to a conventional ileal conduit for urine drainage after cystectomy. The 'neo-conduit' was seeded with autologous smooth muscle cells (SMCs), grown from adipose derived mesenchymal stem cells, for patients undergoing radical cystectomy for bladder cancer.^{43,44} Eight patients have been enrolled in this phase 2 clinical trial to date and early findings have demonstrated regeneration of urothelium, smooth muscle and neuronal tissue on histopathology.⁴⁴ Long-term functional results are currently awaited.

Urethra

The anterior urethra frequently requires reconstruction to treat ischaemic strictures caused by trauma or inflammation and congenital hypospadias.⁴⁵ Substitute urethroplasty, with a skin flap or graft, is most often required in instances of strictures/defects greater >2 cm, recurrent strictures or strictures of the penile urethra. Oral mucosa, derived from buccal or lingual tissue, is the gold standard grafting biomaterial in cases where there is insufficient penile skin to utilise as a flap.⁴⁶ Limitations with this graft harvesting technique are donor site morbidity, necessity for >1 harvesting site in cases of longer strictures/defects and the absence of sufficient donor tissue in the cases of repeat urethroplasty.⁴⁷

Presently, urethral reconstruction using tissue-engineered ECMs is at the forefront of regenerative medicine in urology.⁴⁸ Urethral reconstruction utilising tissue engineering techniques, have been used in hundreds of human patients to date (Table 2). A tissue engineered urethral graft alternative has the potential to eliminate donor site morbidity, decrease operative time and provide graft material in cases of repeat urethroplasty. Table 1 summarises 21 clinical studies that implant a range of tissue engineered scaffolds to treat urethral stricture and hypospadias. Decellularised urethral scaffolds are derived from porcine SIS, cadaveric bladder acellular matrix graft (BAMG), and human acellular dermal matrix (ADM). A naturally autologous collagen based matrix (Mucocell[®]) has also been utilised in addition to the synthetic polymer polyglycolic acid (PGA). Five studies have investigated the effect of seeding autologous cells onto tissue engineered urethral scaffolds. These cells are expanded from bladder urothelial cells (BUC), bladder smooth muscle cells (BSMC), oral keratinocytes (OK) and oral fibroblasts (OF).

Table 2 also demonstrates that tissue engineered urethral scaffolds demonstrate favourable clinical outcomes under certain conditions. Specifically, the success of the graft is dependent on the length of the stricture and condition of the urethral bed whereby shorter strictures and healthier urethral beds are more conducive to clinical success. Furthermore, outcomes with bulbar grafts are superior to penile

Table 1 – Summary and clinical outcomes of studies that describe tissue-engineering methods for reconstructing the urinary bladder in human patients.

Author	Year	Patient no	Age (in years)	Underlying pathology	Scaffold source	Operative procedure	Mean length of follow-up	Clinical outcome
Atala et al. ²²	2006	7	4–19	Myelomeningocele	UCs + SMCs + PGA + collagen + omentum	Augmentation cystoplasty	46 months	Improved compliance up to 56% No complications
Caione et al. ²⁴	2012	5	10	Previous bladder exstrophy repair	SIS	Augmentation cystoplasty	18 months	30% increase in bladder capacity and compliance
Joseph et al. ⁴²	2014	10	3–21	Spina bifida	Adipose stem cells + PGA + PLGA	Augmentation cystoplasty	36 months	No significant improvement in overall compliance. 4/10 experienced a major complication

UCs: urothelial cells; SMCs: smooth muscle cells; PGA: polyglycolic acid; SIS: small intestinal submucosa PLGA: poly-DL-lactide-co-glycolide.

Table 2 – Summary and clinical outcomes of studies that describe tissue-engineering methods for treating urethral stricture disease in human patients.

Author	Year	Patient no	Age (in years)	Defect (Patient no)	Location (Patient no)	Stricture length (cm)	Scaffold source	Cell type	Technique	Follow up (months)	Complications	Successful outcome
Atala et al. ⁴⁹	1999	4	4–20	Hypospadias	Penoscrotal (3) and scrotal (1) meatus	5–15	cBAMG	None	Onlay patch	22	Fistula in 15 cm defect at 6 weeks (1)	3/4 75%
Mantovani et al. ²⁰	2003	1	72	Urethral stricture secondary to 8 cystoscopies	Penobulbar	Not provided	pSIS	None	Dorsal onlay patch	16	None	1/1100%
El-Kassaby et al. ⁵⁰	2003	28	22–61 (40.4)	Anterior urethral stricture	Penile (3) bulbar (11) and penobulbar (14)	1.5–16	cBAMG	None	Ventral onlay patch	37 (36–48)	Penile (1) and penobulbar (3) re-strictures. Subcoronal fistula (1) (spontaneously resolved)	24/28 86%
Sievert et al. ⁵¹	2005	13	10 men (32–56) 3 boys (5.8–16)	Urethral stricture in men and hypospadias in boys	Not provided	Men: 4–10 Boys: 3	pSIS	None	Onlay patch	12	4 re-strictures in men. 1 of these 4 also developed a fistula	9/13 69%
Le Roux ⁵²	2005	9	15–56 (40.22)	Urethral stricture secondary to inflammation and iatrogenic injury	Bulbar (7) and membranous (2)	1–4 (2.22)	pSIS	None	Endoscopic tubular urethroplasty	24	Re-stricture (6) within 3 months. 1 lost to follow-up	2/8 25%
Lin et al. ⁵³	2005	16	18–46, (26.5)	Complex urethral stricture following pelvic fracture (13), anterior urethral stricture (2) and hypospadias (1)	Not available	Not available	hADM	None	Tubular	45.6 (12–72)	Periodical urethral dilation required (4)	14/16 88%
Donkov et al. ⁵⁴	2006	9	26–45 (35.5)	Urethral stricture secondary to inflammatory urethritis (5) and external trauma (4)	Bulbar	4–6	pSIS	None	Dorsal onlay patch	18	Re-stricture due to infection (1) at 6 months. Post micturition dripping (6) and lack of morning erections for 35–69 days (7)	8/9 89%
Hauser et al. ⁵⁵	2006	5	61–80 (68)	Anterior urethral stricture	Bulbar (2) and penobulbar (3)	3.5–10 (9)	pSIS	None	Dorsal onlay patch	12	Re-stricture (4) at mean 12.4 months (range 3.7–17.5).	1/5 20%
Fiala et al. ⁵⁶	2007	50	45–73 (63)	Anterior urethral stricture	Bulbar (10), penobulbar (31) and penile (9)	4–14 (5.2)	pSIS	None	Ventral onlay patch. Stented for 3 weeks	31.2 (24–36)	Re-stricture in bulbar (1), bulbopenile (5) and penile (4) within first 6 months	40/50 80%

El-Kassaby et al. ⁵⁷	2008	15	27–42 (34.4)	Anterior urethral stricture	Penobulbar (7) bulbar (5) and penile (3)	3–18 (7.3)	cBAMG	None	Ventral onlay patch	25 (18–36)	Re-stricture in healthy urethral bed (1/9) and re-stricture in unhealthy urethral bed (4/6)	10/15 66%
Palminteri et al. ⁵⁸	2007	20	20–74 (41)	Anterior urethral stricture	Penile (1) bulbar (16) and penobulbar (3)	2–8 (3)	pSIS	None	Dorsal inlay (14), Ventral onlay (1) and dorsal inlay plus ventral onlay (5) patch	21 (13–35)	Penile (1) and penobulbar (2) re-stricture	17/20 85%
Fossum et al. ⁵⁹	2007	6	14–44 months (28.83)	Hypospadias	Scrotal and perineal meatus	4–6	hADM	Urothelial cells harvested via bladder lavage	Half circumference of penile skin.	51.17 (35–68). Long term study: 86.33, 72–103	Surgically corrected fistula (2) and corrective operation for urinary tract infection (1)	3/6 50%
Bhargava et al. ⁶⁰	2008	5	36–66 (52.8)	Urethral stricture secondary to lichen sclerosis. At least one previous failed urethroplasty (3) multiple internal urethrotomies (2)	Full length (1), bulbar (2) and penobulbar (2)	5–11	hADM	Buccal keratinocytes and fibroblasts	Onlay	33.6 (32–37) Long term study up to 115 months	Complete excision following penile shaft fibrosis (1) and partial excision following hyperproliferation (1) and bulbar re-stricture (2)	1/5 20%
Farahat et al. ⁶¹	2009	10	20–52 (35.7)	Recurrent inflammatory urethral stricture. At least one previous failed urethroplasty (10). No traumatic aetiology or dense spongiofibrosis.	Bulbar	0.5–2 (1.47)	pSIS (1 Layer)	None	Endoscopic dorsal inlay patch	14 (12–18)	Re-stricture (2) at 3 months in longest and second longest strictures (latter having moderate spongiofibrosis)	8/10 80%
Mantovani et al. ⁶²	2011	56	40–72 (60)	Urethral stricture secondary to inflammation, iatrogenic, idiopathic and trauma	Bulbar (35) and penile (21)	5–19 (9.4)	pSIS	None	Dorsal and ventral inlay patches	42	Re-stricture in 4 bulbar strictures and in 7 penile strictures	45/56 80%
Raya-Rivera et al. ⁶³	2011	5	10–14 (11.6)	Complete posterior urethral disruption caused by pelvic trauma (3) and previous failed posterior urethral repair (2)	Membranous urethra	4–6 (4.8)	PGA	Smooth muscle cells and urothelial cells	Tubular	71 (36–76)	Narrowing at the proximal superior graft anastomotic site. Required transurethral incision at 4 weeks (1).	4/5 80%
Palminteri et al. ⁶⁴	2012	25	23–66 (40.5)	Nonobliterative bulbar stricture	Bulbar	1.5–6 (3.3)	pSIS (4 layers)	None	Dorsal onlay (11), ventral onlay (6) and ventral plus dorsal onlay (8)	71 (52–100)	The failure rate was 14% for strictures <4 cm and 100% for strictures >4 cm.	19/25 76%

(continued on next page)

Table 2 – (continued)

Author	Year	Patient no	Age (in years)	Defect (Patient no)	Location (Patient no)	Stricture length (cm)	Scaffold source	Cell type	Technique	Follow up (months)	Complications	Successful outcome
Engel et al. ⁶⁵	2012	10	31–75	Previous internal urethrotomy 1–7 times (10). Previous dilation (2) and transurethral resection of the prostate (1)	Bulbar (9) and penile (1)	1–3	Mukocell	Oral keratinocyte	Onlay patch (9) and inlay patch (1)	Not provided	Restricture (1) in patient with multiple previous urethrotomia interna and dilations	9/10 90%
Orabi et al. ⁴⁵	2013	12	1.5–15 (8)	Hypospadias	Distal (6), midshaft (4) and proximal (2) meatus	1.5–5 (2.7) Graft length	pSIS (4 layers)	None	Onlay patch	23 (6–36)	Fistulae (3), re-stricture/complete disruption due to infection (3)	6/12 50%
Ribeiro-Filho et al. ⁶⁶	2014	44	10–71	Long and complex urethral strictures with multiple urethral procedures (3–30 per patient)	Not provided	3–18	Cadaveric urethras	None	Ventral onlay patch	42 (24–113)	Partial re-stricture (0.5–1.0 cm long) at 2–8 months (6). Complete re-stricture (5). Urethral dilations (9).	33/44 75%
Ram-Liebig et al. ⁶⁷	2015	21	24–76 (54.9)	Anterior urethral strictures. No lichen sclerosis or failed hypospadias repair. Previous treatments (17)	Bulbar (18), proximal penile/ distal bulbar (3)	2–8 (5.5)	Mukocell	Autologous somatic oral mucosa cells	Ventral onlay patch	18 (13–22)	Re-stricture (4) at 1–11 months. 1 away from graft site	17/21 81%

pSIS: porcine small intestinal submucosa; BAMG: bladder acellular matrix graft; PGA: polyglycolic acid; hADM: human acellular dermal matrix.

urethral grafts due to the reduced urethral bed present in the penile urethra whereby the scaffold is sutured to surrounding skin rather than within the more abundant corpus spongiosum present in the bulbar urethra. This decreases the vascularity of the scaffold and therefore limits tissue regeneration. Furthermore, although cell seeded scaffolds have shown promise in initial clinical studies, the cost of producing such grafts is estimated to be 6 times that of acellular scaffolds therefore reducing the attractiveness of this approach. Future studies should focus on reducing the cost of cellularised scaffold production or, alternatively, encourage the use of acellular tissue engineered scaffolds under clinical conditions known to be conducive to successful outcomes.

Future perspectives and conclusions

Significant clinical progress has been made with tissue engineered ECMs in urology in recent years. Acellular ECMs are useful for repairing small urethral defects and cell-seeded ECMs can augment or replace defective tissue segments in the ureter and bladder. Currently, composite scaffolds composed of cell seeded ECMs and synthetic degradable biomaterials are being investigated as regenerative scaffolds to replace solid organs like the urinary bladder and kidney. Soon, it is envisaged that three-dimensional (3D) bioprinting technology may ultimately lead to whole organ development in tissue-engineering. 3D bioprinting technology is garnering attention as it has enabled 3D printing of ECMs, cell lines and supportive growth factors into living tissues in a 3D format. Limitations with 3D bioprinting in its present format are decreased mechanical strength and poor tissue integration of constructs when implanted *in vivo*. Concerns over *in vivo* mechanical durability and biocompatibility need to be addressed to ensure that the progression of tissue engineered ECMs into urological practise continue. Furthermore, differences in the long-term clinical outcomes associated with implanting tissue-engineered constructs in the human urinary tract indicate that the intricacies of the relationships between cell lines, ECM scaffolds and the host's physiological environment are not yet fully understood among researchers and clinicians. These relationships need to be fully clarified and defined before tissue-engineering in urology progresses from bench to bedside in mainstream reconstructive urology.

Acknowledgement

This work was funded in part by the European Union's Horizon 2020 research and innovation programme under the Marie Skłodowska-Curie grant agreement No 708867 awarded to EC.

REFERENCES

1. Flood HD, Malhotra SJ, O'Connell HE, Ritchey MJ, Bloom DA, McGuire EJ. Long-term results and complications using augmentation cystoplasty in reconstructive urology. *Neurourol Urodyn* 1995;14(4):297–309.
2. Orlando G, Wood KJ, Stratta RJ, Yoo JJ, Atala A, Soker S. Regenerative medicine and organ transplantation: past, present, and future. *Transplantation* 2011;91(12):1310–7.
3. Garriboli M, Radford A, Southgate J. Regenerative medicine in urology. *Eur J Pediatr Surg* 2014;24(3):227–36.
4. Davis NF, McGuire BB, Callanan A, Flood HD, McGloughlin TM. Xenogenic extracellular matrices as potential biomaterials for interposition grafting in urological surgery. *J Urol* 2010;184(6):2246–53.
5. Moore T. An artificial bladder. *Lancet* 1953 Jun;261(6772):1176–8 [cited 2017 May 3].
6. Kaleli A, Ansell JS. The artificial bladder: a historical review. *Urology* 1984 Nov;24(5):423–8 [cited 2017 May 3].
7. Crapo PM, Gilbert TW, Badylak SF. An overview of tissue and whole organ decellularization processes. *Biomaterials* 2011;3233–43.
8. Gilbert TW, Sellaro TL, Badylak SF. Decellularization of tissues and organs. *Biomaterials* 2006:3675–83.
9. Callanan A, Davis NF, Walsh MT, McGloughlin TM. Mechanical characterisation of unidirectional and cross-directional multilayered urinary bladder matrix (UBM) scaffolds. *Med Eng Phys Inst Phys Eng Med* 2012;34(9):1368–74.
10. Pokrywczynska M, Gubanska I, Drewa G, Drewa T. Application of bladder acellular matrix in urinary bladder regeneration: the state of the art and future directions. *BioMed Res Intl* 2015;2015:11. <http://dx.doi.org/10.1155/2015/613439>. Article ID 613439.
11. Horst M, Madduri S, Gobet R, Sulser T, Milleret V, Hall H, et al. Engineering functional bladder tissues. *J Tissue Eng Regen Med* 2013:515–22.
12. Davis NF, Mooney R, Piterina AV, Callanan A, Flood HD, McGloughlin TM. Cell-seeded extracellular matrices for bladder reconstruction: an ex vivo comparative study of their biomechanical properties. *Int J Artif Organs* 2013;36(4):251–8.
13. Brown B, Lindberg K, Reing J, Stolz DB, Badylak SF. The basement membrane component of biologic scaffolds derived from extracellular matrix. *Tissue Eng* 2006;12(3):519–26.
14. Atala A, Danilevskiy M, Lyundup A, Glybochko P, Butnaru D, Vinarov A, et al. The potential role of tissue-engineered urethral substitution: clinical and preclinical studies. *J Tissue Eng Regen Med* December 2015;2015:3–19.
15. Davis NF, Callanan A, McGuire BB, Flood HD, McGloughlin TM. Evaluation of viability and proliferative activity of human urothelial cells cultured onto xenogenic tissue-engineered extracellular matrices. *Urology* 2011;77(4):1007.e1–7. Elsevier Inc.
16. Park IH, Lerou PH, Zhao R, Huo H, Daley GQ. Generation of human-induced pluripotent stem cells. *Nat Protoc* 2008;3(7):1180–6.
17. Davis NF, Mooney R, Piterina AV, Callanan A, McGuire BB, Flood HD, et al. Construction and evaluation of urinary bladder bioreactor for urologic tissue-engineering purposes. *Urology* 2011;78(4):954–60. Elsevier Inc.
18. Wallis MC, Yeger H, Cartwright L, Shou Z, Radisic M, Haig J, et al. Feasibility study of a novel urinary bladder bioreactor. *Tissue Eng Part A* 2008;14(3):339–48.
19. Davis NF, Mooney R, Callanan A, Flood HD, McGloughlin TM. Augmentation cystoplasty and extracellular matrix scaffolds: an ex vivo comparative study with autogenous detubularised ileum. *PLoS One* 2011;6(5):1–7.
20. Mantovani F, Trinchieri A, Castelnuovo C, Romanò AL, Pisani E. Reconstructive urethroplasty using porcine acellular matrix. *Eur Urol* 2003;44(5):600–2.
21. Davis NF, Callanan A, McGuire BB, Mooney R, Flood HD, McGloughlin TM. Porcine extracellular matrix scaffolds in reconstructive urology: an ex vivo comparative study of their biomechanical properties. *J Mech Behav Biomed Mater* 2011;4(3):375–82. Elsevier Ltd.

22. Atala A, Bauer SB, Soker S, Yoo JJ, Retik AB. Tissue-engineered autologous bladders for patients needing cystoplasty. *Lancet* 2006;367(9518):1241–6.
23. Baker SC, Southgate J. Bladder tissue regeneration. *Electrospinn Tissue Regen* 2011:225–41.
24. Caione P, Boldrinic R, Salerno A, Nappo SG. Bladder augmentation using acellular collagen biomatrix: a pilot experience in exstrophic patients. *Pediatr Surg Int* 2012;28(4):421–8.
25. Hariharan S, Johnson CP, Bresnahan BA, Taranto SE, McIntosh MJ, Stablein D. Improved graft survival after renal transplantation in the United States, 1988 to 1996. *N Engl J Med* 2000;342(9):605–12.
26. Brook NR, Nicholson ML. An audit 2 years' practice of open and laparoscopic live-donor nephrectomy at renal transplant centres in the UK and Ireland. *BJU Int* 2004;93(7):1027–31.
27. Moon KH, Ko IK, Yoo JJ, Atala A. Kidney diseases and tissue engineering. *Methods* 2016;99:112–9. Elsevier Inc.
28. Sullivan DC, Mirmalek-Sani SH, Deegan DB, Baptista PM, Aboushwareb T, Atala A, et al. Decellularization methods of porcine kidneys for whole organ engineering using a high-throughput system. *Biomaterials* 2012;33(31):7756–64.
29. Song JJ, Guyette JP, Gilpin SE, Gonzalez G, Vacanti JP, Ott HC. Regeneration and experimental orthotopic transplantation of a bioengineered kidney. *Nat Med* 2013;19(5):646–51.
30. Ott HC, Matthesen TS, Goh S-K, Black LD, Kren SM, Netoff TI, et al. Perfusion-decellularized matrix: using nature's platform to engineer a bioartificial heart. *Nat Med* 2008;14(2):213–21.
31. Baptista PM, Siddiqui MM, Lozier G, Rodriguez SR, Atala A, Soker S. The use of whole organ decellularization for the generation of a vascularized liver organoid. *Hepatology* 2011;53(2):604–17.
32. Ko IK, Abolbashari M, Huling J, Kim C, Mirmalek-Sani S-H, Moradi M, et al. Enhanced re-endothelialization of acellular kidney scaffolds for whole organ engineering via antibody conjugation of vasculatures. *Technology* 2014;2(3):243–53.
33. Ability TANT, Abolbashari M, Agcaoili SM, Lee M-K, Ko IK, Aboushwareb T, et al. Discarded human kidneys as a source of ECM scaffold for kidney regeneration technologies. *Biomaterials* 2014;32(1):52–61.
34. Song B, Niclis JC, Alikhan MA, Sakal S, Sylvain A, Kerr PG, et al. Generation of induced pluripotent stem cells from human kidney mesangial cells. *J Am Soc Nephrol* 2011;22(7):1213–20.
35. Zhou T, Benda C, Dunzinger S, Huang Y, Ho JC, Yang J, et al. Generation of human induced pluripotent stem cells from urine samples. *Nat Protoc* 2012;7(12):2080–9.
36. de Jonge PKJD, Simaioforidis V, Geutjes PJ, Oosterwijk E, Feitz WFJ. Recent advances in ureteral tissue engineering. *Curr Urol Rep* 2015;16(1):1–7.
37. Liatsikos EN, Dinlenc CZ, Kapoor R, Alexianu M, Yohannes P, Anderson AE, et al. Laparoscopic ureteral reconstruction with small intestinal submucosa. *J Endourol* 2001;15(2):217–20.
38. Smith TG, Gettman M, Lindberg G, Napper C, Pearle MS, Cadeddu JA. Ureteral replacement using porcine small intestine submucosa in a porcine model. *Urology* 2002;60(5):931–4.
39. Shalhav AL, Elbahnasy AM, Bercowsky E, Kovacs G, Brewer A, Maxwell KL, et al. Laparoscopic replacement of urinary tract segments using biodegradable materials in a large-animal model. *J Endourol* 1999;13(4):241–4.
40. Zhao Z, Yu H, Xiao F, Wang X, Yang S, Li S. Differentiation of adipose-derived stem cells promotes regeneration of smooth muscle for ureteral tissue engineering. *J Surg Res* 2012;178(1):55–62.
41. Liao W, Yang S, Song C, Li X, Li Y, Xiong Y. Construction of ureteral grafts by seeding bone marrow mesenchymal stem cells and smooth muscle cells into bladder acellular matrix. *Transpl Proc* 2013;45(2):730–4.
42. Joseph DB, Borer JG, De Filippo RE, Hodges SJ, McLorie GA. Autologous cell seeded biodegradable scaffold for augmentation cystoplasty: phase II study in children and adolescents with spina bifida. *J Urol* 2014;191(5):1389–94.
43. Sopko NA, Kates M, Bivalacqua TJ. Use of regenerative tissue for urinary diversion. *Curr Opin Urol* 2015;25(6):578–85.
44. Kates M, Singh A, Matsui H, Steinberg GD, Smith ND, Schoenberg MP, et al. Tissue-engineered urinary conduits. *Curr Urol Rep* 2015 Mar;16(3):8. <http://dx.doi.org/10.1007/s11934-015-0480-3>.
45. Orabi H, Safwat AS, Shahat A, Hammouda HM. The use of small intestinal submucosa graft for hypospadias repair: pilot study. *Arab J Urol* 2013;11(4):415–20.
46. Mangera A, Patterson JM, Chapple CR. A systematic review of graft augmentation urethroplasty techniques for the treatment of anterior urethral strictures. *Eur Urol* 2011:797–814.
47. Browne BM, Vanni AJ. Use of alternative techniques and grafts in urethroplasty. *Urol Clin North Am* 2017;44(1):127–40.
48. Mangera A, Chapple CR. Tissue engineering in urethral reconstruction—an update. *Asian J Androl* October 2012;2012:89–92.
49. Atala A, Guzman L, Retik AB. A novel inert collagen matrix for hypospadias repair. *J Urol* 1999:1148–51.
50. El-kassaby AW, Retik AB, Yoo JJ, Atala A. Urethral stricture repair with an off-the-shelf collagen matrix. *J Urol* 2003;169(1):170–3.
51. Sievert KD, Nagele U, Wuelpling C, Praetorius M, Seibold J, Stenzl A, et al. ASPEC – Reconstr 2005;4(3):2005.
52. le Roux PJ. Endoscopic urethroplasty with unseeded small intestinal submucosa collagen matrix grafts: a pilot study. *J Urol* 2005;173(1):140–3.
53. Lin J, Hao J, Jin J, Deng S, Hu J, Na Y. Homologous dermal acellular matrix graft for urethral reconstruction in man (report of 16 cases). *Zhonghua Yi Xue Za Zhi* 2005;85:1057–9.
54. Donkov II, Bashir A, Elenkov CHG, Panchev PK. Dorsal onlay augmentation urethroplasty with small intestinal submucosa: modified Barbagli technique for strictures of the bulbar urethra. *Int J Urol* 2006;13(11):1415–7.
55. Hauser S, Bastian PJ, Fechner G, Müller SC. Small intestine submucosa in urethral stricture repair in a consecutive series. *Urology* 2006;68(2):263–6.
56. Fiala R, Vidlar A, Vrtal R, Belej K, Student V. Porcine small intestinal submucosa graft for repair of anterior urethral strictures. *Eur Urol* 2007;51(6):1702–8.
57. El Kassaby A, AbouShwareb T, Atala A. Randomized comparative study between buccal mucosal and acellular bladder matrix grafts in complex anterior urethral strictures. *J Urol* 2008;179(4):1432–6.
58. Palminteri E, Berdondini E, Colombo F, Austoni E. Small intestinal submucosa (SIS) graft urethroplasty: short-term results. *Eur Urol* 2007;51(6):1695–701.
59. Fossum M, Svensson J, Kratz G, Nordenskjöld A. Autologous in vitro cultured urothelium in hypospadias repair[star, open]. *J Pediatr Urol* 2007;3(1):10–8.
60. Bhargava S, Patterson JM, Inman RD, MacNeil S, Chapple CR. Tissue-engineered buccal mucosa urethroplasty-clinical outcomes. *Eur Urol* 2008;53(6):1263–71.
61. Farahat YA, Elbahnasy AM, El-Gamal OM, Ramadan AR, El-Abd SA, Taha MR. Endoscopic urethroplasty using small intestinal submucosal patch in cases of recurrent urethral stricture: a preliminary study. *J Endourol* 2009;23(12):2001–5.
62. Mantovani F, Tondelli E, Cozzi G, Abed El Rahman D, Spinelli MG, Oliva I, et al. Reconstructive urethroplasty using porcine acellular matrix (SIS): evolution of the grafting technique and results of 10-year experience. *Urologia* 2011;78(2):92–7.

63. Raya-Rivera A, Esquiliano DR, Yoo JJ, Lopez-Bayghen E, Soker S, Atala A. Tissue-engineered autologous urethras for patients who need reconstruction: an observational study. *Lancet* 2011;**377**(9772):1175–82.
64. Palminteri E, Berdondini E, Fusco F, De Nunzio C, Salonia A. Long-term results of small intestinal submucosa graft in bulbar urethral reconstruction. *Urology* 2012;**79**(3):695–701.
65. Engel O, Ram-Liebig G, Reiß P, Schwaiger B, Pfalzgraf D, Dahlem R, et al. 15 tissue – engineered buccal mucosa urethroplasty. Outcome of our first 10 patients. *J Urol* 2012;**187**(4):e6. Elsevier Inc.
66. Ribeiro-Filho L, Fazoli A, Arap MA, Mitre A, Falci R, Chambo JL, et al. Pd3-02 cadaveric organ-specific acellular matrix for urethral reconstruction in humans: long term results. *J Urol* 2014;**191**(4):e20. Elsevier Ltd.
67. Ram-Liebig G, Bednarz J, Stuerzebecher B, Fahlenkamp D, Barbagli G, Romano G, et al. Regulatory challenges for autologous tissue engineered products on their way from bench to bedside in Europe. *Adv Drug Deliv Rev* 2015:181–91.