

Long-Term Dabigatran Treatment Delays Alzheimer's Disease Pathogenesis in the TgCRND8 Mouse Model



Marta Cortes-Canteli, PhD,^{a,b} Anna Kruyer, PhD,^b Irene Fernandez-Nueda, RT,^a Ana Marcos-Diaz, RT,^a Carlos Ceron, MB,^a Allison T. Richards, BA,^b Odella C. Jno-Charles, MB,^b Ignacio Rodriguez, PhD,^{a,c} Sergio Callejas, PhD,^a Erin H. Norris, PhD,^b Javier Sanchez-Gonzalez, PhD,^d Jesus Ruiz-Cabello, PhD,^{a,c,e,f,g} Borja Ibanez, MD, PhD,^{a,h,i} Sidney Strickland, PhD,^{b,*} Valentin Fuster, MD, PhD^{a,j,*}

ABSTRACT

BACKGROUND Alzheimer's disease (AD) is a multifactorial neurodegenerative disorder with important vascular and hemostatic alterations that should be taken into account during diagnosis and treatment.

OBJECTIVES This study evaluates whether anticoagulation with dabigatran, a clinically approved oral direct thrombin inhibitor with a low risk of intracerebral hemorrhage, ameliorates AD pathogenesis in a transgenic mouse model of AD.

METHODS TgCRND8 AD mice and their wild-type littermates were treated for 1 year with dabigatran etexilate or placebo. Cognition was evaluated using the Barnes maze, and cerebral perfusion was examined by arterial spin labeling. At the molecular level, Western blot and histochemical analyses were performed to analyze fibrin content, amyloid burden, neuroinflammatory activity, and blood-brain barrier (BBB) integrity.

RESULTS Anticoagulation with dabigatran prevented memory decline, cerebral hypoperfusion, and toxic fibrin deposition in the AD mouse brain. In addition, long-term dabigatran treatment significantly reduced the extent of amyloid plaques, oligomers, phagocytic microglia, and infiltrated T cells by 23.7%, 51.8%, 31.3%, and 32.2%, respectively. Dabigatran anticoagulation also prevented AD-related astrogliosis and pericyte alterations, and maintained expression of the water channel aquaporin-4 at astrocytic perivascular endfeet of the BBB.

CONCLUSIONS Long-term anticoagulation with dabigatran inhibited thrombin and the formation of occlusive thrombi in AD; preserved cognition, cerebral perfusion, and BBB function; and ameliorated neuroinflammation and amyloid deposition in AD mice. Our results open a field for future investigation on whether the use of direct oral anticoagulants might be of therapeutic value in AD. (J Am Coll Cardiol 2019;74:1910–23) © 2019 The Authors. Published by Elsevier on behalf of the American College of Cardiology Foundation. This is an open access article under the CC BY-NC-ND license (<http://creativecommons.org/licenses/by-nc-nd/4.0/>).

From the ^aCentro Nacional de Investigaciones Cardiovasculares (CNIC), Madrid, Spain; ^bThe Rockefeller University, New York, New York; ^cUniversidad Complutense de Madrid, Madrid, Spain; ^dPhilips Healthcare Iberia, Madrid, Spain; ^eCIC biomaGUNE, Donostia-San Sebastián, Spain; ^fIKERBASQUE, Basque Foundation for Science, Bilbao, Spain; ^gCiber de Enfermedades Respiratorias (CIBERES), Madrid, Spain; ^hIIS-Fundación Jiménez Díaz, Madrid, Spain; ⁱCIBER de Enfermedades Cardiovasculares (CIBERCV), Madrid, Spain; and the ^jIcahn School of Medicine at Mount Sinai, New York, New York. *Drs. Strickland and Fuster are joint senior authors. This work was funded by a Proof-of-Concept Award from the Robertson Therapeutic Development Fund (Dr. Cortes-Canteli), The Rockefeller University; NINDS/NIH grant NIS106668 (Drs. Norris and Strickland); European Union's Seventh Framework Programme (FP7-PEOPLE-2013-IIF), grant agreement n° PIIF-GA-2013-624811 (Drs. Cortes-Canteli and Fuster), CNIC, Madrid, Spain; Miguel Servet type I research contract (CP16/00174 and MS16/00174 [Dr. Cortes-Canteli]), Instituto de Salud Carlos III (ISCIII), CNIC; Iniciativa de Empleo Juvenil (PEJ16/MED/TL-1231 [A. Marcos-Diaz] and PEJ-2018-AI/BMD-11477 [C. Ceron]) from Consejería de Educación, Juventud y Deporte de la Comunidad de Madrid; European Regional Development Funds (FEDER "Una manera de hacer Europa") and European Social Funds (FSE "El FSE invierte en tu futuro"); and with the support of the Marie Curie Alumni Association (Dr. Cortes-Canteli). The CNIC is supported by the ISCIII, the Spanish Ministerio de Ciencia, Innovación y Universidades (MCNU), and the Pro CNIC Foundation, and is a Severo Ochoa Center of Excellence (SEV-2015-0505). CIC biomaGUNE is a Maria de Maeztu Unit of Excellence (MDM-2017-0720). Dr. Sanchez-Gonzalez is an employee of Philips Healthcare. All other authors have reported that they have no relationships relevant to the contents of this paper to disclose. Mike Sharma, MD, served as Guest Associate Editor for this paper.

Manuscript received June 21, 2019; revised manuscript received July 18, 2019, accepted July 28, 2019.



Listen to this manuscript's audio summary by Editor-in-Chief Dr. Valentin Fuster on JACC.org.

Alzheimer's disease (AD) is a progressive and multifactorial neurodegenerative disorder characterized by amyloid- β (A β) plaques, tau tangles, neuroinflammation, and brain atrophy (1). AD is strongly linked with cardiovascular risk factors, and is often accompanied by an important vascular component (2-4). The cerebrovascular pathology present in AD includes blood-brain barrier (BBB) disruption, neurovascular unit dysfunction, neurovascular uncoupling, and cerebral blood flow (CBF) alterations (5-7). Furthermore, chronic dysregulated hemostasis is present in AD, with increased thrombin generation, presence of activated platelets, and leakage of plasma proteins into the brain parenchyma (8,9), favoring the formation and persistence of fibrin clots (10,11).

SEE PAGE 1924

Fibrin(ogen) is up-regulated early in AD (12), is found intravascularly and extravascularly in areas of synaptic dysfunction and amyloid pathology (10,11), and interacts with A β (13,14) inducing the formation of resistant clots (10,15). Because decreasing systemic fibrin(ogen) levels in AD mice ameliorates disease progression (10,11,16), therapeutics that normalize the prothrombotic environment present in AD might be useful in combination with other strategies (17). Indeed, traditional anticoagulants have been reported to be beneficial for dementia patients (18,19) and AD mouse models (20,21). However, to overcome their important limitations, such as the necessity for close monitoring and the high risk of bleeding, direct oral anticoagulants (DOACs) have emerged as a useful alternative (22). Among these, dabigatran is a potent oral direct thrombin inhibitor already approved for several indications, such as the prevention of stroke in patients with nonvalvular atrial fibrillation and the treatment of venous thromboembolism (23). Dabigatran has minimal drug-drug interactions (22), a low risk of intracranial bleeding (24,25), a potent anti-inflammatory effect (26), and an effective reversal agent available (27).

Here, we present evidence that long-term anticoagulation with dabigatran ameliorates multiple features of AD pathogenesis. Dabigatran treatment preserved memory and cerebral perfusion in transgenic AD mice, which was accompanied by improved BBB integrity, together with lower levels of fibrin, amyloid deposition, and neuroinflammatory activity in the AD brain.

METHODS

MICE. TgCRND8 AD mice and nontransgenic littermate controls were provided by The Tanz Centre for Research in Neurodegenerative Diseases, University of Toronto, Canada (28). Only female mice were used for this study due to the aggressive behavior of TgCRND8 male littermates, and single housing was not feasible for long-term and behavioral experiments. Seventy female mice were obtained through in vitro fertilization: 37 TgCRND8 and 33 wild-type (WT) mice. Five TgCRND8 mice died before weaning, and 8 died during placebo/dabigatran treatment, which means a 35% loss in TgCRND8 mice, in line with previous studies (28). Only 1 WT mouse died during placebo treatment. Placebo/dabigatran treatment was also conducted in smaller 30-week-old cohorts, and brains from these mice were extracted and included in the Western blot (WB) and immunohistochemical analyses. Group sizes for all experiments are indicated in each section. Animal protocols were approved by the corresponding institutional animal care and use committees.

DABIGATRAN TREATMENT. Two-month-old female TgCRND8 mice and their nontransgenic WT littermates (n = 13 to 18 mice/group) were randomized into groups receiving chow supplemented with 5 mg/g of the prodrug dabigatran etexilate (BIBR 1048) or placebo (both provided by Boehringer Ingelheim, Ingelheim am Rhein, Germany) and were treated until they were 30 weeks old (30w) (n = 8 to 11 mice/group) or 60 weeks old (60w) (n = 5 to 7 mice/group). Diluted thrombin time assays were performed to measure dabigatran plasma concentration (23).

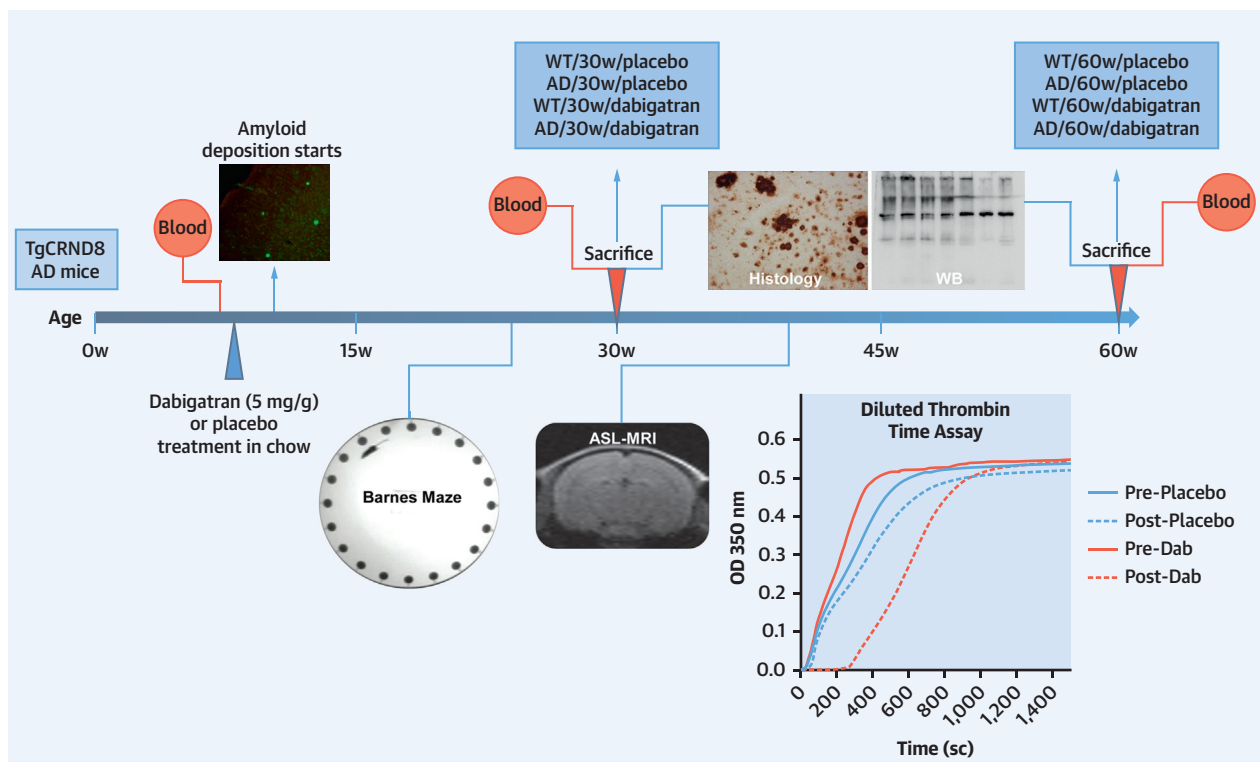
BARNES MAZE. The Barnes maze was used to assess spatial memory in 25-week-old TgCRND8 mice and WT littermates treated with dabigatran/placebo for 17 weeks (n = 16 WT/placebo; n = 14 AD/placebo; n = 16 WT/dabigatran; n = 12 AD/dabigatran mice/group) as described in the [Online Methods](#).

ARTERIAL SPIN LABELING. CBF was evaluated noninvasively by arterial spin labeling (ASL)-magnetic resonance imaging (MRI) on 40-week-old TgCRND8 mice and their WT littermates treated with dabigatran/placebo for 32 weeks (n = 7 WT/placebo, n = 6 AD/placebo, n = 6 WT/dabigatran, n = 5 AD/dabigatran mice/group) as described in the [Online Methods](#).

ABBREVIATIONS AND ACRONYMS

A β = amyloid- β
AD = Alzheimer's disease
AQP4 = aquaporin 4
ASL = arterial spin labeling
BBB = blood-brain barrier
CAA = cerebral amyloid angiopathy
CBF = cerebral blood flow
DOAC = direct oral anticoagulant
MRI = magnetic resonance imaging
PDGFR β = platelet-derived growth factor receptor- β
WB = Western blot
WT = wild type

FIGURE 1 Outline of the Experimental Design



TgCRND8 AD mice and WT littermates ($n = 13$ to 18 female mice/group) started dabigatran/placebo treatment at 8 weeks of age, and were sacrificed after 22 weeks (at 30 weeks of age [30w], $n = 8$ to 11 mice/group) or 52 weeks of treatment (at 60 weeks of age [60w], $n = 5$ to 7 mice/group). Histology and WB assays were performed in the 8 experimental groups (WT/30w/placebo, AD/30w/placebo, WT/30w/dabigatran, AD/30w/dabigatran, WT/60w/placebo, AD/60w/placebo, WT/60w/dabigatran, and AD/60w/dabigatran). Blood was extracted before and after treatment to measure dabigatran concentration by diluted thrombin time assays (representative graph is shown). Barnes maze to assess spatial memory performance was performed 17 weeks after the treatment started (at 25 weeks of age, $n = 12$ to 16 mice/group). Cerebral perfusion was measured noninvasively by ASL-MRI 32 weeks after treatment started (at 40 weeks of age, $n = 5$ to 7 mice/group). AD = Alzheimer's disease; ASL = arterial spin labeling; Dab = dabigatran; MRI = magnetic resonance imaging; WB = Western blot; WT = wild type.

WB ASSAYS. Soluble and insoluble (fibrin-containing) protein fractions were extracted from the cortex and hippocampus of mice in each experimental group ($n = 8$ WT/30w/placebo, $n = 9$ AD/30w/placebo, $n = 10$ WT/30w/dabigatran, $n = 11$ AD/30w/dabigatran, $n = 6$ WT/60w/placebo, $n = 6$ AD/60w/placebo, $n = 6$ WT/60w/dabigatran, $n = 5$ AD/60w/dabigatran mice/group) and subjected to WB analysis as described in the [Online Methods](#).

MOUSE BRAIN STAINING AND QUANTIFICATION. Diaminobenzidine immunohistochemical and double immunofluorescence analyses were performed in free-floating sections as previously described (29). All analyses were performed blindly. Experimental group sizes are the same as described for WB. Details can be found in the [Online Methods](#).

STATISTICS. All numerical values are shown as mean \pm SEM. Graphs, outlier calculations, and statistics

were generated using GraphPad Prism version 8.0.1 software (GraphPad Software, San Diego, California). Comparison of 2 groups (indicated by a horizontal line in the corresponding graph) was performed using the Student's *t*-test. To determine whether the effect of genotype, age, or treatment was significant, 2-way analyses of variance and Tukey's post-test for multiple comparisons was performed. Significance is reported as follows: * $p \leq 0.05$, ** $p \leq 0.01$, and *** $p \leq 0.001$.

RESULTS

TgCRND8 female AD mice and their nontransgenic littermates were fed chow supplemented with dabigatran etexilate or placebo at 8 weeks of age, immediately before amyloid deposition (Figure 1). On the basis of food ingestion per mouse (~ 5 g), animal weights throughout the study (26.5 ± 4.0 g), and the

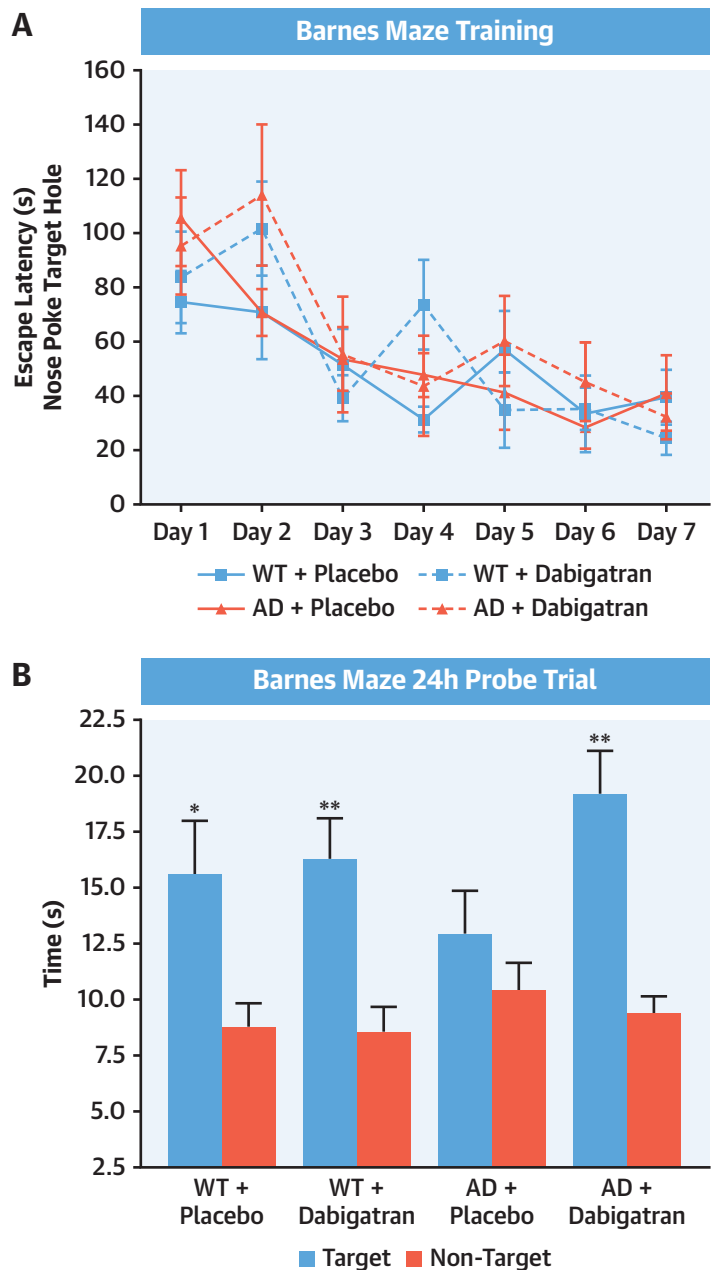
low bioavailability of dabigatran etexilate (6.5%) (30), we estimated that mice received an average dose of ~60 mg/kg of dabigatran etexilate over 24 h. Diluted thrombin time assays showed delayed clot formation in plasma from dabigatran-treated mice (Figure 1), and the average active plasma dabigatran concentration throughout treatment was 141.2 ± 72.5 ng/ml in the WT/dabigatran group and 125.7 ± 64.5 ng/ml in the AD/dabigatran group. During dabigatran/placebo treatment spatial memory and CBF were evaluated by Barnes maze and ASL-MRI, respectively (Figure 1). Mice were sacrificed at 30 or 60 weeks of age, and tissue was collected for histology and WB (Figure 1).

DABIGATRAN TREATMENT PREVENTS SPATIAL MEMORY DECLINE IN TgCRND8 AD MICE. Twenty-five-week-old TgCRND8 AD mice and their WT littermates treated with dabigatran/placebo were tested with the Barnes maze task to evaluate spatial memory. During training, all mice showed comparable decreases in the latency to explore the escape hole, indicating a similar acquisition of spatial learning (Figure 2A). However, during the probe trial, when the escape hole was blocked and spatial memory retention was challenged, TgCRND8 AD mice treated with placebo did not remember where the escape box was and spent similar time near target and nontarget holes (Figure 2B). Dabigatran-treated AD mice performed comparably to WT mice, spending significantly more time in target than in nontarget areas (Figure 2B), demonstrating that dabigatran treatment in AD mice had a beneficial effect on spatial memory retention.

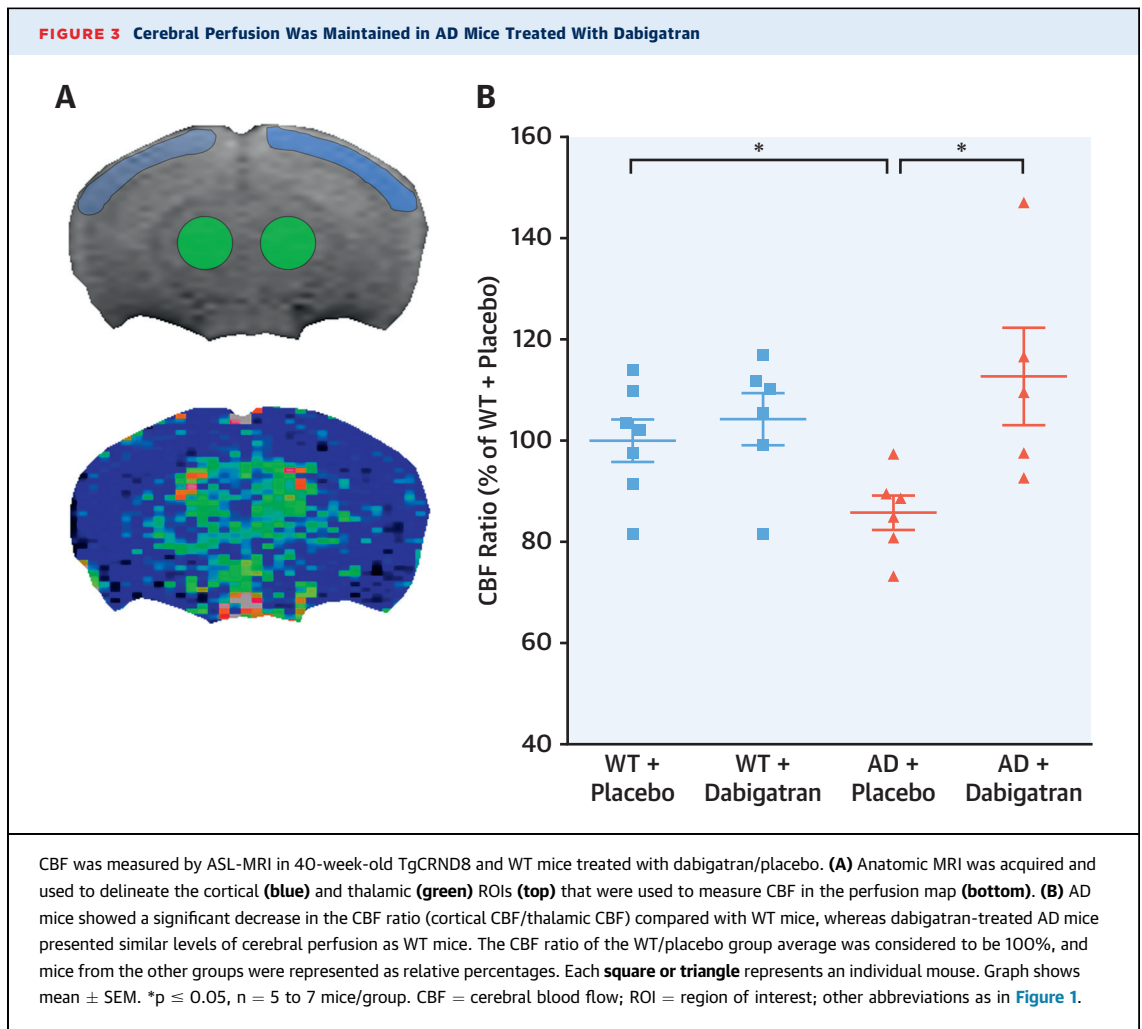
CBF IS PRESERVED IN AD MICE TREATED WITH DABIGATRAN. ASL-MRI experiments were performed on 40-week-old TgCRND8 and WT mice treated with dabigatran/placebo to quantify CBF (Figure 3A). We detected significant cortical hypoperfusion in TgCRND8 AD mice, with an ~15% decrease in CBF compared with WT littermates (Figure 3B) ($100.0 \pm 4.2\%$ WT/placebo vs. $85.8 \pm 3.4\%$ AD/placebo). This hypoperfusion was prevented by dabigatran treatment (Figure 3B) ($85.8 \pm 3.4\%$ AD/placebo vs. $112.7 \pm 9.6\%$ AD/dabigatran).

DABIGATRAN TREATMENT PREVENTS FIBRIN DEPOSITION IN THE AD BRAIN. We next compared the amount of insoluble fibrin present in the cortex and hippocampus of 30- and 60-week-old TgCRND8 and WT mice treated with dabigatran/placebo. WB assays showed that brain fibrin deposition increased as mice aged and as AD pathology progressed (Figure 4) (11). However, after long-term anticoagulation with dabigatran, there was less fibrin in the AD brain (Figure 4), indicating that inhibition of thrombin prevented pathological fibrin clot formation

FIGURE 2 AD Mice Treated With Dabigatran Showed No Cognitive Decline



TgCRND8 AD mice and WT controls treated with dabigatran/placebo were subjected to the Barnes maze task to assess spatial memory at 25 weeks of age. (A) Mice were trained for 7 days, and latency to explore the target hole (nose poke) was measured and plotted. All groups learned the position of the escape box during training. (B) Time spent near the escape and adjoining holes (target quadrant) and average time spent near other holes (nontarget quadrants) during the probe trial were measured and plotted. Placebo-treated AD mice did not show a preference for the target area, whereas dabigatran-treated AD mice explored the target region significantly more than the nontarget locations. Graphs show mean \pm SEM. * $p \leq 0.05$, ** $p \leq 0.01$ target versus nontarget quadrants in each experimental group. $n = 12$ to 16 mice/group. Abbreviations as in Figure 1.



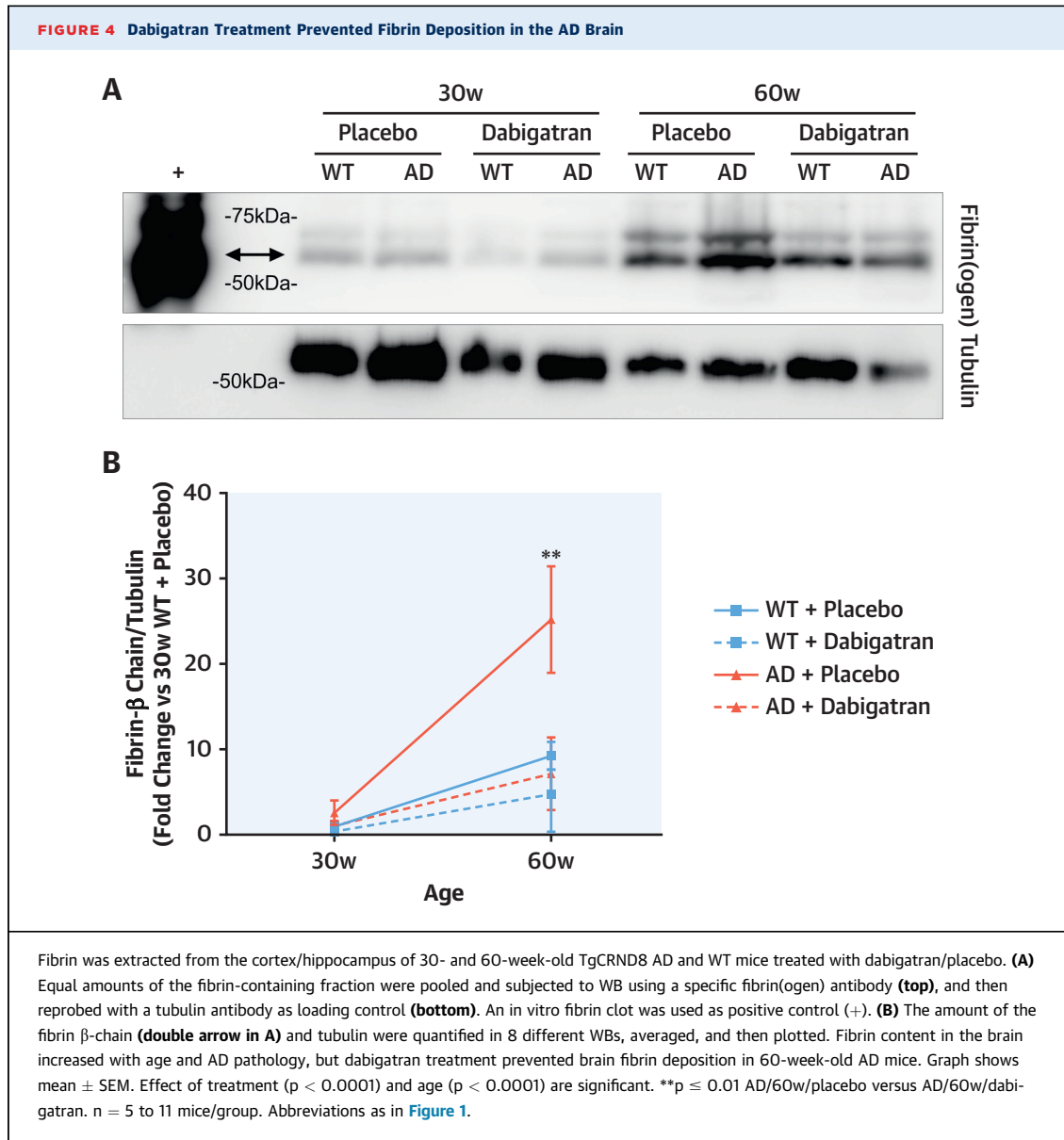
and accumulation in the mouse brain during the course of the disease.

DABIGATRAN TREATMENT AMELIORATES AMYLOID BURDEN IN AD MICE. The extent of amyloid pathology was measured by immunohistochemistry using the 6E10 A β antibody. 6E10 staining showed widespread brain amyloid pathology in 30-week-old TgCRND8 mice that increased at 60 weeks of age (**Figure 5A**). Dabigatran-treated TgCRND8 AD mice also presented A β pathology at both ages (**Figure 5A**), but quantification showed that the cortical amyloid burden was significantly ameliorated by $\sim 24\%$ in the 60-week-old dabigatran group compared with placebo-treated mice (**Figure 5B**) ($3.2 \pm 0.2\%$ AD/60w/placebo vs. $2.5 \pm 0.2\%$ AD/60w/dabigatran).

We also analyzed whether oligomers, one of the most toxic species of A β (31), were also reduced by dabigatran treatment. Immunostaining using the A β -oligomer antibody NAB61 (32) revealed a characteristic halo of oligomeric staining surrounding amyloid

plaques in AD mice (**Figure 5C**) (33). As expected, the amount of A β oligomers increased with age in TgCRND8 placebo-treated mice, but this increase was attenuated by 51.8% in dabigatran-treated AD mice (**Figure 5D**) ($2.1 \pm 0.5\%$ AD/60w/placebo vs. $1.0 \pm 0.2\%$ AD/60w/dabigatran). These results provide evidence that long-term treatment with dabigatran significantly decreased amyloid burden and A β oligomer pathology in AD mice.

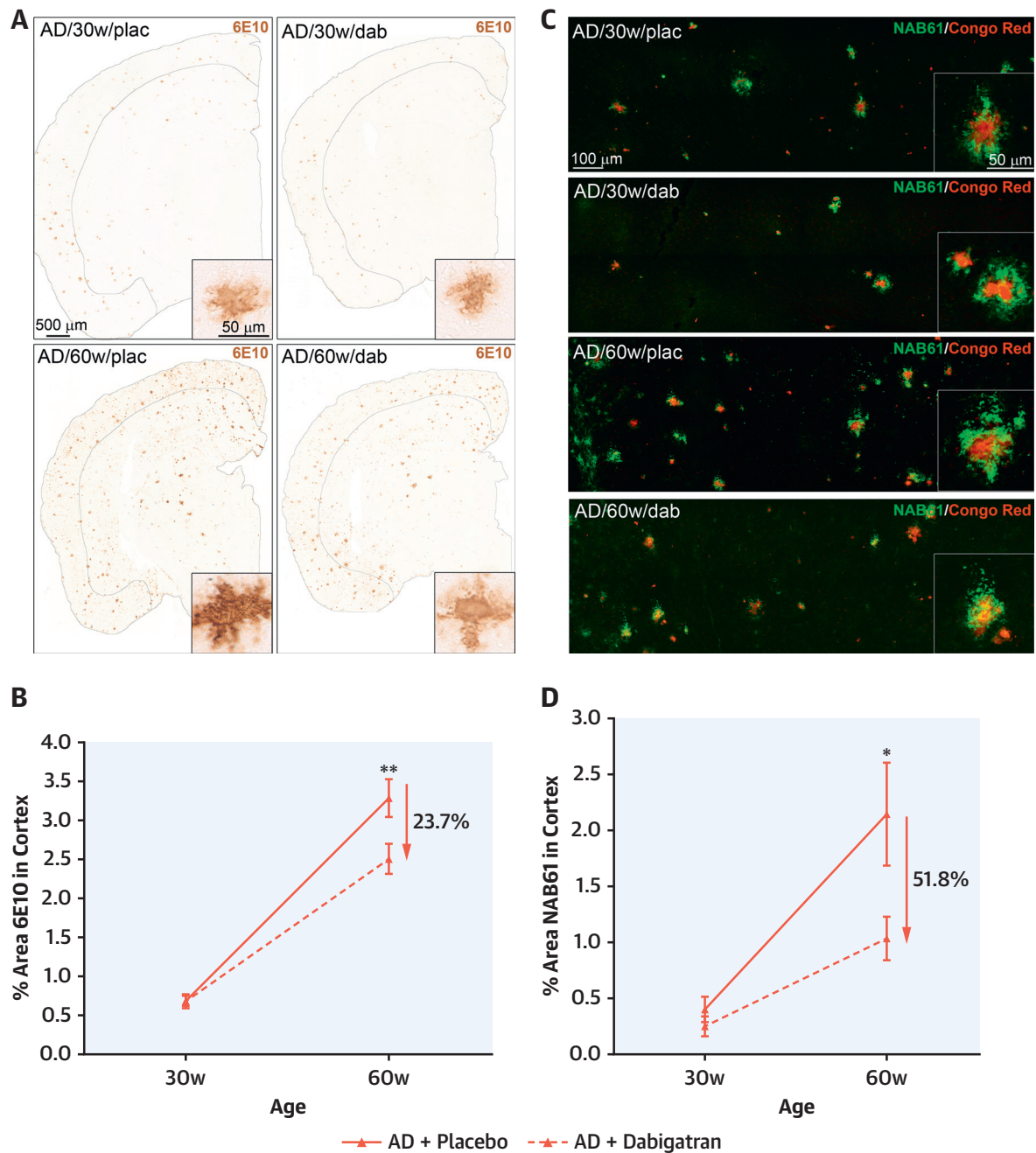
LONG-TERM ANTICOAGULATION WITH DABIGATRAN DECREASES NEUROINFLAMMATION. AD has a robust inflammatory component, mainly orchestrated by microglia and astrocytes (34). CD68 immunohistochemistry showed clusters of phagocytic microglia in the brains of TgCRND8 mice that increased with age and pathological progression (**Figures 6A and 6B**) ($0.5 \pm 0.1\%$ AD/30w/placebo vs. $1.3 \pm 0.2\%$ AD/60w/placebo). Anticoagulation reduced neuroinflammatory activity as there was a 31% decrease in cortical CD68 levels in 60-week-old dabigatran-treated



AD mice compared with placebo ([Figures 6A and 6B](#)) ($1.3 \pm 0.2\%$ AD/60w/placebo vs. $0.9 \pm 0.1\%$ AD/60w/dabigatran). We next analyzed whether AD-related astrogliosis was also ameliorated by long-term anticoagulation. WB assays showed that the overall levels of 2 markers elevated in reactive astrocytes, vimentin and glial fibrillary acidic protein (GFAP), were significantly decreased by 50% and 32.3%, respectively, in TgCRND8 60-week-old dabigatran-treated mice compared with placebo ([Figures 6C and 6D](#)).

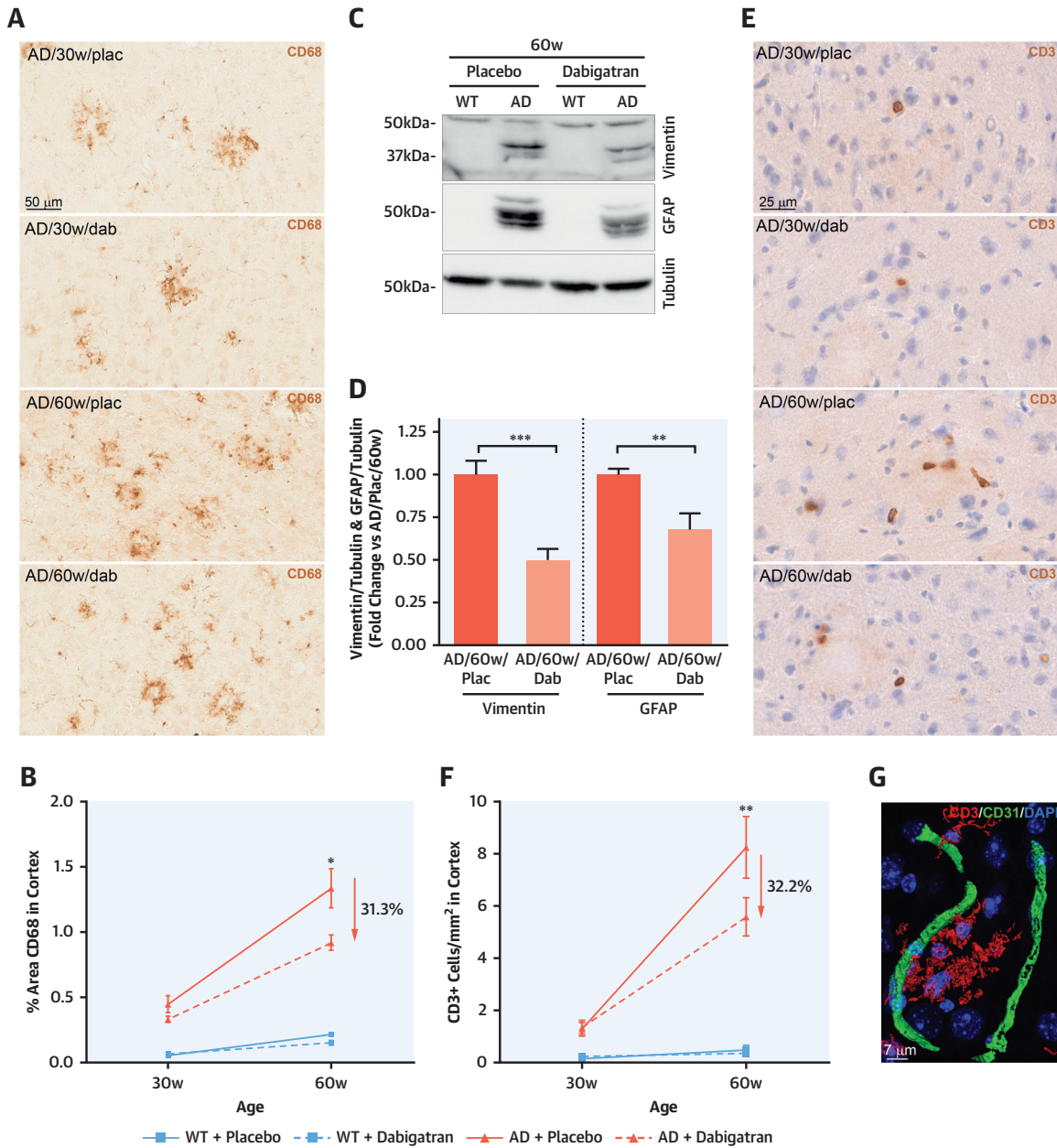
Neuroinflammation in AD is also characterized by infiltration of peripheral T cells into the brain ([35](#)). We detected an increase in CD3-positive cells

inside the brains of TgCRND8 mice compared with nontransgenic controls, and this number was augmented during pathological progression with age ([Figures 6E and 6F](#)) (1.3 ± 0.3 CD3⁺ cells/mm² AD/30w/placebo vs. 8.2 ± 1.2 CD3⁺ cells/mm² AD/60w/placebo). The majority of CD3-positive cells were extravasated into the brain parenchyma ([Figure 6G](#)), and this recruitment to the brain was decreased by 30% in aged AD mice treated with dabigatran ([Figures 6E and 6F](#)) (8.2 ± 1.2 CD3⁺ cells/mm² AD/60w/placebo vs. 5.6 ± 0.7 CD3⁺ cells/mm² AD/60w/dabigatran). All these results demonstrate that long-term anticoagulation with dabigatran ameliorated AD-related neuroinflammation.

FIGURE 5 Long-Term Anticoagulation With Dabigatran Ameliorated Amyloid Burden in AD Mice

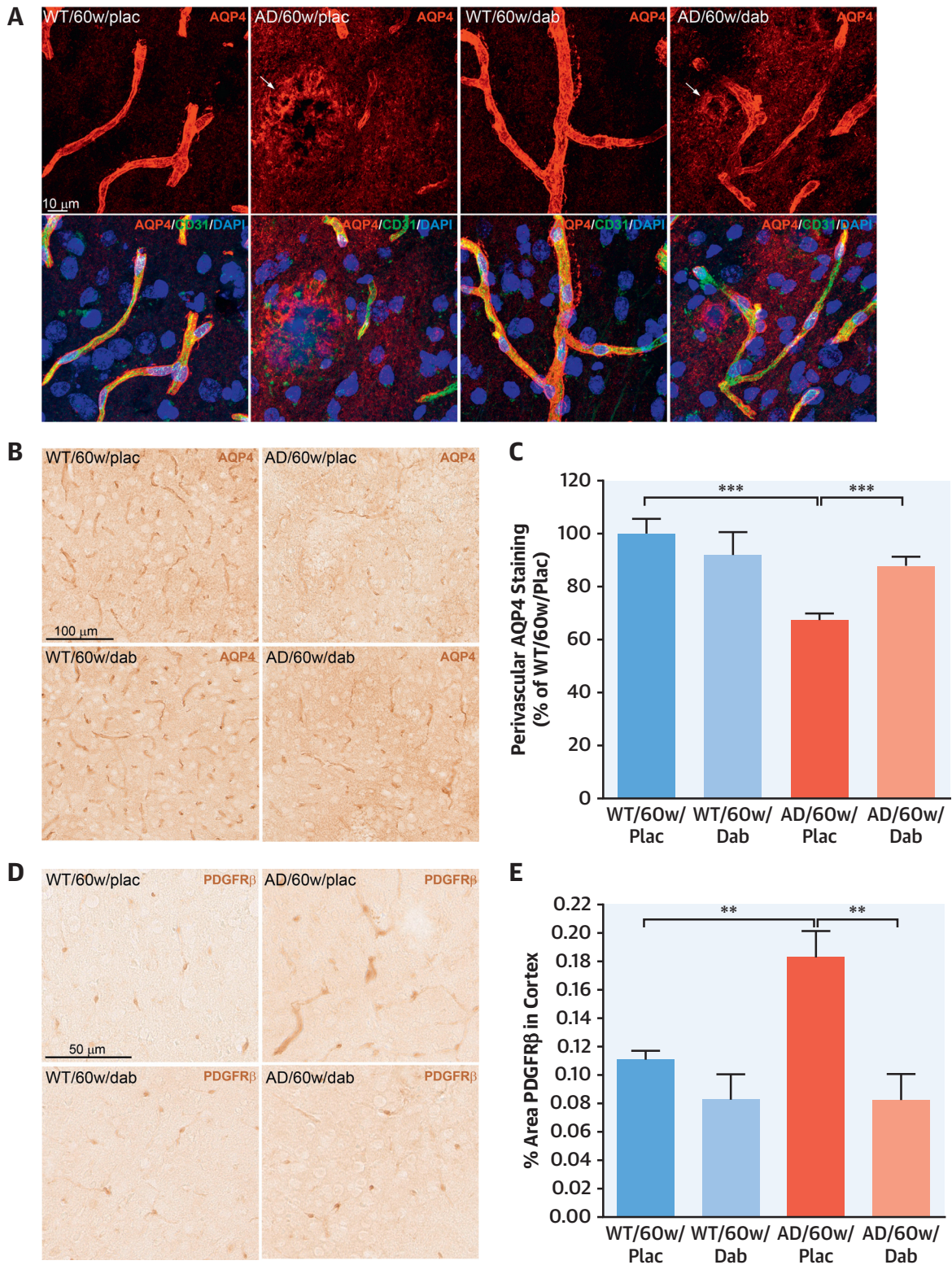
A β brain pathology was analyzed in TgCRND8 and WT mice treated with dabigatran (dab)/placebo (plac). **(A)** A β immunohistochemistry (6E10) showed widespread amyloid pathology throughout the brains of 30- and 60-week-old TgCRND8 AD mice (insets show higher magnification of cortical amyloid plaques). Sections and quantified cortical areas are outlined for clarity. **(B)** The 6E10-positive cortical area was decreased by 23.7% in 60-week-old dabigatran-treated TgCRND8 mice compared with placebo. **(C)** A β oligomer immunofluorescence analysis (NAB61 [green]) showed staining around fibrillar amyloid plaques (Congo Red [red]) in the brains of TgCRND8 mice (see insets for higher magnification). Confocal tile-scan Z-stacks were acquired over the parietal cortex, and quantification of the NAB61-positive area showed dabigatran treatment decreased by 51.8% the amount of oligomeric A β in the cortex of 60-week-old AD mice **(D)**. Graphs show mean \pm SEM. Effect of treatment ($p = 0.0089$ for 6E10 and $p = 0.0083$ for NAB61) and age ($p < 0.0001$ for both) are significant. * $p \leq 0.05$, ** $p \leq 0.01$ AD/60w/placebo versus AD/60w/dabigatran. $n = 5$ to 11 mice/group. Abbreviations as in [Figure 1](#).

FIGURE 6 Dabigatran Treatment Ameliorated Neuroinflammation in AD Mice



(A) Immunohistochemical analysis showed CD68-positive microglial clusters in 30-week-old and more numerous in 60-week-old AD mice. (B) Quantification of the CD68-positive cortical area showed a 31.3% decrease in the amount of phagocytic microglia in 60-week-old dabigatran-treated AD mice compared to placebo. (C) Soluble proteins from 60-week-old mice were extracted, pooled, and subjected to WB using a vimentin antibody (top), and then reprobated with a GFAP antibody (middle) and a tubulin antibody (loading control, bottom). Six different WBs were quantified, averaged, and plotted (D). Degradation products of vimentin and GFAP astrocytic markers drastically increased in AD mice compared with WT mice (53), but their levels were ameliorated in dabigatran-treated AD mice by 50% and 32.3%, respectively. (E) Immunohistochemical staining showed scattered CD3-positive cells in 30-week-old AD brains that increased with age and pathology. (F) Quantification of CD3-positive cells in the cortex showed that infiltrated T cells significantly decreased by 32.2% in dabigatran-treated AD mice compared with placebo. (G) Double immunofluorescence showed that CD3-positive cells (red) were not inside blood vessels (CD31, green) but rather were extravasated into the brain parenchyma. (B and F) The cortical area quantified was similar to the one outlined in the low-power images in Figure 5A. Graphs show mean \pm SEM. The effect of treatment and age were significant ($p < 0.0001$ for both). * $p \leq 0.05$, ** $p \leq 0.01$, *** $p \leq 0.001$ AD/60w/placebo versus AD/60w/dabigatran. $n = 5$ to 11 mice/group (A to F) and $n = 5$ to 6 mice/group (C and D). GFAP = glial fibrillary acidic protein; other abbreviations as in Figures 1 and 5.

FIGURE 7 Dabigatran Treatment Preserved AQP4 Expression and Pericyte Morphology at the BBB



DABIGATRAN TREATMENT PRESERVED BBB INTEGRITY IN AD MICE.

We next analyzed the expression and localization of aquaporin 4 (AQP4), a water channel selectively present in astrocytic perivascular endfeet and essential for A β clearance and neurovascular coupling (36). AQP4 was localized around brain blood vessels in 60-week-old WT mice (Figures 7A and 7B). However, in age-matched AD mice, astrocyte depolarization was found with AQP4 expression shifting from the astrocytic endfeet surrounding vessels to areas of neuropil near the amyloid plaques (Figure 7A). Quantification showed that perivascular AQP4 decreased by 30% in AD mice compared with age-matched WT controls (Figure 7C) ($100.0 \pm 5.6\%$ WT/60w/placebo vs. $67.4 \pm 2.5\%$ AD/60w/placebo). Dabigatran treatment partially prevented the redistribution of AQP4 expression from endfeet to non-endfeet areas in AD mice (Figure 7C) ($67.4 \pm 2.5\%$ AD/60w/placebo vs. $88.0 \pm 3.3\%$ AD/60w/dabigatran).

Because pericytes are also an integral part of the neurovascular unit, we performed immunohistochemical analysis using the pericyte marker platelet-derived growth factor receptor- β (PDGFR β). We observed that pericytes in the TgCRND8 AD mice presented abnormal hypertrophic processes surrounding capillaries (Figure 7D), similar to what has been described in other transgenic AD mouse lines (37). These elongated processes significantly increased the overall PDGFR β -positive area in the cortex of 60-week-old AD mice compared with WT littermates (Figure 7E) ($0.11 \pm 0.006\%$ WT/60w/placebo vs. $0.18 \pm 0.02\%$ AD/60w/placebo). Dabigatran treatment ameliorated these alterations in pericyte morphology and normalized the PDGFR β staining in TgCRND8 AD mice (Figures 7D and 7E) ($0.18 \pm 0.02\%$ AD/60w/placebo vs. $0.08 \pm 0.02\%$ AD/60w/dabigatran).

Taken together, our results indicate that the beneficial effects observed after long-term anticoagulation with dabigatran could be partially due to improved preservation of BBB structure and integrity.

DISCUSSION

Increasing evidence supports a chronic procoagulant state in AD with important implications for disease onset and progression. Here, we present behavioral, physiological, and molecular evidence that targeting the thrombotic component of this disorder with a DOAC ameliorates different AD pathological hallmarks in an AD mouse model (Central Illustration). Treatment with dabigatran preserved cerebral perfusion and prevented memory decline in TgCRND8 AD mice. These functional improvements were accompanied in the long term by inhibition of fibrin deposition, amelioration of amyloid burden and neuroinflammatory activity, and enhanced preservation of the BBB in the AD mouse brain.

Pathological accumulation of cerebral fibrin in the brain parenchyma and inside cerebral blood vessels plays a role on AD pathogenesis (10,11,38). Dabigatran treatment prevented the abnormal deposition of fibrin (Figure 4), which may have facilitated the cerebral circulation in the AD mouse brain (Figure 3). This result is remarkable because CBF alterations precede the onset of dementia (39). Additionally, long-term anticoagulation decreased amyloid plaques, and, more importantly, halved levels of A β oligomers (Figure 5), the toxic A β species recognized as a main contributor to AD synaptic dysfunction (31). Because A β strongly interacts with fibrin (15) and fibrinogen (13), and this interaction induces formation of blood clots resistant to degradation (10,15), decreasing the amount of fibrin by long-term anticoagulation may have prevented A β binding and subsequent entrapment into degradation-resistant clots.

Hemostatic and nonhemostatic mechanisms were likely involved in dabigatran's amelioration of AD neuroinflammation (Figure 6). Reduction in fibrin clot formation, and the subsequent improvement in CBF, may have allowed proper nutrient and oxygen delivery to the brain, supporting neural health and function. In addition, dabigatran also inhibits thrombin's effect on platelet aggregation (23), hence

FIGURE 7 Continued

Immunostaining was performed on brain slices from 60-week-old TgCRND8 AD and WT mice treated with dabigatran/placebo to detect expression and localization of AQP4 and PDGFR β . (A) Double immunofluorescence showed that AQP4 expression (red) was found around blood vessels (CD31 [green]) in the astrocytic endfeet of WT mice. However, AQP4 staining shifted from its perivascular location to neuropil areas surrounding amyloid plaques in AD mice (arrows). (B) Immunohistochemical analysis was performed to segment and quantify the amount of perivascular AQP4 in all experimental groups (C). AD mice treated long term with dabigatran presented significantly more perivascular AQP4 staining than placebo-treated AD mice. (D) PDGFR β immunohistochemistry demonstrated hypertrophic pericytic processes outlining the capillaries of TgCRND8 AD mice. (E) Quantification showed a robust increase of PDGFR β -positive area in the cortex of 60-week-old AD mice compared with WT mice. This abnormal pericyte staining was normalized by dabigatran treatment. Graphs show mean \pm SEM. **p \leq 0.01, ***p \leq 0.001. n = 5 to 6 mice/group. AQP4 = aquaporin 4; PDGFR β = platelet-derived growth factor receptor- β ; other abbreviations as in Figures 1 and 5.

contributing to decrease primary hemostasis and recruitment of white blood cells into the AD brain. Furthermore, thrombin, fibrin, and A β act as proinflammatory mediators in AD (9,34,40,41). Therefore, the inhibition of thrombin and the resulting decrease in fibrin and A β accumulation in the dabigatran-treated AD mice possibly contributed to the amelioration of neuroinflammation. Studies using other AD mouse models have shown that thrombin inhibition diminishes the neuroinflammatory response (40,42), further supporting the role of thrombin in AD-related inflammation.

The BBB is compromised in AD, which translates into neurovascular uncoupling (6), together with leakage of plasma components (e.g., thrombin and fibrin) into the cerebral parenchyma, failure of proper elimination of waste products (e.g., A β), and infiltration of peripheral immune cells into the brain (5). Long-term anticoagulation with dabigatran ameliorated all of these pathological features, possibly through preservation of pericytes and astrocytic endfeet, integral parts of the neurovascular unit (Figure 7). Dabigatran specifically prevented the redistribution of perivascular AQP4, one of the key players in the uptake, clearance, and active transport of A β through the BBB (36), which may have facilitated A β drainage and contributed to the decrease in amyloid burden (Figure 5). Dabigatran treatment also prevented pericyte alterations in the AD mouse brain. Considering that pericyte degeneration in AD contributes to BBB disruption (43), fibrin extravasation (44), and depolarization of astrocyte endfeet (45), preservation of pericyte structure and/or function by dabigatran may have contributed to the observed reduction in fibrin content in the AD brain (Figure 4) and the maintenance of AQP4 at astrocytic endfeet (Figure 7). The imbalance between A β production and clearance through an impaired BBB is considered one of the main pathological processes underlying AD (1). Our results further support the hypothesis that fibrin and altered hemostasis may be one of the missing links between AD and vascular pathology (8,17).

The amelioration of AD-related neuroinflammation, amyloid burden, and BBB dysfunction was observed to be significant only after long-term anticoagulation. Because the procoagulant state in AD is a chronic, sustained process, and fibrin deposition accumulates in the brain as pathology advances with age (Figure 4 and Cortes-Canteli et al. [11]), the effect of dabigatran treatment was more robust after longstanding treatment. Indeed, recent epidemiological studies have shown reduced incidence of dementia in atrial fibrillation patients that undergo long-term anticoagulation (46). Interestingly, we also

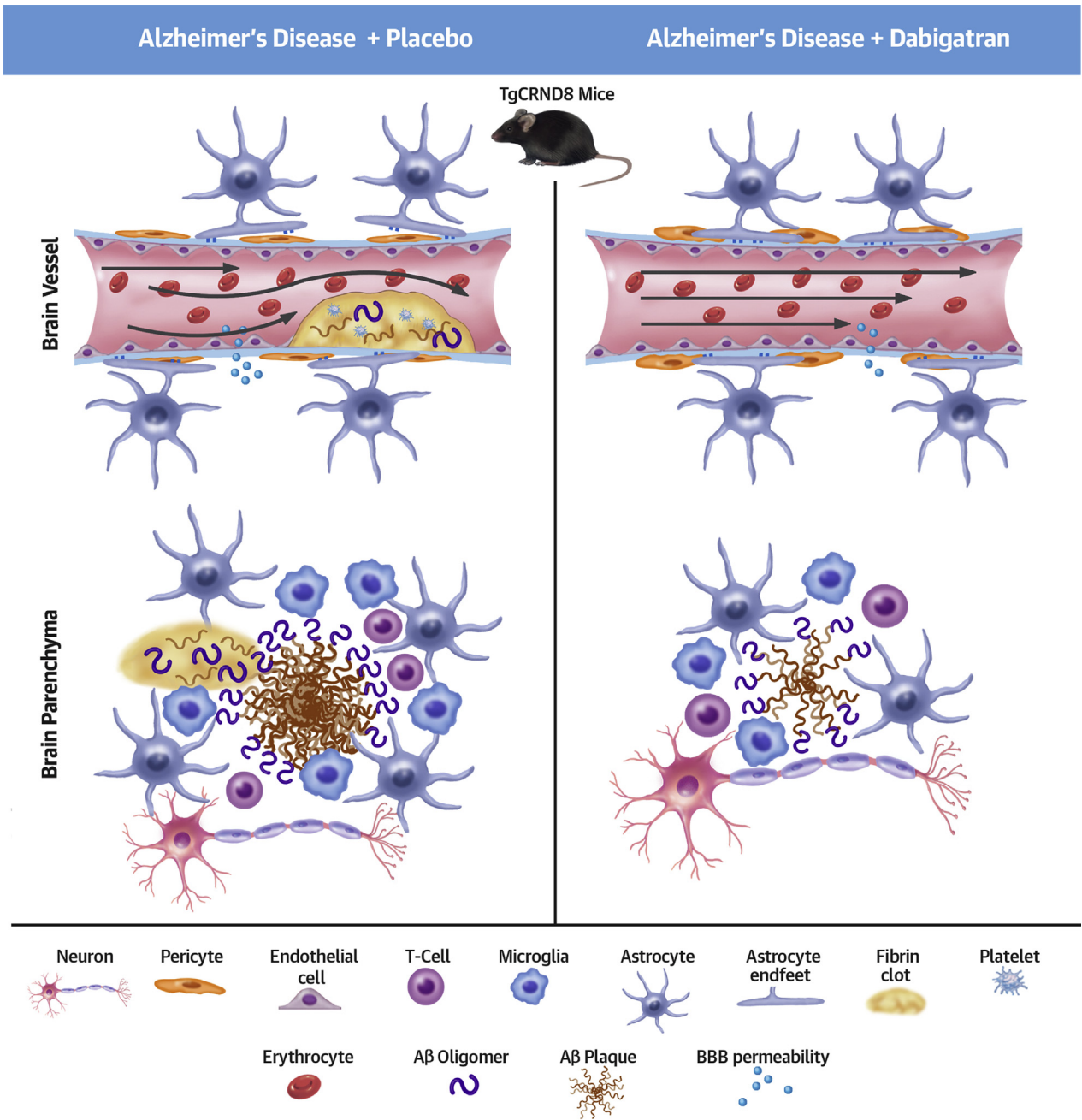
observed that treatment with dabigatran was accompanied by preservation of cognition (Figure 2), which is essential for any molecule to be considered a promising therapeutic approach in AD.

Our results indicate that the normalization of the AD prothrombotic state with dabigatran ameliorated AD pathogenesis. We expect that other clinically approved DOACs, such as factor Xa inhibitors, may have a similar beneficial effect on AD. Repurposing an already approved drug, such as a DOAC, to a new disease indication, such as AD, translates to a quicker transition from bench to bedside and a greater clinical impact.

AD is a multifactorial disease, and efforts should be focused toward the development of multidrug personalized therapies targeting the different mechanisms contributing to an individual's pathology instead of the "1 target, 1 treatment" approach that has not been successful thus far. Our studies indicate that a pathological mechanism worth targeting in AD is the procoagulant state, although other contributing factors should be also treated accordingly.

STUDY LIMITATIONS. One of the limitations of anticoagulation in AD is the increased incidence of intracerebral hemorrhage in AD patients due to the presence of cerebral microbleeds (47) and A β deposition in vessels as cerebral amyloid angiopathy (CAA) (48). The incidence of both of these vasculopathies is also linked with worse cognitive performance, and the appropriate use of antithrombotic agents in this population is under debate (49). Dabigatran presents a low risk of intracranial bleeding (24,25) and does not promote the formation of cerebral microbleeds in AD mice (50). Furthermore, we observed no hemorrhages or incidents of intracerebral bleeding in any of our animals (data not shown). Nevertheless, use of dabigatran or other antithrombotic agents in AD patients with widespread CAA and cerebral microbleeds will need to be carefully evaluated by a heart-brain team of experts to ensure its use outweighs any bleeding risk (49). Yet, if dabigatran is used early in the course of the disease, A β may be cleared more efficiently through the BBB, hence decreasing its deposition in the cortical and leptomeningeal vessels forming CAA. Also, because increased clot formation in AD is a chronic process, long-term treatment with low doses of dabigatran may be sufficient to have a therapeutic effect in AD. The dose used in the present study is lower than what has been used in other animal studies (26,42,51). Because the half-life of dabigatran etexilate in mice is short (~15 min) and dabigatran is 2-fold less effective inhibiting mouse than human thrombin (23), a supratherapeutic dose in mice is needed to achieve similar plasma

CENTRAL ILLUSTRATION Dabigatran Treatment Ameliorates Alzheimer's Disease Pathogenesis in the TgCRND8 Mouse Model



Cortes-Canteli, M. et al. *J Am Coll Cardiol.* 2019;74(15):1910-23.

Long-term treatment with dabigatran prevents fibrin deposition in the Alzheimer's disease brain, ameliorating amyloid pathology and neuroinflammation and preserving blood-brain barrier integrity and central blood flow. Aβ = amyloid-β; BBB = blood-brain barrier.

concentrations of the drug as in humans. Although further studies are required to carefully extrapolate the long-term anticoagulation achieved in our AD mice to humans, the dose we used rendered plasma dabigatran concentrations similar to what has been reported in patients undergoing long-term anticoagulation (52). Additionally, even though dabigatran presents a predictable pharmacokinetic profile (22), long-term anticoagulation in the frail, aging, and comorbid AD population may benefit from a drug-tailored program.

CONCLUSIONS

Long-term anticoagulation with dabigatran inhibits thrombin and the abnormal deposition of fibrin in the AD brain, hence preserving blood flow and facilitating oxygen and nutrient delivery to the brain. This drug, in turn, has a beneficial effect on controlling neuroinflammation, maintaining the integrity and functionality of the BBB, and facilitating A β clearance (Central Illustration). Therefore, therapeutics aimed at normalizing the prothrombotic environment present in AD, in combination with other disease-modifying compounds, might be instrumental in improving AD pathogenesis.

ACKNOWLEDGMENTS The authors thank the Centre for Research in Neurodegenerative Diseases at the University of Toronto (Toronto, Ontario, Canada) and the Center for Neurodegenerative Disease Research at University of Pennsylvania (Philadelphia, Pennsylvania) for kindly providing the TgCRND8 mice and

the NAB61 antibody, respectively. The 7-T MRI scanner used is part of the ReDiB from Infraestructuras Científico-Técnico Singulares (ICTS). The authors also thank Dr. Jay L. Degen for supplying the fibrin(ogen) antibody, Drs. Ashley Goss and Joanne Van Ryn from Boehringer Ingelheim Pharma for providing the chow and information regarding dabigatran's mechanism of action, Marina Saiz for assisting during her CICE-RONE summer project, Carlos Galan-Arriola for his invaluable help with the Central Illustration, and CNIC Histopathology and Microscopy Units for their support with brain staining.

ADDRESS FOR CORRESPONDENCE: Dr. Marta Cortes-Canteli, Centro Nacional de Investigaciones Cardiovasculares (CNIC), Melchor Fernández Almagro 3, 28029, Madrid, Spain. E-mail: mcortes@cnic.es. Twitter: [@mcortescanteli](https://twitter.com/mcortescanteli).

PERSPECTIVES

COMPETENCY IN MEDICAL KNOWLEDGE: AD has a multifactorial etiology, and thrombosis is among the mechanisms involved. In a transgenic mouse model of AD, long-term anticoagulation with dabigatran reduced fibrin deposition, neuroinflammation, amyloid deposition, and cognitive decline.

TRANSLATIONAL OUTLOOK: Concordant results of additional studies in other animal models would support clinical trials of antithrombotic therapy for prevention or amelioration of AD.

REFERENCES

- Lane CA, Hardy J, Schott JM. Alzheimer's disease. *Eur J Neurol* 2018;25:59-70.
- Iadecola C, Gottesman R. Cerebrovascular alterations in Alzheimer disease: incidental or pathogenic? *Circ Res* 2018;123:406-8.
- Picano E, Bruno RM, Ferrari GF, Bonuccelli U. Cognitive impairment and cardiovascular disease: so near, so far. *Int J Cardiol* 2014;175:21-9.
- de la Torre JC. Alzheimer's Turning Point. A Vascular Approach to Clinical Prevention. 1st edition. New York, NY: Springer International Publishing, 2016.
- Sweeney MD, Sagare AP, Zlokovic BV. Blood-brain barrier breakdown in Alzheimer disease and other neurodegenerative disorders. *Nat Rev Neurol* 2018;14:133-50.
- Kisler K, Nelson AR, Montagne A, Zlokovic BV. Cerebral blood flow regulation and neurovascular dysfunction in Alzheimer disease. *Nat Rev Neurosci* 2017;18:419-34.
- Iadecola C. The pathobiology of vascular dementia. *Neuron* 2013;80:844-66.
- Cortes-Canteli M, Zamolodchikov D, Ahn HJ, Strickland S, Norris EH. Fibrinogen and altered hemostasis in Alzheimer's disease. *J Alzheimers Dis* 2012;32:599-608.
- Zamolodchikov D, Strickland S. A possible new role for Abeta in vascular and inflammatory dysfunction in Alzheimer's disease. *Thromb Res* 2016;141 Suppl 2:S59-61.
- Cortes-Canteli M, Paul J, Norris EH, et al. Fibrinogen and beta-amyloid association alters thrombosis and fibrinolysis: a possible contributing factor to Alzheimer's disease. *Neuron* 2010;66:695-709.
- Cortes-Canteli M, Mattei L, Richards AT, Norris EH, Strickland S. Fibrin deposited in the Alzheimer's disease brain promotes neuronal degeneration. *Neurobiol Aging* 2015;36:608-17.
- Kitamura Y, Usami R, Ichihara S, et al. Plasma protein profiling for potential biomarkers in the early diagnosis of Alzheimer's disease. *Neuro Res* 2017;39:231-8.
- Ahn HJ, Zamolodchikov D, Cortes-Canteli M, Norris EH, Glickman JF, Strickland S. Alzheimer's disease peptide {beta}-amyloid interacts with fibrinogen and induces its oligomerization. *Proc Natl Acad Sci U S A* 2010;107:21812-7.
- Zamolodchikov D, Berk-Rauch HE, Oren DA, et al. Biochemical and structural analysis of the interaction between β -amyloid and fibrinogen. *Blood* 2016;128:1144-51.
- Zamolodchikov D, Strickland S. Abeta delays fibrin clot lysis by altering fibrin structure and attenuating plasminogen binding to fibrin. *Blood* 2012;119:3342-51.
- Paul J, Strickland S, Melchor JP. Fibrin deposition accelerates neurovascular damage and neuroinflammation in mouse models of Alzheimer's disease. *J Exp Med* 2007;204:1999-2008.

17. Strickland S. Blood will out: vascular contributions to Alzheimer's disease. *J Clin Invest* 2018; 128:556-63.
18. Walsh AC, Walsh BH, Melaney C. Senile-prenile dementia: follow-up data on an effective psychotherapy-anticoagulant regimen. *J Am Geriatr Soc* 1978;26:467-70.
19. Ratner J, Rosenberg G, Kral VA, Engelsmann F. Anticoagulant therapy for senile dementia. *J Am Geriatr Soc* 1972;20:556-9.
20. Bergamaschini L, Rossi E, Storini C, et al. Peripheral treatment with enoxaparin, a low molecular weight heparin, reduces plaques and beta-amyloid accumulation in a mouse model of Alzheimer's disease. *J Neurosci* 2004;24:4181-6.
21. Timmer NM, van Dijk L, van der Zee CE, Kiliaan A, de Waal RM, Verbeek MM. Enoxaparin treatment administered at both early and late stages of amyloid beta deposition improves cognition of APP^{swe}/PS1^{dE9} mice with differential effects on brain Aβ levels. *Neurobiol Dis* 2010;40:340-7.
22. Shameem R, Ansell J. Disadvantages of VKA and requirements for novel anticoagulants. *Best Pract Res Clin Haematol* 2013;26:103-14.
23. van Ryn J, Goss A, Huel N, et al. The discovery of dabigatran etexilate. *Front Pharmacol* 2013;4:12.
24. Garnock-Jones KP. Dabigatran etexilate: a review of its use in the prevention of stroke and systemic embolism in patients with atrial fibrillation. *Am J Cardiovasc Drugs* 2011;11:57-72.
25. Hart RG, Diener HC, Yang S, et al. Intracranial hemorrhage in atrial fibrillation patients during anticoagulation with warfarin or dabigatran: the RE-LY trial. *Stroke* 2012;43:1511-7.
26. Bogatkevich GS, Ludwicka-Bradley A, Nietert PJ, Akter T, van Ryn J, Silver RM. Anti-inflammatory and antifibrotic effects of the oral direct thrombin inhibitor dabigatran etexilate in a murine model of interstitial lung disease. *Arthritis Rheum* 2011;63:1416-25.
27. Pollack CV Jr., Reilly PA, van Ryn J, et al. Idarucizumab for dabigatran reversal—full cohort analysis. *N Engl J Med* 2017;377:431-41.
28. Chishti MA, Yang DS, Janus C, et al. Early-onset amyloid deposition and cognitive deficits in transgenic mice expressing a double mutant form of amyloid precursor protein 695. *J Biol Chem* 2001;276:21562-70.
29. Cortes-Canteli M, Luna-Medina R, Sanz-Sancristobal M, Alvarez-Barrientos A, Santos A, Perez-Castillo A. CCAAT/enhancer binding protein beta deficiency provides cerebral protection following excitotoxic injury. *J Cell Sci* 2008;121:1224-34.
30. Stangier J, Clemens A. Pharmacology, pharmacokinetics, and pharmacodynamics of dabigatran etexilate, an oral direct thrombin inhibitor. *Clin Appl Thromb Hemost* 2009;15 Suppl 1:95-165.
31. Haass C, Selkoe DJ. Soluble protein oligomers in neurodegeneration: lessons from the Alzheimer's amyloid beta-peptide. *Nat Rev Mol Cell Biol* 2007;8:101-12.
32. Lee EB, Leng LZ, Zhang B, et al. Targeting amyloid-beta peptide (Aβ) oligomers by passive immunization with a conformation-selective monoclonal antibody improves learning and memory in Aβ precursor protein (APP) transgenic mice. *J Biol Chem* 2006;281:4292-9.
33. Koffie RM, Meyer-Luehmann M, Hashimoto T, et al. Oligomeric amyloid beta associates with postsynaptic densities and correlates with excitatory synapse loss near senile plaques. *Proc Natl Acad Sci U S A* 2009;106:4012-7.
34. Heneka MT, Carson MJ, Khoury JE, et al. Neuroinflammation in Alzheimer's disease. *Lancet Neurol* 2015;14:388-405.
35. Jimenez S, Baglietto-Vargas D, Caballero C, et al. Inflammatory response in the hippocampus of PS1M146L/APP751S mouse model of Alzheimer's disease: age-dependent switch in the microglial phenotype from alternative to classic. *J Neurosci* 2008;28:11650-61.
36. Yang C, Huang X, Huang X, et al. Aquaporin-4 and Alzheimer's disease. *J Alzheimers Dis* 2016;52:391-402.
37. Park L, Zhou J, Zhou P, et al. Innate immunity receptor CD36 promotes cerebral amyloid angiopathy. *Proc Natl Acad Sci U S A* 2013;110:3089-94.
38. Canobbio I, Visconte C, Oliviero B, et al. Increased platelet adhesion and thrombus formation in a mouse model of Alzheimer's disease. *Cell Signal* 2016;28:1863-71.
39. Wierenga CE, Hays CC, Zlatar ZZ. Cerebral blood flow measured by arterial spin labeling MRI as a preclinical marker of Alzheimer's disease. *J Alzheimers Dis* 2014;42 Suppl 4:S411-9.
40. Tripathy D, Sanchez A, Yin X, Luo J, Martinez J, Grammas P. Thrombin, a mediator of cerebrovascular inflammation in AD and hypoxia. *Front Aging Neurosci* 2013;5:19.
41. Petersen MA, Ryu JK, Akassoglou K. Fibrinogen in neurological diseases: mechanisms, imaging and therapeutics. *Nat Rev Neurosci* 2018;19:283-301.
42. Marangoni MN, Braun D, Situ A, et al. Differential effects on glial activation by a direct versus an indirect thrombin inhibitor. *J Neuroimmunol* 2016;297:159-68.
43. Winkler EA, Sagare AP, Zlokovic BV. The pericyte: a forgotten cell type with important implications for Alzheimer's disease? *Brain Pathol* 2014; 24:371-86.
44. Sengillo JD, Winkler EA, Walker CT, Sullivan JS, Johnson M, Zlokovic BV. Deficiency in mural vascular cells coincides with blood-brain barrier disruption in Alzheimer's disease. *Brain Pathol* 2013;23:303-10.
45. Armulik A, Genové G, Mäe M, et al. Pericytes regulate the blood-brain barrier. *Nature* 2010; 468:557.
46. Friberg L, Rosenqvist M. Less dementia with oral anticoagulation in atrial fibrillation. *Eur Heart J* 2018;39:453-60.
47. Martinez-Ramirez S, Greenberg SM, Viswanathan A. Cerebral microbleeds: overview and implications in cognitive impairment. *Alzheimers Res Ther* 2014;6:33.
48. Banerjee G, Carare R, Cordonnier C, et al. The increasing impact of cerebral amyloid angiopathy: essential new insights for clinical practice. *J Neurol Neurosurg Psychiatry* 2017;88:982-94.
49. DeSimone CV, Graff-Radford J, El-Harasis MA, Rabinstein AA, Asirvatham SJ, Holmes DR Jr. Cerebral amyloid angiopathy: diagnosis, clinical implications, and management strategies in atrial fibrillation. *J Am Coll Cardiol* 2017;70:1173-82.
50. Marinescu M, Sun L, Fatar M, et al. Cerebral microbleeds in murine amyloid angiopathy: natural course and anticoagulant effects. *Stroke* 2017;48:2248-54.
51. Kadoglou NP, Moustardas P, Katsimpoulas M, et al. The beneficial effects of a direct thrombin inhibitor, dabigatran etexilate, on the development and stability of atherosclerotic lesions in apolipoprotein E-deficient mice: dabigatran etexilate and atherosclerosis. *Cardiovasc Drugs Ther* 2012;26:367-74.
52. Reilly PA, Lehr T, Haertter S, et al. The effect of dabigatran plasma concentrations and patient characteristics on the frequency of ischemic stroke and major bleeding in atrial fibrillation patients: the RE-LY trial (Randomized Evaluation of Long-Term Anticoagulation Therapy). *J Am Coll Cardiol* 2014;63:321-8.
53. Porchet R, Probst A, Bouras C, Draberova E, Draber P, Riederer BM. Analysis of glial acidic fibrillary protein in the human entorhinal cortex during aging and in Alzheimer's disease. *Proteomics* 2003;3:1476-85.

KEY WORDS animal models of human disease, cognitive impairment, neuroinflammation, oral anticoagulation, thrombin, thrombosis

APPENDIX For an expanded Methods section, please see the online version of this paper.