

DOI: 10.5281/zenodo.3404106
UDC: 616.314-089.23



Treatment of dental subtotal coronal lesion through atraumatic surgical extrusion

Adelina Tapes, MD, PhD Applicant

Arsenie Gutan Department of Oro-Maxilo-Facial Surgery and Oral Implantology
Nicolae Testemitanu State University of Medicine and Pharmacy, Chisinau, the Republic of Moldova

Corresponding author: adelinatapes@yahoo.com

Manuscript received July 12, 2019; revised manuscript August 29, 2019

Abstract

Background: Clinical short crowns or teeth with insufficient height of the supragingival part are a provocation for restorative dentistry. Restoring severely damaged teeth requires a comprehensive approach, a well-planned pretreatment. These teeth with subtotal coronary dental lesions can be treated conventionally by surgical resection of the gum and support bone or by the atraumatic surgical extrusion of the tooth as an alternative to avoid complications that may occur following removal of tissues. Now, the world's population lives longer. The hope of life according to WHO in 2016 was 72.0 years old. Respectively, the requirements of the people are higher in order to maintain oral health and effective treatment for the preservation of their own tissues. The atraumatic surgical extrusion of the tooth is a biological solution for the preservation of the tissues, but due to the recent implementation is not fully evaluated its effectiveness.

Conclusions: The Benex system can offer certain advantages to both the patient and the clinician, including the predictability of maintaining the stability and integrity of the dental alveole after the extrusion, due to the applied vertical force. Furthermore, the axial force for several minutes minimizes the oblique and lateral force that decreases compressive manipulations in the periodontal ligament and risk of resorption defects. However, the given technique can be resulted in unpredictable results, because it is an innovative technique and there is a small number of scientific studies on the subject.

Key words: dental extrusion, atraumatic surgical extrusion, Benex system, crown lengthening.

Introduction

Through different marketing methods population is conscious in the ability of the dentist to restore the aesthetics, less the functional part. However, the restoration of tissues with insufficient supragingival height should be enforced in compliance with biological principles. The direction must be dictated in dependence on the concrete clinical situation: apically or coronary. The compromise situation should combine concomitantly: the component of the 1:1-crown: root ratio after treatment and the component of the distance of at least 3 mm of supracrestal dental tissue between the bone and the edge of the future restoration according to the concept of "biological width" [1, 2]. This concept is supreme in understanding the apico-occlusion relationship between the edge of the restoration and the crest of the alveolar bone [1, 3, 4].

The "biological width" – is a combined dimension between the junction epithelium and connective tissue of the attachment, which represents the distance between the deepest point of the gingival attachment to the crest of the alveolar bone. Gargiulo A.W. et al. established the mathematical value of the components of this dimension such as: junction epithelium – 0.97 mm (0.71-1.35) and connective tissue of attachment to the alveolar ridge – 1.07 mm (1.06-1.08) [5]. This dimension has about 2.04 mm. There are two aspects of the crown lengthening (CL): functional and aesthetic one. In both cases surgical intervention comes to reposition the biological width apically by discovering the dental structure [6]. Therefore, in order to have a lasting restoration it is necessary to respect the space of 3 mm be-

tween the bone and the edge of the prosthetic construction, which will allow the reformation of the biological width and the sulcular depth [3, 4, 7-9].

Several studies showed that the biological width after CL intervention is restored between 6 months to 3 years. That's why it needs to be considered the periodontal status of the patient and the habits of the oral cavity hygiene. Additionally a correct diagnosis and interdisciplinary tactics will improve the achievement of predictable conservative results in the frontal aesthetic area [10].

The common causes of the short clinical crown are: deep dental caries extended to the alveolar bone, erosion, dental malformations, tooth fracture, attrition, excessive decrease of the tooth, so the tooth losing retentiveness for a subsequent restorative treatment. The fundamental purpose of the CL is to provide a retentive coronary dimension, clinically appropriate for the stable dento-gingival complex opposite the placement of the restoration edge, and an optimal aesthetic result [10].

However, there are clinical situations, which require a decision to be taken to restore or draw short clinical crowns such as: the root caries not located in cervical part of the root, the place of the perforation incompatible with a subsequent treatment. If the fracture extends to the root the clinician must appreciate the forecasts, accessibility, periodontal biotype, gum thickness and aesthetic appearance before proceeding to the procedure directly. If the fracture compromises the furcation then the radicular resection or extraction is indicated. If the fracture has a favorable localization in the coronary third of the root then the apical flap

operation is indicated with bone resection for exposing the fracture and recreating biological widths or dental extrusion. If the tooth that requires CL has periodontal bags must be appreciated the height of the outstanding support bone, the strategic value, and forecasts. Initial therapy is directed towards decreasing inflammation and stimulating a better homeostasis. Muco-gingival bone surgery can be performed for the elimination of periodontal bags and the concomitant CL. It is essential to apply specific criteria to decide the treatment of election for each individual case. However, the method of atraumatic surgical extrusion (ASE) has the advantages of minimizing the loss of dental tissue and increasing its longevity with minimal cost and in an operative time, without compromising the tooth involved [11].

Advantages and disadvantages of different methods of CL and dental extrusion

There are different methods of treatment for dental subtotal coronal lesion.

To the apical direction. 1. Gingivectomy; 2. Electrosurgery or laser surgery (a method that reduces excess tissue with good bleeding control, but contact with the bone should be avoided here because there is a danger of necrosis); 3. Technique by apical positioned flap with or without bone resection for exposure of a minimum of 3 mm of root (if the bone level is normal).

To the coronary direction: 1. Orthodontic extrusion; 2. ASE with the periostomes or Benex system (BS).

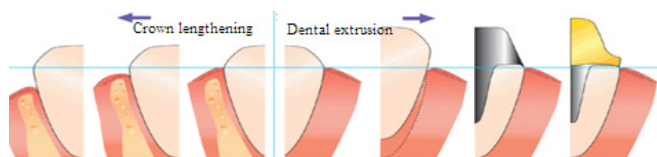


Fig. 1. Methods of treatment for dental subtotal coronal lesion [5].

Each technique has advantages and disadvantages. The method of gingivectomy requires a sufficient amount of keratinized tissue. A great disadvantage of gingivectomy is that in the frontal area it is contraindicated for aesthetic considerations, as well as the technique with the apical positioned flap. However, according to the American Academy of Periodontics 2003 CL – with/or without apically positioned flap is the most common and frequent surgical intervention [5]. A thick biotype of gum manifested by a dense area of keratinized tissue, which ensures a denser flap, makes the intervention more predictable and with a higher success rate compared to the fine biotype [10]. According to the study, apically positioned flap with osteoectomy is more effective than gingivectomy. The procedure for bone resection used in periodontological therapy has been shown to be more effective in stabilizing periodontal destruction [11]. The risks and complications that may occur in the frontal area following the gingivectomy procedure or apically positioned flap are [1, 12-14]:

1. Loss of interproximal papilla.

2. Overweighing.

3. Suprarecesia – what will require correction for root cover again.

4. Repeated increase of gum with the need for retreatment.

This is why it is necessary to include in the treatment protocol the warning of the patient with the risks and post-operative complications that can occur both immediately and tardive.

For CL in the front maxillary area it is important to study the position of the lip line and the exposure of teeth and gums, the relationship between the smile line and the position of the incisal line of the upper frontal teeth by aesthetic point of view. It is useful to examine the symmetry of the right and left side in relation to the median line. In CL through bone resection the existing gum morphology should be analyzed because the gum tends to return to its original position [4, 15].

The increase of the clinical crown to the coronary direction can be performed by orthodontic extrusion, atraumatic surgical extrusion (ASE) with the help of periostomes or Benex system (BS). Orthodontic extrusion can be achieved by traction using fixed, movable or temporary anchoring devices. This method is limited by accepting the patient, the duration of treatment, the risk of returning the tooth to its original position and it is a costly method with unfavorable aesthetics [16, 17]. Repeated rupture of fibers, the retention phase required after extrusion and the tendency to turn back are the main disadvantages for orthodontic extrusion [18]. In cases of deep subgingival cavity, subgingival fracture and when bone surgical resection is contraindicated, it is proposed the ASE with the periostomes or BS with predictable aesthetic and functional results. These techniques are an alternative approach compared to orthodontic extrusion or resection of tissues. The alternative approach through the extrusion results in a lower coronary height of the final restoration compared to the resective therapy, respectively, and the crown-root rate will be more favorable following extrusion than by the technique of resection of tissue [18, 19].

Surgical extrusion by such approach avoids undesirable consequences such as loss of interdental papilla, appearance of aesthetic or functional deformations, repeated return and rupture of periodontal fibers, etc. [1]. For the first time the tooth's luxation was made by Khanberg. He introduced the fine and gentle luxation of the tooth to the desired position. The Khanberg technique is the same like ASE – to bring the root in the desired position without osteoectomy or bone augmentation, the only difference is the utility of the modern atraumatic instruments and systems. This technique reduces the risk of dehydration of the periodontal ligament. The advantages of ASE are: 1. Reducing the time of the entire treatment compared to orthodontic extrusion; 2. Alternative conservative approach to bone architecture compared to bone resection [1, 20].

The ASE with the use of periostomes can also cause the crestale defects, fracture and deformation of the dento-alveolar complex. However, in comparison with periostal

elevators, periostomes allow minimal bone trauma, as they are placed in the periodontal trench and the Sharpey fibers are separated due to a fine blade. The periostomes provides a non-flap extrusion, decreasing discomfort and post-operative pain. The disadvantage of this technique is that it requires the possession of the polished and experienced manual practices for the success of the intervention [1].

The ASE of the tooth through the BS (Helmut Zepf Medizintechnik, GmbH, Hager & Meisinger GmbH) is considered analogically with the extrusive luxation after dental trauma. The incidence of root resorption in such a situation is 15%. According to other studies, the non-progressive resorption of the root meets at a frequency of 30% [18]. Tooth loss can occur in 5% cases, poor tooth mobility in 4.6%, marginal bone loss in 3.7% and progressive root resorption in 3.3% [21]. During extrusion, the fibers in gingival and periodontal tissues are elongated by stretching and new bone is formed in the direction of movement [22].

The indications of dental extrusion are [1, 11, 23, 24]:

- Rehabilitation of compromised teeth by extensive subgingival caries.
- Fracture of the root or endodontic perforation situated in cervical part of it.
- Severe parafunctional habits with massive coronary destructions.

Contraindications of dental extrusion are [16, 18]:

- Insufficient length of the root.
- Insufficient periodontal attachment.
- Fracture of the root or endodontic perforation not situated in cervical part of it.
- High-risk roots fracture (slim roots).
- Teeth with modest endodontic prognosis.
- Teeth with multiple roots and divergent roots.

Although the BS was originally designed for the atraumatic extraction of the tooth, the clinicians expanded its horizons. This system consists of a screwdriver (which is threaded in the root after geometric widening and the creation of the pilot hole) – the connecting part between the tooth and the wheel pulley. In this way, the root being fixed with this device is towed dosed in millimeters, with balanced manipulations being quite easily routed.



Fig. 2. The Benex system [25].

The creation of the pilot hole and the sealing of the screwdriver must be carried out quite mildly so as not to fracture the walls of the root. The traction itself lasts a few minutes [18].

ASE minimizes the deterioration of the root surface, the disruption of the root ligament and the deformation of the bone apophyseal that makes the changes that can occur more predictable.

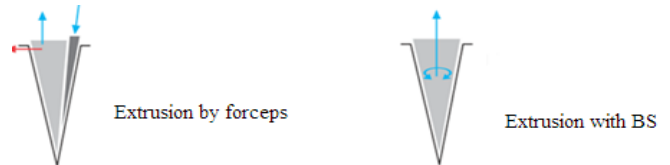


Fig. 3. The traction forces used in dental extrusion [25].

The vertical axial traction force used produces the minimal loss of cementoblasts on the radicular surface compared to the traction using pliers. The rupture leads to the formation of an apical clot at the apex of the root, which subsequently reshape and turn into oscillating bone [18, 26]. It is not fully explained the period of rapid remodeling of the periodontal support ligaments after the extrusion, but the bibliographical analysis confirms the use of ASE in the subtotal dental coronal lesion [16, 18].

CL and dental extrusion are intended for the extension of supragingival dental tissue for restorative or aesthetic purposes. The necessity is dictated by the dental factor or the patient's wish. The clinician will have to choose the treatment of election taking into account the aesthetic, functional and biological aspects of each patient [27].

The anatomical aspects that must be taken into account when deciding CL or dental extrusion are: the anatomy of the root (length and shape), the position of the furcation, the conicity of the root, the smile line, the height of the interdental bone, the anatomy of the hard and soft tissues, insertion of muscles, the width of the gingival tissue attachment. CL depends essentially on the edge of the gum attachment and the thickness of the alveolar ridge. The option of the apical or coronary extension in the CL or dental extrusion will be decided according to the following algorithm [5]:

1. The importance of tooth in the dental arch.
2. The level of the subgingival tooth decay and the degree of apical fracture extension.
3. If the crown/root ratio may be unfavourable after the treatment performed.
4. The length and the morphology of the root.
5. Theoretically the height of the residual bone after CL.
6. The degree of abscess tissue of the remaining support.
7. Possibility of discovering the furcation also with the unwanted discovery of the root that can complicate the final result for CL.
8. Increase of tooth mobility due to diminished support tissue and its effect on occlusion.
9. Possible posttreatment aesthetics and phonetics defects.

10. Possibility of maintaining the control of the plaque after the application of the final restoration.

Conclusions

The Benex system can offer certain advantages to both the patient and the clinician, including the predictability of maintaining the stability and integrity of the dental alveole after the extrusion, due to the applied vertical force. Furthermore, the axial force for several minutes minimizes the oblique and lateral force that decreases compressive manipulations to the periodontal ligament and risk of resorption defects. However, the given technique can be resulted in unpredictable results, because it is an innovative technique and there is a small number of scientific studies on the subject.

References

- Mohan KP, Ravindra RN, Roopa D, Kishore KK. Atraumatic surgical extrusion using periosteum in esthetic zone: a case series. *J Conserv Dent*. 2013;16(2):175-9.
- Harpenau L, Kao RT, Lundergan WP, Sanz M, Hall WB. Hall's critical decisions in periodontology and dental implantology. Shelton, Connecticut : People's Medical Publishing House-USA; 2013. p. 218-220.
- Dibart S. Improving patients' smiles: aesthetic crown-lengthening procedure. In: Dibart S, editor. *Practical periodontal plastic surgery* [Internet]. Ames, Iowa, USA: Blackwell Publishing Professional; 2017. p. 138-46 [cited 2019 May 12]. Available from: <http://doi.wiley.com/10.1002/9780470344637.ch15>.
- Fugazzotto PA. Periodontal-restorative interrelationships: ensuring clinical success. Chichester: Wiley-Blackwell; 2011. p. 31-85.
- Sato Naoshi. *Periodontal surgery: a clinical atlas*. Chicago: Quintessence; 2000. 447 p.
- Zanatta FB, Giacomelli BR, Dotto PP, Fontanella VRC, Rosing CK. Comparison of different methods involved in the planning of clinical crown lengthening surgery. *Braz Oral Res* [Internet]. 2010 Dec [cited 2019 May 12];24(4):443-8. Available from: http://www.scielo.br/scielo.php?script=sci_arttext&pid=S1806-83242010000400012&lng=en&tlng=en
- Nobre CM, de Barros Pascoal AL, Albuquerque Souza E, et al. A systematic review and meta-analysis on the effects of crown lengthening on adjacent and non-adjacent sites. *Clin Oral Investig* [Internet]. 2017 Jan [cited 2019 May 23];21(1):7-16. Available from: <https://www.researchgate.net/publication/306068274>
- de Oliveira PS, Chiarelli F, Rodrigues JA, Shibli JA, Zizzari VL, Piattelli A, et al. Aesthetic surgical crown lengthening procedure. *Case Rep Dent*. 2015;2015:437412.
- Terry DA, Geller W. *Esthetic and restorative dentistry : material selection and technique*. 3rd ed. Hanover Park: Quintessence Publishing Co; 2018. 776 p. Chapter 12. Periodontal plastic surgery.
- Patel A, Chapple I. Periodontal aspects of esthetic dentistry [Internet]. In: Wilson N, editor. *Principles and practice of esthetic dentistry*. Edinburgh: Elsevier; 2015. p. 137-163. (Essentials of esthetic dentistry; Vol. 1) [cited 2019 Jun 20]. Available from: <http://dx.doi.org/10.1016/B978-0-7234-5558-5.00006-3>
- Ganji KK, Patil VA, John J. A comparative evaluation for biologic width following surgical crown lengthening using gingivectomy and ostectomy procedure. *Int J Dent*. 2012;2012:479241.
- Lack JD. Aesthetic crown lengthening: a step by step surgical guide and biologic considerations. *Alpha Omegan*. 2009 Dec;102(4):133-41.
- Srivastava R, Verma PK, Chaturvedi TP, Srivastava A, Yadav P. Miracle of perio plastic surgery: Treatment for esthetic smile. *SRM J Res Dent Sci* 2013;4:125-8.
- Marzadori M, Stefanini M, Sangiorgi M, Mounssif I, Monaco C, Zucchelli G. Crown lengthening and restorative procedures in the esthetic zone. *Periodontol* 2000. 2018 Jun;77(1):84-92. doi: 10.1111/prd.12208.
- Silva CO, Soumaille JMS, Marson FC, Progiante PS, Tatakis DN. Aesthetic crown lengthening: periodontal and patient-centred outcomes. *J Clin Periodontol*. 2015;42(12):1126-34.
- Dietrich T, Krug R, Krastl G, Tomson PL. Restoring the unrestorable! Developing coronal tooth tissue with a minimally invasive surgical extrusion technique. *Br Dent J*. 2019 May 24;226(10):789-93. doi: 10.1038/s41415-019-0268-9.
- Artieda-Estanga A, Castelo-Baz P, Bello-Castro A, Ramos-Barbosa I, Martin-Biedma B, Blanco-Carrion J. Management of a crown-root fracture: A novel technique with interdisciplinary approach. *J Clin Exp Dent*. 2018 Jun 1;10(6):e620-e623. doi: 10.4317/jced.54811. PubMed PMID: 29930782; PubMed Central PMCID: PMC6005095.
- Kelly RD, Addison O, Tomson PL, Krastl G, Dietrich T. Atraumatic surgical extrusion to improve tooth restorability: a clinical report. *J Prosthet Dent*. 2016 Jun;115(6):649-53.
- Jorgensen MG, Nowzari H. Aesthetic crown lengthening. *Periodontol* 2000. 2001;27:45-58.
- Muska E, Walter C, Knight A, Taneja P, Bulsara Y, Hahn M, et al. Atraumatic vertical tooth extraction: a proof of principle clinical study of a novel system. *Oral Surg Oral Med Oral Pathol Oral Radiol*. 2013 Nov 1;116(5):e303-10. doi: 10.1016/j.oooo.2011.11.037.
- Elkhadem A, Mickan S, Richards D. Adverse events of surgical extrusion in treatment for crown-root and cervical root fractures: a systematic review of case series/reports. *Dent Traumatol*. 2014;30(1):1-14.
- Keceli HG, Guncu MB, Atalay Z, Evginer MS. Forced eruption and implant site development in the aesthetic zone: A case report. *Eur J Dent*. 2014 Apr;8(2):269-75. doi: 10.4103/1305-7456.130635. PubMed PMID: 24966782; PubMed Central PMCID: PMC4054062.
- Shobha KS, Mahantesha, Seshan H, Mani R, Kranti K. Clinical evaluation of the biological width following surgical crown-lengthening procedure: a prospective study. *J Indian Soc Periodontol*. 2010 Jul;14(3):160-7.
- Vaziri F, Haerian A, Lotfi Kamran MH, Abrishami M. Evaluation of the effect of surgical crown lengthening on periodontal parameters. *J Dent Mater Tech* [Internet]. 2015 Sep 1 [cited 2019 Jun 20];4(3):143-8. Available from: http://jdm.mums.ac.ir/article_4597.html
- Zepf Medizintechnik GmbH H. Extraction System [Internet]. Luzern; 2018. [cited 2019 Jun 20]. Available from: www.benex-dent.com
- Papadimitriou DE, Geminiani A, Zahavi T, Ercoli C. Sonosurgery for atraumatic tooth extraction: a clinical report. *J Prosthet Dent*. 2012 Dec 1;108(6):339-43. doi: 10.1016/S0022-3913(12)00169-2.
- Ho C. Clinical techniques: assessment and minimal intervention [Internet]. In: Wilson N, editor. *Principles and Practice of Esthetic Dentistry*. Edinburgh: Elsevier; 2015. p. 165-191. (Essentials of esthetic dentistry; Vol. 1) [cited 2019 Jun 20]. Available from: <http://dx.doi.org/10.1016/B978-0-7234-5558-5.00007-5>