

DOI: 10.5281/zenodo.3404088  
UDC: 617-089.5:612.13



## Effect of induction of general anesthesia with propofol and fentanyl on hemodynamic response

Iuliana Feghiu, MD, Assistant Professor

Valeriu Ghereg Department of Anesthesiology and Intensive Care No 1

Department of Pathophysiology and Clinical Pathophysiology

Nicolae Testemitsanu State University of Medicine and Pharmacy, Chisinau, the Republic of Moldova

Corresponding author: i.dimitriu@yahoo.com

Manuscript received July 01, 2019; revised manuscript August 23, 2019

### Abstract

**Background:** Induction of general anesthesia with propofol and fentanyl is frequently associated with changes in arterial blood pressure and heart rate. At present, there are no clinical studies investigating the relation between baseline cardiac autonomic tonus and cardiovascular instability after induction of general anesthesia with propofol and fentanyl.

**Material and methods:** A randomized prospective study was performed with approval of Ethic Committee. Written informed consent was obtained from all patients. We enrolled in the study 47 ASA physical status I-II patients scheduled for elective surgical procedures. Heart rate variability by Holter ECG, arterial blood pressure (systolic, diastolic, mean), and heart rate were measured at baseline, after premedication, as well as after induction of general anesthesia with propofol 2.5mg/kg and fentanyl 1.0 mkg/kg.

**Results:** our research revealed that increased baseline cardiac parasympathetic tonus was a risk factor for development of sinus bradycardia (OR = 21.0 (95%CI 3.9-112.8,  $p < 0.0002$ ) and sinus bradycardia associated with arterial hypotension (OR = 19.2 (95%CI 4.1-88.6,  $p < 0.0001$ ).

**Conclusions:** Induction of general anesthesia with propofol and fentanyl was associated frequently with arterial hypotension and sinus bradycardia. Increased cardiac parasympathetic tonus at rest represents a risk factor for development of arterial hypotension and sinus bradycardia after administration of propofol and fentanyl for induction of general anesthesia.

**Key words:** arterial hypotension, sinus bradycardia, cardiac autonomic tonus.

### Introduction

Propofol is a frequently used hypnotic for sedation as well as for induction of general anesthesia. But, when this drug is injected rapidly it can lead to hemodynamic instability, mainly to arterial hypotension and changes in heart rhythm. Both, sinus tachycardia and sinus bradycardia were reported after administration of propofol for sedation or for induction of general anesthesia [1-3]. Many mechanisms have been involved for explanation of propofol induced arterial hypotension, mainly direct depression of myocardium, reduced peripheral vascular resistance caused by direct vasodilatory effect of the drug, reduction of preload and afterload. The studies anyway, showed controversial results, and any of these factors could be imputed for hemodynamic instability after administration of propofol for sedation or for induction of general anesthesia [2-7]. Administration of propofol for moderate or deep sedation is frequently associated with a significant decrease in mean blood pressure. This hypotensive effect of the drug can be caused by reduction of sympathetic cardiac tonus or disturbances in baroreceptor-mediated cardiac activity [4-6]. Similar to other intravenous anesthetic agents like benzodiazepines and barbiturates, propofol exerts its hypnotic actions by activation of the central inhibitory neurotransmitter – gamma-aminobutyric acid (GABA) [7].

Most often propofol administration is combined with opioid (fentanyl or sufentanyl). This combination has a beneficial effect as can reduce the requirement in myorelaxants in the course of general anesthesia. But, on the other hand the combination between propofol and opioid can enhance the risk for arterial hypotension and bradycardia in patients [8,9]

Heart rate variability (HRV) is a noninvasive electrocardiographic marker which reflects the sympathetic and parasympathetic influences on sinus node of the heart. In other words, HRV analysis shows the baseline autonomic function of the heart. Measurements of HRV are noninvasive, and highly reproducible. They may be performed on the basis of 24 hour Holter recordings or on shorter periods ranging from 0.5 to 5 minutes particularly in the field of dynamic electrocardiography. Most studies in anesthesia and intensive care which used the HRV for analysis of changes in sympathetic-parasympathetic balance of the heart performed the 5 minutes analysis of HRV [10,11].

The purpose of this clinical research was to find a relationship between autonomic heart tonus at rest and the risk for development of arterial hypotension and changes in heart rate after induction of general anesthesia with propofol and fentanyl.

## Material and methods

We performed a prospective randomized study to evaluate the relationship between baseline cardiac autonomic tonus of the heart and the risk for development of cardiovascular instability after induction of general anesthesia with fentanyl and propofol. The study protocol was approved by the Ethic Committee of the State University of Medicine and Pharmacy "Nicolae Testemițanu", Chișinău (No.20, 2.02.2016).

Between March 2017 and September 2017, ASA physical status I-II patients aged less than 60 years (to exclude age-related changes of HRV) scheduled for elective surgeries with normal sinus rhythm on ECG were enrolled in the study. We obtained an informed consent from all research participants. Patients with diseases that could affect autonomic cardiac regulation (endocrine, neurological, cardiovascular diseases) were excluded from the study.

In the operating room, the patients were monitored (Holter ECG (Holter TLC 5000, USA)), non-invasive blood pressure, pulse oximetry and capnography). Baseline heart rate (HR), systolic blood pressure (SBP), diastolic blood pressure (DBP), and respiratory rate were recorded. During induction of general anesthesia, oxygen was delivered to maintain SpO<sub>2</sub> above 95%. All patients received 10 ml/kg of crystalloid before induction of anaesthesia.

HRV parameters, HR, SBP, DBP and respiratory rate were recorded at baseline (T1), 5 minutes after premedication with Fentanyl 1.0 mkg/kg (T2) and 5 minutes after induction of general anesthesia with propofol 2.5 mg/kg and fentanyl 1.0 mkg/kg (T3). If after receiving propofol and fentanyl, patients developed bradypnea or apnea, the mask ventilation was initiated at a rate of 14-16 breaths/min and tidal volume of 7-8 ml/kg, an important requirement for correct registration and analysis of HRV.

HRV parameters were analyzed by Holter computerized system. HRV was interpreted according to the recommendations of the *Task Force of the European Society of Cardiology and the North American Society of Pacing and Electrophysiology* [12]. In this clinical study HRV was used for assessment of autonomic heart tonus at rest.

Sinus tachycardia was considered in any patient who had a heart rate more than 100 beats/min, and sinus bradycardia – a heart rate less than 60 beats/min.

We considered systolic arterial hypertension when SBP was more than 140 mmHg or an increase in SBP of more than 20% from baseline values, systolic arterial hypotension – when SBP was less than 90 mmHg or a decrease in SBP more than 20% below baseline, and diastolic hypotension – when DBP was less than 60 mmHg or a decrease in DBP more than 20% below baseline.

Statistical analysis of the results was performed using GraphPad Prism 6 (GraphPad Software, San Diego, California, SUA). Values with parametric distribution were analyzed by t-pair and repeated measures ANOVA tests. Values with non-parametric distribution were analyzed by Wilcoxon and Friedman tests. The Fisher's exact test was used to compare categorical variables. Results are expressed as 95% confidence interval of odd ratio (parametric data) and median with interquartile range (IQR, non-parametric data). A p value of less than 0.05 was considered statistically significant.

## Results and discussion

The study group consisted of 47 patients (26 females and 21 males), aged 37.5±11.9 years. The mean body mass index was 24.6±3.4 kg/m<sup>2</sup> (it ranged between 16.1 and 30.0 kg/m<sup>2</sup>).

Holter heart rate variability analysis revealed that in baseline 38.3% of patients were with enhanced sympathetic tonus of the heart and 38.3% – with enhanced parasympathetic tonus of the heart. Another 23.4% of patients presented with heart eutonia (fig. 1).

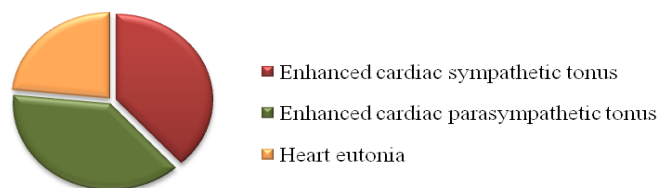


Fig. 1. Structure of the study group in function of vegetative tonus of the heart at rest.

There were no significant changes in SBP, DBP, MAP and HR after premedication with fentanyl (1.0 mkg/kg), but after induction of general anesthesia with propofol 2.5 mkg/kg and fentanyl 1.0 mkg/kg, SBP decreased by

Table 1

Changes in blood pressure and heart rate after premedication and induction of general anesthesia

Parameters	T1	T2	T3	p
SBP	138.9 (134.0-143.7)	133.9 (129.6-138.1)	99.7 (95.9-103.5)	0.001
DBP	85.4* (81.5-89.2)	79.0* (75.5-82.5)	51.1* (48.6-53.5)	0.001
MAP	103.1* (98.9-107.3)	97.7* (94.1-101.3)	67.9* (65.5-70.4)	0.001
HR	73.1 (69.9-76.4)	72.8 (69.4-76.1)	61.4 (59.1-63.6)	0.001

\*Blood pressure and HR values are represented as mean and 95%CI or as median and interquartile range for data with nonparametric distribution.

25.5% (from 133.9 mmHg at T2 to 99.7 mmHg at T3;  $p=0.001$ ), DBP – decreased by 35.5% (from 79.0 mmHg at T2 to 51.1 mmHg at T3;  $p<0.001$ ), MAP – decreased by 30.5% (from 97.7 mmHg at T2 to 67.9 mmHg at T3;  $p<0.001$ ), and HR – decreased by 15.7% (from 72.8 beats/min at T2 to 61.4 beats/min at T3;  $p<0.001$ ), (tab. 1).

After induction of general anesthesia with propofol and fentanyl most patients developed systolic-diastolic or diastolic hypotension (41 patients – 87.2%) and sinus bradycardia (24 patients – 51.1%) (fig. 2, fig. 4). More frequently there was attested diastolic hypotension (35 patients – 74.5%), only in 6 patients (12.8%) there was found systolic-diastolic hypotension. Minimal SBP was 69.0 mmHg, minimal DBP was 37.0 mmHg and minimal registered MAP was 49.0 mmHg. More frequently systolic-diastolic hypotension or diastolic hypotension was registered at 3-5 minutes ( $4.6\pm 0.3$  min) after administration of propofol and fentanyl. Arterial hypotension was corrected with fluids, and none of the patients required vasopressor support. In the study group only in 3 patients (6.4%) was found arterial hypertension. It is worth mentioning the fact that in all these patients arterial hypertension was present only the first 1-3 minutes ( $1.1\pm 0.6$  min) after administration of propofol and fentanyl. Maximal SBP was 169.0 mmHg, maximal DBP was 109.0 mmHg, and maximal registered MAP was 134.0 mmHg. All these 3 patients who developed arterial hypertension after induction of general anesthesia presented enhanced sympathetic tonus of the heart at rest.

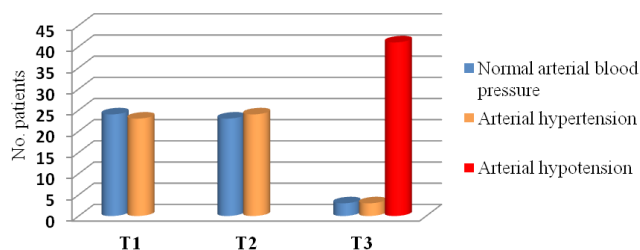


Fig. 2. The number of patients with normal BP, arterial hypertension and arterial hypotension at rest, after premedication and induction of general anesthesia.

It is important to remark the fact that out of 41 patients who developed arterial hypotension after induction of general anesthesia, in 18 patients (43.9%) was attested enhanced parasympathetic tonus of the heart at rest. Holter ECG analysis revealed that all 18 patients with enhanced cardiac parasympathetic tonus in baseline developed arterial hypotension after administration of propofol and fentanyl. Other 15 patients (36.6%) who developed arterial hypotension were with enhanced sympathetic tonus of the heart at rest, and 8 patients (19.5%) – with heart eutonia at rest.

Fisher's exact test of the relation between presence of enhanced parasympathetic tonus of the heart at rest and the risk for development of arterial hypotension after administration of propofol and fentanyl for induction of general anesthesia revealed: Odds ratio – 10.2 (95%CI 0.54-19.8)

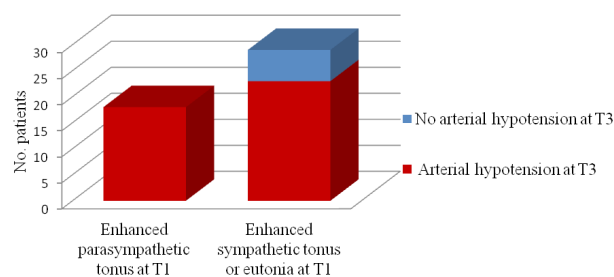


Fig. 3. Relation between autonomic cardiac tonus at rest and development of arterial hypotension after induction of general anesthesia with propofol and fentanyl.

( $p=0.06$ ), with sensitivity – 1.0 (95%CI 0.8-1.0), specificity – 0.2 (95%CI 0.08-0.39). Even if, OR and sensitivity are high, specificity is reduced, such enhanced parasympathetic tonus of the heart in baseline doesn't represent a risk factor for development of arterial hypotension after administration of propofol and fentanyl (fig. 3).

After administration of propofol and fentanyl for induction of general anesthesia there were found changes of HR on ECG. Most patients (51.1%) developed sinus bradycardia (fig. 4). Minimal HR registered by Holter ECG was 43/min. Minimal HR was registered at 3-5 minutes ( $4.1\pm 0.6$  min) after injection of propofol and fentanyl. Sinus tachycardia was registered in 3 patients (6.4%) from the study group. All these 3 patients presented enhanced sympathetic tonus of the heart at rest. Maximal HR registered by ECG Holter was 116/min, and was attested most frequently at

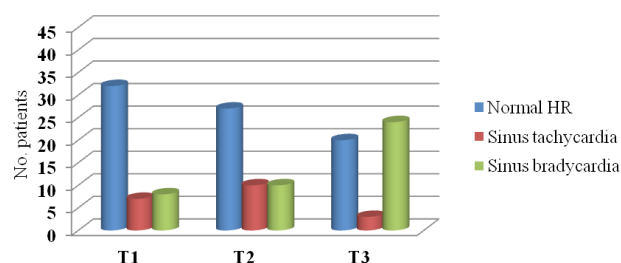
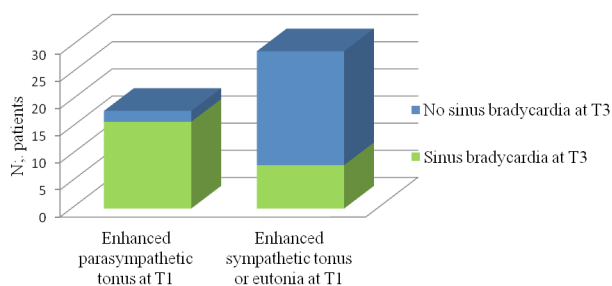


Fig. 4. The number of patients with normal HR, sinus tachycardia and sinus bradycardia at rest, after premedication and induction of general anesthesia.

It is worth mentioning that most patients (66.6%) who developed sinus bradycardia after administration of propofol and fentanyl had increased parasympathetic heart tonus at rest. Sixteen of the 18 patients with enhanced baseline parasympathetic tonus of the heart developed sinus bradycardia after administration of fentanyl and propofol. On the other hand, only 4 of the 18 patients with enhanced basal sympathetic cardiac tonus, and 4 of the 11 patients with heart eutonia at rest developed sinus bradycardia after induction of general anesthesia.

It can therefore be concluded that enhanced baseline parasympathetic tonus of the heart is a risk factor for development of sinus bradycardia after administration of propofol and fentanyl:

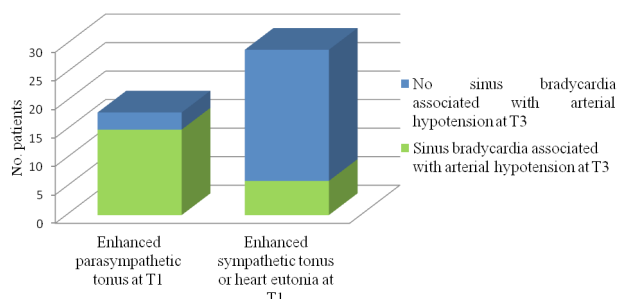


**Fig. 5. Relation between autonomic cardiac tonus at rest and development of sinus bradycardia after induction of general anesthesia.**

Odds Ratio – 21.0 (95%CI 3.9-112.8;  $p < 0.0002$ ); sensibility 0.89 (95%CI 0.65-0.99) and specificity 0.72 (95%CI 0.53-0.87) (fig. 5).

In 21 patients from the study group (44.7%) after injection of propofol and fentanyl was attested arterial hypotension associated with sinus bradycardia. It is important to mention the fact that Holter ECG analysis revealed that out of these 21 patients in 15 (71.4%) was attested enhanced parasympathetic cardiac tonus at rest. On the other hand, only 2 of the 18 patients with enhanced baseline sympathetic cardiac tonus, and 4 of the 11 patients with heart eutonia at rest developed sinus bradycardia associated with arterial hypotension after induction of general anesthesia.

Fisher's exact test of the relation between cardiac autonomic tonus at rest and the risk for development of arterial hypotension associated with sinus bradycardia revealed: Odds Ratio – 19.2 (95%CI 4.1–88.6;  $p < 0.0001$ ); sensitivity – 0.83 (95%CI 0.58-0.96) and specificity – 0.79 (95%CI 0.60-0.92) (fig. 6). It can therefore be concluded that enhanced parasympathetic tonus of the heart at rest is a risk factor for development of sinus bradycardia associated with arterial hypotension after administration of propofol and fentanyl for induction of general anesthesia.



**Fig. 6. Relation between autonomic cardiac tonus at rest and development of arterial hypotension associated with sinus bradycardia after induction of general anesthesia**

### Discussion

Propofol is an intravenous hypnotic agent, which commonly is used for anesthesia induction due to rapid onset, short duration of action, anti-nausea and vomiting effect and feeling comfortable after surgery. The most prominent effect of propofol is a decrease in arterial blood pres-

sure during induction of anesthesia and is associated with a decrease in cardiac output, stroke volume, and systemic vascular resistance. Furthermore, propofol induces severe vasodilation while the effects of myocardial depression are not exactly clear. Vasodilation occurs in both venous and arterial circulation, which leads to reduced preload and afterload [1, 5, 7, 13, 14].

Although there are many studies that evaluated the effect of propofol and fentanyl on cardiac autonomic nervous system using heart rate variability [2-6], the relation between cardiac autonomic tonus at rest and the risk for cardiovascular instability after induction of anesthesia with propofol and fentanyl have not been investigated before.

In the literature there are published several studies which compare the hemodynamic effects of propofol with other hypnotic drugs, most often from the group of barbiturates or benzodiazepines.

In a study by Frolich M.A. et al. which involved 60 healthy volunteers ASA I physical status, subjects received 4 dose level ranges of propofol to provide anxiolytic level to moderate sedative effect. Predicted propofol concentrations in this study were 0.1, 0.2, 0.4 and 0.8 mkg/kg. A significant dose dependent blood pressure reduction was in the propofol group compared to midazolam group. Significant decreases in blood pressure were at propofol concentration 0.4 and 0.8 mkg/kg [13].

In another prospective, double-blinded, randomized clinical study by Kilic E. et al., proved that combination of alfentanil (10.0 mkg/kg) with propofol 0.7 mg/kg for sedation in upper gastrointestinal system endoscopy in morbidly obese patient is more frequently combined with bradycardia and arterial hypotension than combination of propofol with ketamine [8]. Chidambaran V. et al. conducted a study to evaluate total intravenous anesthesia with propofol and fentanyl in obese children and adolescents (aged 9-18 years) during laparoscopic surgery. Propofol was administered at a standardized infusion rate of 1000  $\mu\text{g}/\text{kg}/\text{min}$  combined with fentanyl 50-100  $\mu\text{g}$ . In all patients were attested hemodynamic changes and drop in SBP, DBP and MAP was more than 20% from the baseline value [9].

In a recent study, aiming to compare the effect of the ketamine-propofol mixture (ketofol) and propofol on the insertion conditions of laryngeal mask airway and hemodynamic stability in pediatrics patient (age ranging from 2 to 15 years) physical status ASA I and II, and undergoing elective surgical procedures, Aberra B. et al., proved a significant decrease in blood pressure and heart rate in the group of patients who received propofol (3.5 mg/kg) compared with the group of patients who received a mixture of propofol and ketamine [14]. Soleimani A. et al. proved that induction of general anesthesia in patients with left ventricular dysfunction with diazepam is safer than induction with propofol in term of hemodynamics. In this study in the group of patients who received propofol (1.5 mg/kg) after premedication with fentanyl (2.0  $\mu\text{g}/\text{kg}$ ) the decrease in SBP, DBP and MAP was significantly greater than in the group of



patients who received midazolam or etomidate for induction of general anesthesia [15]. Another group of authors [16], compared the hemodynamic effects of propofol with the hemodynamic effects of etomidate when used for induction of general anesthesia in patients undergoing coronary artery bypass grafting /mitral valve and aortic valve replacement surgery. In this study all patients received fentanyl 2.0 mkg/kg 3 minutes prior to induction. The dose of propofol for induction of general anesthesia was 2.0 mg/kg. There was significant decrease in SBP, DBP and MAP between the groups after induction, after intubation and 5 min postintubation. There was significant decrease in cardiac output and cardiac index in propofol group when compared to baseline values after induction, after intubation and 5 minutes after intubation, but not in etomidate group.

There are several studies which compare the hemodynamic effects of propofol used for sedation in patients undergoing gastrointestinal endoscopy [17-19]. In a prospective, randomized, double-blind study by Usman S. et al. [17] was compared the hemodynamic effects of propofol (1.0 mg/kg propofol followed by repeated doses of 10 to 20 mg propofol intravenously) with that of midazolam associated with meperidine (0.4 mg/kg meperidine intravenously followed three minutes later by 0.05 mg/kg midazolam intravenously) in 100 patients scheduled for diagnostic upper gastrointestinal endoscopy. The authors observed significantly more adverse cardiopulmonary events with propofol compared to meperidine/midazolam (20% vs. 4%,  $p = 0.025$ ). Hypotension incidence was significantly higher in the propofol group compared to the meperidine/midazolam group (12% vs. 0%,  $p=0.027$ ). In this study, the authors found that midazolam/meperidine is superior to propofol with respect to the occurrence of adverse cardiopulmonary events, particularly hypotension. Tsai H. C. et al. performed a meta-analysis of randomized clinical trials aiming to compare the efficacy and safety of propofol and midazolam for sedation in cirrhotic patients undergoing endoscopy. Five studies between 2003 and 2012, including 433 patients, were included. In four of the selected randomized clinical trials arterial hypotension was more frequently in the patients who receive propofol than in patients who receive midazolam. In three of the selected studies was evaluated the incidence of bradycardia based on a heart rate (HR) < 55 beats per minute. The incidence of bradycardia was 6% (9/150) in the propofol group and 2.86% (4/140) in the midazolam group [18]. In another recent meta-analysis conducted to compare the efficacy and safety of midazolam and propofol in gastrointestinal endoscopy five randomized controlled trials involving 552 patients were included [19]. The conclusion of this meta-analysis was that propofol sedation for gastrointestinal endoscopy results in higher endoscopist satisfaction scores, but may increase the incidence of hypotension and bradycardia.

Another study examined the safety and effectiveness of the procedural sedation analgesia technique carried out in the emergency department. The research was done to com-

pare the effectiveness and efficacy of moderate sedation of fentanyl (0.1 mkg/kg) combined with propofol (1.0 mg/kg) or midazolam (1.0 mg/kg). None of the patients in either group developed any adverse events during and after the procedures. No significant drops in blood pressure and heart rate were observed during and after the procedures. Even though a few parameters, such as MAP, SBP and DBP, dropped intra-procedure, these values normalized post-procedure, and the changes were statistically insignificant within and between the groups [20].

Most studies which analyze the hemodynamic effects of propofol alone or propofol associated with opioid (as in this study) proved that a drop in SBP, DBP, MAP and HR can develop. These hemodynamic changes can be present even after administration of propofol and fentanyl in doses lower than in this study. However, there is not a single clinical research which studied the relation between baseline cardiac autonomic tonus of the heart and the risk for development of arterial hypotension and changes of heart rate after administration of propofol and fentanyl for induction of general anesthesia. This study revealed that enhanced baseline cardiac parasympathetic tonus represents a risk factor for development of sinus bradycardia and arterial hypotension associated with sinus bradycardia after administration of propofol and fentanyl for induction of general anesthesia.

## Conclusions

1. Induction of general anesthesia with propofol and fentanyl is frequently associated with arterial hypotension and sinus bradycardia.
2. Enhanced parasympathetic tonus of the heart at rest is a risk factor for development of sinus bradycardia and sinus bradycardia associated with arterial hypotension after injection of propofol and fentanyl.

## References

1. Rawal P, Bajracharya U. Hemodynamic response to sevoflurane and propofol induction: a comparative study. *J Soc Anaesthesiol Nepal*. 2015;2(1):2-7.
2. Mohit M, Radhakrishnan M, Umamaheswara R, Kavyashree KV. Assessment of heart rate variability during different propofol effect site concentrations in patients with supratentorial tumours: a pilot study. *J Neuroanaesthesiol Crit Care*. 2017;4:108-113.
3. Tarvainen MP, Georgiadis S, Lipponen JA, Laitio T, Karjalainen PA, Scheinin H, Kaskinoro K. Analysis of heart rate variability dynamics during propofol and dexmedetomidine anesthesia. In: 32nd Annual International Conference of the IEEE EMBS; 2010 Aug 31-Sept 4; Buenos Aires, Argentina, 2010. P. 1634-7.
4. Tsugayasu R, Handa T, Kaneko Y, Ichinohe T. Midazolam more effectively suppresses sympathetic activations and reduces stress feelings during mental arithmetic task than propofol. *J Oral Maxillofac Surg*. 2010;68:590-6.
5. Win NN, Fukayama H, Kohase H, Umino M. The different effects of intravenous propofol and midazolam sedation on hemodynamic and heart rate variability. *Anesth Analg*. 2005;101:97-102.
6. Hidaka S, Kawamoto M, Kurita S, Yuge O. Comparison of the effects of propofol and midazolam on the cardiovascular autonomic nervous

- system during combined spinal and epidural anesthesia. *J Clin Anesth.* 2005;17:36-43.
7. Sahinovic MM, Struys MM, Absalom AR. Clinical pharmacokinetics and pharmacodynamics of propofol. *Clin Pharmacokinet.* 2018;57(12):1539-1558.
  8. Kilic E, Demiriz B, Isikay N, Yildirim AE, Can S, Basmaci C. Alfentanil versus ketamine combined with propofol for sedation during upper gastrointestinal system endoscopy in morbidly obese patient. *Saudi Med J.* 2016;37:1191-1195.
  9. Chidambaran V, Sadhasivam S, Diepstraten J, Esslinger H, Cox S, Schnell BM, Samuels P, Inge T, Vinks AA, Knibbe CA. Evaluation of propofol anesthesia in morbidly obese children and adolescents. *BMC Anesthesiol.* 2013;13:8.
  10. Anderson T. Heart rate variability: implications for perioperative anesthesia care. *Curr Opin Anaesthesiol.* 2017;30(6):691-697.
  11. Pichot V, Roche F, Celle S, Barthélémy JC, Chouchou F. HRV analysis: a free software for analyzing cardiac autonomic activity. *Front Physiol.* 2016 Nov 22;7:557.
  12. Heart rate variability: standards of measurement, physiological interpretation and clinical use. Task Force of the European Society of Cardiology and the North American Society of Pacing and Electrophysiology. *Circulation.* 1996;93(5):1043-1065.
  13. Frölich MA, Arabshahib A, Katholi C, Prasain J, Barnes S. Hemodynamic characteristics of midazolam, propofol, and dexmedetomidine in healthy volunteers. *J Clin Anesth.* 2011;23(3):218-223.
  14. Aberra B, Aregawi A, Teklay G, Tasew H. Effect of ketofol versus propofol as an induction agent on ease of laryngeal mask airway insertion conditions and hemodynamic stability in pediatrics: an observational prospective cohort study. *BMC Anesthesiol.* 2019;19(1):41.
  15. Soleimani A, Heidari N, Habibi MR, Kiabi FH, Khademloo M, Emami Zeydi A, Sohrabi FB. Comparing hemodynamic responses to diazepam, propofol and etomidate during anesthesia induction in patients with left ventricular dysfunction undergoing coronary artery bypass graft surgery: a double-blind, randomized clinical trial. *Med Arch.* 2017 Jun;71(3):198-203.
  16. Kaushal RP, Vatal A, Pathak R. Effect of etomidate and propofol induction on hemodynamic and endocrine response in patients undergoing coronary artery bypass grafting/mitral valve and aortic valve replacement surgery on cardiopulmonary bypass. *Ann Card Anaesth.* 2015 Apr-Jun;18(2):172-178.
  17. Uzman S, Gurbulak B, Gurbulak EK, Donmez T, Hut A, Yildirim D. A comparison of propofol and midazolam/meperidine sedation in upper gastrointestinal endoscopy. *Wideochir Inne Tech Maloinwazyjne.* 2016;11(3):178-185.
  18. Tsai HC, Lin YC, Ko CL, Lou HY, Chen TL, Tam KW, Chen CY. Propofol versus midazolam for upper gastrointestinal endoscopy in cirrhotic patients: a meta-analysis of randomized controlled trials. *PLoS One.* 2015;10(2):e0117585.
  19. Zhang R, Lu Q, Wu Y. The comparison of midazolam and propofol in gastrointestinal endoscopy: a systematic review and meta-analysis. *Surg Laparosc Endosc Percutan Tech.* 2018;28(3):153-158.
  20. Rahman NH, Hashim A. Is it safe to use propofol in the emergency department? A randomized controlled trial to compare propofol and midazolam. *Int J Emerg Med.* 2010;3(2):105-113.

