



CODEN [USA]: IAJPB

ISSN: 2349-7750

**INDO AMERICAN JOURNAL OF  
PHARMACEUTICAL SCIENCES**Available online at: <http://www.iajps.com>

Research Article

**EIGHT-YEAR LONG-TERM SURVIVAL OF AN ADVANCED  
GASTRIC CANCER PATIENT TREATED BY  
MULTIDISCIPLINARY THERAPY INCLUDING REPEATED  
SURGERY AND METRONOMIC CHEMOTHERAPY****<sup>1</sup>Dr Tehmina Akbar, <sup>2</sup>Dr. Mehwish Jalil, <sup>3</sup>Dr Gul Zareen Khan Tareen**<sup>1</sup>Female Medical Officer, BHU Baral, Palandri, Sudhnoti, AJK, <sup>2</sup>Akhtar Saeed Medical and Dental College Lahore, <sup>3</sup>Women Medical Officer, Govt Said Mitha Teaching Hospital Lahore.**Article Received:** July 2019**Accepted:** August 2019**Published:** September 2019**Abstract:**

*This case was around a 69-year-old male. He had gastric malignancy with broad intra-abdominal lymph hub metastasis, got palliative distal gastrectomy. Although uncommon, some chosen patients with cutting edge gastric malignant growth get an opportunity of long haul survival, similar to the present case. The patient likewise experienced right femoral bone metastasis and IVC tumor thrombus 2.9 years and 6.6 years after the underlying medical procedure, which were treated by radiation treatment. He experienced rehashed resection of metachronous right and left adrenal metastatic sores 2 years and 5.3 years after the underlying activity, individually. The gradually dynamic tumor status was kept up by continuation of metronomic chemotherapy including S-1 as a key medication, and a sum of 8-year long haul survival was accomplished. The viability of multidisciplinary treatment for far cutting edge gastric malignancy patients, particularly a significant job of rehashed medical procedure and metronomic chemotherapy, was talked about in this investigation.*

**Keywords:** Repeated surgery; metronomic chemotherapy; distant metastasis; Long-term survival; Multidisciplinary therapy; advanced gastric cancer.

**Corresponding author:****Dr. Tehmina Akbar,**

Female Medical Officer, BHU Baral, Palandri, Sudhnoti, AJK.

QR code



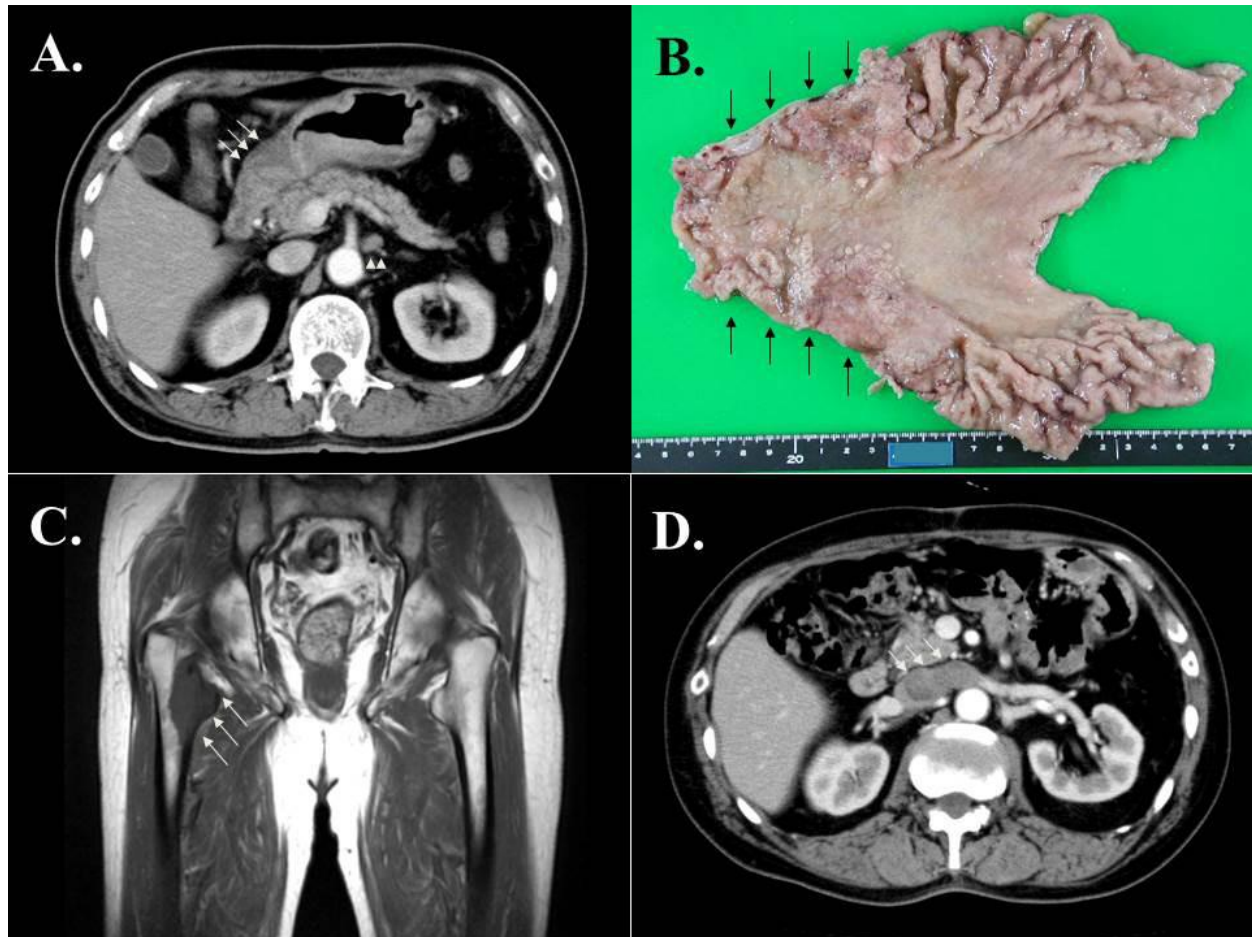
Please cite this article in press Tehmina Akbar et al., *Eight-Year Long-Term Survival of an Advanced Gastric Cancer Patient Treated by Multidisciplinary Therapy Including Repeated Surgery and Metronomic Chemotherapy.*, Indo Am. J. P. Sci, 2019; 06(09).

**INTRODUCTION:**

Gastric malignancy is the fourth most generally analyzed disease and the second most basic reason for malignant growth related passing around the world, and most patients present with cutting edge and additionally metastatic illnesses aside from in East Asia[1]. The impact of resecting metastatic tumors from gastric malignancy is constrained in light of the fact that metastasis from gastric disease is considered to present as different repeat or peritoneal dissemination[2]. In cutting edge or metastatic gastric disease patients with moderately lackluster showing status, the utilization of oral fluoropyrimidines as metronomic chemotherapy, for example, S-1, capecitabine or UFT, is by all accounts possibly beneficial[4]. Some chosen patients with cutting edge and metastatic gastric malignancy may get an opportunity of long haul survival because of late advances in multimodal treatment including medical procedure, radiation treatment and chemotherapy[3], in spite of the fact that a 8-year long-term survival instance of far cutting edge gastric disease, similar to the momentum case, is very uncommon. The metronomic chemotherapy, characterized as incessant or ceaseless organization of regular cytotoxic medication in nearly low dosages over broadened periods with no drawn out breaks, has the potential

advantage not just by accomplishing fundamentally decreased poisonous quality contrasted with most extreme endured chemotherapy, yet additionally by keeping stable tumor status by means of enhancement of the anti-angiogenic properties of cytotoxic drugs[4-6]. For our situation, support of regulated metronomic chemotherapy and the planning of rehashed medical procedure and radiation treatment were of fundamental significance to accomplish long-term survival with positive personal satisfaction. In the present case, metronomic chemotherapy utilizing S-1 as a key medication could offer a more than 5-year long haul survival, just as a positive personal satisfaction with no extreme side effects.

This case was around a 69-year-old male. He was admitted to a medical clinic for general disquietude. He experienced palliative distal gastrectomy to maintain a strategic distance from dynamic GI dying, and minuscule examination uncovered reasonably separated rounded adenocarcinoma penetrating the serosa with phenomenal lymphatic pervasions (Figure 1B), joined by broad local lymph hub association. He was determined to have progressed gastric malignancy with broad lymph hub metastasis by upper gastrointestinal fiberoptic and improved CT filter (Figure 1A).

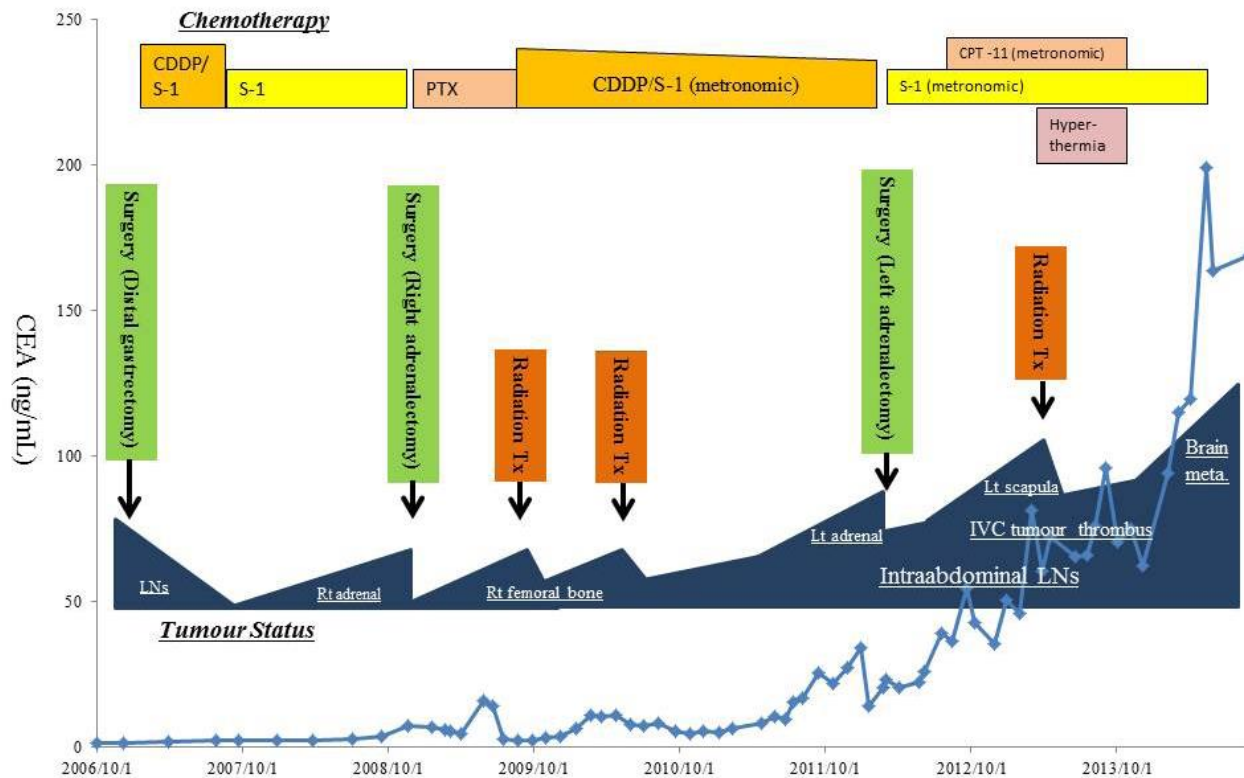


**Figure 1** (A) Enhanced CT scan of the abdomen revealed severely thick wall of the stomach (arrows) with extensive regional lymph node swelling (arrow heads). (B) Gross specimen of the resected distal stomach showed irregular wall thickness involving the antrum. (C) MR images 2.9 years after the initial operation showed right femoral bone metastasis (arrows), which was treated by radiation therapy. (D) Enhanced CT scan 6.6 years after the initial operation revealed tumour thrombus in the inferior vena cava and left renal vein (arrows).

The steady tumor status was kept up by oral S-1 organization, although singular right adrenal metastasis was distinguished and precisely resected 2 years after the underlying task. He took three courses of cisplatin/S-1 (CS) blend chemotherapy and complete reaction was accomplished. Postoperative course was uneventful, and the patient recuperated with no complexities. Postoperative chemotherapy utilizing paclitaxel was presented and well-endured for 9 months until fringe neuropathy created. Consequently, the privilege femoral bone metastasis was created 2.9 years after the underlying activity (Figure 1C), which was treated by rehashed radiation treatment and CS chemotherapy. The illness status was gradually dynamic, however, stable with no side effect, when the left scapula metastasis and IVC tumor thrombus were evident 6.6 years after the underlying task (Figure 1D). The steady tumor status was kept from that point by continuation of 80%

portion of CS chemotherapy, however, the left adrenal metastasis was created 5.3 years after the underlying activity, and again carefully resected. Both metastatic sores were treated by radiation treatment joined with hyperthermia, and incomplete reaction was accomplished. Gradually dynamic tumor status was kept up for extra one year by continuation of metronomic S-1/irinotecan chemotherapy. The infection status was gradually dynamic, however, stable with no side effect, when the left scapula metastasis and IVC tumor thrombus were evident 6.6 years after the underlying task (Figure 1D). The patient's presentation status was decayed because of pneumonia and sepsis 7.2 years after the underlying activity, and just metronomic S-1 monotherapy was proceeded from that point. At long last, mind metastasis and recalcitrant pleural empyema created 7.6 years after the underlying activity, bringing about end of chemotherapy, and the

patient lapsed 8 years after the underlying task (Figure 2).



**Figure 2** The whole clinical course of the current patient with serial changes in serum CEA values. Abbreviations: CDDP: cisplatin; PTX: paclitaxel; CPT-11: irinotecan; Tx: therapy; LNs: lymph nodes; Rt: right; Lt: left; IVC: inferior vena cava; meta.: metastasis.

The viability of multidisciplinary treatment for far cutting edge gastric malignancy patients, particularly a significant job of rehashed medical procedure and metronomic chemotherapy, was talked about in this investigation.

#### REFERENCES:

1. Kamangar F, Dores GM, Anderson WF. Patterns of cancer incidence, mortality, and prevalence across five continents: defining priorities to reduce cancer disparities in different geographic regions of the world. *J Clin Oncol* 2006; **24**: 2137-50. [PMID: 16682732]; [DOI: 10.1200/JCO.2005.05.2308]
2. Ishii T, Ikegami N, Hosoda Y, Koide O, Kaneko M. The biological behaviour of gastric cancer. *J Pathol* 1981; **134**: 97-115. [PMID: 6265613]; [DOI: 10.1002/path.1711340202]
3. Kong F, Qi Y, Liu H, Gao F, Yang P, Li Y, Jia Y. Surgery combined with chemotherapy for recurrent gastric cancer achieves better long-term prognosis. *Clin Transl Oncol* 2015; [Epub ahead of print]. [PMID: 26088414]; [DOI: 10.1007/s12094-015-1327-6]
4. Emmenegger U, Kerbel RS. Five years of clinical experience with metronomic chemotherapy: achievements and perspectives. *Onkologie* 2007; **30**: 606-8. [PMID: 26088414]; [DOI: 10.1007/s12094-015-1327-6]
5. Kerbel RS, Kamen BA. The anti-angiogenic basis of metronomic chemotherapy. *Nat Rev Cancer* 2004; **4**: 423-36. [PMID: 15170445]; [DOI: 10.1038/nrc1369]
6. Klement G, Baruchel S, Rak J, Man S, Clark K, Hicklin DJ, Bohlen P, Kerbel RS. Continuous low-dose therapy with vinblastine and VEGF receptor-2 antibody induces sustained tumour regression without overt toxicity. *J Clin Invest* 2000; **105**: R15-24. [PMID: 10772661]; [PMCID: PMC517491]; [DOI: 10.1172/JCI8829]