



ISSN NO. 2320-5407

Journal Homepage: - www.journalijar.com

INTERNATIONAL JOURNAL OF ADVANCED RESEARCH (IJAR)

Article DOI: 10.21474/IJAR01/9281
DOI URL: <http://dx.doi.org/10.21474/IJAR01/9281>



INTERNATIONAL JOURNAL OF
ADVANCED RESEARCH (IJAR)
ISSN 2320-5407
Journal Homepage: <http://www.journalijar.com>
Journal DOI: 10.21474/IJAR01

RESEARCH ARTICLE

DOG BITE INJURIES IN MAXILLOFACIAL TRAUMA: A CASE REPORT.

Dr. Nitesh Mishra¹, Dr. Akhilesh kumar singh², Dr. Aditi Priya³ and Dr. Janani T⁴.

1. BDS, MDS, Department of oral maxillofacial surgery, Faculty of Dental Sciences, Institute of Medical Sciences, Banaras Hindu University.
2. BDS, MDS, Assistant professor, Department of oral maxillofacial surgery, Faculty of Dental Sciences, Institute of Medical Sciences, Banaras Hindu University.
3. BDS, MDS, Department of Prosthodontics, Faculty of Dental Sciences, Institute of Medical Sciences, Banaras Hindu University.
4. MDS, Department of oral maxillofacial surgery, Faculty of Dental Sciences, Institute of Medical Sciences, Banaras Hindu University.

Manuscript Info

Manuscript History

Received: 12 April 2019
Final Accepted: 14 May 2019
Published: June 2019

Key words:-

Dog bite injuries; Maxillofacial trauma.

Abstract

Position of face in head and neck region make it more exposed as comparison to other region to dog bite injuries. Combination of this fact along with short stature of children make them more prone to dog bite. The surgical approach regarding dog bite injury continues to be debatable. Main controversial topic of discussion in animal bite cases is the ideal time for wound debridement along with initial wound suturing as well as the use of prophylactic antibiotics. Early management, most appropriate prophylaxis in addition to precise evaluation are definitely critical for attaining desired results. This case report is to throw a light on epidemiology, presentation, management and recent advances in case of emergency like animal bite.

Copy Right, IJAR, 2019,. All rights reserved.

Introduction:-

In present scenario dog bite or we can say animal bite is a matter of concern as it pose a serious physical, functional and psychological trauma to wide majority of population especially children as it not only transmits disease but also increase treatment costs. The most common location of dogbite is face in children[1] and it is often seen that most of dogs are familiar with the child[2]. While in children most affected area is head region, adults are commonly affected in body[3,4]. Age is the major factor in determining location of injury. In younger children , most affected areas are the head, face and neck. As the child grows, bites to extremities are common. More than 1000 species of pathogenic bacteria are present in the oral cavity of dog and treatment is difficult because of risk of infection especially in extensive injuries. About 3-20% dog bite wounds develop infections[5]. The treatment of injuries caused by dog bites is done by cleaning, debridement and primary closure of the lesion, anti-rabies and tetanus control and antibiotic prophylaxis.

Classification Of Dog Bite Victims

GROUP 1 -Victim presents within 8–12 h of the incident with fears of contracting rabies or other infections and/or with concerns of permanent disfiguration of the injured body part. These wounds are often contaminated with bacteria but do not show evidence of infection[6]

Corresponding Author:-Nitesh Mishra.

Address:-BDS, MDS, Department of oral maxillofacial surgery, Faculty of Dental Sciences, Institute of Medical Sciences. Banaras Hindu University.

GROUP 2- Victim presents more than 12 h after the incident, most often presenting with signs and symptoms of developing infections[6]

Case Report:-

A 5yr child, victim of dog bite was admitted to trauma center of our institute on an urgent basis. The child has multiple extensive laceration over face involving right infraorbital region, nose and left cheek with some amount of tissue loss at infraorbital region. (Fig .1)

Informed consent was taken from the parents. The surgical procedure was performed under general anaesthesia and oral intubation had been done. Local infiltration given with 2% lignocaine with adrenaline, cleaning of surgical area and irrigation with 0.9% normal saline solution was done, necrosed tissue carefully debrided and rabies immunoglobulin infiltrated around wound and remaining is given IM at an anatomic site distant from vaccination. Wound edges were stabilized and primary closure performed in layers with 4-0 vicryl and then skin closure with 5-0 prolene (fig.2,3), followed by pressure dressing.

Post-operatively patient was medicated with antirabies, analgesic and antibiotics and patient was discharged on the 4th post-operative day and patient came for followup on 1st week (fig.4) and 3rd week (fig.5) after discharge, healing was satisfactory and no any local or systemic complications seen.

Discussion:-

Animal bite such as by dog poses a significant public health risk because it can cause infections, functional, aesthetic problems and may some times leads to widespread morbidity especially when affecting head and neck region.[1] Children being most affected with dog bite as they lack awareness of danger. This might be the most appropriate theory why children are more vulnerable for animal attack. Since height children are less, head and neck region being most commonly affected.

Dog bite injuries are mostly superficial abrasions and lacerations[7]. The typical dog bite results in a combination of torn tissues and adjacent punctures, and they are called "hole-and-tear" effect[8]. The force delivered by dog jaws while biting can be as high as 200-450 psi and result in devitalisation of the wound tissue with associated ripping and tearing motion[9,10] and it can lead to severe deep laceration and may include facial bone and cranial fractures. In some cases dog bite injuries may lead to amputations, including severe vascular and nerve or bony destruction. The nose, lips and cheeks are most commonly affected and known as 'central target area'[4].

Amoxicillin-clavulanate for 3 to 5 days is the first-line antimicrobial prophylaxis for high-risk dog wounds in healthy patients[11]. Alternatively, ampicillin-sulbactam might be given intravenously if the patient is unable to take oral antibiotics. If the patient is allergic to penicillin, first-line treatment is an extended-spectrum cephalosporin or trimethoprim-sulfamethoxazole plus clindamycin[11]. The duration of prophylaxis should be 3-5 days while infected wounds need to be covered with 7-14 days of antibiotic cover[11]. Debridement should be adequate so as to reduce risk of infection in dog bite cases so as eliminate crushed or devitalized tissue which would may serve as source of infection. Thorough irrigation is necessary to remove all particulate matter. Povidone iodine and ethanol mixture diluted with saline serve as a good irrigant[12,13].

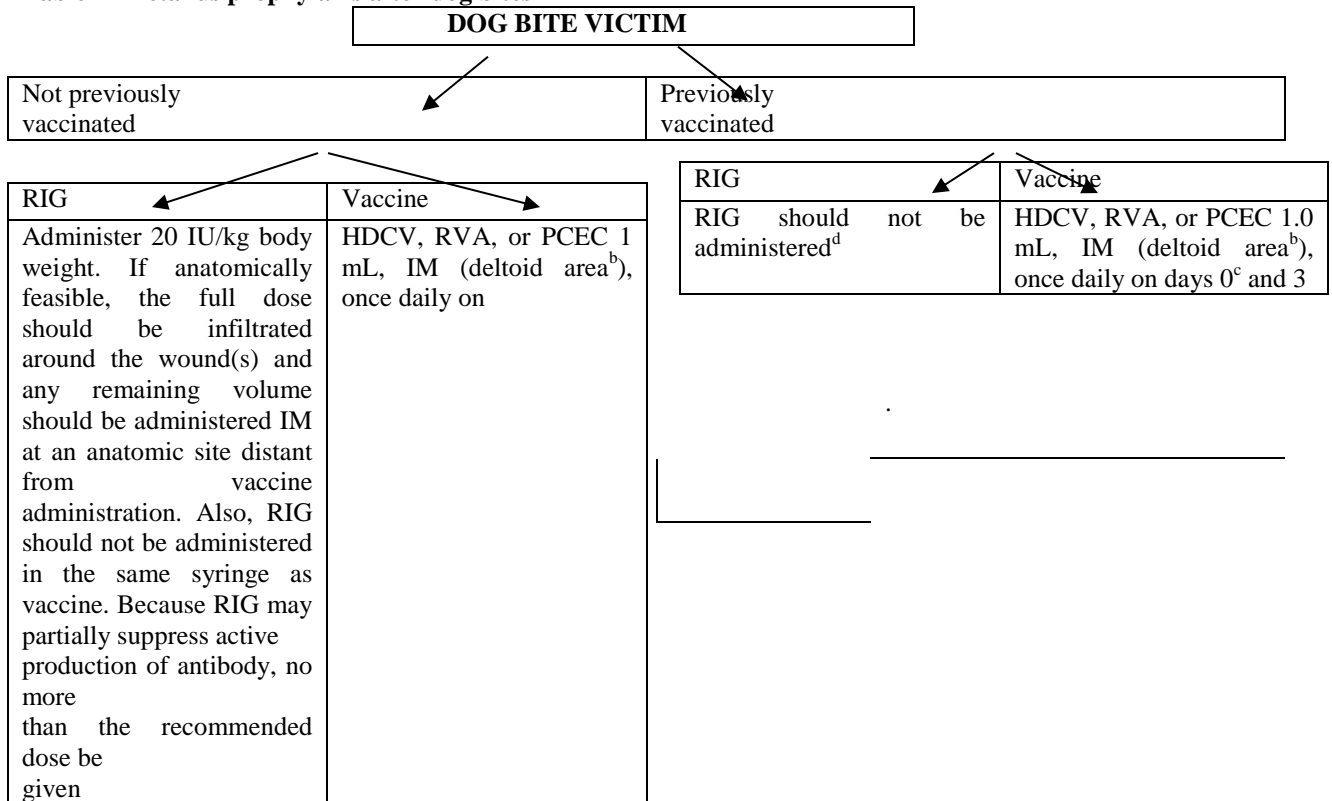
Un-infected wound less than 24hr old can be primarily repaired[14,15]. Success rate of facial wounds closure is high owing to its high vascularity and absence of dependent edema. Subcutaneous sutures should be kept to a minimum as they can precipitate infection. Avulsive injuries which have significant tissue loss where primary repair can't be done can be managed with local or regional flaps, skin grafts or microvascular reconstruction[16]. Tetanus immunization status must be evaluated and treated with immunization or immunoglobulin administration was indicated[17]. [table 2]

Table 1:- WHO 10 general considerations in rabies post exposure prophylaxis

1. wound must be immediately washed for 15 minutes and disinfected.
2. rabies PEP should be instituted immediately. PEP consists of a course of potent, effective rabies vaccine that meets WHO recommendations and administration of rabies immunoglobulin
3. PEP must be applied using vaccine regimens and administration routes that have been proven to be safe and effective.

4.Pregnancy and infancy are not contraindications to PEP.
5.if rabies vaccine is not available on first visit,it can be delayed up to 7days from the date of first vaccine dose.
6.initiation of PEP should not await the results of laboratory diagnosis or be delayed bydog observation when rabies is suspected
7.when suspect rabid animal contacts occur in areas free of carnivore-mediated rabiesand where there isadequate surveillance in place,PEP may not be required
8Patients presenting for rabies PEP even monthsafter having bittwenshould be treated asif the contact has recently occurred
9.PEP could be administered even if the suspect animal is not available for ttesting or observation
10.In areas enzootic for rabies,PEP should be instituted immediately unless adequate laboratory surveillance and dataindicates that the species involved is not a vector of rabies.

Table -2 Tetanus prophylaxis after dog bites



RIG rabies immune globulin; IU immunizing unit; IM intramuscularly;HDCV human diploid cell vaccine; RVA rabies vaccine adsorbed; PCEC purified chick embryo cell vaccine .

1. These regimens apply to all age groups including children.
2. The deltoid area is the only acceptable site of vaccination for adults and older children. For younger children, the outer aspect of the thigh may be used. Vaccine should never be administered in the gluteal area.
3. Day 0 is the day the first dose of vaccine is administered .
4. Any person with a history of pre-exposure vaccination with HDCV, RVA, or PCEC prior post-exposure prophylaxis with HDCV, RVA or PCEC, or previous vaccination with any other type of rabies vaccine and a documented history of antibody response to the prior vaccination.

Conclusion:-

Dog bites are quite common injuries that preferably affect children, and the head and neck region is the most affected region. Trauma can leave aesthetic and psychological sequelae to victims, so the treatment must involve a multidisciplinary team in order to minimize the damages caused. Immediate surgical intervention provides a better aesthetic result and antibiotic prophylaxis reduces or prevents the risk of infection. .

Conflict Of Interest
None

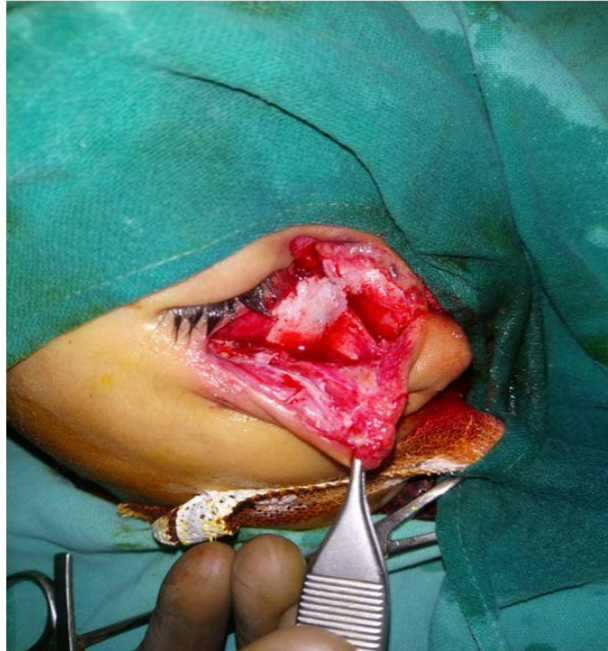

Fig 1:-Lacerated wound

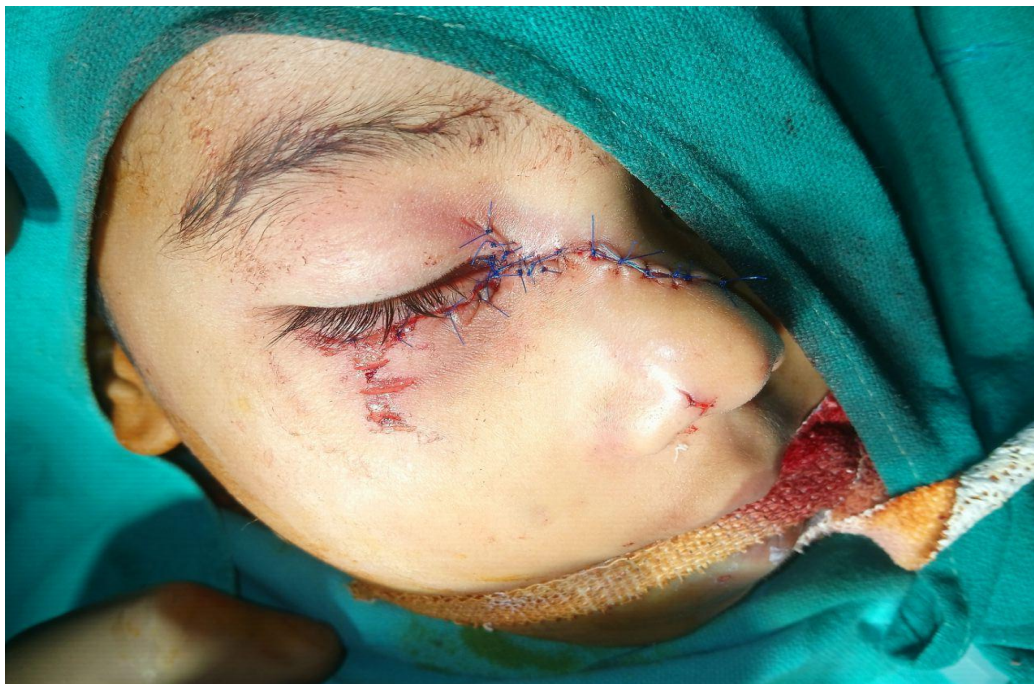

Fig 2:- Primary closure

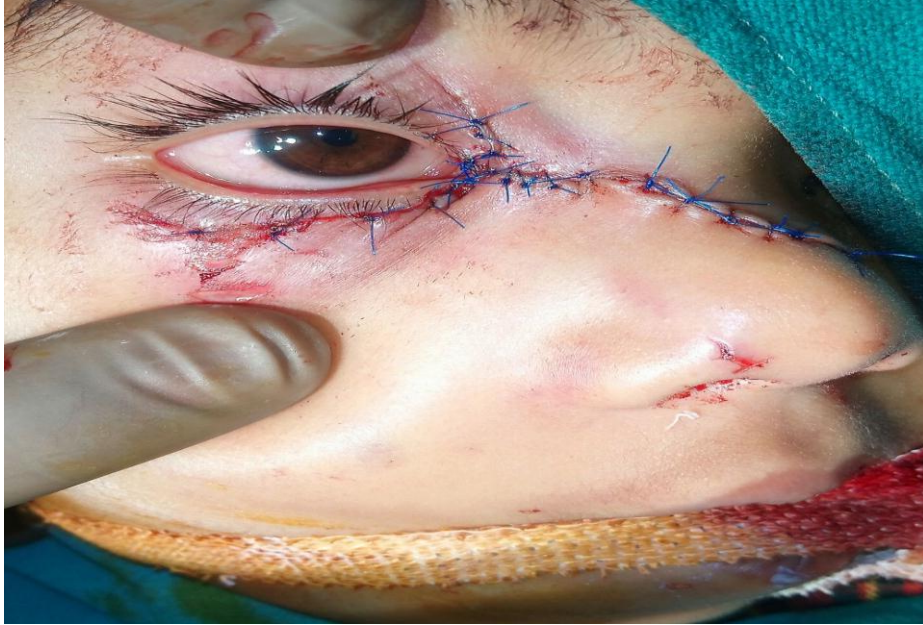

Fig 3:- Primary closure obtained

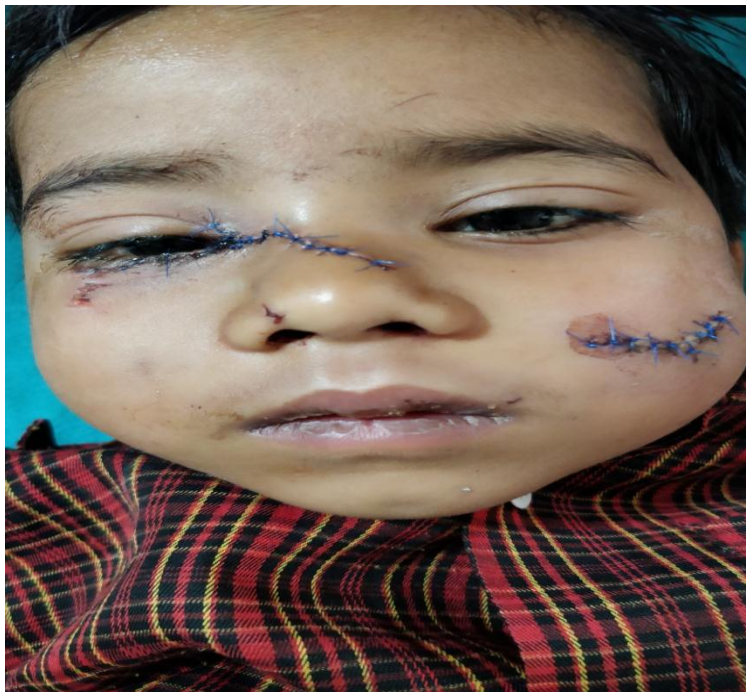

Fig 4:- Follow-up after 1 week

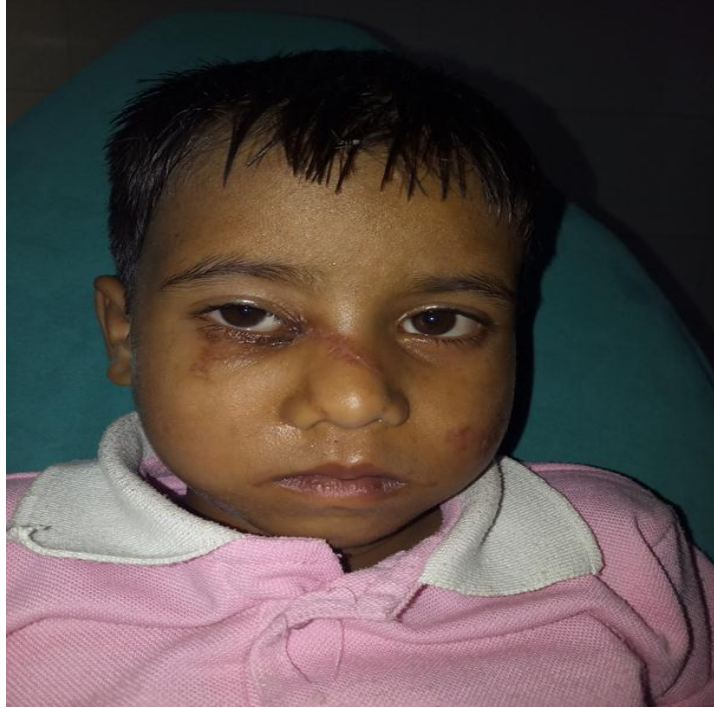

Fig 5:-Follow-up after 3 weeks

References:-

1. Dendle C, Looke D, Management of mammalian bites, *Aust. Fam. Phys.* 38(11) (2009) 868–874..
2. Kaye A E, Belz J M, Kirschner R E, Pediatric dog bite injuries: a 5-year review of the experience at the Children's Hospital of Philadelphia, *Plast. Reconstr. Surg.* 124 (2) (2009) 551–558.
3. Bykowski M R, Shakir S, Naran S, Smith D M, Goldstein J A, Grunwaldt L, Saladino R A, Losee J E, Pediatric dog bite prevention: are we barking up the wrong tree or just not barking loud enough? *Pediatr. Emerg. Care* (2017), <http://dx.doi.org/10.1097/pec.0000000000001132>.
4. Morgan M, Palmer J, Dog bites, *BMJ* 334 (7590) (2007) 413–417.
5. Wolff KD (1998) Management of animal bite injuries of the face: experience with 94 patients. *J Oral Maxillofac Surg* 56:838–843
6. Smith PF, Meadowcroft AM, May DB (2000) Treating mammalian bite wounds. *J Clin Pharm Ther* 25:85–99
7. Stefanopoulos PK, Tarantzopoulou AD (2005) Facial bite wounds: management update. *Int J Oral Maxillofac Surg* 34:464–472
8. Talan DA, Citron DM, Abrahamian FM, Moran GJ, Goldstein EJ, Emergency Medicine Animal Bite Infection Study Group (1999) Bacteriologic analysis of infected dog and cat bites. *N Engl J Med* 340(2):85–92
9. Goldstein EJ (1999) Current concepts on animal bites: bacteriology and therapy. *Curr Clin Top Infect Dis* 19:99–111
10. Morgan JP, Haug RH, Murphy MT (1995) Management of facial dog bite injuries. *J Oral Maxillofac Surg* 53:435–441
11. Goldstein AJ (1999) Current concepts on animal bites. Bacteriology and therapy. *Curr Clin Top Infect Dis* 19:99–111
12. Hansmann F, Below H, Kramer A, Müller G, Geerling G (2008) Prospective study to determine the penetration of iodide into the anterior chamber following preoperative application of topical 1.25% povidone-iodine. *Graef Arch Clin Exp* 245(6):789–793
13. Kramer A, Below H, Bieber N, Kampf G, Toma CD, Hübner NO, Assadian O (2007) Quantity of ethanol absorption after excessive hand disinfection using three commercially available hand rubs is minimal and below toxic levels for humans. *BMC Infect Dis* 7:117
14. Wu PS, Beres A, Tashjian DB, Moriarty KP (2011) Primary repair of facial dog bite injuries in children. *Pediatr Emerg Care* 27(9):801–803
15. Abrahamian FM, Goldstein EJC (2004) Bites. In: Gorbach SL, Bartlett JG, Blacklow NR (eds) *Infectious diseases*, 3rd edn. Lippincott, Williams and Wilkins, Philadelphia, p 1440

16. Natarajan S, Galinde JS, Asnani U, Sidana S, Ramaswami R (2012) Facial dog bite injury. *J Contemp Dent* 2(2):34–38
17. American Academy of Pediatrics (2009) Bite wounds. In: Pickering LK, Baker CJ, Kimberlin DW, Long SS (eds) *Red book: 2009 report of the Committee on Infectious Diseases*, 28th edn. American Academy of Pediatrics, Elk Grove Village, pp 187–191.