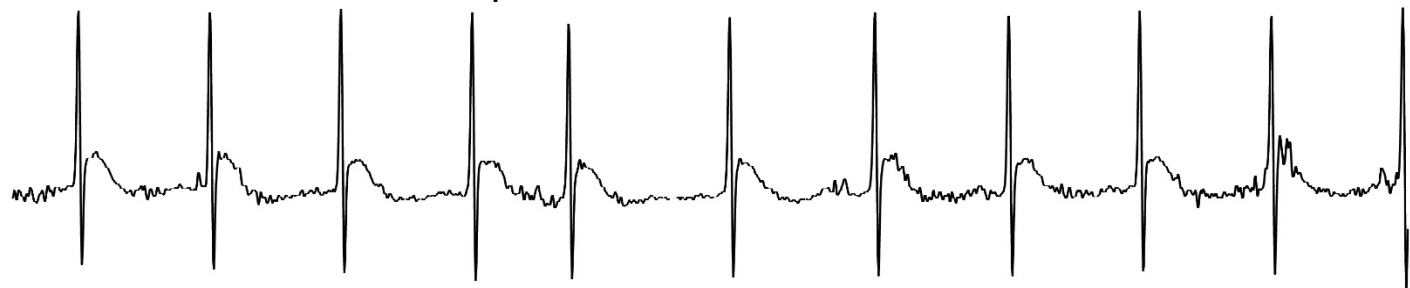
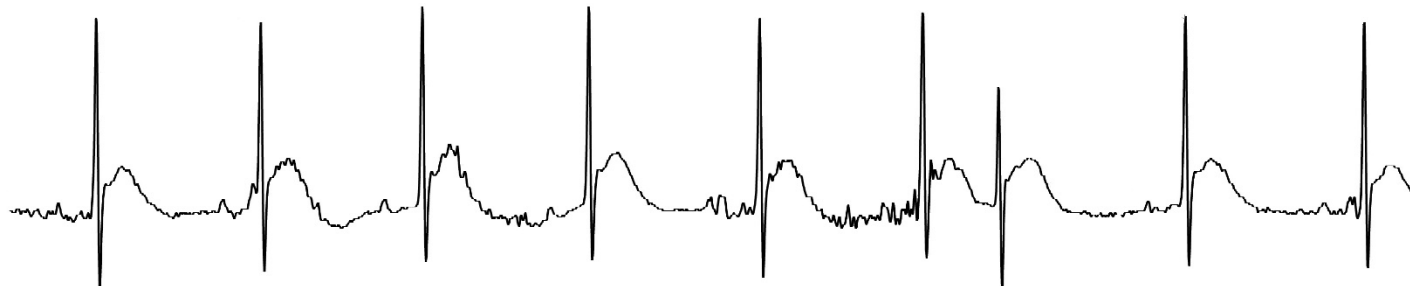


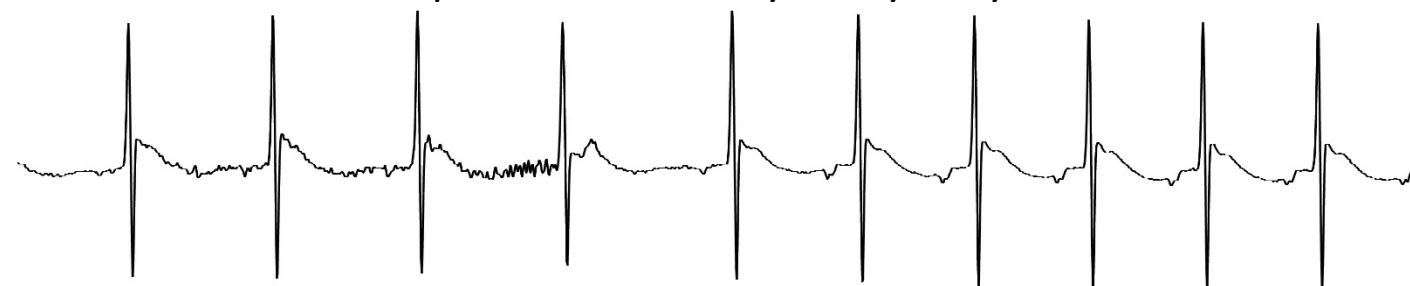Supraventricular extrasistole



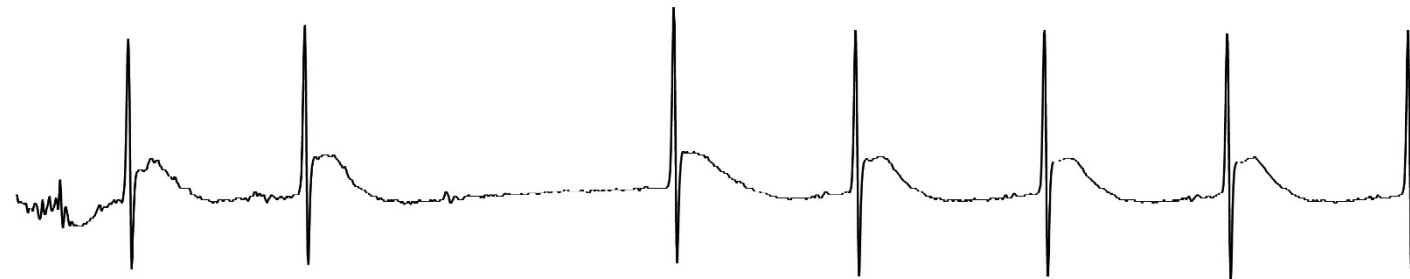
Sinus arrhythmia



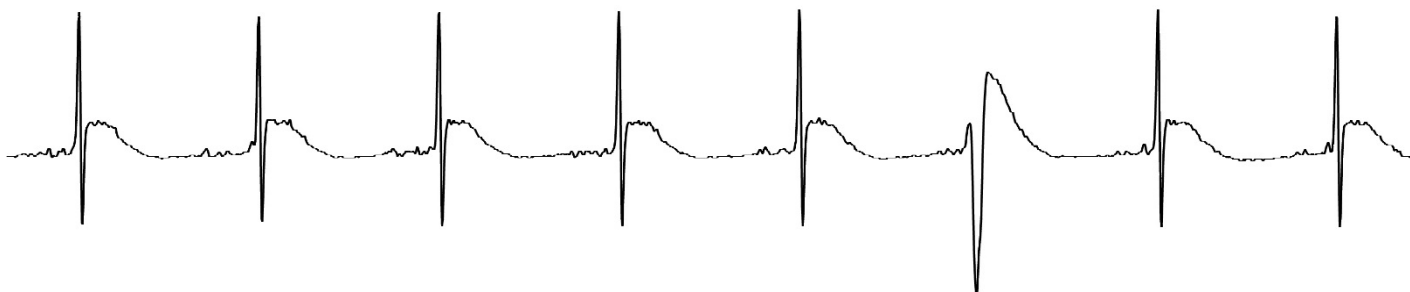Sinus pause followed by Tachyarrhythmia



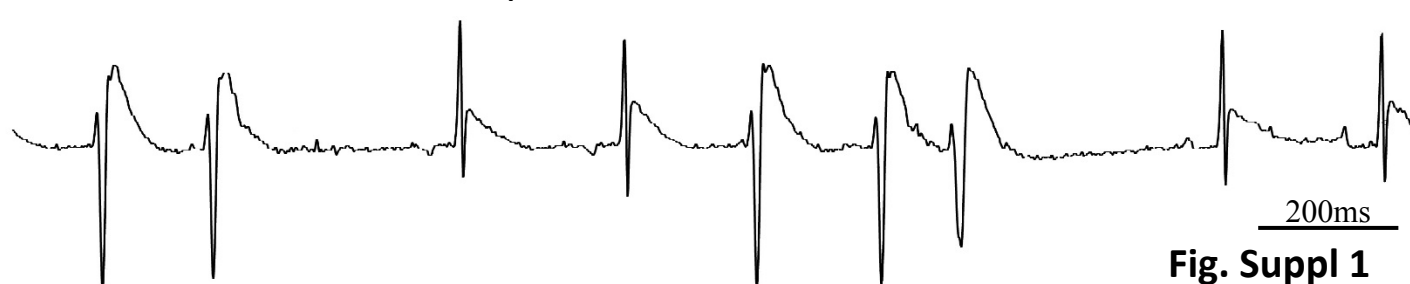
AV-block



Ventricular extrasistole



Multiple ventricular extrasistoles



200ms

Fig. Suppl 1