

## A CURIOUS CASE OF FEVER AND INTERSTITIAL LUNG DISEASE

Dr. Shahid Mahdi<sup>1</sup>, Dr. Darpanarayan Hazra<sup>2</sup> & Dr. Zainab Mahdi<sup>3</sup>

\*<sup>1</sup>Cardiac Intensive Care, BLK Super specialty Hospital

### *Abstract*

Antisynthetase syndrome is a rare chronic autoimmune inflammatory myopathy with fever, interstitial lung disease, Raynaud's phenomenon and polyarthritis. The exact underlying cause of antisynthetase syndrome is not yet known. Diagnosis is made with presence of Jo-1 (Histidyl tRNA synthase) antigen in a patient with underlying interstitial lung disease, myositis, arthritis, Raynaud's phenomenon and mechanic's hand. Some of the other antisynthetase antibodies are PL-7 (antigen – threonyl-tRNA synthase), PL-12 (antigen - Alanine-tRNA synthetase), OJ (antigen – Isoleucyl-tRNA synthetase), EJ (antigen - Glycyl-tRNA synthetase), KS (Antigen – Asparaginyl-tRNA synthetase, WA (Antigen- Autoantibody to a 48 kDa transfer RNA related protein), YRS (antigen - Tyrosyl-tRNA synthetase) however the prevalence is found to be highest with anti Jo-1 antibody (25-30%). In a patient with nonspecific interstitial pneumonitis, Raynaud's phenomenon and arthralgia antisynthetase syndrome can be best diagnosed with anti ZO ab, though prevalence of the disease is not yet known and in a patient with usual interstitial pneumonitis and fever diagnosis of anti synthetase syndrome can be made with anti KS antibodies. Symptomatic treatment is preferred, which may include immunosuppressive therapy and corticosteroids especially in a patient with muscle and lung involvement.

### *Keywords:*

Antisynthetase syndrome, anti Jo-1 antibodies, ILD with myositis, ILD with Raynaud's phenomenon

## I. Introduction

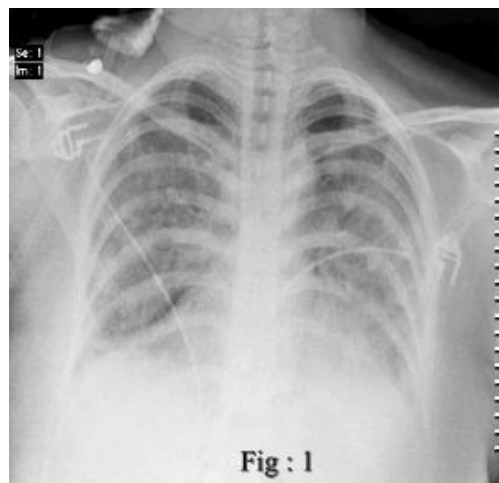
Anti synthetase syndrome is a very rare entity and only a few cases have been studied. It affects mostly females and is assumed to have a genetic predisposition, after certain viral infection or after certain drug use. Some studies also suggest that various types of cancers are also associated with antisynthetase syndrome. The most common symptoms include fever, loss of appetite, loss of weight, myositis, polyarthritis, interstitial lung disease, mechanic's hands and Raynaud's phenomenon. The prognosis of the disease is mostly depends on the extent of lung parenchymal involvement.

We hereby report a case of 33 years old lady presented to the emergency room with complains of fever, worsening of shortness of breath, polyarthritis for 6 weeks duration associated with weight loss and was previously diagnosed to have Raynaud's phenomenon. Her serology revealed antibodies against Jo-1 antigen and was started on corticosteroids and immunosuppressive therapy. However by the time anti Jo-1 ab was found to be positive, the extent of pulmonary involvement was massive and even on mechanical ventilator and other supports patient deteriorated and succumb to death.

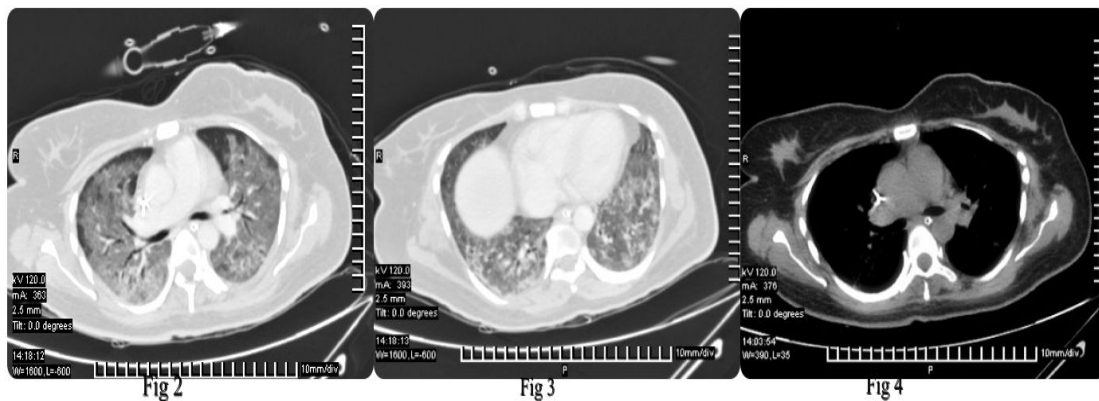
## II. Case report

A 33 old normotensive, non-diabetic lady presented to the emergency room with complains of fever, worsening of shortness of breath, polyarthritis for 6 weeks duration associated with weight loss. She also complained of numbness and color changes of digits on cold exposure. Her presentation was gradual and progressive in onset following an episode of high fever for which she was hospitalized and managed on empiric antibiotic therapy 6 weeks back. Initially she had responded well to the anti biotic therapy but had relapsed. She was previously diagnosed to have Raynaud's phenomenon and was on conservative management. She had no complains or any previous history oral

ulcers, malar rash, photosensitivity hair loss redness of eyes, serositis, seizures, weakness (Proximal/distal), skin tightening, chest pain, palpitation, hemoptysis, COPD, bronchial asthma, pulmonary embolism or any thromboembolic events (CVA, MI, amaurosis fugax, limb ischemia or recurrent pregnancy loss) in other system in the past. Her general examination revealed a dyspnoeic, febrile (102.3 F) patient with tachycardia (124b/min - regular), B.P (140/90mmHg), tachypnea (22/min). Chest examination revealed bilateral extensive rales and a few rhonchi. Other systemic examination was unremarkable. Initial blood investigations at the time of admissions were Hb - 14.1 gm/dl, TLC - 32,100 cells/mm<sup>3</sup> with 90% PMNs, platelet count - 3,47,000 cells/mm<sup>3</sup>, Na - 139 mmol/L; K - 3.9 mmol/L; Creatinine - 0.9 mg/dl; Urea - 21 mg/dl, serum protein - 5.46g/dl; albumin - 2.6g/dl; globulin - 2.96g/dl; bilirubin - 0.76mg/dl; AST - 122 IU/L; ALT - 208 IU/L; Alkaline Phosphatase - 117 IU/L. Arterial Blood Gases revealed pH - 7.48; pO<sub>2</sub> - 44; pCO<sub>2</sub> - 30; HCO<sub>3</sub> - 18. ECG was fine.



*CXR (Fig: 1) revealed diffuse bilateral haziness*



### III. IV.

*HRCT (Fig2, 3, 4) revealed extensive ground glassing opacification in bilateral lungs with irregular patchy infiltration in both lung bases*

Patient was started on intravenous antibiotics and non-invasive mechanical ventilation, which was later, switched to invasive ventilation, as high pressures were required to generate the required tidal volume. Differential diagnoses entertained were BOOP, Sarcoidosis and Hamman Rich Syndrome and was started on pulse Methyl Prednisolone therapy. Bronchoscopy revealed a clean endobronchial tree; bronchoalveolar lavage (BAL) obtained from RML and RLL was pauci-cellular with bronchial epithelial cells, macrophages and few inflammatory cells (N - 80%; L - 20%). Biopsy was not taken in view of high ventilatory requirements and poor general condition of the patient. Blood serology revealed Rheumatoid Factor and Antibodies against Jo-1 antigen positive. ANA, ANCA and Quantiferon Gold were negative; IgA, IgG and IgM levels were normal. Antibodies against HIV, HBV and HCV were negative. In view of Anti Jo-1 antibodies positive another differential diagnosis of antisynthetase antibody syndrome was made. She was continued with pulse Methyl Prednisolone therapy to which she responded favorably and by 10 days of therapy her blood counts had improved substantially and had good hemodynamics. She was extubated and maintained good oxygenation on non-invasive ventilation. However after this she developed acute onset quadriparesis with proximal muscles more affected and had sluggish reflexes, respiratory muscle weakness with a CPK level of 509 and normal MB fraction. In view of respiratory fatigue she was re intubated and started on IV Cyclophosphamide but her general condition gradually deteriorated and she finally expired.

### III. Discussion

The patient was suspected to have antisynthetase syndrome on the basis of Raynaud's phenomenon, arthralgia and pulmonary infiltrates. She was found to have antibodies to Jo-1 (histidyl-transfer RNA (tRNA) synthetase) using enzyme-linked immunoabsorbant assay (ELISA). Bronchoscopy with lavage and trans bronchial lung biopsy (at other center) showed no evidence of infectious or granulomatous disease probably because tissue samples were too small for precise histological diagnosis and therefore bronchoscopy and bronchoalveolar lavage was repeated again at our center but biopsy was avoided as the patient was on pressure control ventilation requiring high positive end expiratory pressure (PEEP). The CD4:CD8 ratio from bronchoalveolar lavage was not available and muscle biopsy was planned the next day, however the patient expired before it could be executed.

The antisynthetase syndrome belongs to the group of idiopathic inflammatory muscle diseases. The key clinical features of this syndrome are acute Polymyositis/dermatomyositis (PM/DM) at its onset, fever and symmetrical non-erosive arthritis, mechanic's hands, Raynaud's phenomenon and interstitial lung disease [1, 5]. The hallmark of the disorder is the presence of specific autoantibodies that recognize aminoacyl-tRNA synthetases but the most common lab investigations done on routine basis, is anti-Jo-1, which closely correlates with fibrosing alveolitis [6]. Among the remaining antisynthetase, anti-PL12 is found in 2–5% of patients with PM/DM and can be associated with isolated pulmonary fibrosis [5]. A small percentage (2–11%) of patients with dermatomyositis [5] do not have muscle involvement (amyopathic dermatomyositis or dermatomyositis sine myositis) but about 60% of these patients have anti-PL12 antibodies and 20% have anti-Jo-1 antibodies as in our patient [5]. In PM/DM, interstitial lung disease is the major clinical problem in patients with the Antisynthetase syndrome [7] and shares similarities with idiopathic pulmonary fibrosis or scleroderma-related pulmonary disease [7] and therefore determines the overall prognosis, having a mortality of over 40%. The prevalence of the disease appears to be greater in patients with positive anti-Jo-1 antibodies [1, 6, 7]. Interstitial lung disease may clinically present with persistent cough, chest pain, diminished exercise tolerance, dyspnea at rest, or even acute respiratory failure [7]. Moreover, dyspnea may be due to respiratory muscle weakness, drug-induced pneumonitis especially by methotrexate, pneumonia and less commonly due to fibrosis. Lung involvement with an acute aggressive alveolitis overshadowing the myopathy is rare [7]. Digital clubbing can occur, but less frequently than in idiopathic pulmonary fibrosis. Idiopathic pulmonary fibrosis may be the first and only manifestation, which can rapidly evolve into diffuse alveolar damage [1,5] and shows no response to steroid treatment and eventually patient succumbs to death. Therefore it is important to identify patients with amyopathic DM and non-specific interstitial pneumonitis (NSIP) early in the disease course and institute therapy prior to development of diffuse alveolar damage.

Pulmonary function test showing a characteristic restrictive impairment, chest radiographs revealing bilateral and predominantly basilar interstitial infiltrates and HRCT revealing ground glass, linear infiltrates appearing as irregular opacities, airspace consolidation, parenchymal micro nodules, or honeycombing pattern are the features of this disease. The bronchoalveolar lavage (BAL) in an early stage of the disease may show lymphocytic alveolitis with high CD8+ T cells counts, which denotes good response to steroids. The presence of eosinophils and

neutrophils are found less commonly and indicates progression to fibrosis. Lung biopsy may reveal NSIP; diffuse alveolar damage, usual interstitial pneumonia (UIP) and bronchiolitis obliterans organizing pneumonia (BOOP) [7]. Treatment with steroids usually with prednisone in the range of 60 mg/day seems to be effective for controlling the extra-pulmonary manifestations of the syndrome. Patients with NSIP or BOOP have a more favorable prognosis than patients with UIP or diffuse alveolar damage [7], because these are usually steroid-resistant and may require additional immunosuppressive treatment.

Interstitial lung disease shows poor response to steroids and the optimal treatment for these patients has yet to be established.

#### IV. Conclusion

Antisynthetase syndrome should be considered in patients with interstitial lung disease even without evidence of myositis. Early diagnosis and early institution of immunosuppressive therapy may change clinical course of the syndrome though most of them have a steep downhill course. The role of Intravenous immunoglobulin and steroids which usually improves muscle strength and has not been elucidated in patients with antisynthetase syndrome and needs further study

#### REFERENCES

1. Love LA, Leff RL, Fraser DD, Targoff IN, Dalakas M, Plotz PH, Miller FW (1991) A new approach to the classification of idiopathic inflammatory myopathy: myositis-specific autoantibodies define useful homogenous patients groups. *Medicine* 70:360–374
2. Hochberg MC, Feldman D, Stevens MB (1986) Adult onset PM/DM: an analysis of clinical and laboratory features and survival in 76 patients with a review of the literature. *Semin Arthritis Rheum* 15:168–178
3. el-Azhary RA, Pakzad SY (2002) Amyopathic dermatomyositis: retrospective review of 37 cases. *J Am Acad Dermatol* 46:560–565
4. Caproni M, Cardinali C, Parodi A et al (2002) Amyopathic dermatomyositis: a review by the Italian Group of Immunodermatology. *Arch Dermatol* 138:23–27
5. Friedman AW, Targoff IN, Arnett FC (1996) Interstitial lung disease with autoantibodies against aminoacyl-tRNA synthetases in the absence of clinically apparent myositis. *Semin Arthritis Rheum* 26:459–467
6. Phillips TJ, Leigh IM, Wright J (1987) Dermatomyositis and pulmonary fibrosis associated with anti-Jo1 antibody. *J Am Acad Dermatol* 17(2 Aug Pt 2): 381–382.
7. Interstitial lung disease in a patient with Antisynthetase syndrome and no myositis: Sotiris C. Plastiras . Fotini C. Soliotis. Panayiotis Vlachoyiannopoulos . George E. Tzelepis *Clin Rheumatology* (2007) 26: 108–111

**Author Bibliography**

	<p>Dr. Shahid Mahdi DNB (Respiratory medicine), FRCCM (SINGAPORE), MNCCP, MISCCM. Associate Director and Head Cardiac Intensive Care BLK Super specialty hospital, New Delhi <a href="mailto:mahdishahid@gmail.com">mahdishahid@gmail.com</a></p>
	<p>Dr. Darpanarayan Hazra MBBS Junior resident Cardiac Intensive Care BLK Super specialty hospital, New Delhi <a href="mailto:drdarpahazra@gmail.com">drdarpahazra@gmail.com</a></p>
	<p>Dr. Zainab Mahdi MBBS, DNB (student) Emergency medicine Fortis Hospital, Mohali <a href="mailto:itszainab@gmail.com">itszainab@gmail.com</a></p>