



CODEN [USA]: IAJPB

ISSN: 2349-7750

## INDO AMERICAN JOURNAL OF PHARMACEUTICAL SCIENCES

Available online at: <http://www.iajps.com>

Research Article

### COMPARISON OF TREATMENT OUTCOMES OF SURGICAL REPAIR IN INGUINAL HERNIA WITH CLASSIC VERSUS PREPERITONEAL METHODS ON REDUCTION OF POSTOPERATIVE COMPLICATIONS

<sup>1</sup>Dr. Hafiz Syed Zaigham Ali Shah, <sup>2</sup>Dr. Muhammad Arsalan Sharif, <sup>3</sup>Dr. Namra Javed  
<sup>1</sup>MBBS; King Edward Medical University Lahore, Pakistan., <sup>2</sup>MBBS; Nishtar Medical College  
Multan, Pakistan., <sup>3</sup>MBBS; Allama Iqbal Medical College Lahore, Pakistan.

Article Received: March 2019

Accepted: April 2019

Published: May 2019

**Abstract:**

*The occurring of inguinal hernia is in 1.5per cent of the population that is general in 5% of male people. The type that is bilateral about 12% of customers, the immediate and the combined people are more repeated than the secondary. Simultaneous or repair that is sequential come discussed especially after tension-free repairs. This research was actually practiced evaluate treatment outcome of surgical maintenance therapy with two-sided Lichtenstein hernioplasty for the therapy of major two-sided hernia that is inguinal.*

*This study included 80 male patients with major bilateral hernias that are inguinal. They certainly were broken down arbitrarily into two groups that are equal. People A underwent bilateral Lichtenstein hernioplasty and people B underwent repair that is surgical. Preoperative, operative, and characteristics that are postoperatively recorded for each and every client from inside the study. Patients comprise followed right up at 3, 6, and one year postoperatively.*

*As regards preoperative data, there seemed to be no difference that is statistically significant in both groups. The repair that is surgical grabbed a somewhat less time as compared to bilateral Lichtenstein techniques; the mean operative times for medical maintenance therapy and two-sided Lichtenstein was 84.0±8.6 and 96.4±6.2 min, respectively. Visual analogy rating of pain 12h postoperatively was notably low in the repair that is surgical than in the bilateral Lichtenstein group. As regards operative and postoperative difficulties, there seemed to be no difference that is significant in both groups. Medical centers keep, return to normal activities that are daily and inguinodynia rates comprise close in both communities. There seemed to be no recorded recurrence both in combined communities as much as 1 follow-up year.*

*Bilateral primary inguinal hernias may operate within one setting without a boost in morbidity or recurrence price. The surgical repair tends to be a close replacement for bilateral Lichtenstein procedure to treat bilateral inguinal hernia, with the equivalent end result.*

**Keywords:** *Hernioplasty, Bilateral, Inguinal hernia, Lichtenstein, Stoppa*

**Corresponding author:**

**Dr. Hafiz Syed Zaigham Ali Shah,**  
MBBS; King Edward Medical University Lahore, Pakistan.

QR code



Please cite this article in press Hafiz Syed Zaigham Ali Shah et al., *Comparison Of Treatment Outcomes Of Surgical Repair In Inguinal Hernia With Classic Versus Preperitoneal Methods On Reduction Of Postoperative Complications.*, Indo Am. J. P. Sci, 2019; 06(05).

**INTRODUCTION:**

Basically, hernia stands out as the protrusion associated with a viscus or component of a viscus all the way through an irregular beginning through the membranes of the containing pit. Seventy-five percent of most abdomen wall hernias take place in the crotch. Inguinal hernia repair was the commonest process overall practice that is surgical. Hernias occur in about 1–5% of the general population. Inguinal hernias are unilateral and about 20% of patients with inguinal hernia present bilateral hernias according to the reports after the diagnosis (Gamagami et al., 2018).

Originally the hernia term comes from the Greek hernias (which means budding). A hernia is described as tiredness in the fibromuscular tissues around the wall structure from were contents in the cavity underlying it develops through the wall. The strengthening in the posterior facet of the inguinal which is the most important objective in inguinal hernia repair. Bassini pioneered the repair that is surgical of hernia (he performed the 1st operation in 1884 and published the outcome in 1889). Hernias can happen anywhere, it was usually from inside the prior abdominal wall in certain, the inguinal, femoral, and umbilical regions, linea alba, and internet of earlier incisions. The umbilical inguinal, femoral hernias are covered around 75% of the population. The inguinal area (lying between the decreased belly and the thigh) was the point that is weakest in the anterior abdominal wall structure where hernia typically does occur. A hernia can happen in any condition that increases intra-abdominal pressure (Goodwin and Traverso, 1995).

If it is considered historically in any individual whooping cough in childhood happens to be a predisposing factor that is important. In people, a powerful effort that is muscular of coughing and pushing throughout micturition or laxation may affect a hernia. For decades, there is a thought that parallel maintenance of two-sided inguinal hernias could get associated with morbidity that is high reappearance price. The introduction of tension-free maintenance techniques directed to a great noticeable change in this concept. Keeping of a prosthetic mesh was needed in all types of available or laparoscopic repair that is tension-free. The most frequently sang techniques that are open to Lichtenstein's and Stoppa's hernioplasties. Advantages of parallel repair of bilateral inguinal hernia patient express, and bear effectiveness, just like the client was afflicted by one anesthesia, a hospital keep, and merely one time

period recovery (Jago, 2000).

Stoppa's fantastic prosthetic reinforcing stimulus in the sac that is viscerally performed in 1975. Stoppa covered the reduced a portion of the parietal wall structure with wide interlocks that discusses the orifice that is myopectineal. This calls for an analysis of the preperitoneal room, wire architecture, detection as well as decrease in the sac and placing an extensive mesh amongst the peritoneum and prior wall that is abdominal (James, 2017).

**METHODS:****Patients:**

This potential research engaged 80 male clientele who tended to the General Surgery Department, Hospital Pakistan.

**Inclusion criteria:**

People with main bilateral inguinal hernias with the age of 20-60 years are included in this research.

**Exclusion criteria:**

Strenuous hernia (impeded or strangulated), people with affiliated intraperitoneal pathology, as well as abdomen wall infections were excluded from this research.

Updated permission was actually extracted from each respondent. Patients comprise allotted to two categories of 40 patients each. Patients were labeled of the classification that is Nyhus. Underwent patient of hernia by multiple Lichtenstein interlock hernioplasty and the other cluster underwent Stoppa's repair. They underwent investigations that are routine and people located fit for surgery comprise operated upon. The time that is operative from facial skin incision to wound dressing) was actually recorded. The core endpoint is the evaluation of constant groin pain and hernia recurrence in both groups. The secondary endpoints comprise perioperative parameters (operative time, and intraoperative and postoperative complications), the medical facility remains, postoperative soreness rating, and time of return to typical activity that is daily and follow-up information.

**Lichtenstein hassle-free hernioplasty:**

The inguinal skin surgical incision was, in fact, made 0.5 inches above and parallel with the inguinal sinew from above and lateral to the pubic tubercle to below and medial to the anterior outstanding spine that is iliac. The sac that is indirect, ligated making use of section. The big direct sacs happened to be invaginated and plicated Vicryl through operating 0 of 6x11 cm was applied in every case. The mesh was

fixed in position polypropylene that is using. The mesh was fixed down to the inguinal ligament and up with the conjoint tendon (through the pubic tubercle to beyond the orifice of the ring that is internal.

#### The Procedure of Stoppa:

The method invented by Stoppa had been applied. Individuals were given spinal anesthesia with anti-biobiotic prophylaxis. The abdomen was taken off by Pfannenstiel incision. Subcutaneous excess fat and rectus sheath were opened. Both recti separated in the midline. Dissection in the space that is pre-peritoneal from the retropubic space of Retzius to the rectus abdominis muscles and epigastric vessels laterally, extending to the retroinguinal space. Spermatic cord and gonadal vessels were identified. Superior pubic rami, obturator foramina, and iliac vessels were visualized. Lightweight acs that are direct and reduced. Large sacs happened to be ligated with a purse-string suture and got rid of. Indirect sacs were divided, the part that is proximal sutured, in addition to the distal part was actually leftover in-situ connected to the wire. If indirect hernia was sliding,

dissection in the sac through the cord structures was performed.

#### Follow-up

Patients were then followed up on a monthly basis when it comes down to 3 months that is first next after three months from inside the outpatient center to take into account reappearance. Year patients were totally followed up for a period of 1.

#### RESULTS:

As mentioned in Table 1 below this research involved 80 male patients with primary bilateral hernias that are inguinal comprise separated into two groups. Group "A" included 40 customers just who underwent bilateral Lichtenstein hernioplasty that is tension-free. Group "B" integrated 40 customers who underwent Stoppa maintenance. As concerns data that are pre-operative, cigarette, comorbidities, Body Mass Index and category of hernia (as previously mentioned in Fig. 1)], there were no statistically big differences when considering both groups.

**Table 1 Preoperative assessment**

Preoperative data	Group A (bilateral Lichtenstein tension-free hernioplasty) (n=40)	Group B (Stoppa repair) (n=40)
<b>Age</b>		
Minimum–maximum	23–58	21–60
Mean±SD	41.8±4.8	43.4±6.2
Smoking [n (%)]	16 (40)	14 (35)
<b>Comorbidities [n (%)]</b>		
Hypertension	4 (10)	6 (15)
Diabetes	4 (10)	6 (15)
COPD	8 (20)	10 (25)
BPH	6 (15)	4 (10)
<b>BMI</b>		
Minimum–maximum	23.0–35.3	25.4–36.8
Mean±SD	27.4±2.8	28.2±2.6
<b>Type of hernia [n (%)]</b>		
Direct (bilateral)	32 (80)	34 (85)
Indirect (bilateral)	6 (15)	4 (10)
Direct (unilateral) +indirect (bilateral)	2 (5)	2 (5)

BPH, benign prostatic hypertrophy; COPD, chronic obstructive pulmonary disease.

The operative time was somewhat less in-group B patients (Stoppa repair); it ranged between 64 and 94

min, with a mean of 84.0±8.6 minute, whereas in people A (bilateral Lichtenstein tension-free

angioplasty, they varied between 72 and 114 min, with a mean of  $96.4 \pm 6.2$  min ( $P < 0.001$ ). There had been no complications that are intra-operative or vascular injury) in both groups. In relation to post-operative complications (injury seroma and hematoma, urine retention, wound infection, and

scrotal swelling), chronic groin serious pain, postoperative hospital keep, and return to operate, there comprise no statistically big distinctions (as mentioned in below Table 2). No recurrence took place in virtually any client after 1 of follow-up in either group year.

**Table 2 Operative and postoperative parameters**

Perioperative parameters	Group A (bilateral Lichtenstein tension-free hernioplasty) (n=40)	Group B (Stoppa repair) (n=40)
Operation time (min)		
Minimum–maximum	72–114	64–94
Mean±SD	$96.4 \pm 6.2$	$84.0 \pm 8.6$
Postoperative complications [n (%)]		
Wound seroma and hematoma	4 (10)	2 (5)
Urine retention	2 (5)	2 (5)
Wound infection	2 (5)	2 (5)
Scrotal swelling	4 (10)	6 (15)
Chronic groin pain [n (%)]		
Absent	34 (85)	36 (90)
Present	6 (15)	4 (10)
Postoperative hospital stay (days)		
Minimum–maximum	1–2	1–3
Mean±SD	$1.0 \pm 0.40$	$1.6 \pm 0.8$
Median	1	1.5
Return to work (days)		
Minimum–maximum	12.0–18.0	14.0–26.0
Mean±SD	$16.00 \pm 4.60$	$20.00 \pm 3.80$

As concerns, postoperative serious pain scoring determined by the aesthetic analog level at 12 h postoperatively, there comprise mathematically significant distinctions between both groups in favor

of people B patients, however, there was no difference that is statistically significant both communities in serious pain at 24h and 1 week postoperatively because below discussed Table 3.

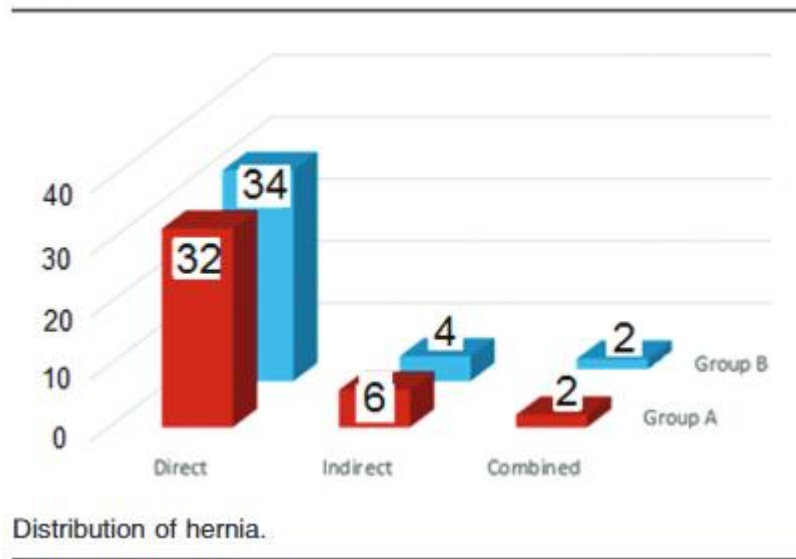
**Table 3 Postoperative pain in both groups**

Groups	Postoperative pain		
	12 h	24 h	7 days
<b>Group A</b>			
Minimum–maximum	9–6	5–3	2–0
Mean±SD	6.2±1.8	3.3±1.1	1.1±0.4
<b>Group B</b>			
Minimum–maximum	8–5	4–3	2–1
Mean±SD	5.6±0.6	3.8±0.4	1.4±0.2
<i>P</i> value	0.010	0.5	0.6

**DISCUSSION:**

The inguinal hernia has an incidence that is of and 60 years. Reports practiced researchers indicated that the age that is mean of was 52.7 years. In the study that is a present mean period of speech was an actually 41.8±4.8 year in group one, and 43.4±6.2 age in group B, which one is the younger than the average

age revealed of the Fernandez and Tartas research (James, 2017). This may be as a result of the known truth that a lot of in the patients while in the present research were workers. All the patients studied were male individuals in the present study (Waite, Herman and Doyle, 2016).

**Figure 1**

For a long time, it absolutely was believed that accompaniment repair of bilateral inguinal hernias should never be carried out, since this may produce increased postoperative problems (serious pain, wound complications, and recurrences). Today, it was well recognized that synchronous repair of bilateral hernia was possible and effective. The information of Hernia based on one-stage treatment (laparoscopic or Lichtenstein) for the control of two-

sided inguinal hernias was almost complete and very informative for the suffered people. The Stoppa technique is actually a method that is the alternative repair of two-sided inguinal hernia, but mainly for experienced doctors with this technique. This directed us to execute this research to evaluate the Stoppa procedure together with the Lichtenstein techniques for surgery of bilateral hernias that are inguinal (Katri, 2009).

Giant corrective support with the intuitive sac or Stoppa therapy is a pre-peritoneal strategy concerning bilateral inguinal hernias. This therapy includes wide dissection of the space that is pre-peritoneal. The classical Stoppa's repair is done by wrapping the decreased a portion of the parietal peritoneum through a huge polypropylene mesh that is chevron-shaped. Pelissier et al suggested that all recurrences occur through the orifice that is myopectineal hence, a mesh covering only this neighborhood was effective, as sang from inside the Rives therapy (Mentes and Bagci, 2009).

Sharma et al. , carried out research to figure out clinical outcome and expenses effectiveness of open pre-peritoneal mesh insertion in contrast with Lichtenstein interlock maintenance in the primary two-sided hernia that is inguinal. They translated that inguinodynia Lichtenstein repair was more as contrasted with the open pre-peritoneal repair. They attributed them to dissection in the canal that is inguinal mesh fixation. The mesh is placed in the preperitoneal plane and gets fixed in place by intra-abdominal pressure in the open preperitoneal technique. Both have close recurrence rates. They determined that the available approach that is preperitoneal a safer, best and economical replacement for Lichtenstein mesh repair (Sinha et al., 2006).

Askar et al. executed a potential study that is the randomized repair of bilateral inguinal hernia in 40 patients comparing the Stoppa techniques with simultaneous two-sided Lichtenstein technique. They determined that the Stoppa maintenance was obviously a reliable technique for bilateral inguinal hernia, ingesting considerably operative times, reduced postoperative serious pain, early return to program task, low recurrence rate and patient satisfaction level that is good. These email address details are comparable to the result of the study that is present (Ohuchi et al., 2018).

### CONCLUSION:

Multiple repairs of bilateral inguinal hernia are secure and efficient since it was associated with better satisfaction that is patient less expensive in addition to the patient is exposed to only 1 medical facility admission, anesthesia and requires merely one year of recuperation lacking any build in morbidity or perhaps the reappearance rate. Stoppa's method of hernia maintenance is an excellent replacement for two-sided Lichtenstein's maintenance to treat bilateral inguinal hernia with relative medical procedure and postoperative challenges. Stoppa's

repair can even be accomplished wearing a reasonably shorter time, so because of this could possibly be the method preference, especially in risky patients with a two-sided hernia that is inguinal. Moreover, Stoppa's repair need routinely included in virtually any medical care system handling hernia patients and in the earning that is professional of junior doctors.

### REFERENCES:

1. Gamagami, R., Dickens, E., Gonzalez, A., D'Amico, L., Richardson, C., Rabaza, J. and Kolachalam, R. (2018). Open versus robotic-assisted transabdominal preperitoneal (R-TAPP) inguinal hernia repair: a multicenter matched analysis of clinical outcomes. *Hernia*, 22(5), pp.827-836.
2. Goodwin, J. and Traverso, L. (1995). A prospective cost and outcome comparison of inguinal hernia repairs. *Surgical Endoscopy*, 9(9).
3. Jago, R. (2000). Stapled and nonstapled laparoscopic transabdominal preperitoneal inguinal hernia repair. *Surgical Endoscopy*, 15(7), pp.766-766.
4. James, R. (2017). Postoperative Pain in Laparoscopic Transabdominal Preperitoneal Versus Lichtenstein Open Mesh Repair Techniques for Inguinal Hernia. *Journal of Surgery Pakistan*, 22(3).
5. Katri, K. (2009). Open preperitoneal mesh repair of recurrent inguinal hernia. *Hernia*, 14(1), pp.115-115.
6. Mentes, O. and Bagci, M. (2009). Postoperative pain management after inguinal hernia repair: lornoxicam versus tramadol. *Hernia*, 13(4), pp.427-430.
7. Nayak, D. (2017). A Study on Comparison between Open Preperitoneal Mesh Repair and Lichtenstein Mesh Repair for Inguinal Hernia. *Journal of Medical Science And Clinical Research*, 05(05), pp.21225-21228.
8. Ohuchi, M., Fukunaga, M., Nagakari, K., Azuma, D., Kohama, S., Nomoto, J. and Sakamoto, K. (2018). Surgical technique and outcomes of transabdominal preperitoneal inguinal hernia repair after radical prostatectomy: dissection between the transversalis fascia and superficial layers of preperitoneal fascia. *Hernia*, 23(1), pp.167-174.
9. Sinha, R., Sharma, N., Dhobal, D., and Joshi, M. (2006). Laparoscopic total extraperitoneal repair versus anterior preperitoneal repair for inguinal hernia. *Hernia*, 10(2), pp.187-191.

10. Waite, K., Herman, M. and Doyle, P. (2016). Comparison of robotic versus laparoscopic transabdominal preperitoneal (TAPP) inguinal hernia repair. *Journal of Robotic Surgery*, 10(3), pp.239-244.