

ORIGINAL ARTICLE

Evaluation of predictive value of 1H MR spectroscopy for response of neoadjuvant chemotherapy in musculoskeletal tumors

Predrag Cirkovic¹, Jelena Mihailovic¹, Lejla Paripovic², Vesna Ilic², Dusan Ristic³, Igor Djuriscic⁴, Aleksandar Djordjevic⁵, Ruzica Maksimovic⁶

¹Institute for Oncology and Radiology of Serbia, Department for Radiology, Belgrade, Serbia; ²Institute for Oncology and Radiology of Serbia, Department for Pediatric Oncology, Belgrade, Serbia; ³Institute for Oncology and Radiology of Serbia, Department for Medical Oncology, Belgrade, Serbia; ⁴Institute for Oncology and Radiology of Serbia, Department for Surgery, Belgrade, Serbia; ⁵Institute for Orthopedic Surgery "Banjica", Department for Orthopedic Oncology, Belgrade, Serbia; ⁶School of Medicine, University of Belgrade, Center for Radiology and Magnetic Resonance, Clinical Center of Serbia, Belgrade, Serbia

Summary

Purpose: Bone and soft tissue tumors are rare. There is a variety of types and each one has its own particular behavior, treatment and patient outcome. The assessment of treatment response following the 3rd cycle of chemotherapy is one of the most important aspects of patient care, as therapeutic options and the timing of surgery may vary depending on the achievement of response. Hence, we focused on the advanced imaging technique, proton magnetic resonance spectroscopy (1H MRS), aiming at improving the diagnostic accuracy and the tumor response to therapy, based on the absolute concentration of choline (Cho) as biomarker of malignancy.

Methods: Twenty patients were studied. All of them had a pathological diagnosis after biopsy. MRI examinations were performed using a 1.5 T MR scanner (Avanto; Siemens, Erlangen, Germany). Single-voxel 1H MR spectroscopy was performed by using a PRESS with TR/TE 1530/100 ms, before chemotherapy and after the 3rd cycle. 1H MRS was

processed in LC model.

Results: Of 20 patients, 7 responded to neoadjuvant chemotherapy and 13 did not. In responders, the mean concentration of tCho before therapy was 4.7±2.5 mmol/kg, which showed statistically significant reduction after therapy. In non-responders, the mean tCho concentration before therapy was 2.9±0.9 mmol/kg which remained the same or increased after the 3rd cycle of neoadjuvant chemotherapy (2.7±2.5 mmol/kg; range from 2.05 to 5.79 with no statistical significance). Compared to reference healthy group, tCho concentrations were increased in all cases.

Conclusions: 1H MRS appears to be valuable technique for evaluation of response to neoadjuvant chemotherapy of patients with musculoskeletal tumors (MSK).

Key words: choline, musculoskeletal, proton spectroscopy, response, tumor

Introduction

Bone and soft tissue tumors are rare. There is a variety of types and each one has its own particular behavior, treatment and patient outcome. The etiology of these tumors is basically unknown. Some researchers have suggested a genetic cause

because of the increased incidence in patients with certain conditions (hereditary osteocartilaginous exostosis, Maffucci's syndrome, Paget's disease) and because certain tumors have genetic mutations of their cells [1,2].

Correspondence to: Predrag Cirkovic, MD, MSc. Institute for Oncology and Radiology of Serbia
Pasterova 14, 11000 Belgrade, Serbia.
Tel: +381 11 2067209, Fax: +381 11 2685300, E-mail: lariscp2014@gmail.com
Received: 18/03/2018; Accepted: 21/04/2018

Bone and soft tissue tumors are classified by their cell or tissue type and their ability to spread beyond the original site [2,3]. Thus, they fall into two major categories (benign or malignant). Malignant tumors, also known as sarcomas, are a relatively rare form of cancer, often requiring treatment with chemotherapy and/or radiation therapy and major surgery. Neoadjuvant chemotherapy is standard treatment for MSK tumors with evaluation of therapeutic success determined after the 3rd cycle [3-5]. Therapeutic effectiveness of neoadjuvant chemotherapy usually is assessed based on the percentage of the tumor necrosis.

The assessment of treatment response following chemotherapy is one of the most important aspects of patient care, as therapeutic options and the timing of surgery may vary depending on the success of response. As a non-invasive technology with no ionizing radiation, magnetic resonance imaging (MRI) is the favored modality for evaluation of soft tissue tumors and tumor-like conditions because of its superior soft tissue contrast and multiplanar imaging capability [6], and offers unique contributions in determining and monitoring the therapeutic response. From an anatomic imaging perspective, MRI offers higher contrast resolution compared to CT and ultrasound. From the perspective of imaging the tumor microenvironment, MRI can provide an assessment of the tumor vasculature, and the potential to provide detailed information about the biochemical environment, tissue composition, and structure [7-9]. However, for many patients, conventional MRI is unable to provide a specific histological diagnosis or assess the true extent of viable or necrotic malignant tumor, factors that are important to determine the response to treatment and patient prognosis [10-12]. Several studies have already demonstrated imaging morphological parameters as a criterion for differentiating benign from malignant MSK tumors and response to therapy, such as size, margins demarcation, involvement of adjacent vital structures and homogeneity in signal intensity. However, in several cases conventional MRI presents low specificity in the differential diagnosis of MSK tumors, as many of the lesions present nonspecific characteristics [13,14]. Nevertheless, advanced MRI techniques, such as MR proton spectroscopy (MRS), have been associated with conventional MRI, with the objective of improving the diagnostic accuracy of this imaging method, in particular in the assessment of the malignancy potential of a lesion [12,14,15]. Namely, MRS has been focused on increased levels of choline in malignant bone and soft tissue tumors, an observation in agreement with evidence that choline is a useful marker

of malignancy in several organ systems, including brain, breast, prostate and liver. For soft tissues, the *in vitro* studies showing that disorders that influence cell membrane turnover, such as uncontrolled proliferation in malignant transformation, result in changes in the concentration of choline-containing compounds [13-18].

The objective of this study was to evaluate the contribution of 1H-MR spectroscopy to determine treatment response after the 3rd cycle of MSK lesions, analyzing their choline peak, in an attempt to predict the overall response.

Methods

Patients

The study included 20 patients (12 male, 8 female, 5- 46 years old). All patients were pathologically diagnosed with biopsy. The control group consisted of 15 volunteer healthy patients (age-matched). Prior to the MRI examination, evaluation of all relevant clinical data was performed. MRI scans were performed initially on diagnosis, before chemotherapy and surgery and then after the 3rd or 4th cycle of neoadjuvant chemotherapy according to revised European Society of Medical Oncology (ESMO) guidelines [20]. The patients were classified as responders or non-responders depending on the clinically evaluated treatment success. Treatment success was evaluated by the attending physician. Physicians assessed disease outcomes at follow-up visits through the available clinical data including imaging techniques, alkaline phosphatase levels, physical examinations and medical records. The response classifications were extracted from the patient medical records and defined as clinical complete response (CR) or partial response (PR), stable disease (SD) or progressive disease (PD).

MRI

Conventional MRI examinations were performed with a 1.5 T Magnetom Avanto (Siemens, Erlangen, Germany) with body coils using imaging sequences which included T1- and T2- weighted spin echo images (repetition time (TR)/echo time (TE): 426/3600/15/104 ms; matrix: 521 × 512) and post-contrast T1-weighted images with fat saturation. The conventional protocol was performed including coronal, sagittal and axial plane. Field of view (FOV), slice thickness and spacing between slices varied according with the tumor size. The paramagnetic contrast agent (0.1 mmol/kg Magnevist, Schering, Germany) was applied in all patients.

MRS

Proton spectroscopy was performed by in-house made protocol, with a single-voxel point-resolved spectroscopy sequence with TR/TE = 1530/100 ms and averages 192. The volumes of interest (VOI) (ranging from 10 mm² to 14 mm²) were positioned in the areas presenting contrast uptake, avoiding the inclusion of bone structures, fat and muscles. Voxel was placed over lesions

based on hyperintensity on T2W and postcontrast T1W fat saturated MR images in an attempt to avoid zone of necrosis. Because of heterogeneity of MSK tumors before contrast T1W was evaluated to exclude hemorrhage zone and influence of partial effect. A fully relaxed, single-shot, unsuppressed spectrum was acquired to measure the water and lipid peaks. 1H MRS was processed in LCmodel and the absolute concentration of metabolite was calculated. The presence of a choline peak within the lesion was defined by the 3.2 ppm peak on obtained spectra. Pre-therapy spectrum was obtained from all patients, monitored sequentially after the 3rd or 4th cycle of neoadjuvant chemotherapy, before surgical resection. Only 2 patients could not be monitored due to non-cooperation.

Statistics

For each parameter of interest, mean and standard deviation were computed. To ensure that there were no significant deviations from Gaussian distribution, Kolmogorov-Smirnov normality tests were performed.

To test for differences in metabolite concentrations (internal reference) among responder and non-responder group, analysis of variance (ANOVA) was performed, followed by Bonferroni-corrected *post-hoc t*-tests.

All statistical analyses were carried out using the statistical software SPSS 17 and *p*<0.05 values were considered as statistically significant.

Results

Table 1 demonstrates the demographic characteristics, histopathological findings and Table 2 proton spectroscopy data of the studied tumors.

The presence of choline (Cho) peak at 3.2 ppm was demonstrated in 20/20 cases on initial 1H MR spectra of MSKs. The pooled analysis of data showed that pre-therapy mean concentration of tCho was 3.6 ± 2.2 mmol/kg which decreased to 1.6 ± 2.2 mmol/kg after the 3rd cycle of chemotherapy in 9/20 patients. A retrospective comparison of tCho concentration after classifying the patients as responders and non-responders (based on clinical response) was carried out. Of 20 patients, 7 were responders and 13 non-responders. The MR spectral patterns obtained prior to therapy and after the 3rd cycle in a responder are shown in Figure 1. In responders, the mean concentration of tCho before therapy was 4.7 ± 2.5 mmol/kg which showed statistically significant reduction after therapy (Table 2). In non-responders, the mean tCho concentration before therapy was 2.9 ± 0.9 mmol/kg which remained the same or increased after the 3rd cycle of chemotherapy (2.7 ± 2.5 mmol/kg) (Table 2). Results of non-responders showed tCho concentrations ranging from 2.05 to 5.79 mmol/kg. The MR spectra obtained in non-responders are shown on Figure 2. There was a statistically significant differ-

ence between responder and non-responder group evaluated by proton MR spectroscopy (*p*<0.01). Compared to reference healthy group tCho concentrations were increased in all cases. Receiver operating characteristic (ROC) curves analysis is presented on Figure 3.

Discussion

The assessment of treatment response following chemotherapy is one of the most important aspects of patient care, as therapeutic options and the timing of surgery may vary depending on the achievement of response. Toxicity of chemotherapeutic drugs is a serious concern and requires close

Table 1. Summary of data regarding the cases of musculoskeletal tumors

Patient no.	Pathological diagnosis		Location
	Bone tumor	Soft tissue tumor	
1	Osteosarcoma		tibia
2	Ewing sarcoma		femur
3		schwannoma	forearm
4	Osteosarcoma		femur
5	Osteosarcoma		humerus
6	Ewing sarcoma		femur
7	Osteosarcoma		tibia
8		Alveolar rhabdomyosarcoma	shin
9	Ewing sarcoma		femur
10	Osteosarcoma		humerus
11	Ewing sarcoma		femur
12	Osteosarcoma		femur
13	Osteosarcoma		femur
14	Ewing sarcoma		femur
15	Ewing sarcoma		femur
16		Alveolar rhabdomyosarcoma	thigh
17	Osteosarcoma		scapula
18	Osteosarcoma		femur
19	Osteosarcoma		femur
20	Osteosarcoma		fibula

Table 2. Absolute concentration of choline in responder and non-responder group obtained with 1H MRS

	Absolute concentration of choline ±SD /mmolkg ⁻¹		
	before therapy	after the 3 rd cycle	
Responder	4.7 ± 2.5	1.6 ± 2.2	<i>p</i> <0.01
Non-responder	2.9 ± 0.9	2.7 ± 2.5	

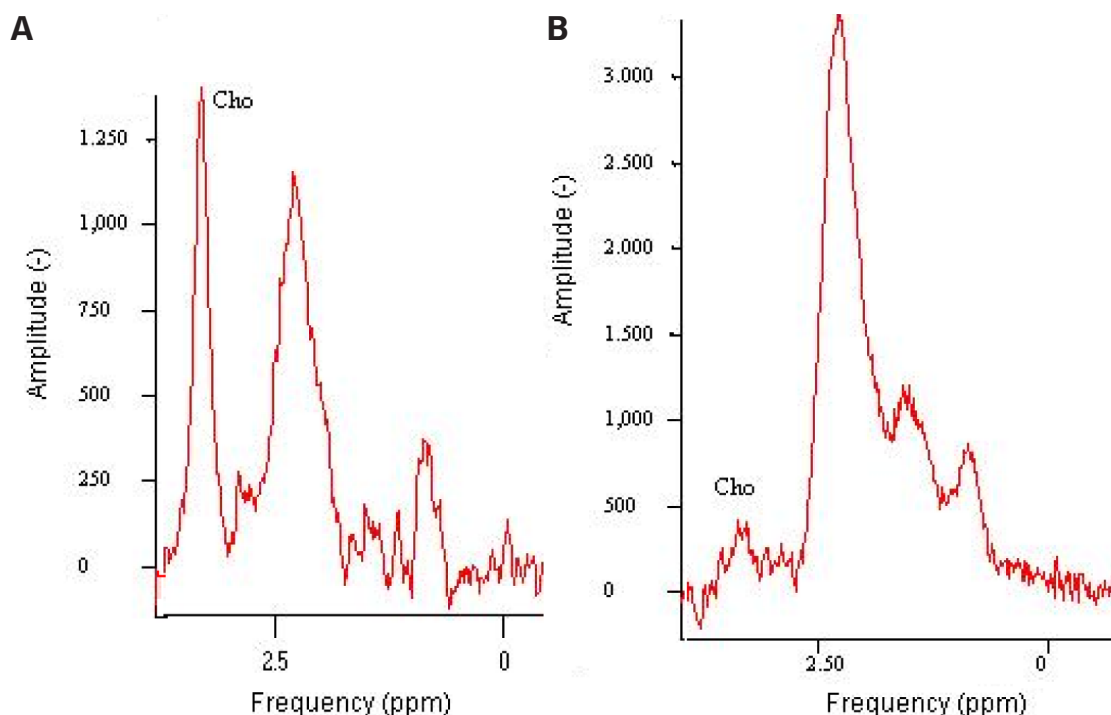


Figure 1. 1H MR spectra in a patient with diagnosed musculoskeletal tumor before (A) and after the 3rd cycle (B) of chemotherapy. From (B) spectra there is evidence of decreased Cho concentration.

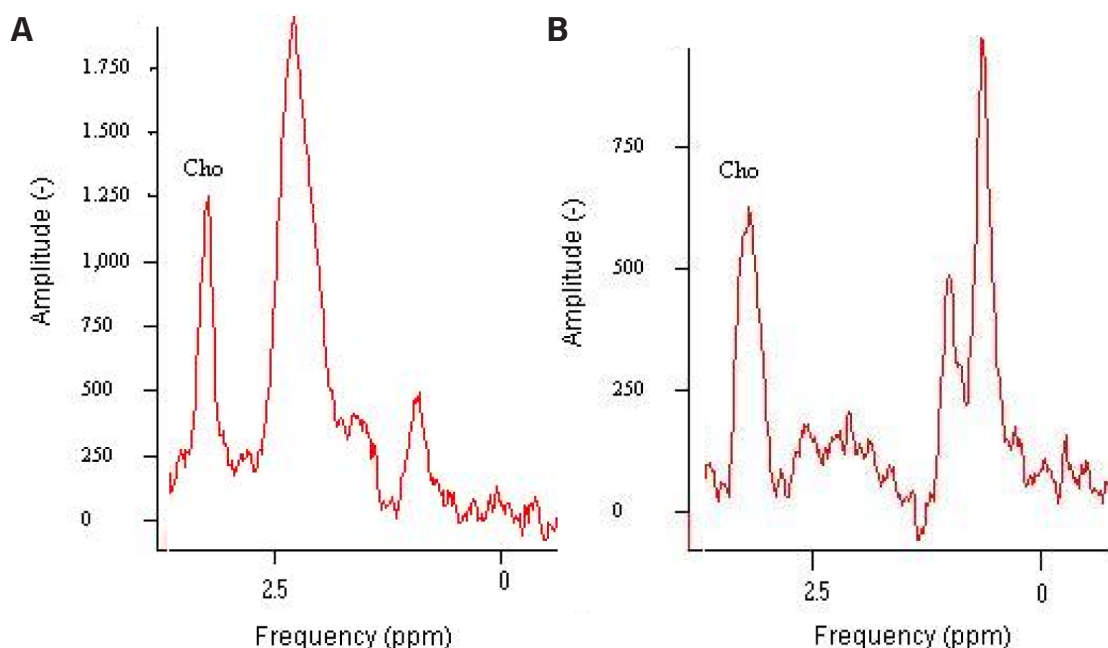


Figure 2. 1H MR spectra in a patient with musculoskeletal tumor before (A) and after the 3rd cycle (B) of chemotherapy. It can be seen that after chemotherapy Cho concentration is similar.

monitoring of the response of patients. Nearly 30-40% of patients do not respond to chemotherapeutic drugs or show partial response [21-24]. Early prediction of treatment response may avoid the exposure of these patients to serious side effects. We have documented earlier the tumor response in soft tissue and bone tumor patients undergoing neoadjuvant chemotherapy using single-voxel 1H-

MRS using presence or absence of tCho [25,26]. In this study, patients who were objective responders had a lower tCho level than did patients who were non-responders after chemotherapy. All patients who were non-responders had either no change or a higher tCho level.

It is well known that Cho is a precursor of acetylcholine and a component of the phospholipid

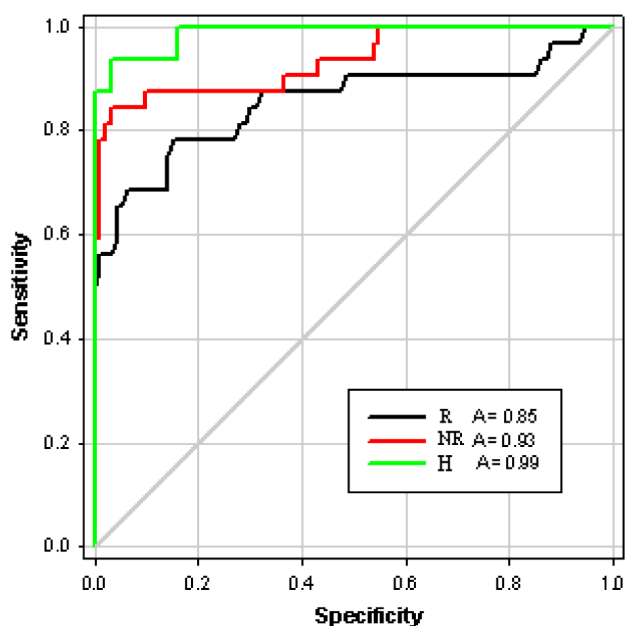


Figure 3. Results of receiver operating characteristics (ROC) analysis of characterization of musculoskeletal lesions on the basis of absolute quantitative metrics. Graphs show ROC curves generated in responder (R) (black line), non-responder (NR) (red line) and in healthy (H) group (green line). Areas under each curve are large (R, 0.85; NR, 0.93, H, 0.99), which are highly sensitive and relatively specific.

metabolism of cell membranes. The Cho peak visible at 3.2 ppm contains contributions from glycerophosphocholine, phosphocholine and choline, all compounds that are involved in the synthesis and degradation of cell membranes. Therefore, increased Cho likely reflects increased membrane synthesis or an increased number of cells, both conditions that are seen in malignant tumors which may be the reason why non-responders showed higher tCho concentration. For MSK lesions, Wang et al. showed that choline could be reliably detected in large malignant bone and soft tissue tumors using single-voxel MR spectroscopy at 1.5 T [19]. Fayad et al. showed that choline could be detected in malignant skeletal sarcomas using the multivoxel technique at 1.5 T [17,18]. Other studies have shown false-positive Cho peaks in benign giant cell tumors of bone and a variety of other inflammatory or benign neoplastic processes [12]. Because a subset of benign lesions is known to contain Cho, there has been a focus on improving quantitative assessment of the Cho level within MSK lesions with the aim of enhancing specificity. Relative quantification methods including measurement of peak ratios between metabolites and between a metabolite and the background noise level showed that good discrimination between

malignant and benign lesions can be achieved. The preliminary data from this study revealed that Cho content may correlate with histologic grade.

In our study we used absolute quantification of Cho of the MSK system with modification of previously described methods of Cho quantification for evaluation of lesions in the brain and breast, a robust method of measuring absolute Cho concentration within the MSK system with water as an internal reference compound [27-31]. A key assumption underlying this quantification method is that the water content is constant between voxels, lesions, and patients [32-35]. To our knowledge the current study is the first to report the absolute quantification of tCho using water as an internal reference compound at 1.5 T in the MSK system.

It is expected that quantitative 1H MR spectroscopy will not only improve the accuracy of MRI in depicting MSK and soft tissue tumors, but as shown here, it may be used with MRI to assess response in the course of treatment. These promising findings were obtained in a small group of patients, and, thus, a prospective study with larger patient cohorts is needed. Nevertheless, the tCho concentration measurements were reproducible. The etiology of the observed inter-individual variation in Cho concentration cannot be deciphered from this study. Our intention for this study was primarily to establish the feasibility of this quantification method, validating and implementing it for determining Cho concentration in the MSK system at 1.5T.

Conclusions

As a tool for studying sources of physiologic and pathologic variability, MRS is advantageous as a non-invasive measure of Cho concentration in MSK pathology, particularly with potential application to MSK lesion characterization and determination of therapeutic response. For future investigation, multiple avenues of studies are warranted, including alternative MRS quantitation schemes for the MSK system. A larger study may also provide information about the possibility of using MR spectroscopy to predict when a patient is expected to have a pathologic complete response, compared to histological necrosis findings. However, more patients need to be studied to obtain a cut-off value of tCho concentration to differentiate responders from non-responders.

Conflict of interests

The authors declare no conflict of interests.

References

- Li Y, Ji F, Liang Y, Zhao T, Xu C. Correlation analysis of expressions of PTEN and p53 with the value obtained by magnetic resonance spectroscopy and apparent diffusion coefficient in the tumor and the tumor adjacent area in magnetic resonance imaging for glioblastoma. *JBUON* 2018;23:391-7.
- Miller SL, Hoffer FA. Malignant and benign bone tumors. *Radiol Clin North Am* 2001;39:673-99.
- Coindre JM. Grading of soft tissue sarcomas: review and update. *Arch Pathol Lab Med* 2006;130:1448-53.
- Coindre JM, Terrier P, Bui NB et al. Prognostic factors in adult patients with locally controlled soft tissue sarcoma. A study of 546 patients from the French Federation of Cancer Centers Sarcoma Group. *J Clin Oncol* 1996;14:869-77.
- Skubitz KM, D'Adamo DR. Sarcoma. *Mayo Clin Proc* 2007;82:1409-32.
- Yang J, Frassica FJ, Fayad L, Clark DP, Weber KL. Analysis of Nondiagnostic Results after Image guided Needle Biopsies of Musculoskeletal Lesions. *Clin Orthop Relat Res* 2010;468:3103-11.
- De Schepper AM, De Beuckeleer L, Vandevenne J, Somville J. Magnetic resonance imaging of soft tissue tumors. *Eur Radiol* 2000;10:213-23.
- He Q, Xu RZ, Shkarin P et al. Magnetic resonance spectroscopic imaging of tumor metabolic markers for cancer diagnosis, metabolic phenotyping, and characterization of tumor microenvironment. *Dis Markers* 2003;19:69-94.
- Bhujwalla ZM, Artemov D, Ballesteros P, Cerdan S, Gillies RJ, Solaiyappan M. Combined vascular and extracellular pH imaging of solid tumors. *NMR Biomed* 2002;15:114-9.
- Gillies RJ, Bhujwalla ZM, Evelhoch J et al. Applications of magnetic resonance in model systems: tumor biology and physiology. *Neoplasia* 2000;2:139-51.
- Chenevert TL, Meyer CR, Moffat BA et al. Diffusion MRI: a new strategy for assessment of cancer therapeutic efficacy. *Mol Imaging* 2002;1:336-43.
- Fadul D, Fayad LM. Advanced modalities for the imaging of sarcoma. *Surg Clin North Am* 2008;88:521-37.
- Exton JH. Signaling through phosphatidylcholine breakdown. *J Biol Chem* 1990;265:1-4.
- Sostman HD, Prescott DM, Dewhirst MW et al. MR imaging and spectroscopy for prognostic evaluation in soft tissue sarcomas. *Radiology* 1994;190:269-75.
- Fayad LM, Barker PB, Bluemke DA. Molecular characterization of musculoskeletal tumors by proton MR spectroscopy. *Semin Musculoskelet Radiol* 2007;11:240-5.
- Fayad LM, Barker PB, Jacobs MA et al. Characterization of musculoskeletal lesions on 3-T proton MR spectroscopy. *AJR Am J Roentgenol* 2007;188:1513-20.
- Fayad LM, Bluemke DA, McCarthy EF, Weber KL, Barker PB, Jacobs MA. Musculoskeletal tumors: use of proton MR spectroscopic imaging for characterization. *J Magn Reson Imaging* 2006;23:23-8.
- Fayad LM, Salibi N, Wang X et al. Quantification of muscle choline concentrations by proton MR spectroscopy at 3 T: technical feasibility. *AJR Am J Roentgenol* 2010;194:W73-W9.
- Wang CK, Li CW, Hsieh TJ, Chien SH, Liu GC, Tsai KB. Characterization of bone and soft-tissue tumors with in vivo 1H MR spectroscopy: initial results. *Radiology* 2004;232:599-605.
- The ESMO/European Sarcoma Network Working Group. Soft tissue and visceral sarcomas: ESMO Clinical Practice Guidelines for diagnosis, treatment and follow-up. *Ann Oncol* 2014;25 (Suppl 3):102-12.
- Schuetze SM, Baker LH, Benjamin RS, Benjamin RS, Canetta R. Selection of response criteria for clinical trials of sarcoma treatment. *Oncologist* 2008;13 (Suppl 2):32-40.
- Jaffe CC. Response assessment in clinical trials: implications for sarcoma clinical trial design. *Oncologist* 2008;13(Suppl 2):14-8.
- Stacchiotti S, Collini P, Messina A et al. High-grade soft-tissue sarcomas: tumor response assessment--pilot study to assess the correlation between radiologic and pathologic response by using RECIST and Choi criteria. *Radiology* 2009;251:447-56.
- Liu Q, Li A, Sun S, Luo R, Chen F. The true role of mRECIST guideline: does it really estimate viable tumor or merely improves accuracy in hepatocellular carcinoma response evaluation. *JBUON* 2014;19:398-405.
- Aboagye EO, Bhujwalla ZM. Malignant transformation alters membrane choline phospholipid metabolism of human mammary epithelial cells. *Cancer Res* 1999;59:80-4.
- Egmont-Petersen M, Hogendoorn PC, van der Geest RJ et al. Detection of areas with viable remnant tumor in postchemotherapy patients with Ewing's sarcoma by dynamic contrast-enhanced MRI using pharmacokinetic modeling. *Magn Reson Imaging* 2000;18:525-35.
- Gill SS, Thomas DG, Van Bruggen N et al. Proton MR spectroscopy of intracranial tumours: in vivo and in vitro studies. *J Comput Assist Tomogr* 1990;14:497-504.
- Glunde K, Artemov D, Penet MF, Jacobs MA, Bhujwalla ZM. Magnetic resonance spectroscopy in metabolic and molecular imaging and diagnosis of cancer. *Chem Rev* 2010;110:3043-59.
- Roebuck JR, Cecil KM, Schnall MD, Lenkinski RE. Human breast lesions: characterization with proton MR spectroscopy. *Radiology* 1998;209:269-75.
- Kurhanewicz J, Vigneron DB, Nelson SJ et al. Citrate as an in vivo marker to discriminate prostate cancer from benign prostatic hyperplasia and normal prostate peripheral zone: detection via localized proton spectroscopy. *Urology* 1995;45:459-66.
- Merchant TE, Thelissen GR, de Graaf PW, Nieuwenhuizen CW, Kievit HC, Den Otter W. Application of a mixed imaging sequence for MR imaging characterization of human breast disease. *Acta Radiol* 1993;34:356-61.
- Wu JS, Hochman MG. Soft-tissue tumors and tumor-like lesions: a systematic imaging approach. *Radiology* 2009;253:297-316.

-
33. Kawai A, Sugihara S, Kunisada T, Uchida Y, Inoue H. Imaging assessment of the response of bone tumors to preoperative chemotherapy. *Clin Orthop Relat Res* 1997;337:216-25.
 34. Machann J, Stefan N, Schick F. (1)H MR spectroscopy of skeletal muscle, liver and bone marrow. *Eur J Radiol* 2008;67:275-84.
 35. Boesch C, Machann J, Vermathen P, Schick F. Role of proton MR for the study of muscle lipid metabolism. *NMR Biomed* 2006;19:968-88.