

ORIGINAL ARTICLE

Management and treatment of children with medulloblastoma in Serbia, a middle-income country

Jelena Bokun¹, Danica Grujicic^{2,3}, Milica Skender-Gazibara^{3,4}, Lejla Paripovic⁵, Tatjana Pekmezovic^{3,6}, Darija Kusic-Tepavcevic^{3,6}, Vesna Ilic⁵, Savo Raicevic⁷, Dragana Stanic¹, Ivana Miskovic¹, Milan Saric¹, Marina Nikitovic^{1,3}

¹Institute for Oncology and Radiology of Serbia, Clinic for Radiation Oncology, Belgrade, Serbia; ²Clinic of Neurosurgery, Clinical Center of Serbia, Belgrade, Serbia; ³Faculty of Medicine, University of Belgrade, Belgrade, Serbia; ⁴Institute of Pathology, Faculty of Medicine, University of Belgrade, Belgrade, Serbia; ⁵Institute for Oncology and Radiology of Serbia, Department for Pediatric Oncology, Belgrade, Serbia; ⁶Institute of Epidemiology, Faculty of Medicine, University of Belgrade, Belgrade, Serbia; ⁷Department for Pathology, Clinical Center of Serbia, Belgrade, Serbia

Summary

Purpose: The aim of this study was to present the management and treatment of children with medulloblastoma in Serbia, a middle-income country (MIC).

Methods: The data of 87 children diagnosed with medulloblastoma and treated at the Institute for Oncology and Radiology of Serbia from 2000 to 2013 were analyzed.

Results: The children's median age was 8.3 years (range 2.5-17.3). Eighty-two (94.2%) were 3 years or older. Sixty-two (71.3%) patients had stage M0 medulloblastoma, 12 (13.8%) had stage M1 and 13 (14.9%) had stage M2 or M3. As of October 2015, 51 (58.6%) patients were alive and 31 (35.6%) had died. Five patients (5.7%) were lost to follow-up. Twenty-six patients relapsed. The median follow-up time was 58 months (range 4-187). Mean overall survival

(OS) was 76.4% at 3 years, 66.2% at 5 years and 59.2% at 10 years. Mean disease-free survival (DFS) was 75.8% at 3 years, 62.8% at 5 years and 56.6% at 10 years. Mean OS of stage M0 patients was 86.4% at 3 years, 74% at 5 years and 63.1% at 10 years. The OS of stage M1, M2 and M3 patients combined was 48.9% at 3 years, 44.0% at 5 years and 37.7% at 10 years.

Conclusion: In Serbia, a MIC, it is possible to achieve good treatment results in children with medulloblastoma using international treatment guidelines and recommendations, available resources and an experienced team of professionals dedicated to pediatric neurooncology.

Key words: children, medulloblastoma, survival, treatment

Introduction

Medulloblastoma is the most common malignant brain tumor in children, accounting for approximately 20% of all childhood brain cancers [1-4]. Standard treatment for this disease consists of surgery, craniospinal radiation and chemotherapy [2,5]. The use of these modalities in modern therapeutic protocols has resulted in an OS rate greater than 70% in children aged 3 years or older [2,5,6].

The mainstay of treatment is a multi-disciplinary team with adequate neuroradiology, neurosurgery, pathology, radiotherapy (RT) and chemotherapy resources [1,3,7,8]. Although improved outcomes and cure rates in children with medulloblastomas have been observed in high-income countries (HIC), they are not observed in low- and middle-income countries (MIC) [3,7].

Herein, we present the management and treatment results of children with medulloblastoma in Serbia, an MIC.

Methods

The data of 87 pediatric patients with medulloblastoma who were treated at the Institute for Oncology and Radiology of Serbia between January 2000 and December 2013 were analyzed. The inclusion criterion was histopathologic diagnosis of medulloblastoma with no previous history of malignant disease. The majority of the patients were diagnosed and operated upon at the Clinic of Neurosurgery, Clinical Center of Serbia, in Belgrade. Histopathologic examination was performed at the Institute of Pathology, Faculty of Medicine, University of Belgrade, Belgrade, in collaboration with the Department of Pathology Clinical Center of Serbia, Belgrade. All the patients underwent RT and chemotherapy at the Institute for Oncology and Radiology of Serbia, Belgrade. These institutions are national referral centers for the diagnosis and treatment of childhood brain tumors. Any patient with medulloblastoma is admitted to these hospitals to confirm the diagnosis and develop a treatment strategy [9-12].

Treatment of all of the patients began with surgery, which was classified as gross total resection if there was no evidence of residual disease, near-total resection if up to 1.5 cm³ residual disease remained and subtotal resection if more than 1.5 cm³ residual disease remained. The extent of resection was based on the neurosurgeons' operative notes and computed tomography (CT) or magnetic resonance imaging (MRI) results. The Chang classification [13] was used to stage metastatic disease: stage M0, no evidence of metastases; M1, microscopic metastases in the cerebrospinal fluid (CSF); M2, macroscopic, intracranial leptomeningeal metastases; M3, intraspinal leptomeningeal metastases; and M4, metastases outside the cerebrospinal axis. In most of the patients, spinal extension was evaluated via cervical, thoracic and lumbar MRI and lumbar CSF cytology.

Histopathologic classification of the tumor was performed according to the 2000/2007 WHO criteria [14-16]. After completion of the appropriate staging procedures, all children were treated with a combination of RT and chemotherapy. Until 2006, patients received two-dimensional RT (2D-RT). Craniospinal irradiation was performed with conventionally fractionated doses of 30-36 Gy and boosted to 50-56 Gy in the posterior fossa. Standard fractionation in the pediatric population is defined as daily fractions in the range of 1.5-1.8 Gy, 5 days a week, depending on patient age. Starting in 2006, three-dimensional conformal RT (3D-CRT) was introduced. Patients received risk-adapted craniospinal RT at doses of 23.4 Gy for average-risk disease and 36 Gy for high-risk disease, with a boost to the posterior fossa of 50.4-55.8 Gy.

A combination regimen of cisplatin, lomustine (CCNU) and vincristine has been used as adjuvant chemotherapy after RT. Different treatment strategies were applied, based on patient age and the presence of

metastatic disease. For young children under 4 years of age, several regimens were used to postpone radiation. In most regimens, such as Baby brain (ESO SIOP), HIT 91, and HIT 2000, various combinations of vincristine, cisplatin, carboplatin, etoposide and cyclophosphamide were used. For patients with poor prognosis, chemotherapy and postoperative RT followed by maintenance chemotherapy were administered using different chemotherapy regimens: "8-in-one-day" regimen ("8 in 1"), Baby brain (ESO SIOP), HIT 91, and HIT 2000.

According to our protocol, after the completion of treatment, follow-up examinations were performed every 3 months during the first and second year, every 6 months in years 3 to 5, and yearly thereafter. Patient disease status was assessed via clinical examination and MRI imaging.

Statistics

Mean, median, standard deviation and range were used to describe patient demographic characteristics. The Kaplan-Meier method with 95% confidence interval (CI) was used to estimate OS and DFS.

Table 1. Patient, disease and therapy characteristics

Characteristics	Number of patients	%
Age (years)	range 2.5-17.3	median 8.3
Gender		
Male	53	60.9
Female	34	39.1
Extent of resection		
Gross total	53	60.9
Near total	22	25.3
Subtotal	12	13.8
Biopsy only	0	0
Metastatic stage		
M0	62	71.3
M1	12	13.8
M2/M3	13	14.9
Histology		
Classic	61	70.1
Nodular/desmoplastic	23	26.4
Large cell/anaplastic	3	3.4
Radiotherapy		
2D	50	57.5
3D	37	42.5
Chemotherapy		
Yes	78	89.7
No	9	10.3
Chemotherapy protocol		
Packer	35	44.9
HIT 2000	26	33.3
ESO SIOP/Baby brain	6	7.7
"8 in 1"	3	3.8
Other	8	10.3

Log-rank test and Cox model were used to test for differences between groups. p values < 0.05 were deemed statistically significant.

Results

The clinical characteristics of the 87 patients are shown in Table 1. The median patient age at the time of diagnosis was 8.3 years (range 2.5-17.3). Eighty-two patients (94.2%) were 3 years or older. The male to female ratio was 1.56. Symptoms were present for 1 to 18 months, with a median of 2 months. A delayed diagnosis was correlated with a high rate of advanced disease (p=0.043). The classic histologic variant was observed in 61 patients (70.1%), the nodular/desmoplastic variant in 23 (26.4%) patients and the large cell/anaplastic disease in 3 (3.4%) patients.

Meningeal dissemination within the sub-arachnoid space (cranial M2 or spinal M3) was

observed in 13 patients (14.9%), and the presence of tumor cells in the CSF without macroscopic disease on imaging (M1) was observed in 12 (13.8%) patients. Most of the patients (62, 71.3%) had no metastatic disease (M0). Spinal seeding was observed on spinal MRI in 68 patients (78.2%). Cytologic dissemination to the CSF was observed in 73 (83.9%) patients.

All the patients were treated with surgery. Resection was classified as gross total in 53 (60.9%) patients, near total in 22 (25.3%) patients and sub-total in 12 (13.8%) patients. No patient had biopsy alone. Postoperative MRI of the brain was used in the majority of the patients (58;66.7%). Cranial CT was used in 29 (33.3%) patients.

All the patients received craniospinal RT with a local boost to the posterior fossa. Fifty patients received 2D-RT (57.5%) and 37 (42.5%) 3D-CRT. In most cases RT was initiated within 4-6 weeks of the definitive surgery. There were no statistically

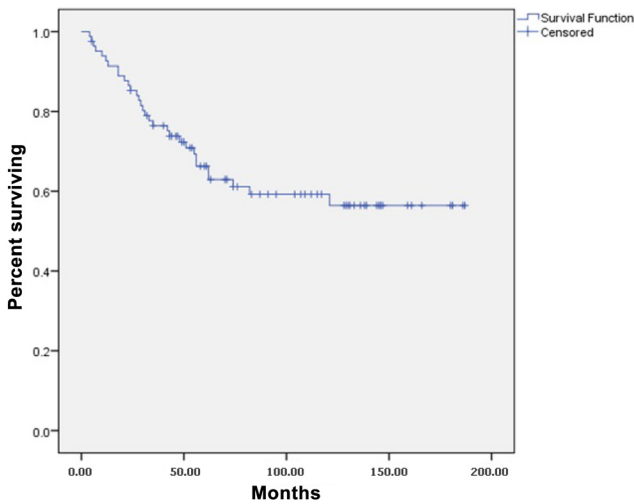


Figure 1. Overall survival in 87 patients with medulloblastoma.

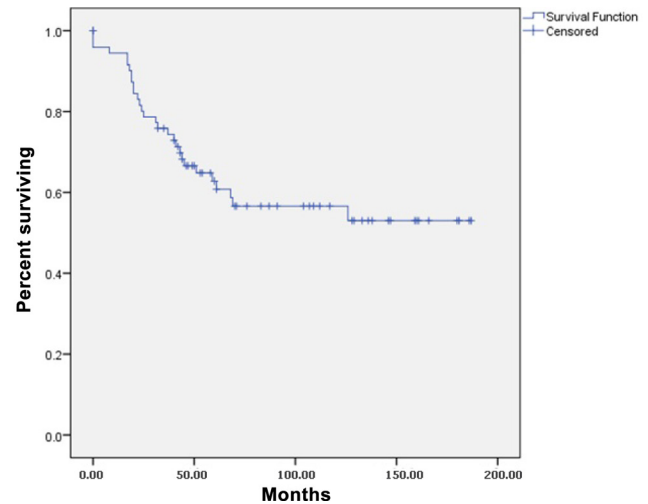


Figure 2. Disease-free survival in 87 patients with medulloblastoma.

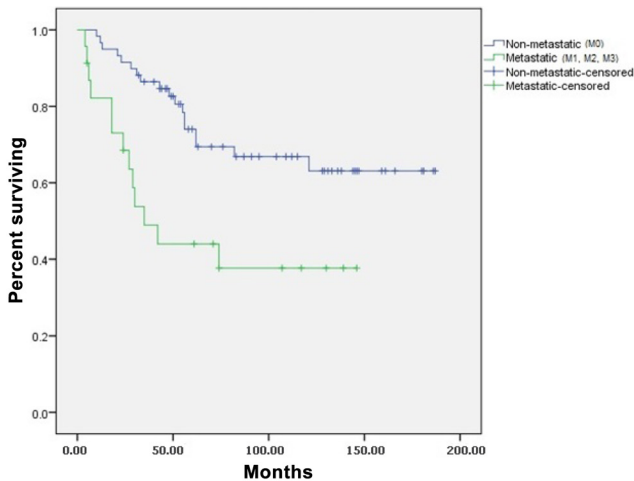


Figure 3. Overall survival by metastatic stage category (p=0.003).

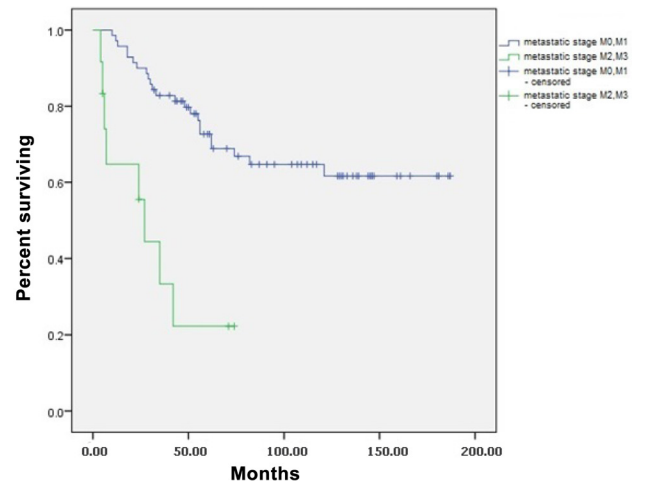


Figure 4. Disease-free survival by metastatic stage category (M0, M1 vs. M2, M3) (p<0.0001).

significant differences in OS ($p=0.531$) between the two RT techniques (2D-RT vs. 3D-CRT).

Pre-radiotherapy neoadjuvant chemotherapy followed by craniospinal RT was used in 11 (12.6%) patients. The majority of patients (73;83.9%) were treated with adjuvant platinum-based chemotherapy.

As of October 2015, 51 (58.6%) patients were alive and 31 (35.6%) had died. Five (5.7%) patients were lost to follow-up. All of the deceased patients had died due to tumor spread. Five patients with metastatic disease did not achieve remission. Twenty-six patients relapsed. Disease recurrence was observed in the posterior fossa alone in 4 patients, the posterior fossa and the brain or spine in 4 patients, and the brain or spine alone in 18 patients. Extra-neural metastases developed in one patient.

The mean and median follow-up times of the 87 children were 74.35 ± 52.3 months and 58 (range 4–187) months, respectively. OS was 76.4% at 3 years, 66.2% at 5 years and 59.2% at 10 years (Figure 1). DFS was 75.8% at 3 years, 62.8% at 5 years and 56.6% at 10 years (Figure 2). Among the patients with localized disease (M0), OS was 86.4% at 3 years, 74% at 5 years and 63.1% at 10 years. Among the patients with disseminated disease (M1, M2, M3), OS was 48.9% at 3 years, 44% at 5 years and 37.7% at 10 years. OS differed significantly ($p=0.003$) between metastatic stage groups, with better OS in patients with localized disease (M0) than patients with disseminated disease (M1, M2, M3) (Figure 3). Among the patients with Chang stage M0/M1, OS was 82.8% at 3 years, 72.7% at 5 years and 64.7% at 10 years, whereas among the patients with Chang stage M2/M3, OS was 33.3% at 3 years and 22% at 5 years. OS differed significantly ($p<0.0001$) between the patients with localized disease (M0) or microscopic metastases in the CSF (M1) and the patients with macroscopic intracranial and/or intraspinal leptomeningeal metastases (M2,M3;Figure 4).

Discussion

Brain tumors are a leading cause of cancer-related deaths in children, and medulloblastomas are the most common malignant pediatric brain tumors, accounting for approximately 40% of pediatric posterior fossa CNS tumors [6,17]. Current management strategies are based on the results of successive multicenter randomized clinical trials, including those of the North American Pediatric Oncology Group (POG), the Children's Cancer Group (CCG) and the International Society of Pediatric Oncology (SIOP) [18].

With the current standard of treatment, i.e., the maximum safe surgical resection possible followed by adjuvant craniospinal irradiation and cytotoxic platinum-based chemotherapy, the overall patient survival has reached 70% [19]. Among patients with standard-risk disease, this percentage is increased to more than 80% [20,21]. Recent case series, many of which are prospective and treated patients over the past decade, report survival rates of 85% for non-disseminated medulloblastomas and of 65-70% in high-risk patients [17,21,22]. The most effective combination of radiation therapy and chemotherapy in children older than 3 years yields long-term disease control in 80% of children with average-risk disease and in 60-70% of those with high-risk medulloblastoma [23]. Gatta et al. reported that the standard of care for children older than 3 years, comprising surgical resection, craniospinal irradiation and chemotherapy, resulted in overall cure rates of 70-75% [24,25].

In our study, which included 87 patients with medulloblastomas treated at the Institute for Oncology and Radiology of Serbia between January 2000 and December 2013, the OS was 76.4% at 3 years, 66.2% at 5 years and 59.2% at 10 years. DFS was 75.8% at 3 years, 62.8% at 5 years and 56.6% at 10 years.

Packer et al. reported that the reasons for these improved survival rates are due to improved post-operative care, earlier or better disease detection - especially with respect to disseminated disease -, more aggressive surgery, improved radiotherapeutic techniques and refinements in the timing and dosing of chemotherapy [17,21,22].

The SIOP PODC Clinical Practice Guidelines [7] state that treatment in some MICs yields better outcomes in environments where adequate surgery, RT and chemotherapy resources and educated professionals are available.

We postulated that the improved cure rates and treatment results observed are due to the following reasons: small number of delayed diagnoses, low rate of advanced disease at presentation, advances in neuro-imaging, improved staging, improvements in neurosurgical techniques, improved perioperative care, no significant delays in irradiation, RT team with experience and standard RT equipment, use of effective chemotherapy regimens and multidisciplinary approach.

In our study of 87 patients, symptoms were present for between 1 to 18 months, with a median of 2 months. These data suggest a small number of delayed diagnoses.

Postoperative MRI of the brain was used in the majority of patients (58;66.7%), whereas cranial CT was used in 29 (33.3%) patients. Spinal MRI

was performed on 68 (78.2%) patients, and CSF was assessed in 73 (83.9%) patients. From 2000 to 2013, the number of cranial CT imaging decreased, and the number of brain MRI scans increased. No patient received risk-adapted treatment without postoperative MRI of the brain and spine.

Macroscopic metastases (M2,M3) were observed in 13 (14.9%) patients and microscopic metastases (M1) were identified in 12 (13.8%). Most patients (62;71.3%) did not show metastatic disease (M0). Our data suggest a low rate of advanced disease at presentation. In our group of patients, improvements in neurosurgical techniques were evident from the following: gross total resection was achieved in 53 patients (60.9%), near-total resection in 22 (25.3%), and subtotal in 12 (13.8%) patients. No patients underwent biopsy alone.

Two recent international trials by the SIOP group revealed that delaying RT after definitive surgery by 7 weeks or more increases the risk of relapse [26,27]. In our group, the majority of RT treatments (80.3%) were initiated within 4-7 weeks of definitive surgery. There were no major delays in RT.

CT-based 3D planning has become the standard of care in HIC [7]. As of 2007, 3D-CRT has been the standard of care at the Institute for Oncology and Radiology of Serbia.

The use of adjuvant and neoadjuvant chemotherapy in the treatment of children with medulloblastomas is now well established [7]. In our group, different treatment strategies were applied based on patient age and metastatic disease status according to standard recommendations.

Metastatic (M) stage had statistically significant impact on OS and DFS, with better results in patients with localized disease (M0) than in those with disseminated disease (M1, M2, and M3).

The OS of standard-risk patients at 5 years has improved to 70-80% with current surgical, RT and chemotherapy approaches [18,21]. More than 80% of patients with standard-risk disease are cured with current therapeutic approaches in the treatment of medulloblastoma: maximum safe surgical resection of the tumor, craniospinal irradiation, irradiation boost around the primary tumor and adjuvant chemotherapy [20].

Gajjar et al. reported the results of a prospective multicenter trial (St Jude Medulloblastoma-96). Among average-risk patients, 5-year OS was 85%, and event-free survival (EFS) was 83% [5].

Taylor et al. published the results of a large multicenter randomized study (SIOP/UKCCSG PNET 3) of non-metastatic medulloblastoma. OS at 3 and 5 years was 79.5 and 70.7%, respectively, and EFS at 3 and 5 years was 71.6 and 67.0%, respectively [18].

In our study, the OS of patients with localized disease (M0) was 86.4% at 3 years, 74% at 5 years and 63.1% at 10 years. The DFS of patients with localized disease (M0) was 79.4% at 3 years and 67.4% at both 5 and 10 years.

The presence of meningeal dissemination at the time of diagnosis is a strongly negative prognostic factor. Patients with metastasis constitute a high-risk group with poor survival rates. The survival rate of patients with disseminated disease at diagnosis does not exceed 30-40% [28-30].

The European phase III clinical trial SIOP/UK-CSG PNET-3, in which high-risk medulloblastoma patients were treated with neoadjuvant chemotherapy (Preradiotherapy chemotherapy) followed by RT, resulted in a 5-year progression-free survival (PFS) rate of less than 40% [18]. Furthermore, metastatic patients showed significantly lower PFS than standard-risk patients, with rates of 57% and 40% in M1 and M2 stage patients, respectively [31,32].

Freeman et al. and Zeltzer et al. reported 5-year OS rates of 55-76% [33,34]. Patient series performed over the past decade, many of which were prospective, describe survival rates of 65-70% for high-risk patients [22].

In the randomized prospective multicenter trial HIT 91, the 3-year PFS of M1 patients was 65% and that of M2-M3 patients was 30% [35].

A Children Oncology Group study reported that for patients with high-risk disease, the addition of chemotherapy to a high dose of craniospinal irradiation and adjuvant chemotherapy might cure approximately 65% of the patients [20,36]. The best outcome reported for high-risk medulloblastoma patients, a 5-year EFS of 70%, was achieved with craniospinal irradiation with a boost to the primary tumor site after maximum surgical resection followed by dose-intensive chemotherapy with autologous peripheral blood stem cell rescue [5].

In the treatment of our patients with disseminated disease (M1, M2, M3), we observed an OS of 48.9% at 3 years, of 44% at 5 years, and of 37.7% at 10 years. Among the M0/M1 patients, OS was 82.8% at 3 years, 72.7% at 5 years and 61.7% at 10 years. Among the M2/M3 patients with macroscopic metastases, OS was 33.3% at 3 years and 22.2% at 5 years. This poorer outcome of children with metastatic medulloblastoma is consistent with previous reports [18,28-30,35]. Considering the outcomes observed for high-risk patients, the first target of treatment is to improve survival.

Conclusion

The treatment of childhood medulloblastoma

has yielded improved survival in HIC. Seventy to eighty percent of children with this disease are cured. In Serbia, a MIC, the treatment results for childhood medulloblastoma are quite promising. The findings suggest that good outcomes can be obtained with management based on current reference guidelines and treatment recommendations, available resources and an experienced team of professionals dedicated to pediatric neurooncology.

Conflict of interests

The authors would like to thank Ana Ivkovic, senior librarian at the Institute for Oncology and Radiology of Serbia, for her assistance with the preparation of this manuscript.

Conflict of interests

The authors declare no conflict of interests.

References

- Von Hoff K, Rutkowski S: Medulloblastoma. *Curr Treat Options Neurol* 2012;14:416-26.
- Gajjar AJ, Robinson GW. Medulloblastoma-translating discoveries from the bench to the bedside. *Nat Rev Clin Oncol* 2014;11:714-22.
- Gajjar A, Finlay JL. The Management of Children and Adolescents With Medulloblastoma in Low and Middle Income Countries. *Pediatr Blood Cancer* 2015;62:549-50.
- Pekmezovic T, Golubicic I, Tepavcevic DK et al. Incidence of primary central nervous system tumors among children in Belgrade (Serbia), 1991-2004. *Pediatr Hematol Oncol* 2009;26:332-7.
- Gajjar A, Chintagumpala M, Ashley D et al. Risk-adapted craniospinal radiotherapy followed by high-dose chemotherapy and stem-cell rescue in children with newly diagnosed medulloblastoma (St.Jude Medulloblastoma-96): long term results from a prospective, multicentre trial. *Lancet Oncol* 2006;7:813-20.
- Partap S, Fisher PG. Update on new treatments and developments in childhood brain tumors. *Curr Opin Pediatr* 2007;19:670-4.
- Parkes J, Hendricks M, Ssenyonga P et al. SIOP PODC Adapted Treatment Recommendations for Standard-Risk Medulloblastoma in Low and Middle Income Settings. *Pediatr Blood Cancer* 2015;62:553-64.
- Nikitovic M, Golubicic I. Treatment options for childhood medulloblastoma. *Military Medical and Pharmaceutical Journal of Serbia (Vojnosanit Pregl)* 2013;70:773-7.
- Nikitovic M, Stanic D, Pekmezovic T et al. Pediatric glioblastoma: a single institution experience. *Child's Nerv System* 2016;32:97-103.
- Nikitovic M, Bokun J, Paripovic L, Golubicic I, Grujicic D, Sopta J. Bone Metastases in Medulloblastoma-Single Institution Experience. *Pediatr Hematol Oncol* 2013;30:80-91.
- Nikitovic M, Golubicic I, Pekmezovic T, Grujicic D, Plesinac-Karapandzic V. Outcome of childhood brain tumors in Serbia. *JBUON* 2011;16:290-6.
- Bokun J, Klikovac T, Vujic D, Nikitovic M. The role of the psychologist in the preparation of young children for radiotherapy.short review. *JBUON* 2011;16:561 -4.
- Chang CH, Housepian EM, Herbert C Jr. An operative staging system and a megavoltage radiotherapeutic technique for cerebellar medulloblastomas. *Radiology* 1969;93:1351-9.
- Eberhart CG, Kepner JL, Goldthwaite PT et al. Histopathologic Grading of Medulloblastomas A Pediatric Oncology Group Study. *Cancer* 2002;94:552-60.
- Kleiheus P, Cavenee WK. WHO/IARC Classification of Tumours (2000). Tumours of the nervous system. Pathology and Genetics. WHO/IARC Classification of Tumours, 3th edition. Volume 1. Lyon: IARC Press, 2000.
- Louis DN, Ohgaki H, Wiestler OD, Cavenee WK. WHO Classification of Tumours of the Central Nervous System. WHO/IARC Classification of Tumours. 4th Edition, Volume 1. Lyon: IARC Press, 2007.
- Packer RJ, Sutton LN, Elterman R et al. Outcome for children with medulloblastoma treated with radiation and cisplatin, CCNU and vincristine chemotherapy. *J Neurosurg* 1994;81:690-98.
- Taylor RE, Bailey CC, Robinson K, Weston CL, Ellison D, Ironside J, Lucraft H, Gilbertson R, Tait DM, Walker DA, Pizer BL, Imeson J, Lashford LS; International Society of Paediatric Oncology; United Kingdom Children's Cancer Study Group. Results of a randomized study of preradiation chemotherapy versus radiotherapy alone for nonmetastatic medulloblastoma: The International Society of Paediatric Oncology/ United Kingdom Children's Cancer Study Group PNET-3 Study. *J Clin Oncol* 2003;21:1581-91.
- Skowron P, Ramaswamy V, Taylor DM. Genetic and molecular alterations across medulloblastoma subgroups. *J Mol Med* 2015;93:1075-84.
- Gajjar A, Packer RJ, Foreman NK, Cohen K, Haas-Kogan D, Merchant TE; COG Brain Tumor Committee. Review Children's Oncology Group's 2013 Blueprint for Research: Central Nervous System Tumors. *Pediatr Blood Cancer* 2013;60:1022-6.
- Packer RJ, Goldwein J, Nicholson HS et al. Treatment of children with medulloblastoma with reduced dose craniospinal radiation therapy and adjuvant chemotherapy: A Children Cancer Group Study. *J Clin Oncol* 1999;17:2127-36.
- Packer RJ. Progress and challenges in childhood brain tumors. *J Neuro-Oncology* 2005;75:239-42.

23. Kun LE, MacDonald S, Tarbell NJ. Tumors of the posterior fossa and the spinal canal. In: Halperin EC, Constine LS, Tarbell NJ, Kun LE (Eds): *Pediatric Radiation Oncology* (5th Edn). Wolters Kluwer/Lippincott Williams & Wilkins, Philadelphia 2011, pp 53-84.
24. Gatta G, Zigon G, Capocaccia R et al. EURO CARE Working Group. Survival of European children and young adults with cancer diagnosed 1995-2002. *Eur J Cancer* 2009;45:992-1005.
25. Gatta G, Botta L, Rossi S et al. Childhood cancer survival in Europe 1999-2007: Results of EURO CARE-5 - A population-based study. *Lancet Oncol* 2014;15:35-47.
26. Lannering B, Rutkowski S, Doz F et al. Hyperfractionated versus conventional radiotherapy followed by chemotherapy in standard-risk medulloblastoma. Results from the randomized multicenter HIT-SIOP PNET 4 trial. *J Clin Oncol* 2012;30:3187-93.
27. Taylor RE, Bailey CC, Robinson KJ et al. Impact of radiotherapy parameters on outcome in the International Society of Pediatric Oncology/United Kingdom Children's Cancer Study Group PNET 3 study of preradiotherapy chemotherapy for M0-M1 medulloblastoma. *Int J Radiat Oncol Biol Phys* 2004;58:1184-93.
28. Urbeuraga A, Navajas A, Burgos J, Pijoan JI. A review of clinical and histological features of Spanish paediatric medulloblastomas during the last 21 years. *Childs Nerv Syst* 2016;22:466-74.
29. Rutkowski S, Bode U, Deinlein F, Ottensmeier H, Warmuth-Metz M, Soerensen N. Treatment of early childhood medulloblastoma by postoperative chemotherapy alone. *N Engl J Med* 2005;352:978-86.
30. Jenkin D, Al Shabanah M, Al Shail E et al. Prognostic factors for medulloblastoma. *Int J Radiat Oncol Biol Phys* 2000;47:573-84.
31. Taylor RE, Bailey CC, Robinson KJ et al. Outcome of patients with metastatic (M2-M3) medulloblastoma treated with SIOP/ UKCCSG PNET 3 chemotherapy. *Eur J Cancer* 2005;41:727-34.
32. Massimino M, Biassoni V, Gandola L et al. Childhood medulloblastoma. *Crit Rev Oncol Hematol* 2016;105:35-51.
33. Freeman CR, Taylor RE, Kortmann RD, Carrie C. Radiotherapy for medulloblastoma in children: a perspective on current international clinical research efforts. *Med Pediatr Oncol* 2002;39:99-108.
34. Zeltzer PM, Boyett JM, Finlay JL et al. Metastasis stage, adjuvant treatment and residual tumor are prognostic factors for medulloblastoma in children: conclusions from the Children's Cancer Group 921 randomized phase III study. *J Clin Oncol* 1999;17:832-45.
35. Kortmann RD, Kuhl J, Timmermann B et al. Postoperative neoadjuvant chemotherapy before radiotherapy as compared to immediate radiotherapy followed by maintenance chemotherapy in the treatment of medulloblastoma in childhood: results of the German prospective randomized trial HIT 91. *Int J Radiat Oncol Biol Phys* 2000;46:269-79.
36. Jakacki RI, Burger PC, Zhou T et al. Outcome of children with metastatic medulloblastoma treated with carboplatin during craniospinal radiotherapy. A Children's Oncology Group Phase I/II Study. *J Clin Oncol* 2012;30:2648-53.