



CODEN [USA]: IAJPB

ISSN: 2349-7750

INDO AMERICAN JOURNAL OF  
**PHARMACEUTICAL SCIENCES**

Available online at: <http://www.iajps.com>

Research Article

**COMPARATIVE ANALYSIS OF ENDOSCOPIC RETROGRADE  
CHOLANGIOPANCREATOGRAPHY TREATMENT METHODS FOR  
HEPATIC ECHINOCOCCOSIS INVASION IN BILIARY TRACT  
WITHOUT JAUNDICE**

<sup>1</sup>Dr. Naveed Ashraf Khan, <sup>2</sup>Pro. Ren Li, <sup>2</sup>Pro. Fan Hai Ning, <sup>2</sup>Pro Wang hai Jiu, <sup>2</sup>Dr. Wang Zhexin,  
<sup>2</sup>Dr. Gong Fu Cheng

<sup>1</sup>Qinghai University Affiliated Hospital, City Xining, China, <sup>2</sup>Qinghai University Affiliated Hospital, City Xining, Qinghai, China.

Article Received: January 2019

Accepted: February 2019

Published: March 2019

**Abstract:**

**Objectives:** To investigate the clinical effect of radical resection of ERCP (Endoscopic retrograde cholangiopancreatography) in patients with hepatic Echinococcosis and biliary tract without jaundice, the research was carried out in Qinghai province at Qinghai university Affiliated hospital. The objectives of study were to assess Comparative analysis of ERCP treatment methods for hepatic Echinococcosis invasion and biliary tract without jaundice

**Methodology:** Analysis of 29 cases of hepatic bubble hydatid invasion and biliary tract without jaundice treated by our department from January 2015 to March 2018, according to the different treatment methods, 9 cases (experimental group) and radical resection of patients with ERCP+ENBD were divided into 20 cases with radical resection of two-stage lesions (Control group), the operation time of each group, the amount of blood loss during operation, the biliary leakage of postoperative complications, the average length of hospital stay, the average hospitalization cost, the median time of carrying peritoneal drainage tube after operation, preoperative, 3 days after operation, 7 days ALT, AST, ALP, and other liver work indexes were analyzed.

**Results:** There was no significant difference between the two groups in the average length of hospital stay, average hospitalization cost, general data (sex, age, location of lesion, size of lesion, etc.), liver function index before and after operation (AST, albumin, PT, INR, 3 days after Operation ALP, AST, albumin, PT and INR, etc.) (0.05). However, there was a statistically significant difference between postoperative biliary complications (biliary leakage) and the median time of postoperative drainage tube (P<0.05).

**Conclusion:** For hepatic bubble hydatid invasion and biliary tract without jaundice, the first stage of ERCP+ENBD, two-stage lesion radical resection can significantly reduce the occurrence of postoperative biliary complications (biliary leakage), and ERCP+ENBD has the advantages of minimally invasive, simple, safe surgical technique in liver resection patients

**Key Words:** ERCP ENBD Jaundice Hydatid disease hepatic Echinococcosis with biliary tract invasion.

**Corresponding author:****Dr. Naveed Ashraf Khan,**

Qinghai University Affiliated Hospital, City Xining, China.

QR code



Please cite this article in press Naveed Ashraf Khan et al., *Comparative Analysis of Endoscopic Retrograde Cholangiopancreatography Treatment Methods for Hepatic Echinococcosis Invasion in Biliary Tract without Jaundice.*, Indo Am. J. P. Sci, 2019; 06(03).

**INTRODUCTION:**

Cystic Echinococcosis (CE) and alveolar Echinococcosis (AE) is a zoonotic disease which belong to same parasitic family. Cystic Echinococcosis caused by Echinococcosis Granulosis and alveolar Echinococcosis caused by Echinococcosis Multicularis. Regarding clinical manifestation both diseases have different prognosis. Echinococcosis is a rare and life-threatening zoonotic disease caused by multiple arial Echinococcosis infection in the human body [1], after eating food that has been infected with Echinococcosis by humans, growth and development in the gastrointestinal tract, through intestinal blood circulation and lymphatic circulation, through the portal vein invasion of the liver, the formation of hepatic hydatid disease.

The Echinococcosis grows in the liver, continues to invade the liver essence, forms the mass lesion, the surrounding normal liver tissue because of the Echinococcosis lesion compression, the erosion forms the inflammatory hyperplasia, the bubble Echinococcosis further invades the surrounding blood vessels, the bile duct, induces the infection, jaundice and so on symptom, and can pass through the lymphatic duct and the blood vessel to the retroperitoneal Brain lymph and so on have the characteristics of similar malignant tumor constantly to the surrounding tissue infiltration growth [2].

And there are no obvious specific symptoms in the early stage of liver bubble Echinococcosis, and when there are obvious symptoms of jaundice, malnutrition, peritoneal effusion, massive lower extremity edema, other sign and symptoms, we are aware of the visit of large hospitals. When the above symptoms occur, most of the patients in the middle and late stage, and has a wide range of intrahepatic blood vessels and bile duct invasion, compression or invasion of the bile duct often lead to obstructive jaundice, involving the bile duct system obstructive jaundice is one of the more common symptoms, once delayed treatment, the patient will develop liver failure [3].

Radical resection is the first choice for patients with hepatic hydatid disease at present ERCP (endoscopic retrograde cholangiopancreatography) is a techniques that enables to examine the pancreatic and bile ducts. This surgical technique include bendable, lighted tube (endoscope) about the thickness of index finger is placed through mouth and into stomach and part of the small intestine. In the first part of duodenum a small opening known as ampulla and a small plastic tube which is known as cannula is passed through the endoscope into this opening.

Contrast material is injected and under the X-rays machine observation study are taken and the ducts of the pancreas and liver we can explore in different biliary tract diseases. However, most patients have a poor physical foundation and are unable to tolerate other treatments, and the need to relieve jaundice promptly is an important measure for such patients. ERCP+ENBD can effectively alleviate the above symptoms, however, for the hepatic Echinococcosis invasion and biliary tract jaundice can be a stage of ERCP+ENBD detection of bile duct invasion. To detect the invasion of the bile duct, two-stage radical resection can effectively avoid bile duct injury. This paper discusses the clinical effect of radical resection of ERCP+ENBD in patients with hepatic Echinococcosis and biliary tract without jaundice, which is reported below.

**MATERIALS AND METHODS:****Subjects of study**

To investigate the clinical effect of preoperative ERCP+ENBD treatment in patients without jaundice AE, 29 patients diagnosed with hepatic Echinococcosis were selected from March 2014 to May 2018 in the hospital affiliated with Qinghai University, randomly divided into 2 groups: the ERCP treatment Group (9 persons) was accepted The ERCP treatment Group (20 persons) was the control group. Incorporation criteria: (1) in line with the "Liver two Echinococcosis diagnosis and treatment expert consensus (2015 edition)" Diagnosed as hepatic hydatid disease, and no obstructive jaundice patients; (2) With recent surgical indications of hepatic Echinococcosis; (3) Complete clinical data of the case; (4) No previous history of abdominal surgery; exclusion criteria: (1) combined with Echinococcus, hepatobiliary malignant tumor, hepatic abscess, hepatic cyst, biliary calculi, acute pancreatitis, abnormal coagulation function, cirrhosis, hepatitis, Patients with blood diseases and other diseases that affect the study. (2) The combination of heart, brain, lung and other important organ lesions affected the study of patients.

**Iodine experimental allergy patients.**

General Information: The group collected a total of 29 patients, 10 cases and 19 female cases in the hospital affiliated to Qinghai University between May 2018 and March 2014, diagnosed with hepatic Echinococcosis. Age 8-61.

Among them, there were 14 cases of upper abdominal pain discomfort, 6 cases of the abdominal obstruction, and 9 cases of intrahepatic lesions were found in medical examination.

**Imaging Examination**

All patients were examined with CT or MRI imaging before an operation. The diameter of the hydatid was above 3cm, and all were less than 20cm, of which 9 cases were smaller than 10cm, 20 cases were larger than 10cm.

All Hydatid lesions were located in the left or right half of the liver, and all involved liver and left a vascular or biliary tract, invasion and 1 case of diaphragm invasion, 1 case involving the peripheral organs (adrenal glands), intrahepatic multiple 5 cases.

**Other related checks**

All patients had a preoperative liver function in Class A-B, the Hydatid experiment was positive, and the pathological results were confirmed to be hepatic Echinococcosis after the operation.

**General Procedure**

Preoperative preparation and operation of 2-1ERCP Routine examination of three major routines, coagulation function, biochemical function of the examination, parallel related imaging examination, such as chest, electrocardiogram, nuclear magnetism, etc., to carry out a comprehensive preoperative evaluation. Regular fasting 6h, no drinking 4h, before the operation 30min to the diazepam, Anisodamine, Piperidine hydrochloride intramuscular injection, the use of intravenous compound anesthesia.

Operate in strict accordance with the operating specifications [4] prepared by Changhai Hospital.

**Pre-operative preparation and surgical methods**

Preoperative examination in routine, coagulation

function, and biochemical examination, related imaging examination, assessment of the risk of surgery. Pre-operative 12h fasting, no drinking, and to prepare the digestive tract. The operation was completed by the experienced chief physician of our department, and the surgical incision was selected according to the location and size of the lesion by B-scan ultrasonography or CT examination, which was often used for the purpose of exposing the best surgical field of view with the lower oblique incision or the upper abdomen "human" glyph (Kocher's incision) incision in the right rib margin. Complete removal of intrahepatic lesions while ensuring complete structural integrity and functional compensation of the remaining liver, and maximum relief of tissue damage and bleeding. Hepatic blood flow blocking technique was used to control the amount of bleeding during the operation. For the larger case of the lesion, the tumor can be reduced to obtain more operation space, liver tissue using an ultrasonic suction knife for separation, at the same time with an electric knife to the liver wound for the exact hemostasis, the exposed bile duct, blood vessels for detachment, ligation. Half liver or enlarged semi-hepatic resection, complete resection of the lesion and surrounding affected tissue, invasion of blood vessels to repair blood vessels or artificial blood vessel substitution, involving the biliary tract, biliary reconstruction or biliary bowel anastomosis. Finally, there was no biliary leakage and hemorrhage in the liver wound examination, and the exact seam was carried out.

The peritoneal drainage tube was retained in the operative area or under the diaphragm, and the T tube was retained as appropriate.

Surgical methods in 29 patients with advanced hepatic bubble echinococcosis

<b>Experimental group</b>	<b>Number of cases</b>
<b>Right three-leaf + left liver and intestine anastomosis</b>	<b>1</b>
<b>Most resection of the right lobe of the liver</b>	<b>3</b>
<b>Resection of hepatic bubble hydatid lesion</b>	<b>4</b>
<b>Right half hepatectomy + left hepatic canal jejunum liver and intestine anastomosis</b>	<b>1</b>
<b>Control group</b>	<b>Number of cases</b>
<b>Partial resection of the right lobe of the liver</b>	<b>4</b>
<b>Right semi-hepatectomy + cholecystectomy + diaphragmatic repair + peritoneal flushing and drainage</b>	<b>1</b>
<b>Left Semi-hepatectomy</b>	<b>3</b>
<b>Treatment of +S5 ablation in the left half hepatectomy</b>	<b>1</b>
<b>Liver left tri-leaf resection + liver right anterior, right posterior hepatic duct molding + biliary anastomosis</b>	<b>1</b>
<b>Left extrahepatic lobe resection + hepatic right lobe lesion resection</b>	<b>1</b>
<b>Middle Liver resection</b>	<b>1</b>
<b>Hepatic echinococcosis lesion resection + cholecystectomy</b>	<b>3</b>
<b>Right semi-hepatectomy + cholecystectomy + cystic drainage of left hepatic hydatid lesions + intestinal adhesion loosening.</b>	<b>1</b>
<b>Right semi-hepatectomy + caudate resection + hepatic left-lobe lesion resection + right adrenal resection + inferior vena cava repair</b>	
<b>Repair of +t Tube Drainage</b>	<b>1</b>
<b>Right Half hepatectomy</b>	<b>2</b>
<b>Right three-leaf resection of the liver + resection of hepatic S3 segment lesions</b>	<b>1</b>

#### **Groups of Postoperative Treatment and Observation Indicators**

The patient's vital signs were closely monitored after the operation, and anti-inflammatory, fluid replacement, liver protection, hemostasis, nutrition, and other treatments were routinely given. The patients were properly protected from the abdominal

drainage tube and ENBD tube to prevent accidental prolapse, and the daily drainage volume was recorded. Changes, and observed whether patients had bile leakage, and observed whether patients had bile leakage, the formation of biliary tract infection, record the operation time, intraoperative blood loss, postoperative complications (biliary leakage, pleural effusion, wound infection, cholangitis), average The

number of hospital stays, the average hospitalization cost, the median time of postoperative abdominal drainage tube, preoperative, postoperative 3 days, 7 days ALT, AST, ALP and other liver function indicators.

#### **Statistical Analysis**

Statistical analysis was performed using spss25.0. The measurement data was expressed as ( $\bar{x}\pm s$ ), the count data were expressed as an absolute number, and the multi-group data test of measurement data was analyzed by repeated measures analysis of variance. The statistical test of the two groups was performed by paired t-test. The chi-square test was used to compare the count data. If the chi-square test condition was not met, the Fisher exact probability test was used, and  $P<0.05$  was considered statistically significant. The time spent on surgery, the amount of bleeding, the average length of hospital stay, the time of tube administration were analyzed by t-test, and the postoperative complications were examined by  $\chi^2$  test.

#### **RESULTS:**

##### **General Information**

A total of 29 subjects were enrolled in this study.

Among them, 9 patients in the ERCP group (experimental group) were successfully intubated and indwelled with ENBD. No ERCP group (control group) was received before surgery. There were 10 male patients and 19 female patients. The patients were aged 8-61 years old, with an average age of  $32.45\pm 13.01$  years old, all of whom were Tibetans. The preoperative liver function was graded at 23 A and 6 B; 14 patients were admitted. At the time, the abdominal distension was a discomfort to varying degrees, and the remaining patients had no special discomfort. The size of the lesion: the experimental group has a long diameter of  $12.13\pm 3.64$  mm and a short diameter of  $8.71\pm 2.96$  mm. The long diameter of the control group was  $11.87\pm 4.43$ mm, and the short diameter was  $8.08\pm 5.53$ mm. In the experimental group, 9 cases were successfully intubated and left ENBD. One case of hyperammonemia occurred after ERCP and healed after treatment with acid suppression and inhibition of enzymes. In the control group, 7 patients had bile leakage after the operation, 4 patients had pleural effusion, and 2 patients had wound infection. The above complications did not occur in the experimental group.

Table 2 Comparison of Clinical Data Between Treatment Group and Control Group and Comparison of the General Situation Between the Treatment Group and the Control Group

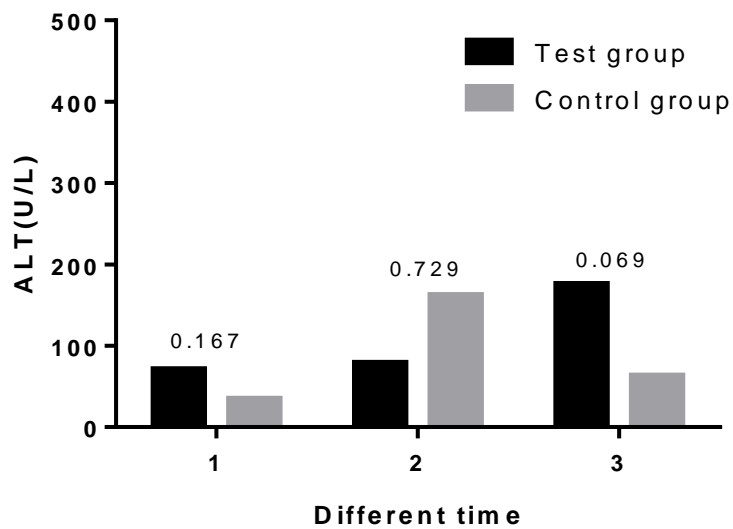
Variables	total	treatment group	control	group P
total	29	9	20	-
age	29	33.22±10.2	32.1±14.33	0.834
gender				0.64
Male	10	3	7	
Femlae	19	6	13	
Nationality				
Tibetan	29	9	20	
other	0	0	0	
Lesion size				
Long Trail	29	12.13±3.64	11.87±4.43	0.839
Short path	29	8.71±2.96	8.08±5.53	0.646
Lesion location				0.025
Left half liver	8	1	7	
Right half liver	16	8	8	
Left and right liver	5	0	5	
Liver function grading				0.49
Class A	24	8	16	
Class B	5	1	4	

There were two statistically significant differences between the two groups in age and lesion size ( $P>0.05$ ).

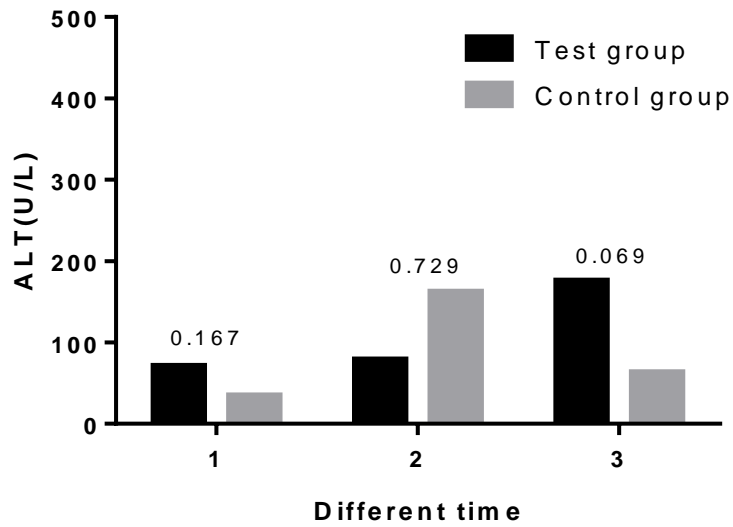
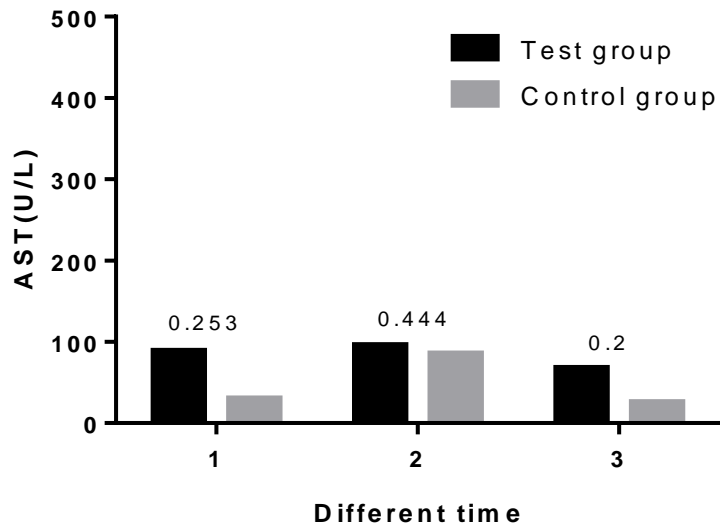
Table 3 Comparison of clinical effects between 5-2 treatment group and control group and Comparison of test indicators between treatment group and control group

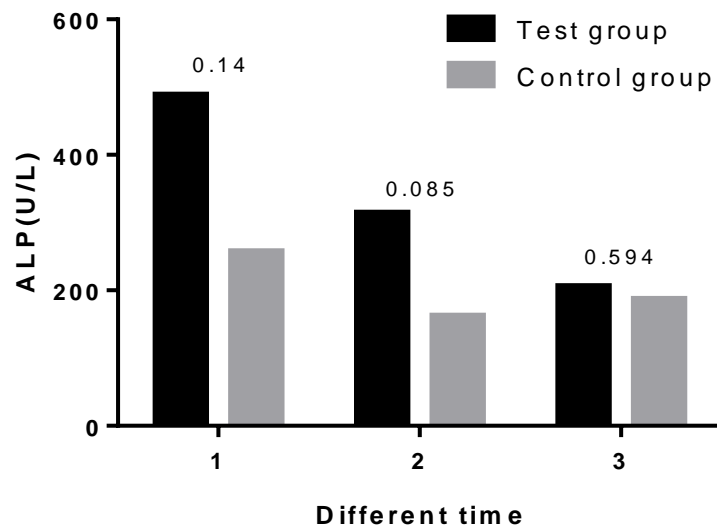
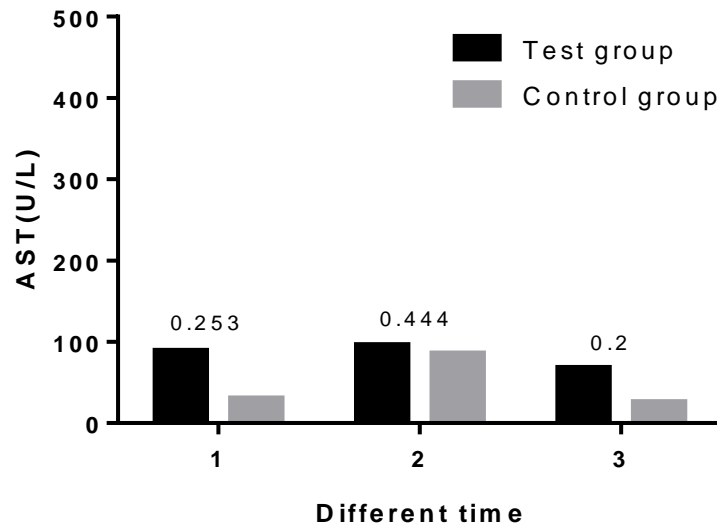
	Number of patients	test group	Control group	P value
Number of patients	29	9	20	
Preoperative ALT	36 (19.5-81)	71 (28-133)	35(18.25-52)	0.167
ALT 3 days after surgery	160 (62-284.5)	79 (41.5-408)	162.5(78.75-254)	0.729
ALT 7 days after surgery	89 (44-161.5)	176 (69.5-235.5)	63.5(43.5-114.88)	0.069
Preoperative AST	32 (24-79)	89 (22-162.5)	30.5(24.25-51.96)	0.253
AST 3 days after surgery	90 (32-192)	96 (28.5-512.5)	85.5(33.5-96.93)	0.444
AST 7 days after surgery	28 (25.9-63)	68 (28.5-731.9)	25.9(25.9-38.25)	0.2
Preoperative ALP	276 (165.65-654.7)	489 (232.3-731.9)	257.5(135-568.45)	0.14
3 days after surgery ALP	174 (119.5-346.6)	314.4 (157.15-514.95)	162.5(95.75-237.73)	0.085
7 days after surgery ALP	194 (109.8-337.45)	206 (136.75-302.9)	187.5(107.15-386.25)	0.594
Preoperative albumin	35 (32.6-38)	35.4 (32.15-40.05)	34.85(32.4-36.8)	0.472
Albumin 3 days after surgery	29.7 (27.6-33.05)	29.7 (27.9-34.05)	30.1(27.45-32.5)	0.403
Albumin 7 days after surgery	30.9 (28.55-33.4)	28.3 (26.65-33.75)	31.4(29.43-33.55)	0.234
Preoperative PT	12.6 (11.6-13.8)	12.8 (11.6-13.65)	12.15(11.48-14.35)	0.89
3 days after surgery	12.5 (12.05-14.25)	12.4 (11.85-14.9)	12.55(12.1-14.13)	0.54

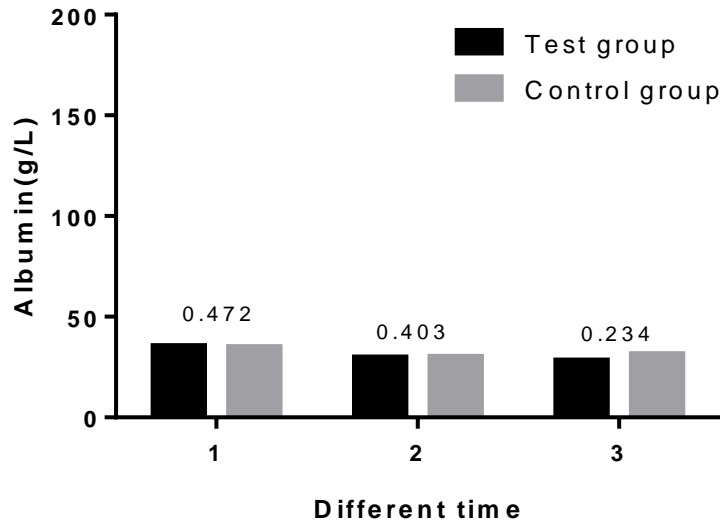
7 days after surgery	12.2 (8.86-13.85)	13 (11.55-15.9)	11.4(7.72-13.55)	0.44
Preoperative INR	1.05 (0.97-1.14)	1.07(0.97-1.13)	1.02(0.95-1.20)	0.982
3 days after surgery INR	1.04 (1.02-1.2)	1.03(0.99-1.24)	1.05(1.03-1.19)	0.729
7 days after surgery INR	1.02 (0.78-1.16)	1.08(0.92-1.31)	0.95(0.7-1.13)	0.055











Transverse axis 1, 2 and 3 represent preoperative, 3 and 7 days postoperatively, respectively. The number above the bar graph represents the P value.

As can be seen from the P value in the figure, there is no difference.

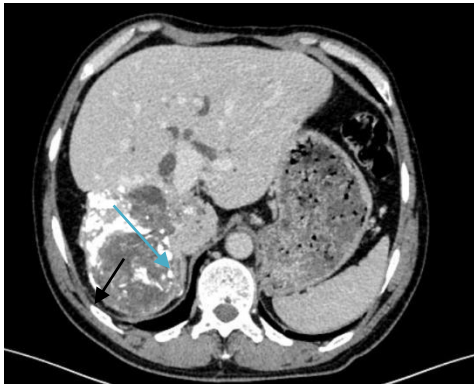Table 4 Comparison of clinical effects between treatment group and control group

compare projects	test group	Control group	P Value
Cases	9	20	
surgery time-consuming	235 (210-291)	257.5 (182.5-311.75)	0.871
hospital stay	32.67±8.66	29.4±8.56	0.352
Amount of bleeding	1600 (1000-1900)	1000 (425-1500)	0.077
Hospital costs	65494.9 (37727.44±78613.08)	44975.61 (39903.67±63399.29)	0.417
Tube time	21±7.762	13.55±8.224	0.032

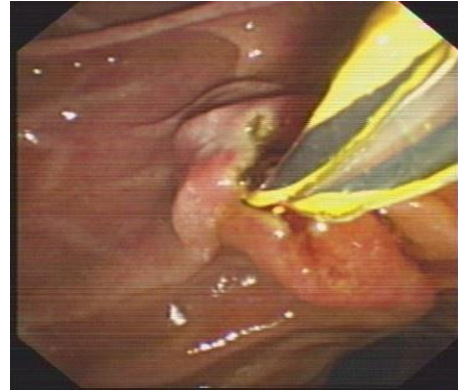
Table 5 Comparison of postoperative complications between experimental group and control group

Group	Number of cases	Bile leakage	pleural effusion	Incision infection	cholangitis
Test group	9	0	0	0	2
Control group	20	20	74	2	0
P Value		0.042	0.148	0.326	0.217

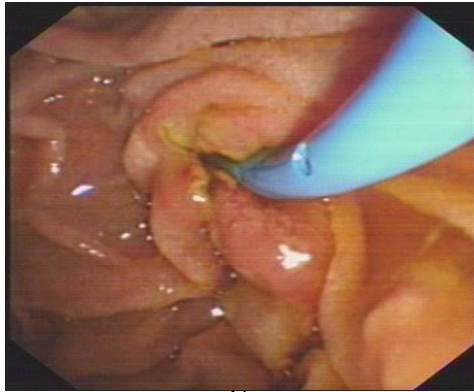
Fisher's exact probability test was performed in the two groups. The difference of  $P > 0.05$  was not statistically significant and may be related to the small sample size



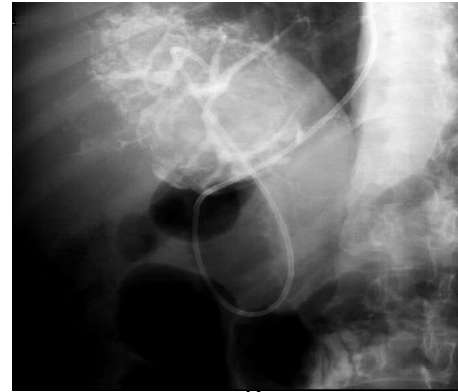A



B



C



D

A: preoperative CT, black arrow for hydatid lesion, Blue arrow for the expansion of the bile duct;B: endoscopic intubation in success;C: the guide wire guided placement ENBD tube;D: ERCP imaging in right hepatic duct development is not clear.

Fig1 Preoperative ERCP imaging features, endoscopic procedures, and intraoperative angiography

### DISCUSSION:

Hydatid disease is a zoonotic disease [5], with the most serious hazard and the highest mortality rate of Echinococcosis, and the Echinococcosis accounts for about 1.4% of the total number of human Echinococcosis, hepatic Echinococcosis The prognosis is extremely poor, with approximately 90% of patients dying within 10 years [6].

Surgical treatment is often the first choice, and radical surgery is the only effective treatment for blistering. However, the rate of radical resection is low. Some foreign scholars have reported that the resection rate of radical surgery is 50% [7], while China is relatively low. The treatment of hepatic alveolar Echinococcosis in multiple treatment centers in China [8-10] showed that radical surgery has improved postoperative quality of life and reduced

postoperative recurrence rate than quasi-radical or palliative surgery. The obvious advantages and radical surgery can completely remove the hepatic alveolar Echinococcosis lesions and the proliferative active zone around the lesions, the probability of postoperative recurrence is significantly reduced, but due to hepatic Alveolar Echinococcosis has invasive growth characteristics, The lesions of some patients with hepatic Alveolar Echinococcosis involve the invasion of the biliary tract and important blood vessels, which makes the risk of complications such as bile leakage and hemorrhage after radical resection in some patients with hepatic Alveolar Echinococcosis significantly increased due to lesion invasion and anatomical structure. Difficulties in the identification, postoperative residual bile leakage caused by bile duct injury during radical resection of

the lesion are the most common complication after radical surgery. In this group, it reached 35% (7/20), and the center The Quality Control Center in Qinghai Province for Insect Disease Surgery has treated a large number of patients with hepatic Alveolar Echinococcosis and invaded the biliary tract. According to the results of the study in this group, no patients in the radical surgery group had a postoperative recurrence, and the treatment effect was clear.

Combined with the clinical experience of the Center for many years, the imaging relationship (hepatic hydatid dynamic CT enhancement and upper abdominal MRI plain scan + enhanced + MRCP + DWI) was used to check the adjacent relationship between the lesion and the intrahepatic vital vascular and bile duct system. Analytical judgment, in addition to the observation of the location, extent, and boundary of the lesion, MRCP can clearly observe the intrahepatic blood vessels, bile ducts and invasion [11], clear the presence or absence of extrahepatic metastasis, and measure the residual liver volume by digital three-dimensional reconstruction technique; Comprehensive evaluation of liver function was performed by comprehensive liver function grading, biochemical indicators of blood and liver function, and results of indocyanine green excretion test [12-13].

For patients with good reserve function and sufficient residual liver volume, seek radical resection; but for patients with important vascular involvement, autologous blood vessel or artificial blood vessel replacement after resection of the blood vessels; repair of diaphragmatic muscles for violation of diaphragmatic muscle; Invasion of adjacent tissues and organs, the corresponding regional lymph node dissection and the removal of affected tissue and organ can achieve the purpose of radical resection [14].

Besides, with the rapid development of ERCP technology in diagnosis and treatment, the application of ERCP has been widely carried out in various aspects of hepatobiliary and pancreatic diseases and has made good application progress, so that many diseases can be diagnosed and treated under endoscopy. Studies have shown that ERCP is the most effective method for the treatment of obstructive jaundice in patients with other causes such as stones, tumors, and inflammation [15-24], but reports of ERCP application in vesicles are still rare.

For the hepatic Alveolar Echinococcosis and biliary tract without jaundice may be due to bile inflow into the lesion, in order to further explore the incidence of postoperative bile leakage, this group of prospective

studies of hepatic Alveolar Echinococcosis invading the biliary tract without jaundice In the first phase, ERCP+ENBD was used to detect the invasion of the bile duct. In the second phase, the radical resection and radical resection were compared. The general data and the liver function indexes such as ALT, AST, and ALP before and 3 days and 7 days after surgery were used. There was no statistical significance ( $P>0.05$ ), but for the prevention of postoperative bile leakage, the difference between the experimental group and the control group was statistically significant ( $P<0.05$ ), that is, the incidence of postoperative bile leakage was significantly lower than the curative effect. The group was removed, and no postoperative bile leakage occurred in the experimental group. Erzurumlu K [25] and others reported that 8 cases of ERCP have achieved good results in the treatment of biliary complications caused by hepatic Echinococcosis. Sharma BC [26] et al. performed ERCP placement on the biliary tract in 28 cases of postoperative complications of hydatid. The stent opens the physiological channel of the liver and intestine circulation, avoids the loss of bile salts and body fluids, relieves the biliary stenosis, reduces the pressure of the biliary tract, and cures the postoperative bile leakage in patients [27]. This group of studies through ERCP nipple incision and placement of ENBD, this operation is simple, small trauma, can effectively drain bile [28], reduce electrolyte imbalance caused by bile loss, digestion and absorption function and lack of fat-soluble vitamins, improve appetite, mental and physical strength, and easy to observe bile drainage in time to find the occlusion of the lumen, thereby improving the nutritional status of patients and promoting patient healing.

Clinically, bile leakage is mainly divided into the following four categories: (1) cyst leakage in the cystic duct. (2) Leakage of the gallbladder bed or prehepatic duct. (3) Major bile ducts leak. (4) major bile duct transverse injury or damage [29], for intraoperative bile duct injury caused by bile duct leakage, intraoperative electrocoagulation injury, clinical experience is for small leaks, bile into the abdominal cavity, peritonitis can be limited conservative treatment such as adequate drainage of the abdominal cavity and strengthening of infection control can generally heal itself after 1~2 weeks. However, for a large leak, bile flows into the abdominal cavity, resulting in large damage, requiring interventional or surgical treatment.

Moreover, the main harm of bile leakage is that bile can cause peritonitis, abdominal infection, water-acid acid-base balance disorder, and septic shock, and the

mortality rate is high. Liu Dehui et al [30] reported that the mortality caused by bile leakage can be as high as 4 %. For patients with bile leakage, early diagnosis and timely drainage are the keys to treatment [31]. With the rapid development of endoscopic techniques at home and abroad, minimally invasive treatment has become the treatment of choice and prevention of bile leakage. On the one hand, ERCP examination is beneficial to find the location of bile leakage and the degree of bile duct injury, which can provide new ideas for the next surgical treatment. ENBD is beneficial to reduce the pressure in the bile duct, reduce the flow of bile from the leakage, and reduce the local tissue chemical stimulation. Control infection, timely and effective bile duct decompression drainage is conducive to early healing of bile leakage and reduces the incidence of complications [32]. To this end, the experimental investigation was conducted to prevent the occurrence of postoperative bile leakage, and it was confirmed that the occurrence of bile leakage after radical resection of hepatic alveolar infestation and biliary tract without jaundice was significantly higher than that of the experimental group. In the experimental group, the first phase of ERCP+ENBD explored the bile duct invasion, which provided a new idea for the next surgical treatment. In the operation, the injection of methylene blue injection through ENBD was used to understand the intraoperative bile duct and the ligation of the bile duct. Causes bile leakage that is not easily noticeable to the naked eye and reduces postoperative bile leakage. This group of experiments also confirmed this point, providing new ideas and new methods for preventing postoperative bile leakage in hepatobiliary and other operations.

However, there was no statistically significant difference in the length of hospital stay, hospital stay, operation time, and intraoperative blood loss between the experimental group and the control group. However, the average length of hospital stay and hospitalization expenses in the experimental group was significantly higher than that in the control group. Maybe related to ERCP surgical supplies and secondary surgery intervals. Moreover, this study found that the incidence of the control group in the two groups of patients was significantly higher than the experimental group, but the statistical significance was not significant ( $P>0.05$ ), may be related to the number of cases, if further exploration of its significance, need to increase the sample capacity. There was a statistically significant difference in the time of extubation of the abdominal drainage tube ( $P<0.05$ ). The control group was considered to be effective, but large-scale cases were

also collected for comparison.

#### CONCLUSION:

The conclusion of this study is that, for patients with hepatic Alveolar Echinococcosis and biliary tract without jaundice, the first phase of ERCP+ENBD, the second phase of radical resection, a new method, although not in hospitalization costs, surgery time, hospitalization days, etc. Bringing benefits, but ERCP+ENBD has the advantages of minimally invasive, simple, and safe, which can promote the improvement of the postoperative quality of life, and provide a new idea and new method for reducing postoperative bile leakage in hepatobiliary surgery. It is worth further clinical practice. Research and promotion.

#### REFERENCES:

1. 姜涛, 彭心宇. 肝包虫病治疗的研究进展[J]. 农垦医学, 2007, 29(2): 138-141.
2. 温浩, 徐明谦. 实用包虫病学[M]. 北京: 科学出版社, 2007: 208-227.
3. 温浩. 肝包虫诊断和手术治疗新进展[J]. 中华消化外科志, 2011, 10(4): 290-292.
4. 李兆申, 胆道疾病内镜诊断与治疗学. 2006: 第二军医大学出版社.
5. Debourgogne A, Goehringer F, Umhang G, Etal .Primary cerebral alveolar echinococcosis: mycology to the rescue[J].J Clin Microbiol,2014,52:692-694.
6. Koch S, Bresson-Hadni S, Miguet JP, et al. Experience of liver transplantation for incurable alveolar echinococcosis: a 45-case European collaborative report[J]. Transplantation, 2003, 75(6): 856-863.
7. Partensky C ,LandraudR,ValettePJ,etal.Radical and nonradical hepatic resection for alveolar echinococcosis : report of 18 cases[J].World J Surg,1990,14( 5) : 654-659.
8. 张瀚之, 陈哲宇, 严律南, 等. 肝包虫病外科治疗的单中心经验[J].中国普外基础与临床杂志, 2015, 22(2): 144-148.
9. 阿卜杜艾尼·啊卜力孜, 温浩 . 难治性肝泡型包虫病的多学科个体化治疗[J].临床肝胆病杂志, 2015, 31(4): 639-641.
10. 张昀昊, 任利, 阳丹才让, 等. 肝泡型包虫病根治性切除163例回顾性分析[J].中国普通外科杂志, 2016, 25(2): 257-263.
11. 梁东,李桂萍,傅振超,俞天生,等.肝泡状棘球蚴病的临床治疗[J].肝胆外科杂志 2004,12(5): Inside back cover.
12. 董家鸿, 郑树森, 陈孝平, 等. 肝切除术前肝脏储备功能评估的专家共识 (2011 版) [J].中华消化外科杂志, 2011, 10(1): 20-25.

13. 马荣花, 郭亚民, 朱海宏, 等. 泡型肝包虫病患者肝切除术后肝储备功能的评价参数[J]. 世界华人消化杂志, 2015, 23(2): 308-312.
14. 王冠, 罗兰云, 邹海波, 等. 中晚期肝泡型包虫病36例手术治疗体会[J]. 中国普外基础与临床杂志, 2016, 23(11): 1379-1383.
15. 裴的善. 梗阻性黄疸的少见病因[J]. 新消化病学杂志 1995; 3(特刊 3): 55
16. 章华光. 诊断为肝炎的梗阻性黄疸 95 例原因分析[J]. 新消化病学杂志 1997; 5: 106-107.
17. 张军, 刘玉河, 姜希宏, 徐克森. 梗阻性黄疸内毒素血症与细胞免疫功能的关系[J]. 华人消化杂志 1998; 6: 305-306
18. 宁国礼, 马丽萍, 李柏文, 张利群, 王凤华. 恶性梗阻性黄疸误诊原因分析及对策[J]. 华人消化杂志 1998; 6(特刊 7): 266
19. 杨敏, 刘兴, 巴善铎, 张风玉. 125 例梗阻性黄疸的 ERCP 诊断分析[J]. 华人消化杂志 1998; 6: 740
20. 李兆申. 中国 ERCP 研究现状[J]. 世界华人消化杂志 2000; 8: 446-448
21. 李虎城, 许红兵, 黄辉, 陈丽楠, 李小龙, 张自强. ENBD 和(或)ERBD 的临床应用[J]. 世界华人消化杂志 2000; 8: 718-719
22. 李达民. 梗阻性黄疸致肝细胞凋亡的研究进展[J]. 中国普通外科杂志, 2014, 23(7): 967-971.
23. Boulay B R, Birg A. Malignant biliary obstruction: From palliation to treatment[J]. World J Gastrointest Oncol, 2016, 8(6): 498.
24. 张宽学, 董雷, 张晓辉. ERCP 对肝外胆管癌的诊断价值[J]. 新消化病学杂志 1997; 5: 317-318
25. Spiliadis C, Georgopoulos S, Dailianas A, Konstantinidis A, Rimikis M, Skandalis N. The use of ERCP in the study of patients with hepatic echinococcosis before and after surgical intervention [J]. Gastrointestinal Endoscopy, 1996, 43(6): 575-5
26. Sharma BC, Reddy RS, Garg V. Endoscopic management of hepatic hydatid cyst with biliary communication[J]. Dig Endosc. 2012; 24: 267-270.
27. Spiliadis C, Georgopoulos S, Dailianas A, Konstantinidis A, Rimikis M, Skandalis N. The use of ERCP in the study of patients with hepatic echinococcosis before and after surgical intervention [J]. Gastrointestinal Endoscopy, 1996, 43(6): 575-5
28. 李虎成, 许红兵. 术前内镜下胆道内外引流的临床意义[J]. 中国内镜杂志, 2001; 7: 44-45
29. 范毓权. 腹腔镜胆囊切除术并发胆漏的原因及防治[J]. 中外医学研究, 2013, 11(36): 127-128.
30. 刘德辉, 潘瑞芹, 贾振庚, 等. 胆囊切除后胆漏和出血与胆囊床组织学关系[J]. 中华外科杂志, 1990, 28(11): 665-667.
31. Christ OE, Vasiliadis K, Goulimaris I, et al. A single center experience in minimally invasive treatment of postcholecystectomy bile leak, complicated with biloma formation[J]. J Surg Res, 2007, 141(2): 171-175.
32. 吴伟新, 沈卫星, 崔恒官, 等. 腹腔镜胆囊切除术后胆漏的临床分析[J]. 中国临床医学, 2012, 19(1): 38-39.