



CODEN [USA]: IAJPBB

ISSN: 2349-7750

**INDO AMERICAN JOURNAL OF
PHARMACEUTICAL SCIENCES**Available online at: <http://www.iajps.com>

Review Article

**BODY STUFFER CASE REPORT AND LITERATURE
REVIEW****¹⁻³Mohammed Abdulrahman Alhelail*, ⁴Rakan Abdullah Alsairafi, ¹⁻³Abdulghani
Abdullah Alsairafi, and ⁵Rawabi Suhail Qadhi.**¹Department of Emergency Medicine, Ministry of the National Guard – Health Affairs, Riyadh, Saudi Arabia.²King Abdullah International Medical Research Center, Riyadh, Saudi Arabia.³King Saud bin Abdulaziz University for Health Sciences, Riyadh, Saudi Arabia.⁴Department of Emergency Medicine, King Faisal General Hospital, Makkah, Saudi Arabia.⁵Department of Pharmacology and Toxicology, Faculty of Medicine, Umm al-Qura University, Makkah, Saudi Arabia.**Abstract:**

People use various methods to conceal illicit drugs for the purposes of trafficking them while evading detection. Body stuffers, unwrapped or poorly wrapped drugs, are impulsively swallowed or inserted vaginally or rectally to avoid detection and apprehension. The amount of drugs involved is usually much smaller than that used by body packers who swallow drugs in rubber or latex packaging, typically for the purpose of trafficking. Body stuffers are one of the rare emergency room presentations with no clear guidelines regarding management, and ideal management differs depending on multiple factors, such as the type of drug and concealment, the amount of the drug, the time since it was ingested, any co-ingested constipating agents, and the drug's wrappings.¹ Furthermore, we are reporting this case because we are not familiar with such cases in Saudi Arabia, also found that management should be directed towards patient's presentation.

Keyword: Body stuffers, Amphetamine, Emergency medicine, Toxicology, Saudi Arabia.

***Corresponding author:**

Mohammed Abdulrahman Alhelail,
Department of Emergency medicine,
Ministry of the National Guard – Health Affairs,
Riyadh, Saudi Arabia, Tel: +966505225402;
E-mail: alhelail@yahoo.com

QR code



Please cite this article in press Mohammed Alhelail et al., *Body Stuffer Case Report and Literature Review.*,
Indo Am. J. P. Sci., 2019; 06(02).

INTRODUCTION:

To our knowledge, no description of the clinical course of action for amphetamine body stuffers has been published in Saudi Arabia. We are not aware of any standardized procedure for treatment or observation of amphetamine body stuffers in our poison center, or among our hospitals in Saudi Arabia. Nevertheless, Amphetamine abuse in Saudi Arabia has the second most common substances abuse as per ministry of health (MOH) in 2019. It remains unclear whether the unique aspects of amphetamine sales, packaging, and use produce unique clinical symptoms and signs. The goal of reporting this case is to describe the characteristics, presentation, and hospital course of action of amphetamine body stuffers.

One common packet used for a body stuffer is the condom, which may hold up to 5 grams of a narcotic. These packets are often visible on plain radiography. The rupture of even one such packet may be fatal, and endoscopy is contraindicated because it carries the risk of iatrogenic packets rupturing. If a packet appears to be passing intact through the intestinal tract, observation until the packet reaches the rectum is the favored treatment.[2] Some authors advocate the use of whole-bowel irrigation (WBI) to aid the process.

On the other hand, surgery techniques may accelerate the drug's release and exaggerate amphetamine toxicity, leading to death. Emergency surgery is indicated for body packers with cocaine poisoning and for some cases of heroin poisoning. Urgent surgery is indicated for obstruction, perforation, the passage of packet fragments, and the failure of conservative treatments.[3]

CASE PRESENTATION:

A 19-year-old male presented to the ER alone after he ingested a plastic bag containing 15-17 tablets of amphetamine, which he described as well-sealed. He had passed a police checkpoint one hour prior to presentation. He had no fever, excessive sweating, abdominal pain, vomiting, nausea, chest pain, or loss of consciousness. He used to smoke cannabis but had not used amphetamines before. He had no known history of addiction, suicidal tendencies, or psychiatric problems. On examination, the patient was vitally stable, conscious, and oriented. His pupils were equally reactive, and his abdomen was soft, lax, and without tenderness or exaggerated sound.

At that time, venous blood gas, urine toxicology, [Table1&2] and radiographic imaging [Figure1] were ordered, and the toxicologist on call was contacted. He suggested keeping the patient nil per oral (NPO), considering oral activated charcoal, oral polyethylene glycol, and keeping the patient for observation. He stated that if at any time the patient developed sympathomimetic symptoms to take him to the operation room for an exploratory laparotomy.

The patient took activated charcoal and about 250 ml of oral polyethylene glycol. The patient then vomited the bag, and it contained a brown material, likely gastric content. There was a small opening in the bag. [Figure2]

The patient then received another oral dose of 25 mg activated charcoal, NPO, and IV fluids, and he was observed for 3-4 hours. He was then cleared from medical point of view with no symptoms and stable vital signs.

pH	7.396
pCO ₂	42.7
pO ₂	40.4
HCO ₃	25.6
BE	0.6
Hgb	9.7
P/F Ratio	192.5
Na ⁺	141.4
K ⁺	3.09
Ca ²⁺	1.190
Glu F	5.3

Amphetamine Screen	Negative
Barbiturate Screen	Negative
Benzodiazepine Screen	Positive
Cocaine Screen	Negative
Opiate Screen	Negative
Cannabis Screen	Positive

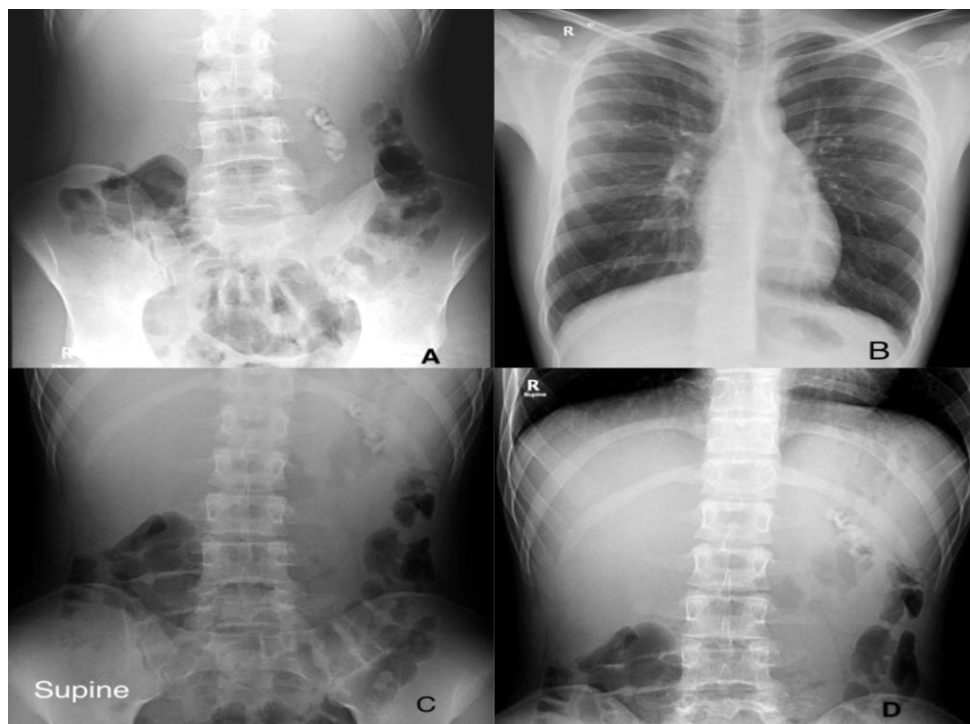


Figure 1: (A) Upright abdomen X-ray showing radiopaque material, (B) AP chest X-ray, (C and D) Supine abdomen X-ray showing the radiopaque material



Figure 2: The plastic bag after it was retrieved from the patient and showing the brown material

Literature review

Topic overview

We are reporting this case because it is one of the rare complaints to our institution with a common overall presentation of body stuffers. Drug addiction is an important medical and social problem, and increasing trends of illicit drug use worldwide as it is reported in world drug report 2017 by United Nations Office on Drugs and Crime (UNDOC) make it worthy of attention. Since the marketing of such drugs is illegal, so-called "body-packing" is frequently used for concealed transportation. Another strategy is "body-stuffing," a process in which a drug package is hastily swallowed to avoid arrest.[4] Police department records in Kingdom of Saudi Arabia (KSA) show that drug-related crime is a growing problem in KSA, which is ranked at 45 out of 102 countries.[5]

Patients who stuff drugs present a diagnostic and therapeutic challenge to emergency physicians. patient's history, laboratory, and radiology studies must be interpreted with caution. Management strategies should focus on the drugs ingested and be tailored to the needs of each individual patient. After the oral ingestion of drug packets, toxicity is most frequently absent or mild. However, although most cases involve low rates of complications, both significant toxicity and death can occur.[6,7,8,9] The likelihood of toxicity and death depends on multiple factors, such as time of presentation after ingestion, which is sometimes delayed because patients in police custody usually deny the occurrence of body-stuffing or will not present to a hospital until they develop symptoms. For example, the ingestion of crack cocaine vials may present symptoms delayed by as much as 3 to 4 hours.[10]

Special characteristics

A higher incidence of toxicity results from ingesting drugs by body stuffers than by body packers, most likely because body packers ingest packets that are made for ingestion, unlike body stuffers.[11] Clinical parameters are useful in predicting outcomes in patients who have body-packed methamphetamine. For example, there is a greater likelihood of severe outcomes if the presenting pulse is greater than 120 bpm or the presenting temperature is greater than 38°C.[12]

In our literature review, there is a case report of an unusual method of ingesting methamphetamine called "parachuting," in which a patient placed methamphetamine in a plastic bag with a small hole in an attempt to create a sustained-release mechanism. He was treated with activated charcoal and (WBI), observed for 24 hours, and discharged.

He returned 42 hours after his ingestion with tachycardia, agitation, hypertension, and rhabdomyolysis, requiring mechanical ventilation and a midazolam drip.[13]

Role of laboratory testing and diagnostic imaging

Laboratory drug testing is a challenging way to screen body stuffers because these patients are often habitual substance users. Thus, a positive drug screen could be related to prior use, current toxicity, or both, and a negative result does not exclude recent ingestion or leaking packages. Several authors have reported drug toxicity or death occurring in the presence of a negative urine screen.[13,14]. Diagnostic imaging shows that there is no gold standard test for detecting concealed drug packets. Some authors estimate that the sensitivity of abdominal x-rays in the detection of drug packets in body packers ranges from 47–95%, though the performance of computed tomography (CT) in detecting drug packets has been proposed as superior to x-rays.[15,16,17] Other authors suggest that radiographic detection can be increased with oral contrast, though its utility has not been established.[9,18] Although CT-scanning may identify some packets that are missed by plain radiographs, its sensitivity has not been investigated, and missed packets have been reported with this modality as well.[19] However, another study of 70 patients founds that there is no relationship between CT scan findings and clinical manifestations of methamphetamine body stuffers, indicating that severe outcomes may be observed, even in the face of negative CT scans.[20]

Management

Body stuffers who are exhibiting drug toxicity should be managed according to standard principles for managing the concealed substance in question, and strategies span activated charcoal administration, WBI, endoscopy, and surgery, depending on systemic manifestations.

On the other hand, one study of 132 body packers and body stuffers showed that the medical management of these patients is rarely associated with serious complications. The results also showed that these patients' lengths of stay are generally long, averaging 2 days before complete elimination of the drug packages.[21] However, this finding was not statistically significant ($p = 0.13$).

Management of asymptomatic body stuffers has not been well-evaluated. Treatment with activated charcoal and (WBI) is often advocated for high-risk patients. Although these methods have not been proven to reduce morbidity or mortality, they offer theoretical benefits.[9,10,22,23] Activated charcoal

may reduce the absorption of liberated drugs, as both heroin and cocaine are well-adsorbed into activated charcoal. This strategy can limit drug absorption from leaking or ruptured packets, but its use should be tempered by the understanding that the presence of activated charcoal in the gut may contaminate the peritoneum in the event of a rupture or surgery.[24]

Whole-bowel irrigation may reduce intestinal transit times, leading to earlier passages of packets. However, it is unlikely to offer any clinical benefits unless a life-threatening number of drug packets have been ingested. While a clear stool is an endpoint of therapy, it does not necessarily indicate that all the ingested drug packets have passed. There was a reported case in which a 39-year-old male retained a packet in his stomach despite clear stools after a WBI.[25]

Patients with gastrointestinal complaints should be evaluated for lack of intestinal movement (ileus) or obstructions. Removal of packets has been performed by endoscopy,[18,22,26] but this is useful only for a small number of packets. Furthermore, only packets that have not passed beyond the pylorus can be retrieved using upper gastrointestinal endoscopy (UGIE).[27] Endoscopy should be used with extreme caution as it may cause packets to rupture, leading to toxicity, or aspirate and cause airway obstructions.[28] Still, there are a number of reports of asymptomatic body stuffers being managed by UGIE without any complications.[27]. Use of colonoscopy has also been reported, but it carries a risk of rupture similar to that associated with upper endoscopy.[29]

The European Society of Gastrointestinal Endoscopy (ESGE) recommends close observation in asymptomatic individuals who have concealed packets of drugs by swallowing (body-packing). Also, it recommends against endoscopic retrieval, and it recommends surgical referral in cases of suspected packet rupture, failure of packets to progress, or intestinal obstruction.[30]

The need for surgical intervention has been reported in some cases. Two body stuffer patients who underwent exploratory laparotomy have been reported; however, the surgery was not useful in removing the packets and led to severe methamphetamine toxicity. These cases show that surgical treatment may be ineffective and even harmful in body stuffers.[31] Surgery is a mainstay of treatment for swallowed drug packages, particularly when drug leaks and intoxication are a problem.[27]

Drug packets that have been in the stomach for >48 hours are not an indication for surgery, which is recommended only for patients with signs of intoxication or ileus. Conservative treatment is recommended for all other patients.[32]

Another author reported on cases at the Frankfurt and Paris airports from 1985 to 2002; 4,660 body packers and 312 body pushers were identified. Sixty-four patients of body packers (1.4%) developed life-threatening symptoms of cocaine overdose as a result of ruptured containers. In 20 patients, emergency laparotomies were performed, and the containers were removed; all of these patients survived. The other 44 patients died before surgical treatment could be performed. Only one body pusher required medical attention.[29]

Another study reviewed demographic data, ingestion characteristics, and clinical progress. Patients developed new or worsening features of drug toxicity within 6 hours of presentation, with a mean time to development of symptoms of 2 h 50 minutes \pm 1 h 39 minutes. An observation period of 6 hours from the time of admission was required, even if the patient was asymptomatic or there was a resolution of the presenting signs and symptoms, although this was not confirmed in other studies.[33,34] However, an *American Journal of Emergency Medicine* response to a letter to the editor argues that "some patients may have complications after the observation period." A confirmatory radiological study is needed to demonstrate the complete clearance of packets. A systematic protocol for the management of body packers results in minimal morbidity and no mortality.[35]

CONCLUSION:

This case illustrates challenges in establishing a guideline for the management of patients with body stuffers. Thus, more case reports are needed to establish a clear one. Our findings suggest that patients with a history of concealed drugs who are asymptomatic at 6 hours are at a low risk of complications and should not require hospital admission. As regards screening or diagnosing patients with body stuffers, laboratory investigations show no benefit. Furthermore, if a patient requires imaging, a CT scan would be the modality of choice, but it is still not a guarantee. Whole-bowel irrigation and activated charcoal are not proven to reduce mortality or morbidity. All the same, they offer theoretical benefits that make them reasonable choices if there are no contraindications. Gastrointestinal endoscopy carries a risk of packet rupture. Accordingly, it is limited to certain patients. Since Cocaine overdose can be a life-threatening

situation, the only possible treatment is immediate laparotomy for the removal of the container if the cause is overdose of a ruptured container in a body packer.

Conflict of interest statement

None declared.

Funding

The authors have not received any funding or benefits from industry to conduct this study.

Authors' contribution

Authors contributed significantly and in agreement with the content of the manuscript. The senior author was the treating physician. Other authors participated in the literature review, data collection and writing of the final draft.

REFERENCES:

- West PL, McKeown NJ, Hendrickson RG. Methamphetamine body stuffers: an observational case series. *Ann Emerg Med*, 2010; 55(2):190-7.
- Chirica M, Champault A, Dray X, Esophageal perforations. *J Visc Surg*, 2010; 147:e117.
- Booker RJ, Smith JE, Rodger MP. Packers, pushers and stuffers—managing patients with concealed drugs in UK emergency departments: a clinical and medicolegal review. *Emerg Med J*, 2009; 26(5):316-20.
- Traub SJ, Hoffman RS, Nelson LS. Body packing—the internal concealment of illicit drugs. *N Engl J Med*, 2003; 349:2519–26.
- European Institute for Crime Prevention and Control [Internet]. International Statistics on Crime and Justice; 2011, Accessed 26 Oct. 2018. Available from: <http://www.nationmaster.com/country-info/stats/Crime/Drug-related-crime>
- Fineschi V, Centini F, Monciotti, Turillazzi E. The cocaine “body stuffer” syndrome: a fatal case. *Forensic Sci Int*, 2002; 126:7-10.
- Introna Jr F, Smialek JE. The “mini-packer” syndrome. *Am J Forensic Med Pathol*, 1989; 10:21- 24.
- Jordan MT, Bryant SM, Aks SE, Wahl M. A five-year review of the medical outcome of heroin body stuffers. *J Emerg Med*, 2009; 36:250-256.
- June R, Aks SE, Keys N, Wahl M. Medical outcome of cocaine body stuffers. *J Emerg Med*, 2000; 18:221-224.
- Hoffman RS, Chiang WK. Prospective evaluation of “crack-vial” ingestions. *Vet Hum Toxicol*, 1990; 32:164-167.
- Marc B, Gherardi R, Baud FJ, Diamant-Berger O. Managing drug dealers who swallow the evidence. *BMJ*: first published as 10.1136/bmj.299.6707.1082-a on 28 October 1989, page 1082 *BMJ Volume 299*
- Kelly A. Towards evidence-based emergency medicine: best BETs from the Manchester Royal Infirmary. BET 1: what prognostic factors can predict outcomes of methamphetamine body stuffers? *Emerg Med J*, 2013; 339-40.
- Hendrickson RG, Horowitz BZ, Norton RL, Notenboom H. “Parachuting” meth: a novel delivery method for methamphetamine and delayed-onset toxicity from “body stuffing.” *Clin Toxicol*, 2006; 44:379-382.
- Gill JR, Graham SM. Ten years of “body packers” in New York City: 50 deaths. *J Forensic Sci*, 2002; 47:843-846.
- McCarron MM, Wood JD. The cocaine “body-packer” syndrome. Diagnosis and treatment. *JAMA*, 1983; 250:1417-20.
- Caruana DS, Weinbach B, Goldfrank L, et al. Cocaine-packet ingestion. *Ann Intern Med*, 1980; 9:429-30.
- Karhunen PJ, Suoranta H, Penttilä A, Pitkäranta P. Pitfalls in the diagnosis of drug smuggler’s abdomen. *J Forensic Sci*, 1991; 36:397-402.
- Cranston PE, Pollack Jr CV, Harrison BR. CT of crack cocaine ingestion. *J Comput Assist Tomogr*, 1992; 16:560-563.
- Eng JGH, Aks SE, Waldron R, Aks SE, Waldron R, Marcus C, Issleib S. False-negative abdominal CT scan in a cocaine body stuffer. *Am J Emerg Med*, 1999; 17:702-704.
- Bahrami-Motlagh H, Hassanian-Moghaddam H, Zamani H, Gachkar L, Zamani N. Correlation of abdominopelvic computed tomography with clinical manifestations in methamphetamine body stuffers. *Radiol Med*, 2018; 123:98–104.
- Heymann-Maier L, Trueb L, Schmidt S, Carron PN, Hugli O, Heymann E, Yersin B. Emergency department management of body packers and body stuffers. *Swiss Med Wkly*, 2017; 147:w14499.
- Jordan MT, Bryant SM, Aks SE, Wahl M. A five-year review of the medical outcome of heroin body stuffers. *J Emerg Med*, 2009; 36:250-256.
- Sporer KA, Firestone J. Clinical course of crack cocaine body stuffers. *Ann Emerg Med*, 1997; 29:596-601.
- Goertemoeller S, Behrman A. The risky business of body packers and body stuffers. *J Emerg Nurs*, 2006; 32:541–544.
- Hoffman RS, Smilkstein MJ, Goldfrank LR. Whole bowel irrigation and the cocaine body-packer: a new approach to a common problem. *Am J Emerg Med*, 1990; 8:523-7.
- Pollack CV Jr, Biggers DW, Carlton FB Jr, Achord JL, Cranston PE, Eggen JT, Griswold

- JA. Two crack cocaine body stuffers. *Ann Emerg Med*, 1992; 21:1370-1380.
- 27 Asil M, Dertli R. Successful endoscopic treatment of an unusual foreign body in the stomach: a package of heroin. *Ulus Travma Acil Cerrahi Derg*, 2017; 23(4):354-356.
- 28 Suarez CA, Arango A, Lester III JL. Cocaine-condom ingestion: surgical treatment. *JAMA*, 1977; 238:1391-1392.
- 29 Schaper A, Hofmann R, Bargain P, Desel H, Ebbecke M, Langer C. Surgical treatment in cocaine body packers and body pushers. *Int J Colorectal Dis*, 2007; 22:1531-1535.
- 30 Birk M, Bauerfeind P, Deprez PH, Häfner M, Hartmann D, Hassan C, Hucl T, Lesur G, Aabakken L, Meining A. Removal of foreign bodies in the upper gastrointestinal tract in adults: European Society of Gastrointestinal Endoscopy (ESGE) clinical guideline. *Endoscopy*, 2016; 48(5):489-96.
- 31 Bahrami-Motlagh H, Hassanian-Moghaddam H, Behnam B, Arab-Ahmadi M. Failure of surgical treatment in methamphetamine body-stuffers. *J Forensic Leg Med*, 2015; 32:70-2.
- 32 de Bakker JK, Nanayakkara PW, Geeraedts LM Jr, de Lange ES, Mackintosh MO, Bonjer HJ. Body packers: a plea for conservative treatment. *Langenbecks Arch Surg*, 2012; 397(1):125-30.
- 33 Yamamoto T, Malavasi E, Archer JR, Dargan PI, Wood DM. Management of body stuffers presenting to the emergency department. *Eur J Emerg Med*, 2016; 23(6):425-429.
- 34 Moreira M, Buchanan J, Heard K. Validation of a 6-hour observation period for cocaine body stuffers. *Am J Emerg Med*, 2011; 29(3):299-303.
- 35 Mandava N, Chang RS, Wang JH, Bertocchi M, Yrad J, Allamaneni S, Aboian E, Lall MH, Mariano R, Richards N. Establishment of a definitive protocol for the diagnosis and management of body packers (drug mules). *Emerg Med J*, 2011; 28(2):98-101.