

ORIGINAL ARTICLE

Lymph node metastases in clinically N0 patients with papillary thyroid microcarcinomas - a single institution experience

Merima Goran¹, Tatjana Pekmezovic^{2,3}, Ivan Markovic^{1,3}, Nada Santrac¹, Marko Buta^{1,3}, Dusica Gavrilovic⁴, Nikola Besic⁵, Yasuhiro Ito⁶, Igor Djuriscic¹, Gordana Pupic⁷, Radan Dzodic^{1,3}

¹Surgical Oncology Clinic, Institute for Oncology and Radiology of Serbia, Belgrade, Serbia; ²Institute for Epidemiology, Belgrade, Serbia; ³School of Medicine, University of Belgrade, Belgrade, Serbia; ⁴Data Center, Institute for Oncology and Radiology of Serbia, Belgrade, Serbia; ⁵Institute for Oncology of Ljubljana, Ljubljana, Slovenia; ⁶Department of Surgery, Kuma Hospital, Kobe, Japan; ⁷Department of Pathology, Institute for Oncology and Radiology of Serbia, Belgrade, Serbia

Summary

Purpose: To register the frequency of central and lateral lymph node metastases (LNMs) from papillary thyroid microcarcinomas (PTMCs), and to assess whether sentinel lymph node (SLN) biopsy of the lateral compartment is an accurate technique to select patients with true positive but clinically negative lymph nodes for one-time selective lateral neck dissection (sLND). The correlation between tumor characteristics (size, multifocality, bilaterality, capsular invasion) and LNMs was analyzed.

Methods: During a 10-year-period (2004-2013), 111 clinically N0 patients with PTMCs had total thyroidectomy, central neck dissection and SLN biopsy of the lateral neck compartment in our institution. SLN mapping was performed by subcapsular injection of 0.2 to 0.5ml of 1% methylene blue dye. If SLNs were positive on frozen section, one-time sLND was done.

Results: Forty per cent of PTMCs were multicentric. LNMs were detected in 25% of the patients and isolated central

LNMs were found in 18% of the patients. Lateral LNMs were present in 7% of the patients, of which 4% were isolated, skip LNMs. All these patients had therapeutic sLND. Specificity and sensitivity of SLN biopsy were 100% and 57%, positive and negative predictive values were 100% and 97%, respectively. Method's accuracy was 97%.

Conclusions: SLN biopsy of the lateral neck compartment is more precise than physical examination and ultrasonography for detection of lateral LNMs in clinically N0 patients with PTMCs. Intraoperative assessment of lateral lymph nodes (SLNs) provides one-time therapeutic dissection for patients with occult LNMs at initial operation, reducing the need for additional operations. This method provides appropriate disease staging and optimizes treatment.

Key words: lymph node metastases, methylene blue dye, papillary thyroid microcarcinomas, sentinel lymph node biopsy

Introduction

Papillary thyroid carcinomas ≤ 1 cm in size are defined as microcarcinomas [1]. Microcarcinomas can be discovered after total thyroidectomy for benign disease (incidental), identified at autopsy (indolent); diagnosed by physical or ultrasonical ex-

amination; cytologically confirmed by fine needle aspiration biopsy; or they can be occult, characterized by clinical metastases, while primary tumors are detected on definitive pathological examination, or not detected at all [2]. In recent years, the

incidence of PTMCs is increasing [3]. The majority of PTMCs have indolent course and excellent prognosis. Some authors recommend observation as an alternative to surgical treatment for low-risk PTMCs [4]. However, very rarely, PTMCs can have a more aggressive course with recurrence and distant metastases [5, 6]. Therefore, the extent of surgical resection of the thyroid gland and regional lymph nodes in PTMCs is a subject of debate among surgeons [4,5,7-10].

Due to the frequent neck LNM in patients with PTMCs, total thyroidectomy with central neck dissection is performed as a standard procedure at the Institute for Oncology and Radiology of Serbia (IORS), along with detection of SLN in the lateral neck compartments to decide upon necessity for one-time lateral neck dissection [11].

The aim of this study was to register the frequency of central and lateral LNMs from PTMCs, to assess whether SLN biopsy of the lateral compartment is an accurate technique to select patients with true positive but clinically negative lymph nodes for one-time sLND, as well as to analyze the predictive values of tumor size, multifocality, bilaterality and capsular invasion in relation to LNMs frequency.

Methods

Patients included in this study were treated at IORS from 2004 to 2013 as a part of an ongoing project of the National Ministry of Science for early diagnostic of lymph node metastases using SLN biopsy. All 111 patients had PTMCs and were clinically N0 (based on physical examination and ultrasonography). They were treated with total thyroidectomy, central neck dissection and SLN biopsy of the lateral neck compartments to identify occult lateral LNMs and perform one-time sLND. Patients with preoperative neck lymphadenopathy on physical and/or ultrasonic examination, as well as patients in whom surgical or fine needle biopsy of neck lymph nodes proved thyroid carcinoma metastasis were not included in the study.

SLN biopsy of the lateral regions after methylene blue dye mapping was first published in 2006 by Dzodic et al. [11]. In all patients 0.2 to 0.5 ml of 1% methylene blue dye is injected prior to the lobe mobilization, just beneath the thyroid gland capsule, with coagulation of the capsule to avoid leakage of the vital dye. Lateral neck compartments are explored for blue dyed lymph nodes that are extirpated and sent for frozen section study. In cases where there were no blue dyed lymph nodes, blue dyed lymphatic vessels are visually followed and the nearest lymph nodes (one or more) are harvested as the first draining nodes in the lateral neck region - SLN. If frozen section study of SLNs iden-

tified metastases, sLND was carried out immediately. If metastases could not be detected this way, but were diagnosed on definitive pathohistological examination, sLND was subsequently performed.

Statistics

To determine a correlation between tumor size and the occurrence of LNMs, all patients were classified into two groups, those with tumors under or 5 mm in size (≤ 5 mm), and those with a tumor size over 5 mm (5.1-10 mm).

Sample distribution for normality was tested by Kolmogorov-Smirnov test. Descriptive statistics (frequency, percentage, average, median, standard deviation (SD) and range) was used to summarize data about patients, tumor characteristics and treatment. The association between parameters was tested by the Pearson's chi-square test, Fisher's exact test and Wilcoxon's rank sum test, as appropriate. All comparisons were two-sided and a p value <0.05 was considered statistically significant. Data analysis was performed in the statistical program R [version 3.1.1 (2014-07-10) - "Sock it to Me" Copyright (C) 2014 The R Foundation for Statistical Computing Platform: i386-w64-mingw32/i386 (32-bit); (download: 10.22.2014)].

Results

The mean patient age was 49 years, with females' predominance. Characteristics of the patients and tumors are shown in Table 1. The mean tumor size was 4.93 ± 2.76 mm. More than 60% of patients had a dominant tumor ≤ 5 mm. Multicentric carcinomas were detected in 40% of the whole thyroid specimens. Capsular invasion was present in 19% of the cases, while no tumor had vascular invasion.

Characteristics of LNMs (in total and by PTMC tumor size categories ≤ 5 mm vs 5.1-10 mm) are shown in Table 2. LNMs were pathologically confirmed in 28 (25.23%) patients: isolated central LNMs (pN1a) in 20 (18.03%) patients; lateral LNMs (pN1b) in 8 (7.21%) patients, of which 3 (2.70%) had LNMs in both central and lateral neck region, while 5 (4.50%) had only isolated LNMs - skip metastases (Table 2, Figure 1). Almost all patients with lateral LNMs (7/8 patients) had 1 or 2 LNMs, except for one patient with 13 lateral LNMs.

Altogether, 3 patients had postoperative complications. In one patient recurrent laryngeal nerve was accidentally cut on one side and subsequently reconstructed by direct anastomosis. One patient had a transient hypoparathyroidism. In one patient a transient Horner's syndrome was

Table 1. Characteristics of patients, tumors and sentinel lymph nodes

Characteristics	N (%)
Characteristics of patients	
Gender	
Male	17 (15.32)
Female	94 (84.68)
Age (years)	
Mean (SD ^a)	49.42 (12.53)
Median (range)	51 (23-73)
Characteristics of tumors ^b	
Tumor size (in mm)	
Mean (SD ^a)	4.93 (2.76)
Median (range)	5 (0.5-10)
Tumor size (categories, mm)	
≤ 5	72 (64.86)
5.1-10	39 (35.14)
Number of foci	
Solitary	67 (60.36)
Multiple	44 (39.64)
Unilateral	20 (18.02)
Bilateral	24 (21.62)
Capsular invasion	
Yes	21 (18.92)
No	90 (81.08)
Characteristics of SLNs ^c	
Coloring	
Colored lymph nodes	77 (69.37)
Colored lymphatic vessels	16 (14.41)
Uncolored lymph nodes	18 (16.22)
Frozen section analysis	
Benign	105 (94.59)
Malignant	4 (3.60)
Paraffin	2 (1.80)
Definitive histopathology	
Benign	103 (92.79)
Malignant	8 (7.21)
Total	111 (100)

^a standard deviation, ^b papillary thyroid microcarcinomas, ^c sentinel lymph nodes

observed.

During the follow-up period (1-11 years, median 4.5), none of the patients had locoregional recurrence or distant metastasis.

According to PTMC tumor size categories (≤ 5 mm vs 5.1-10 mm), there was no statistically significant difference in the frequency of LNMs (Table 2). There was nearly statistically significant difference in the median number of central LNMs (1 vs 2, respectively, $p=0.054$, Table 2) and presence of lateral and/or central LNMs (19.44 vs 35.90% respectively, $p=0.057$, Table 2) in patients with PTMC tumor size ≤5 mm vs 5.1-10 mm. Pa-

tients with capsular invasion had significantly more often lateral LNMs in comparison to those without (23.81 vs 3.33%, respectively; $p<0.05$, Table 3). Statistically significant correlation was found between other tumor characteristics (multifocality, bilaterality) and presence of lateral LNMs (Table 3).

Finally, it should be noted that due to relatively small cohort of patients with the presence of LNMs (25.23% patients), more extensive exploration of predictive factors for the occurrence of LNMs was not possible.

Identification rate of SLNs in lateral neck regions was 84% (Table 1). On frozen section and definitive pathological analysis, the sensitivity, specificity, positive predictive value and negative predictive value of SLN biopsy method were as follows: 57%, 100%, 100% and 97%, respectively. The accuracy of the method was 97.25% (Table 4).

In 2 patients, frozen section analysis of SLNs was inconclusive. After the diagnosis of lateral LNMs was set on standard paraffin-embedded pathological examination, these patients received adequate sLND in the second operation.

In 3 patients SLN micrometastases were not identified on frozen section analysis, but after using immunohistochemical staining in the definitive pathological examination. These patients had another operation for sLND.

Discussion

PTMCs generally have an excellent prognosis, with rare locoregional recurrence or distant metastasis and very low disease-specific mortality. For this reason, some Japanese authors recommend observation of patients with cytologically proven low-risk PTMCs, followed by surgical intervention only in cases with tumor enlargement and new LNMs [12]. However, there are also high-risk PTMCs that do not have indolent course and can be locally aggressive, or give distant metastases [5-7].

LNMs are common in PTMCs [13]. Predictors of LNMs in PTMCs are well known and include multifocality, tumor size and capsule invasion [14,15]. In a study by Wada et al. 64 % of patients with PTMCs had central LNMs [13], which is more than observed in this study (21%). According to the literature, independent factors predicting the occurrence of central LNMs are: tumor diameter larger than 5 mm, extrathyroid extension, as well as multifocality [16-19]. Statistical analysis for this cohort of 111 patients showed no significant

Table 2. Characteristics of lymph node metastases from papillary thyroid microcarcinomas according to tumor size categories

Localization of LNMs ^a	Total N (%)	PTMC ^d size categories		Test
		N (%) ≤ 5 mm	N (%) 5.1-10 mm	
<i>Lateral</i>				
Without metastases	103 (92.79)	68 (94.44)	35 (89.74)	Fisher exact p=0.45
With metastases	8 (7.21)	4 (5.56)	4 (10.26)	
Number of metastases ^b				
Mean (SD ^c)	2.88 (4.12)	1.5 (0.58)	4.25 (5.85)	Wilcoxon rank sum W=7; p=0.87
Median (range)	1.5 (1-13)	1.5 (1-2)	1.5 (1-13)	
<i>Central</i>				
Without metastases	88 (79.28)	60 (83.33)	28 (71.79)	Pearson χ^2 $\chi^2_1=2.05$; p=0.15
With metastases	23 (20.72)	12 (16.67)	11 (28.21)	
Number of metastases ^b				
Mean (SD ^c)	2.96 (2.65)	2.58 (3.15)	3.36 (2.06)	Wilcoxon rank sum W=35.5; p=0.054
Median (range)	2 (1-11)	1 (1-11)	2 (1-7)	
<i>Lateral and/or central</i>				
Without metastases	83 (74.77)	58 (80.56)	25 (64.10)	Pearson χ^2 $\chi^2_1=3.63$; p=0.057
With metastases	28 (25.23)	14 (19.44)	14 (35.90)	
Localization ^b				
Only central	20 (18.03)	10 (13.88)	10 (25.65)	Fisher exact p=0.21
Only lateral	5 (4.50)	2 (2.78)	3 (7.69)	
Central & lateral	3 (2.70)	2 (2.78)	1 (2.56)	
Number of metastases ^b				
Mean (SD ^c)	3.25 (3.98)	2.64 (3.13)	3.86 (4.72)	Wilcoxon rank sum W=69.5; p=0.18
Median (range)	2 (1-19)	1.5 (1-12)	2 (1-19)	
Total	111 (100)	72 (64.86)	39 (35.14)	-

^a lymph node metastases, ^b only for patients with metastases, ^c standard deviation, ^d papillary thyroid microcarcinomas

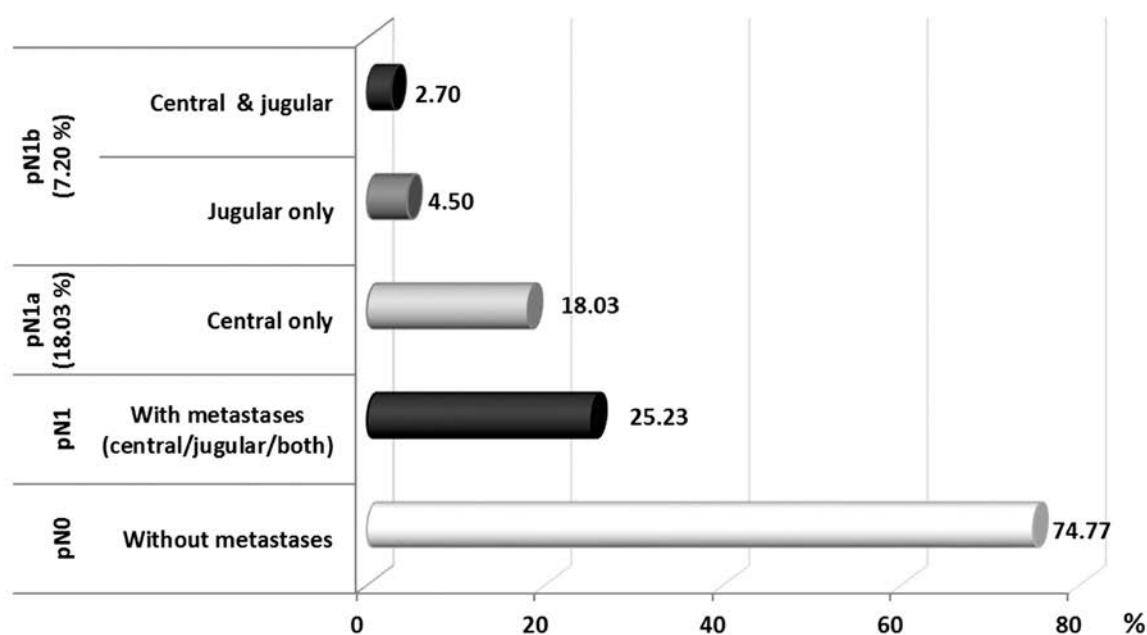


Figure 1. Percent distribution of papillary thyroid microcarcinoma lymph node metastases in different regions of the neck.

Table 3. Tumor characteristics and localization of lymph node metastases in papillary thyroid microcarcinomas

Characteristics	Categories		Test
	N (%) No	N (%) Yes	
Capsular invasion			Fisher exact
Lateral metastases			
Without	87 (96.67)	16 (76.19)	p=0.006
With	3 (3.33)	5 (23.81)	
Central metastases			
Without	71 (78.89)	17 (80.95)	p=1
With	19 (21.11)	4 (19.05)	
Central & lateral metastases			
Without	70 (77.78)	13 (61.9)	Pearson χ^2 $\chi^2_1=2.27$;p=0.13
With	20 (22.22)	8 (38.1)	
Total	90 (100)	21 (100)	-
Multifocality	No (1 tumor)	Yes (≥ 2 tumors)	Pearson χ^2
Lateral metastases			
Without	60 (89.55)	43 (97.73)	Fisher exact p=0.14
With	7 (10.45)	1 (2.27)	
Central metastases			
Without	53 (79.1)	35 (79.55)	$\chi^2_1=0.003$;p=0.96
With	14 (20.9)	9 (20.45)	
Central & lateral metastases			
Without	49 (73.13)	34 (77.27)	$\chi^2_1=0.24$;p=0.62
With	18 (26.87)	10 (22.73)	
Total	67 (100)	44 (100)	-
Bilaterality ^a	No (1 lobe)	Yes (2 lobes)	Fisher exact
Lateral metastases			
Without	20 (100)	23 (95.83)	p=1
With	0 (0)	1 (4.17)	
Central metastases			
Without	17 (85)	18 (75)	p=0.48
With	3 (15)	6 (25)	
Central & lateral metastases			
Without	17 (85)	17 (70.83)	p=0.31
With	3 (15)	7 (29.17)	
Total	20 (100)	24 (100)	-

^a applies only to patients with 2 or more tumors (N=44 patients; Table 1)

difference in the rate of central LNMs in regard to tumor size categories (≤ 5 mm vs 5.1-10 mm), although there were more patients with central LNMs in the subgroup with larger tumors (17 vs 28%, respectively). In addition, the frequency of central LNMs was not higher in multifocal or bilateral tumors, or tumors with capsular invasion. These results are in agreement with those in the study by Roh et al. [20]. However, opposite findings were obtained by other studies [16,17]. The authors of the present study routinely and safely perform central neck dissection because tumor size and other factors cannot be treated reliably

enough for prediction of LNMs. Similarly, the macroscopic characteristics of lymph nodes cannot be sufficient enough to decide upon presence or absence of metastases. Also, LNMs often do not uptake radioactive iodine and can only be treated surgically [21].

In hands of experienced surgeons, complications are very rare [22]. In this study, only one in 111 patients (0.9%) had recurrent laryngeal nerve injury, with immediate repair by direct anastomosis, while there were no patients with permanent hypoparathyroidism. One of the advantages of methylene blue dye injection for SLN mapping

Table 4. Cross tabulation of data on sentinel lymph nodes pathology, validity, predictability and accuracy of the sentinel lymph node biopsy technique

Characteristics	N (%)
Frozen section & definitive histopathology of SLN ^{a,b}	
Malignant & Malignant	4 (3.67)
Malignant & Benign	0 (0)
Benign & Malignant	3 (2.75)
Benign & Benign	102 (93.58)
Total	109 (100)
Statistical evaluation of SLN ^a biopsy method	
Sensitivity	57.14
Specificity	100.00
Positive predictive value	100.00
Negative predictive value	97.14
Accuracy	97.25

^asentinel lymph nodes, ^b data for N=109 patients – without 2 patients with inconclusive frozen section analysis on sentinel lymph nodes (definitive histopathology results were: benign in one and malignant in another one patient)

is coloring of central lymph nodes. This provides reliable distinction between blue stained lymph nodes and parathyroid glands that do not uptake the vital dye, so it is easier to identify them and preserve during dissection. This is especially important for less experienced surgeons.

The rate of lateral LNMs in PTMCs is not negligible in the relevant literature. The frequency of lateral LNMs at PTMCs in study by Zeng et al. is approximately 35% [23] which is almost 5-fold higher than the 7.21% observed in our study. Independent predictive factors for the occurrence of lateral LNMs are: presence of LNMs in the central compartment [23,24], extrathyroid extension and tumor multifocality [16]. In the present study, only capsular invasion of the tumor was statistically significant factor associated with lateral LNMs.

Lateral LNMs without metastases in the central region (skip metastases) were observed in 4.5% of our patients. Similarly, Chung et al. reported skip metastases in 7.7% [25]. On the contrary, Kim in his work detected such pattern of metastases in only 0.6% [26]. Chung et al. could not find any specific characteristics of the tumor to be associated with the appearance of skip metastases [25]. Zhang et al. reported that tumors localized in the upper third of the lobes have a higher risk of lateral LNMs in comparison to the central LNMs [16].

SLN biopsy of the lateral neck region is a useful method for detection of occult LNMs (clini-

cally N0 patients). Ultrasonography detects only a small proportion of metastatic lymph nodes in the lateral compartment if they are clinically non-palpable [27].

Either methylene blue dye [11] or Tc 99m could be used for successful mapping of SLNs [28]. No radioactive marker is used at IORS for thyroid cancer.

With this method of lymph node mapping using methylene blue dye and frozen section analysis of SLNs, 7% of patients with PTMCs were converted from cN0 to pN1b stage, the stage that carries the risk of recurrence [29], and therapeutic sLND is necessary for these patients [30]. SLN biopsy provided proper staging of the disease, with agreement of frozen section and definite pathological analysis of SLNs in 97.25% of the patients that were accurately selected for one-time sLND. The sensitivity of the method is low (57%) since SLN micrometastases were not identified on frozen section analysis in 3 patients. Identification of occult metastases of the lateral neck region enables the surgeon, to identify patients at high risk who would benefit from some additional therapy, i.e. radioactive iodine therapy or closer follow-up.

PTMCs often give metastases in the central and lateral neck regions. Predictive factors for lateral LNMs, as pathological characteristics of tumors, cannot help the surgeon to decide for one-time lateral neck dissections. SLN biopsy of the lateral neck compartments is more precise than physical examination and ultrasonography for detection of lateral LNMs in clinically N0 patients with PTMCs. Intraoperative assessment of the lateral compartments by frozen section analysis of SLNs is useful to avoid unnecessary dissections, as well as undertreatment of patients with occult LNMs present at initial operation. SLN biopsy, after methylene blue dye injection, can be used for intraoperative identification of high-risk subgroups of patients with PTMCs who would benefit from additional one-time lateral neck dissections. The greatest value of this method is appropriate staging which optimizes treatment for patients with PTMCs. Although PTMCs are considered as prognostically good, not all cases behave biologically the same way, which leaves space for further research.

Acknowledgements

The study was reviewed by the Medical Ethics Committee of the School of Medicine in Belgrade,

Republic of Serbia, and performed in accordance with the ethical standards laid down in the appropriate version of the 1964 Declaration of Helsinki. Our study was approved by the Institutional Review Board of the Institute of Oncology and Radiology of Serbia and conducted with the understanding and consent of all subjects involved. The study was entirely financed by the project of the Ministry of Science of the Republic of Serbia: "Early diagnosis of lymph node metastases using sentinel lymph

node biopsy in epithelial malignant tumors", 2005 (project number 111601). Study sponsors had no involvement in the study design, in the collection, analysis and interpretation of data, in the writing of the manuscript, and in the decision to submit the manuscript for publication.

Conflict of interests

The authors declare no conflict of interests.

References

- Baloch ZW, LiVolsi VA. Microcarcinoma of the thyroid. *Adv Anat Pathol* 2006;13:69-75.
- Boucek J, Kastner J, Skrivan J et al. Occult thyroid carcinoma. *Acta Otorhinolaryngol Ital* 2009;29:296-304.
- Grodski S, Delbridge L. An update on papillary microcarcinoma. *Curr Opin Oncol* 2009;21:1-4.
- Miyauchi A. Clinical Trials of Active Surveillance of Papillary Microcarcinoma of the Thyroid. *World J Surg* 2016;40:516-522.
- Mercante G, Frasoldati A, Pedroni C et al. Prognostic factors affecting neck lymph node recurrence and distant metastasis in papillary microcarcinoma of the thyroid: results of a study in 445 patients. *Thyroid* 2009;19:707-716.
- Piana S, Ragazzi M, Tallini G et al. Papillary thyroid microcarcinoma with fatal outcome: evidence of tumor progression in lymph node metastases: report of 3 cases, with morphological and molecular analysis. *Hum Pathol* 2013;44:556-565.
- Orsenigo E, Beretta E, Fiacco E et al. Management of papillary microcarcinoma of the thyroid gland. *Eur J Surg Oncol* 2004;30:1104-1106.
- Besic N, Zgajnar J, Hocevar M, Petric R. Extent of thyroidectomy and lymphadenectomy in 254 patients with papillary thyroid microcarcinoma: a single-institution experience. *Ann Surg Oncol* 2009;16:920-928.
- Donatini G, Castagnet M, Desurmont T, Rudolph N, Othman D, Kraimps JL. Partial Thyroidectomy for Papillary Thyroid Microcarcinoma: Is Completion Total Thyroidectomy Indicated? *World J Surg* 2016;40:510-515.
- Ardito G, Avenia N, Giustozzi E et al. Papillary thyroid microcarcinoma: proposal of treatment based on histological prognostic factors evaluation. *Ann Ital Chir* 2014;85:1-5.
- Dzodic R, Markovic I, Inic M et al. Sentinel lymph node biopsy may be used to support the decision to perform modified radical neck dissection in differentiated thyroid carcinoma. *World J Surg* 2006;30:841-846.
- Haugen BR, Alexander EK et al. 2015 American Thyroid Association Management Guidelines for Adult Patients with Thyroid Nodules and Differentiated Thyroid Cancer: The American Thyroid Association Guidelines Task Force on Thyroid Nodules and Differentiated Thyroid Cancer. *Thyroid* 2016;26:1-133.
- Wada N, Duh QY, Sugino K et al. Lymph node metastasis from 259 papillary thyroid microcarcinomas: frequency, pattern of occurrence and recurrence, and optimal strategy for neck dissection. *Ann Surg* 2003;237:399-407.
- Gülben K, Berberoğlu U, Celen O, Mersin HH. Incidental papillary microcarcinoma of the thyroid--factors affecting lymph node metastasis. *Langenbecks Arch Surg* 2008;393:25-29.
- Varshney R, Pakdaman MN, Sands N et al. Lymph node metastasis in thyroid papillary microcarcinoma: a study of 170 patients. *J Laryngol Otol* 2014;128:922-925.
- Zhang L, Wei WJ, Ji QH et al. Risk factors for neck nodal metastasis in papillary thyroid microcarcinoma: a study of 1066 patients. *J Clin Endocrinol Metab* 2012;97:1250-1257.
- Lee SH, Lee SS, Jin SM, Kim JH, Rho YS. Predictive factors for central compartment lymph node metastasis in thyroid papillary microcarcinoma. *Laryngoscope* 2008;118:659-662.
- Roti E, degli Uberti EC, Bondanelli M, Braverman LE. Thyroid papillary microcarcinoma: a descriptive and meta-analysis study. *Eur J Endocrinol* 2008;159:659-673.
- Zhao Q, Ming J, Liu C et al. Multifocality and total tumor diameter predict central neck lymph node metastases in papillary thyroid microcarcinoma. *Ann Surg Oncol* 2013;20:746-752.
- Roh JL, Kim JM, Park CI. Central cervical nodal metastasis from papillary thyroid microcarcinoma: pattern and factors predictive of nodal metastasis. *Ann Surg Oncol* 2008;15:2482-2486.
- Kaczka K, Luks B, Jasion J, Pomorski L. Sentinel lymph node in thyroid tumors - own experience. *Contemp Oncol* 2013;17:184-189.
- White ML, Gauger PG, Doherty GM. Central lymph node dissection in differentiated thyroid cancer.

- World J Surg 2007;31:895-904.
23. Zeng RC, Zhang W, Gao EL et al. Number of central lymph node metastasis for predicting lateral lymph node metastasis in papillary thyroid microcarcinoma. *Head Neck* 2014;36:101-106.
 24. Kwak JY, Kim EK, Kim MJ et al. Papillary microcarcinoma of the thyroid: predicting factors of lateral neck node metastasis. *Ann Surg Oncol* 2009;16:1348-1355.
 25. Chung YS, Kim JY, Bae JS et al. Lateral lymph node metastasis in papillary thyroid carcinoma: results of therapeutic lymph node dissection. *Thyroid* 2009;19:241-246.
 26. Kim YS. Patterns and predictive factors of lateral lymph node metastasis in papillary thyroid microcarcinoma. *Otolaryng Head Neck Surg* 2012;147:15-19.
 27. Roh JL, Park JY, Kim JM, Song CJ. Use of preoperative ultrasonography as guidance for neck dissection in patients with papillary thyroid carcinoma. *J Surg Oncol* 2009;99:28-31.
 28. Lee SK, Kim SH, Hur SM, Choe JH, Kim JH, Kim JS. The efficacy of lateral neck sentinel lymph node biopsy in papillary thyroid carcinoma. *World J Surg* 2011;35:2675-2682.
 29. Wang LY, Palmer FL, Nixon IJ et al. Lateral Neck Lymph Node Characteristics Prognostic of Outcome in Patients with Clinically Evident N1b Papillary Thyroid Cancer. *Ann Surg Oncol* 2015;22:530-536.
 30. Ito Y, Miyauchi A, Inoue H et al. An observational trial for papillary thyroid microcarcinoma in Japanese patients. *World J Surg* 2010;34:28-35.