



CODEN [USA]: IAJPB

ISSN: 2349-7750

INDO AMERICAN JOURNAL OF PHARMACEUTICAL SCIENCES

Available online at: <http://www.iajps.com>

Research Article

THE ROLE OF LACTULOSE FOR THE PROPHYLAXIS OF HEPATIC ENCEPHALOPATHY IN PATIENTS WITH ACUTE VARICEAL BLEED

¹Sabir Hussain, ²Mujahid Iqbal, ³Huda Abbas, ⁴Wajahat Hussain, ⁵Muhammad Imran, ⁶Muzammil Irshad

¹FCPS (Medicine), Assistant professor Medicine, Ghazi khan Medical College Dera Ghazi Khan., ²FCPS (Medicine), Assistant professor Medicine, Ghazi khan Medical College Dera Ghazi Khan, ³MCPS (Community Medicine), Assistant Professor Community Medicine, Quaid-e-Azam Medical College, Bahawalpur, ⁴MPH, FCPS (Community Medicine), Demonstrator Community Medicine Quaid-e-Azam Medical College, Bahawalpur, ⁵MSPH, DHQ Hospital, Layyah., ⁶FCPS (Medicine), Nishtar Medical University, Multan.

Article Received: December 2018

Accepted: February 2019

Published: March 2019

Abstract:

Background: Lactulose, a non-absorbable osmotic laxative, is frequently used in the treatment and prevention of overt hepatic encephalopathy in patients with cirrhosis and acute variceal bleed.

Objective: To determine the role of lactulose for the prophylaxis of hepatic encephalopathy in the patients with acute variceal bleed.

Material and Methods: This quasi experimental study was conducted at Nishtar Medical University and Hospital Multan from July 2018 to December 2018 after taking ethical approval from institutional review board. All the patients of either gender, fulfilling the inclusion criteria, were included in the study after having informed consent. Complete history and examination were carried out in all patients. All the patients were given lactulose in a dose of 30 ml three times a day. Patients were followed up for the presence of any feature of hepatic encephalopathy for 48 hours after admission by the researchers. All the data was entered and analyzed using SPSS version 17.

Results: There were 186 patients in total. Males were 60.8% while females were 39.2%. Mean duration of bleed was 49.92±18.78 hours. Overall, hepatic encephalopathy was diagnosed to be present in 20.4% while it was absent in 79.6%. Lactulose failed to prevent hepatic encephalopathy in 21.90% males and 19.50% females (p -value = 0.712). In terms of age, lactulose was ineffective within 48 hours of treatment in 16.30%, 23.10%, 21.30% patients in age groups < 30 years, 31-45 years and > 45 years, respectively (p -value = 0.75). Similarly, lactulose was found to be ineffective in 18%, 19.40% and 23.40% patients at duration of 01, 02 and 03 days of treatment, respectively (p -value = 0.82).

Conclusion: Lactulose is effective in the prophylaxis of hepatic encephalopathy in patients with acute variceal hemorrhage.

Key words: Lactulose, Hepatic Encephalopathy, Acute variceal hemorrhage.

Corresponding author:**Sabir Hussain,**

FCPS (Medicine), Assistant professor Medicine,
Ghazi khan Medical College Dera Ghazi Khan.

QR code



Please cite this article in press Sabir Hussain et al., *The Role Of Lactulose For The Prophylaxis Of Hepatic Encephalopathy In Patients With Acute Variceal Bleed.*, Indo Am. J. P. Sci, 2019; 06(03).

INTRODUCTION:

Cirrhosis, one of the significant causes of morbidity and mortality throughout the world, is the most common non-neoplastic cause of death among the hepatobiliary diseases [1]. Hepatic encephalopathy, a common but potentially reversible complication of cirrhosis, is a neuropsychiatric syndrome that can develop in chronic liver disease (CLD) and acute liver failure, characterized by cognitive and motor deficit [2]. Symptoms of hepatic encephalopathy include disorientation, poor coordination and confusion. A general consensus exists that the excess of ammonia and inflammation cause astrocyte swelling and cerebral edema [3]. Precipitating factors of hepatic encephalopathy include infection, constipation, gastrointestinal bleed, electrolyte disturbances, hepatocellular carcinoma (HCC), dehydration, hypotension, use of benzodiazepines and alcohol [4]. Treatment options depend on the acuity of hepatic encephalopathy. Indoor management includes supportive care, reversal of precipitating factors and lactulose or rifaximin therapy [5]. Frequency of precipitating factors is found to be different in various studies. Upper gastrointestinal bleed (56%) is one of the leading precipitating factors, including the acute variceal bleed [6].

Lactulose, a non-absorbable osmotic laxative, is an effective agent used in the prevention of hepatic encephalopathy in patients with cirrhosis and acute variceal bleed as it reduces ammoniagenic substrates in the gut. An Indian study reported that only 14% of the patients with acute variceal bleed developed hepatic encephalopathy in lactulose group compared to 40% in non-lactulose group. [7,8]

OBJECTIVE:

To evaluate the role of lactulose for the prophylaxis of hepatic encephalopathy in patients with acute variceal bleed.

OPERATIONAL DEFINITIONS:

Hepatic encephalopathy: It was labeled to be present or positive if any one of the following three features were encountered in 48 hours after starting lactulose:

- **Flapping tremors:** These were the tremors of hand when wrist was extended resembling bird flapping its wings.
- **Constructional apraxia:** An inability or difficulty to build, assemble or draw objects.
- **Altered sensorium:** GCS score less than or equal to 12/15.

It was labeled to be absent or negative if the above-mentioned features were not encountered in 48 hours

after starting lactulose.

Acute variceal bleed: It was diagnosed on the basis of history of haematemesis or melena of duration less than 72 hours and was confirmed by the presence of coffee-ground / black / bloody aspirate from the nasogastric tube.

Role of lactulose: It was labeled as effective when patients receiving lactulose had no above-mentioned features of hepatic encephalopathy within 48 hours of starting lactulose and labeled as ineffective when patients receiving lactulose developed above-mentioned features of hepatic encephalopathy within 48 hours of starting lactulose.

MATERIAL AND METHODS:

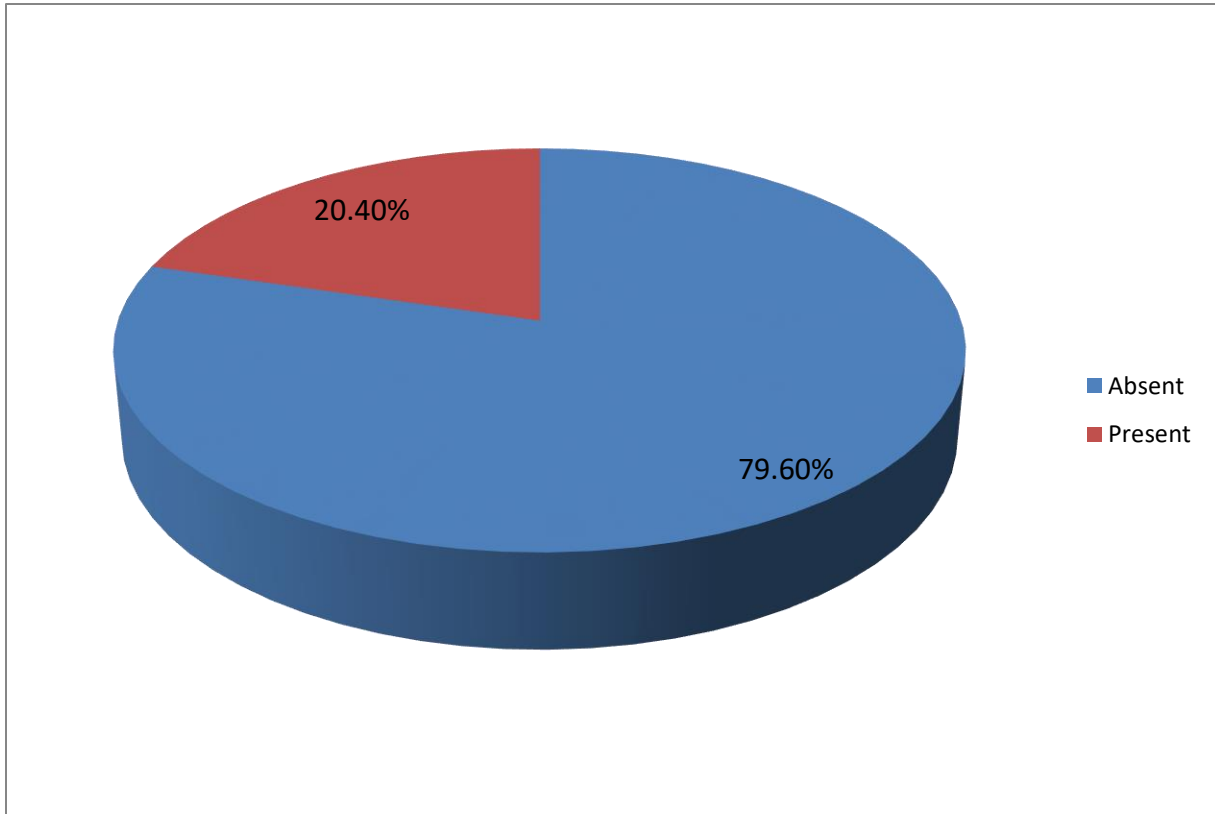
This quasi experimental study was conducted in Nishtar Hospital, Multan from July 2018 to December 2018 after taking ethical approval from institutional review board. All the patients of either gender, between 18-60 years age, presenting with first episode of variceal bleeding and having upper gastrointestinal bleed, identified by the presence of hematemesis, melena, hematochezia or a positive nasogastric tube aspiration of coffee-ground, black or bloody contents admitted in the medical ward during study duration were included in the study. Exclusion criteria was signs of hepatic encephalopathy, history of haematemesis or melena of duration more than 72 hours, patients having other precipitating factors for hepatic encephalopathy like constipation for > 24 hours, infections (spontaneous bacterial peritonitis, urinary tract infection or respiratory tract infection), electrolyte imbalance (hypokalemia serum potassium < 3.5), serious co-morbid illness (like renal, cardiac or respiratory failure, neurological problem) and patients not willing to take part in the study. Patients who fulfilled the inclusion criteria were explained about the nature and purpose of the study and informed consent was taken. Complete history and examination was carried out in all patients. All the patients were given lactulose in a dose of 30ml three times a day. Patients were followed up for the presence of any feature of hepatic encephalopathy for 48 hours after admission by the researchers. All the data was entered and analyzed by using SPSS version 17. Chi square test was applied to see any statistical difference between the groups. P value ≤ 0.05 was taken as significant.

RESULTS:

There were 186 patients in total. Males were 60.8% while females were 39.2% (Graph 1). Mean age of the patients was 42.02 + 13.31. Mean duration of bleed was 49.92 + 18.78 hours. Overall, hepatic encephalopathy was diagnosed to be present in 20.4%

while it was absent in 79.6%(Graph 1. Flaps were identified after treatment in 20.4%, apraxia 20.4%

while altered sensorium was observed in 12.9% patients.



Graph 1: Frequency of Hepatic Encephalopathy in Patients with Acute Variceal Hemorrhage After Treatment with Lactulose.

Table 1: Gender distribution of study participants (n=186)

Gender	Frequency	Percentage
Males	113	60.8%
Females	73	39.2%
Total	186	100%

Table 2: Age distribution of study participants (n=186)

Age	Frequency	Percentage
< 30	49	26.3
30-45	52	27.9
> 45	85	45.8
Total	186	100

When the effect of gender was noted on the role of lactulose in the prevention of hepatic encephalopathy it was found that among 113 males mean age was 41.63 + 13.09 years, mean duration of bleeding was

2.11 + 0.82 days, flapping tremors were identified in 22/113 (19.5%), Constructional apraxia in 22/113 (19.5%) and altered sensorium in 15/113 (13.3%). Overall among males encephalopathy was diagnosed

to be present in 22/113 (19.5%). Among 73 females, mean age was 42.62 + 13.71 years, mean duration of bleeding was 2.03 + 0.73 days, flapping tremors and constructional apraxia was present in 16/73 (21.9%)

while altered sensorium developed in 9/73 (12.3%). Overall hepatic encephalopathy was diagnosed in 16/73 (21.9%) females. P-value was found out to be 0.686 (Graph 3, Table 5).

Table 3: Gender distribution of the respondents and hepatic encephalopathy

		Males (n= 113)	Females (n= 73)	p-value
Flapping tremors	Present	22	16	0.686
	Absent	91	57	
Constructional apraxia	Present	22	16	0.686
	Absent	91	57	
Altered sensorium	Present	15	9	0.851
	Absent	98	64	
Hepatic encephalopathy	Present	22	16	0.686
	Absent	91	57	

When the effect of age was noted on the frequency of development of hepatic encephalopathy in patients with acute variceal hemorrhage it was found that among patients in age group < 30 years, there were 49 patients in total, males were 29/49 (59.2%) while females were 20/49 (40.8%). Mean duration of bleeding was 1.98 + 0.75 days. Flaps and constructional apraxia developed in 8/49 (16.3%) while altered sensorium developed in 4/49 (8.2%). Overall, hepatic encephalopathy was diagnosed in 8/49 (16.3%). Among patients in age group 31-45 years, there were 52 patients in total, males were 35/52

(67.3%) while females were 17/52 (32.7%). Mean duration of bleeding was 2.10 + 0.79 days. Flaps and constructional apraxia developed in 12/52 (23.1%) while altered sensorium developed in 9/52 (17.3%). Overall, hepatic encephalopathy was diagnosed in 12/52 (23.1%). Among patients in age group > 45 years, there were 85 patients in total, males were 49/85 (57.6%) while females were 36/85 (42.4%). Mean duration of bleeding was 2.12 + 0.79 days. Flaps and constructional apraxia developed in 18/85 (21.3%) while altered sensorium developed in 11/85 (12.9%). Overall, hepatic encephalopathy was diagnosed in 18/85 (21.2%) (p-value = 0.684). (Graph 4, Table 6).

Table 4: Age Distribution of Study participants and hepatic encephalopathy

		Age < 30 (n = 49)	Age 30-45 (n= 52)	Age > 45 (85)	p-value
Flapping tremors	Present	8	12	18	0.684
	Absent	41	40	67	
Constructional apraxia	Present	8	12	18	0.684
	Absent	41	40	67	
Altered sensorium	Present	4	9	11	0.391
	Absent	45	43	74	
Hepatic encephalopathy	Present	8	12	18	0.684
	Absent	41	40	67	

When the effect of duration of bleeding was noted on the frequency of development of hepatic encephalopathy in patients with acute variceal hemorrhage it was found that in patients with duration

of bleed < 1 day, there were 50 patients in total, males were 32 (64%) while females were 18 (36%). Flaps and constructional apraxia developed in 9/50 (18%) while altered sensorium developed in 2/50 (4%).

Overall, hepatic encephalopathy was diagnosed in 9/50 (18%). Among patients with duration of bleeding > 2 days, there were 136 patients in total. Flaps and constructional apraxia developed in 29/136 (21.32%)

while altered sensorium developed in 22/136 (16.18%). Overall, hepatic encephalopathy was diagnosed in 29/136 (21.32%). P-value was found out to be 0.618. (Graph 5, Table 7).

Table 7: Duration of upper GI bleeding and hepatic encephalopathy

		Duration < 1 days (n= 50)	Duration > 2 days (n = 136)	p-value
Flapping tremors	Present	9	29	0.618
	Absent	41	107	
Constructional apraxia	Present	9	29	0.618
	Absent	41	107	
Altered sensorium	Present	2	22	0.051
	Absent	48	114	
Hepatic encephalopathy	Present	9	29	0.618
	Absent	41	107	

DISCUSSION:

Hepatic encephalopathy (HE) is a neuropsychiatric disorder due to effects of various toxins that accumulate in the blood because of inability of the liver to perform normal detoxifying functions. The majority of drugs used in the treatment of HE are primarily directed at the reductions or elimination of the increased neurotoxic ammonia levels. The intestinal ammonia productions and the action of the toxin can be reduced by the elimination of bacterial flora in the gut. The treatment of choice for altering bacterial flora is non-absorbable disaccharides, such as lactulose and lactitol. Lactulose exerts a bifidogenic effect accompanied by a favorable effect on the colonic ammonia metabolism.

Variceal hemorrhage occurs in 25–30% of patients with cirrhosis. Development of HE is a serious complication following variceal bleeding and is associated with increased morbidity and mortality. The intestinal absorption of toxic substances generated from blood proteins is the main pathophysiologic mechanism for the development of HE following upper gastrointestinal bleeding. Treatment with enemas, gut irrigation with mannitol, paramomyacie and lactulose has been used for rapid elimination of blood from the gastrointestinal tract and modification of intestinal bacterial flora for the prevention of development of HE. We performed this study to evaluate the efficacy of lactulose for prevention of development of clinically overt HE following upper gastrointestinal bleeding in patients with cirrhosis.⁹

¹⁰The exact mode of action by lactulose is thought to

be the conversion to lactic acid and acetic acid resulting in acidification of the gut lumen. This favors conversion of ammonia (NH₃) to ammonium (NH₄⁺), which is relatively membrane impermeable; therefore, less ammonia is absorbed by the colon. Gut acidification inhibits ammoniagenic coliform bacteria, leading to increased levels of nonammoniagenic lactobacilli. Nonabsorbable disaccharides also work as a cathartic, clearing the gut of ammonia before it can be absorbed. [11]

Lactulose is effective in the management of acute and chronic hepatic encephalopathy. Recently, it has been shown that lactulose is also effective in the prevention of secondary episodes of HE. [10] Orthograde whole gut irrigation with mannite or paromomycine plus lactulose have found to be effective in the prevention of HE after upper gastrointestinal bleed in some previous trials. It has also been shown that treatment with lactulose can clear blood from the bowel more effectively which also plays a role in the prevention of HE.

In our study there were 186 patients in total. Males were 113/186 (60.8%) while females were 73/186 (39.2%). Mean age of the patients was 42.02 + 13.31. Mean duration of bleed was 2.08 + 0.78 days. Flaps were identified after treatment in 38/186 (20.4%), apraxia was found in 38/186 (20.4%) while altered sensorium was found in 24/186 (12.9%). Overall, hepatic encephalopathy was diagnosed to be present in 38/186 (20.4%) while it was absent in 148/186 (79.6%) patients. The frequency of hepatic

encephalopathy in our study was slightly higher than that reported in a randomized controlled trial conducted in 2011 with seventy patients in which authors concluded that lactulose is effective for prevention of hepatic encephalopathy in patients with acute variceal hemorrhage. [12]

In our study when the effect of gender was noted on the effectiveness of lactulose in the prevention of hepatic encephalopathy it was found that male patients had slightly more chances of development of hepatic encephalopathy as 21.90% of the male patients as compared to 19.50% of the female patients developed the signs of hepatic encephalopathy within 48 hours of starting the treatment with lactulose. However, this difference was very small and statistically non-significant as p-value turned out to be 0.712 after application of chi-square test. When the effect of age was noted on the effectiveness of lactulose it was found that patients in age group 31-45 years had shown the highest trend for the development of hepatic encephalopathy with as many as 23.10% of these patients developed the signs of hepatic encephalopathy despite treatment with lactulose. On the other hand patients in age group < 30 years had the highest effectiveness of lactulose as only 16.30% of these patients developed encephalopathy. Patients in age group > 45 years also showed a higher trend for lactulose ineffectiveness with 21.30% of patients manifesting one or more features of hepatic encephalopathy despite lactulose treatment. One explanation of this difference could have been the advancement of the underlying liver disease in elderly patients as compared to younger patients, however we did not include the parameters for assessment of severity of underlying liver disease such as Child's scoring or MELD scoring. The difference, however, was statistically non-significant with a p-value of 0.75.

When the effect of duration of bleeding was noted on the effectiveness of lactulose it was found that the trend was higher ineffectiveness of the lactulose treatment in preventing encephalopathy as the duration of bleeding prolonged. It was found that lactulose was most effective in preventing encephalopathy in patients with duration of bleeding within 1 day as only 18% of patients demonstrated signs of encephalopathy after treatment with lactulose. This percentage rose to 19.40% in those with duration of bleeding 2 days and was highest in those with duration of bleeding 3 days in whom as many as 23.40% of the patients developed encephalopathy. This difference was also statistically non-significant with p-value = 0.82. However, it provides a clue towards the fact that early institution of lactulose in

patients with acute variceal hemorrhage does decrease the chances of hepatic encephalopathy more than late institution of the treatment.

Our data also confirms the results of some previously published trials on the effects of whole gut irrigation with mannitol and one with lactulose plus paromomycin.¹³ Most of these studies used Linton's or Sengstaken-Blakemore tube to stop bleeding or partly used sclerotherapy to control bleeding. Most of these studies have not used antibiotics or vasoactive therapy like somatostatin or terlipressin. The main strength of our study was that it had followed the standard protocol and all of the patients received ceftriaxone, terlipressin/somatostatin and underwent endoscopic band ligation within 12 h of presentation, which is the standard of treatment followed all over the world.

The main limitations of our study was that it was not a randomized controlled trial which could have provided a much more firm evidence in favor of lactulose in prevention of hepatic encephalopathy. Another limitation of our study was that we did not do gut's bacterial flora analysis to assess the role of lactulose on gut flora but this had been assessed in previous trials in the literature. [14] Also, we could not measure arterial ammonia in patients at baseline or during follow up which could have given us evidence for the effectiveness of lactulose in decreasing ammonia levels. However, it has been shown earlier in previous studies that lactulose decreased arterial ammonia levels and has a bifidogenic effect accompanied by a favorable effect on colonic ammonia metabolism. [15] We believe that lactulose would have acted by these mechanisms, resulting in reduced frequency of hepatic encephalopathy as compared to patients not treated with lactulose.

CONCLUSION:

To conclude, this study shows that lactulose is effective in the prevention of hepatic encephalopathy in patients with cirrhosis and acute upper gastrointestinal bleed irrespective of the age, gender or duration of bleed and thus should be an immediate and integral part of the treatment regimen in all such patients.

REFERENCES:

1. Agrawal A, Sharma BC, Sharma P, Sarin SK. Secondary prophylaxis of hepatic encephalopathy in cirrhosis: an open-label, randomized controlled trial of lactulose, probiotics, and no therapy. The American journal of gastroenterology. 2012 Jul;107(7):1043.

2. Felipo V. Hepatic encephalopathy: effects of liver failure on brain function. *Nature Reviews Neuroscience*. 2013 Dec;14(12):851.
3. Gluud LL, Dam G, Borre M, Les I, Cordoba J, Marchesini G, Aagaard NK, Vilstrup H. Lactulose, rifaximin or branched chain amino acids for hepatic encephalopathy: what is the evidence?. *Metabolic brain disease*. 2013 Jun 1;28(2):221-5.
4. Kimer N, Krag A, Møller S, Bendtsen F, Gluud LL. Systematic review with meta-analysis: the effects of rifaximin in hepatic encephalopathy. *Alimentary pharmacology & therapeutics*. 2014 Jul;40(2):123-32.
5. Luo M, Li L, Lu CZ, Cao WK. Clinical efficacy and safety of lactulose for minimal hepatic encephalopathy: a meta-analysis. *European journal of gastroenterology & hepatology*. 2011 Dec 1;23(12):1250-7.
6. Maharshi S, Sharma BC, Srivastava S, Jindal A. Randomised controlled trial of lactulose versus rifaximin for prophylaxis of hepatic encephalopathy in patients with acute variceal bleed. *Gut*. 2015 Aug 1;64(8):1341-2.
7. Rahimi RS, Singal AG, Cuthbert JA, Rockey DC. Lactulose vs polyethylene glycol 3350-electrolyte solution for treatment of overt hepatic encephalopathy: the HELP randomized clinical trial. *JAMA internal medicine*. 2014 Nov 1;174(11):1727-33.
8. Rai R, Saraswat VA, Dhiman RK. Gut microbiota: its role in hepatic encephalopathy. *Journal of clinical and experimental hepatology*. 2015 Mar 1;5:S29-36.
9. Fernández J, Tandon P, Mensa J, Garcia-Tsao G. Antibiotic prophylaxis in cirrhosis: Good and bad. *Hepatology*. 2016 Jun 1;63(6):2019-31.
10. Hussain A, Qayyum A, Muhammad D, Javed M, Iqbal MN. Bacteriology of spontaneous bacterial peritonitis. *Professional Med J*. 2007;14:551-5.
11. Sharma P, Sharma BC, Agrawal A, Sarin SK. Primary prophylaxis of overt hepatic encephalopathy in patients with cirrhosis: an open labeled randomized controlled trial of lactulose versus no lactulose. *Journal of gastroenterology and hepatology*. 2012 Aug;27(8):1329-35.
12. Sharma P, Agrawal A, Sharma BC, Sarin SK. Prophylaxis of hepatic encephalopathy in acute variceal bleed: a randomized controlled trial of lactulose versus no lactulose. *J Gastroenterol Hepatol*. 2011;26(6):996-1003.
13. Tromm A, Griga T, Greving I. Orthograde whole gut irrigation with mannite versus paromomycine + lactulose as prophylaxis of hepatic encephalopathy in patients with cirrhosis and upper gastrointestinal bleeding: results of a controlled randomized trial. *Hepatogastroenterology*. 2000;47:473-7.
14. Bouhnik Y, Attar A, Joly FA. Lactulose ingestion increases faecal bifidobacterial counts: A randomised double-blind study in healthy humans. *Eur J Clin Nutr*. 2004;58:462-6.
15. Zakria M, Hussain SR, Abid Butt MR, Rana GF. Hepatic encephalopathy; precipitating factors in patients with cirrhosis. *Professional Med J*. 2008;15:375-9.