



CODEN [USA]: IAJ PBB

ISSN: 2349-7750

**INDO AMERICAN JOURNAL OF
PHARMACEUTICAL SCIENCES**Available online at: <http://www.iajps.com>

Research Article

**A RETROSPECTIVE ANALYSIS OF INCIDENCE OF
TRANSFORMATION OF LAPROSCOPIC
CHOLECYSTECTOMY INTO OPEN CHOLECYSTECTOMY****¹Dr. Nabeel Riaz, ²Dr. Rameesha Rashid, ³Dr. Quratulain Majeed Kayani**^{1,3}RHC Mandra Teh Gujar Khan, Rawalpindi, ²Federal Medical and Dental College, Islamabad.**Article Received:** December 2018**Accepted:** February 2019**Published:** March 2019**Abstract:**

Objective: To analyze the incidence of intraoperative risk factors responsible for the transformation of laparoscopic cholecystectomy into open cholecystectomy in our environment.

Study design: A retrospective analytical study.

Place and Duration: In the Surgical Department of Benazir Bhutto Hospital Rawalpindi for one year duration from September 2017 to September 2018.

Methods: All patients who underwent laparoscopic cholecystectomy (n=283) and underwent open surgery (n = 10) were included. The reasons behind the transformation and the factors leading to it were recorded.

Results: A retrospective analysis of 283 patients with ages ranging from 25 to 65 years with M: F, 2: 8 and body weight between 45 and 95 kilograms was analyzed. Ten out of two hundred and eighty-three (283) patients had to be converted into open cholecystectomy due to reasons such as visceral adhesions or dense omntal - 2 (0.7%), mirizi syndrome - 2 (0.7%), and intrahepatic thick gall bladder2 (0.7%), gallbladder carcinoma 1 (0.4%), gallbladder empyema 1 (0.4%), gallbladder 1 (0.4%), cirrhosis liver 1, (0.4%), perforated gall bladder 1 (0.4%) . The success rate of cholecystectomy was 96.5% (273 of 283 cases), and the conversion rate to open type was 3.5% (10 out of 283 cases).

Conclusion: The etiology responsible for the transformation of LC into OC is multifactorial, but adequate preoperative evaluation, good skills and laparoscopic surgical team, adequate experience and innovations are important factors in achieving successful laparoscopic cholecystectomy.

Key words: Open cholecystectomy, laparoscopic cholecystectomy, conversion rate, risk factors.

Corresponding author:**Dr. Nabeel Riaz,**

RHC Mandra Teh Gujar Khan, Rawalpindi.

QR code



Please cite this article in press Nabeel Riaz et al., *A Retrospective Analysis Of Incidence Of Transformation Of Laproscopic Cholecystectomy Into Open Cholecystectomy.*, Indo Am. J. P. Sci, 2019; 06(03).

INTRODUCTION:

Pathology related to hepatobiliary system constitutes an important part of digestive system disease. This is the most common problem of bile ducts among cholelithiasis. Carl-Langenbuch was credited for performing the first cholecystectomy in Berlin on 15 July 1882 [1]. However, the emergence of laparoscopic cholecystectomy has revolutionized the treatment of cholelithiasis [2]. In France, Philippe Moret (1987) performed laparoscopic cholecystectomy for the first time. Laparoscopic cholecystectomy was accepted as the gold standard in the treatment of patients with symptomatic cholelithiasis, and replaced conventional open cholecystectomy as outlined in the National Institutes of Health Consensus Conference2 (1993) [3]. However, some factors affect the outcome of laparoscopic cholecystectomy. The conversion rate of laparoscopy (LC) in open cholecystectomy (OC) depends on a variety of factors, including preoperative variables, intraoperative factors (findings), surgical skills, and the availability of the latest surgical instruments [4]. We present a retrospective study reporting our experience of Laparoscopic cholecystectomy and its causes of transformation into open type.

MATERIALS AND METHODS:

This retrospective analytical study was performed in two hundred thirty-eight patients between September 2017 to September 2018 who were operated for laparoscopic cholecystectomy. All patients under 65 years of age who presented with OPD with the diagnosis of cholelithiasis without contraindication to general anesthesia were included in the study. All patients underwent a standard 4-port laparoscopic cholecystectomy procedure. A detailed note of the reasons for conversion was recorded for patients undergoing conversion. Factors leading to transformation and how these factors can be prevented were also recorded.

RESULTS:

Ten out of two hundred and eighty-three (283) patients had to be converted into open cholecystectomy due to reasons such as dense omental or visceral adhesions - 2 (0.7%), mirizzi syndrome - 2 (0.7%), and vesicles, gallbladder carcinoma 1 (0.4%), gallbladder empyema 1 (0.4%), gallbladder 1 (0.4%), cirrhosis liver 1, (0.4%), perforated gall bladder 1 (0.4%). The success rate of cholecystectomy was 96.5% (273 of 283 cases), and the conversion rate to OK was 3.5% (10 out of 283 cases).

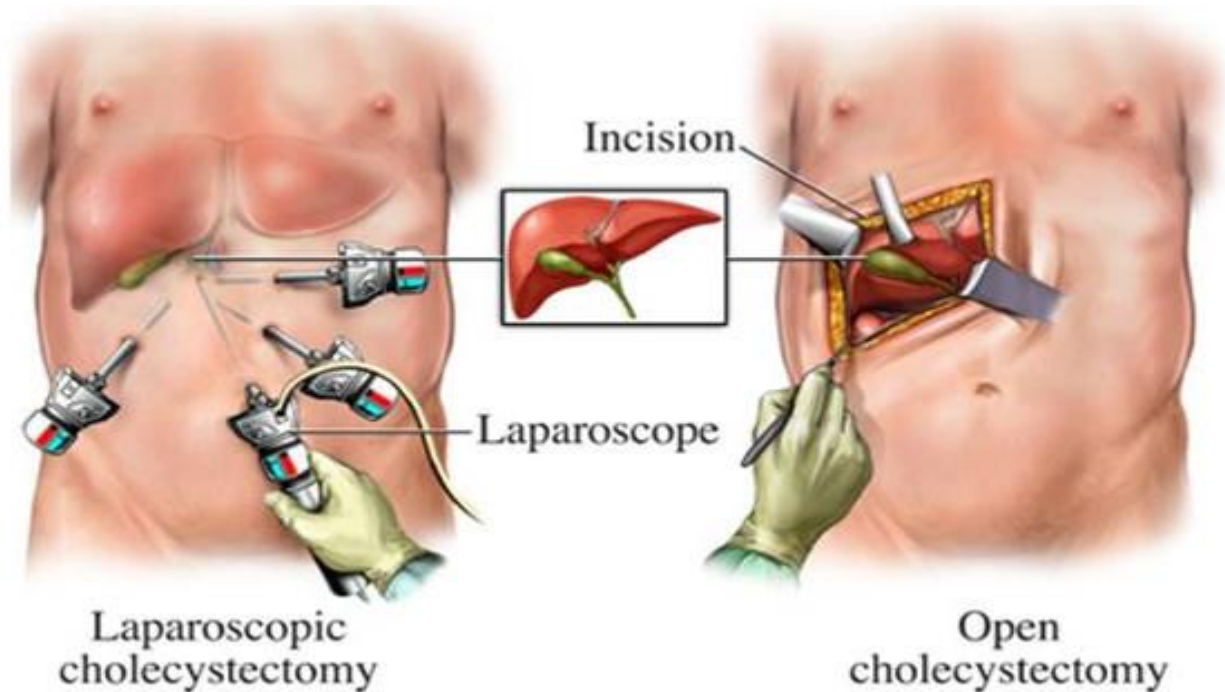
Table 1. Reasons for conversion from laparoscopic to open chole (n=10/283)

Reasons for conversion	No.	%age
Dense omental or visceral adhesions	2	0.7
Gall bladder mass	1	0.4
Empyema Gall bladder	1	0.4
Cirrhotic liver with shrunken gallbladder	1	0.4
Intrahepatic thick walled gall bladder	2	0.7
Mirizzi syndrome	2	0.7
Perforated Gall bladder	1	0.4
Total	10	3.5 %

DISCUSSION:

Complex findings per operation are the only factors responsible for the failure of laparoscopic cholecystectomy, leading to conversion to open cholecystectomy⁵⁻⁷. However, with the emergence of the latest equipment and equipment and the development of laproscopic skills, conversion rates have decreased in recent years. In our study, we

attempted to find the conversion rate of laparoscopic cholecystectomy in open cholecystectomy to be 3.5% among all cholecystectomies performed between September 2017 to September 2018 in the elective list⁸. These results can be compared with the results of any specialist center. However, there was little change in the percentage of etiologic factors that resulted from the transformation.



Among previous studies, the ratio of commitment-related transformation was very high up to 5.8%, but this rate was 0.7% in our study. Adhesions cause visual impairment of GB access and cause lesions in the intestines and other organs, but the percentage is significantly reduced by the presence of advanced devices such as ligasura and harmonic scalpel [9-10]. Similarly, the incidence of biliary leakage and uncontrolled bleeding from the cystic artery is treated with the latest and best adjoining ligatures. According to the review of the research article, in the last two decades, the reasons for the transformation were anatomy (50%), "others" (16%), and bleeding (14%). suspected choledocholithiasis (11%) and suspected bile duct injury (8%) [11]. In the laparoscopy, we successfully deal with complications such as choledocholithiasis, adhesions and bleeding from the cystic artery. The incidence of iatrogenic injury in CBD is negligible [12-14]. With the best understanding of the pathophysiology of cholelithiasis, the evolution of the latest diagnostic tools, the improvement and availability of advanced laparoscopic devices, and revised surgical skills, resulted in a significant reduction in conversion rates [15]. A severe change in open cholecystectomy as well as the percentage of factors responsible for transformation.

CONCLUSION:

The etiology responsible for the transformation of LC into OC is multifactorial, but adequate preoperative

evaluation, good skills and laparoscopic surgical team, adequate experience and innovations are important factors in achieving successful laparoscopic cholecystectomy.

REFERENCES:

1. Zhao, Rongce, Fei Liu, Chenyang Jia, Kefei Chen, Yonggang Wei, Junhua Chen, and Bo Li. "Hepatic Pedicle Occlusion with the Pringle Maneuver During Difficult Laparoscopic Cholecystectomy Reduces the Conversion Rate." *World journal of surgery* 43, no. 1 (2019): 207-213.
2. Mangieri, Christopher W., Bryan P. Hendren, Matthew A. Strode, Bradley C. Bandera, and Byron J. Faler. "Bile duct injuries (BDI) in the advanced laparoscopic cholecystectomy era." *Surgical endoscopy* 33, no. 3 (2019): 724-730. Mangieri, C. W., Hendren, B. P., Strode, M. A., Bandera, B. C., & Faler, B. J. (2019). Bile duct injuries (BDI) in the advanced laparoscopic cholecystectomy era. *Surgical endoscopy*, 33(3), 724-730.
3. Ambe, Peter C., Jens Plambeck, Victoria Fernandez-Jesberg, and Konstantinos Zarras. "The role of indocyanine green fluoroscopy for intraoperative bile duct visualization during laparoscopic cholecystectomy: an observational cohort study in 70 patients." *Patient safety in surgery* 13, no. 1 (2019): 2.
4. Griffiths, Ewen A., James Hodson, Ravi S.

- Vohra, Paul Marriott, Tarek Katbeh, Samer Zino, Ahmad HM Nassar, and West Midlands Research Collaborative. "Utilisation of an operative difficulty grading scale for laparoscopic cholecystectomy." *Surgical endoscopy* 33, no. 1 (2019): 110-121.
5. Fruscione, Mike, Russell C. Kirks, Allyson Cochran, Keith Murphy, Erin H. Baker, John B. Martinie, David A. Iannitti, and Dionisios Vrochides. "Routine versus difficult cholecystectomy: using predictive analytics to assess patient outcomes." *HPB* 21, no. 1 (2019): 77-86. Fruscione, M., Kirks, R. C., Cochran, A., Murphy, K., Baker, E. H., Martinie, J. B., ... & Vrochides, D. (2019). Routine versus difficult cholecystectomy: using predictive analytics to assess patient outcomes. *HPB*, 21(1), 77-86.
 6. Sala-Hernández, Angela, Pablo Granero Castro, Eva Montalvá Orón, Javier Maupoey Ibáñez, Rafael García-Domínguez, José Bueno Lledó, Jose Luís Ibáñez Cirión, and Rafael López Andújar. "Evaluation of Patient Safety and Satisfaction in a Program of Ambulatory Laparoscopic Cholecystectomy Program With Expanded Criteria." *Cirugía Española (English Edition)* 97, no. 1 (2019): 27-33.
 7. Saumoy, Monica, Amy Tyberg, Elizabeth Brown, Soumitra R. Eachempati, Michael Lieberman, Cheguevara Afaneh, Rastislav Kunda et al. "Successful Cholecystectomy After Endoscopic Ultrasound Gallbladder Drainage Compared With Percutaneous Cholecystostomy, Can it Be Done?." *Journal of clinical gastroenterology* 53, no. 3 (2019): 231-235.
 8. Khan, Saad Ullah, Jun Yi Soh, Nazli Muhibullah, Aikaterini Peleki, Muhammad Abdullah, and Peter William Waterland. "EMERGENCY LAPAROSCOPIC CHOLECYSTECTOMY: IS DEDICATED HOT GALL BLADDER LIST COST EFFECTIVE?." *Journal of Ayub Medical College Abbottabad* 31, no. 1 (2019): 3-7.
 9. Jain, Ankit, Peeyush Kumar, Shah Syed Mahmood, and Bachan Singh Barthwal. "'How Hot Is Too Hot to Handle': A Retrospective Analysis of 'Hot Cholecystectomy' at a Tertiary Care Centre." *Journal of Clinical & Diagnostic Research* 13, no. 1 (2019).
 10. Sharma, V., Kaundal, V., Sharma, A., Singh, G., Shah, P. and Kapoor, A., 2019. Giant gall stone: a rare finding performed with open cholecystectomy. *International Surgery Journal*, 6(2), pp.630-632.
 11. Mannino, M., Toro, A., Teodoro, M., Coccolini, F., Sartelli, M., Ansaloni, L., Catena, F. and Di Carlo, I., 2019. Open conversion for laparoscopically difficult cholecystectomy is still a valid solution with unsolved aspects. *World Journal of Emergency Surgery*, 14(1), p.7.
 12. Kou, Kai, Xingkai Liu, Yuelei Hu, Feixiang Luo, Dawei Sun, Guangyi Wang, Yan Li, Yuguo Chen, and Guoyue Lv. "Hem-o-lok clip found in the common bile duct 3 years after laparoscopic cholecystectomy and surgical exploration." *Journal of International Medical Research* (2019): 0300060518817216.
 13. Kawai, Hironari, Takeyuki Misawa, Kazuto Sasaya, and Yoshishige Aoyama. "Dual-hemostat port closure technique with customized surgical suture after laparoscopic cholecystectomy: Single-center experience." *Asian journal of endoscopic surgery* (2019).
 14. Kawai, Hironari, Takeyuki Misawa, Kazuto Sasaya, and Yoshishige Aoyama. "Dual-hemostat port closure technique with customized surgical suture after laparoscopic cholecystectomy: Single-center experience." *Asian journal of endoscopic surgery* (2019).
 15. Al Tamimi, Adil Shaker. "An Additional Step in the Technique of Laparoscopic Cholecystectomy can Minimize the Incidence of Major Bile Duct Injury." *Journal of Pharmaceutical Sciences and Research* 11, no. 1 (2019): 159-162.