

Potoczniak Bartosz, Dzedzic Artur, Kosior Piotr, Bąk Marcin, Blicharski Tomasz, Massalska-Malecka Teresa, Jarecki Jaromir. Early, posttraumatic, frontal instability of the knee joint deriving from damaged medial collateral ligament, after total knee arthroplasty, complicated with wound dehiscence and Clostridium difficile infection in a 70-year-old patient. Journal of Education, Health and Sport. 2019;9(2):192-198. eISSN 2391-8306. DOI <http://dx.doi.org/10.5281/zenodo.2561234>
<http://ojs.ukw.edu.pl/index.php/johs/article/view/6576>
<https://pbn.nauka.gov.pl/sedno-webapp/works/903575>

The journal has had 7 points in Ministry of Science and Higher Education parametric evaluation. Part B item 1223 (26/01/2017).
1223 Journal of Education, Health and Sport eISSN 2391-8306 7

© The Authors 2019;

This article is published with open access at Licensee Open Journal Systems of Kazimierz Wielki University in Bydgoszcz, Poland
Open Access. This article is distributed under the terms of the Creative Commons Attribution Noncommercial License which permits any noncommercial use, distribution, and reproduction in any medium, provided the original author (s) and source are credited. This is an open access article licensed under the terms of the Creative Commons Attribution Non commercial license Share alike.
(<http://creativecommons.org/licenses/by-nc-sa/4.0/>) which permits unrestricted, non commercial use, distribution and reproduction in any medium, provided the work is properly cited.

The authors declare that there is no conflict of interests regarding the publication of this paper.

Received: 30.01.2019. Revised: 30.01.2019. Accepted: 10.02.2019.

Early, posttraumatic, frontal instability of the knee joint deriving from damaged medial collateral ligament, after total knee arthroplasty, complicated with wound dehiscence and Clostridium difficile infection in a 70-year-old patient

**Bartosz Potoczniak¹, Artur Dzedzic¹, Piotr Kosior¹, Marcin Bąk¹, Tomasz Blicharski²,
Teresa Massalska-Malecka³, Jaromir Jarecki^{1,2}**

¹ Trauma and Orthopedic Ward with Spinal Surgery, Independent Public Province Specialist Hospital, Chełm, Poland

² Orthopedic and Rehabilitation Clinic, Independent Public Clinical Hospital No.4 in Lublin, Lublin, Poland

³ Human Physiology Department, Medical University of Lublin, Lublin, Poland

Correspondence: Bartosz Potoczniak, Trauma and Orthopedic Ward with Spinal Surgery, Independent Public Province Specialist Hospital, ul. Ceramiczna 1, 22-100 Chełm, Poland.
Tel: 0048-600870701

E-mail: b.potoczniak@gmail.com

Abstract

Gonarthrosis is a joint disease in which a balance between regenerative and degenerative processes of articular cartilage is impaired. Its main symptoms are: pain, swelling, rigidity, function restraint as well as articular deformation [1]. It is estimated that about 40% of the knee joint degeneration is a consequence of ageing of the body. 60% of remaining cases of gonarthrosis is a result of excessive strain, contusion and injury. Patients with advanced arthrosis are qualified for total arthroplasty of the knee. Medial collateral ligament (MCL) is

responsible for the medial stability of the knee joint, it prevents from valgus deformity and restrains external rotation of tibia relative to the femur. Injury, most often distorting the knee, may lead to straining as well as complete rupture of the MCL [2,3]. We present a case of a 70-year-old patient with MCL injury that happened three weeks after total knee arthroplasty, complicated by wound dehiscence. Insufficiency of the medial collateral ligament in our patient had an effect in longer healing process and rehabilitation. Main treatment options are: revision surgery with use of constrained implants and injured medial collateral ligament reconstruction. Constrained implants may have reduced longevity in some patients through aseptic loosening. Our patient underwent a MCL reconstruction. Reconstruction of MCL without revision arthroplasty has good results for injured MCL after total arthroplasty of the knee.

Keywords: gonarthrosis, total knee arthroplasty, chronic wound, medial collateral ligament, VAC

1. Introduction

This case presents a 70-year-old patient with early MCL injury after TKA complicated by wound dehiscence and *Clostridium difficile* infection. Degenerative joint disease – osteoarthritis (OA) is a chronic, non-inflammatory and common joint disease characterized with degeneration of synovial joint cartilage, and new bone formation at joint surfaces and margins [4]. Osteoarthritis is the most common joint disease and one of the most common causes of physical deformity. It affects both genders and all races. Although 30 % of individuals above 75 years old have symptoms, non-symptomatic (radiologic) osteoarthritis is presented over 20 % of the patients at 3rd decade and 80 % at 8th decade [5]. Knee is the most commonly affected joint, particularly due to weight bearing. Knee osteoarthritis may significantly impact an individual's quality of life. TKA improves the comfort of patients' lives.

2. Case report

70-year-old patient was admitted to the Trauma and Orthopedic Ward with Spinal Surgery in Chełm for scheduled total arthroplasty of left knee (TKA). Reason for the qualification for the procedure was progressive arthrosis of the joint, that 5 years since diagnosis, despite rehabilitation treatment and use of corticosteroids, lead to 12 degrees varus deformity, loose of unhampered mobility and strong pain. Anterior-posterior and lateral radiograph of the left knee revealed grade 4 severity of osteoarthritis in Kellgren and Lawrence system for classification of osteoarthritis of knee [6] (Figures 1,2). Radiographs showed massive osteophytes at the margin of the joint, shaping at and stretching the MCL. At the time of admittance to the Ward, patient complained of strong pain to left knee, estimated at 8 in 10-point VAS scale. Physical examination showed full knee extension, 90 degrees active and passive flexion.

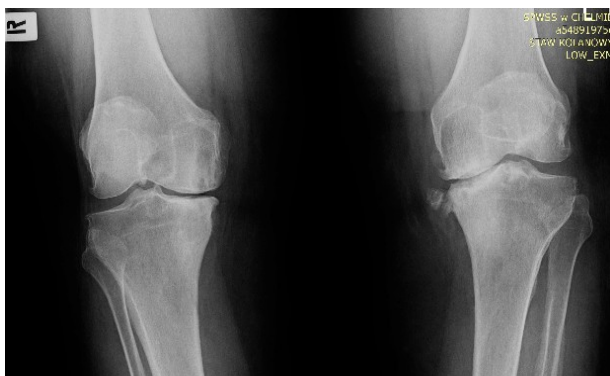

Fig. 1. Anterior- posterior radiograph of both knees (day 0)

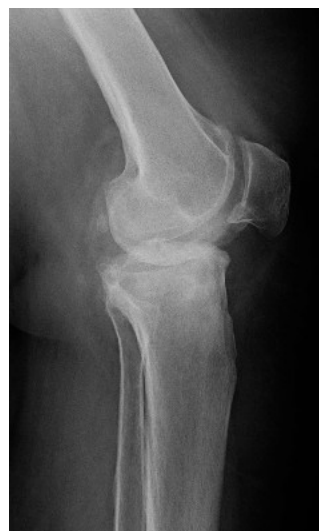

Fig. 2. Lateral radiograph of left knee (day 0)

Table 1. Orthopaedic scores

Score	Result day 0	Result day 270
WOMAC	44,2	81,3
2000 IKDC	14,9	57,5
KSS	47	77
KSS Functional	70	65
Oxford	11	39
VAS	8	2

Crepitus in patellofemoral joint was felt at movement, as well as tenderness of the medial joint space at palpation. Patient reported a history of hypertension, her BMI index was calculated at $40,9\text{kg/m}^2$. Orthopaedic scores were used for pre- operative evaluation [7] (Table 1. Chart 3.) Surgery was performed the day after admittance (day 1). Using Payr's anterior approach [8], Zimmer Biomet NexGen endoprosthesis was implanted. Pie crusting technique was used to release soft tissue contracture of medial compartment and MCL ossification [9]. Patient was verticalized on the first day after the surgery and in the early phase of rehabilitation, a CPM device was used. On the third day after arthroplasty, due to low red blood cell count, patient required red blood cell transfusion. On the 6th day patient was referred to the Rehabilitation Ward in Lublin, where she performed active-passive exercises of the left knee, isometric MQF exercises and underwent laser therapy. On the 12th day after surgical procedure patient contracted diarrhea. C. difficile infection was diagnosed and antibiotic treatment with 500mg of metronidazole was administered every 8 hours for a week, with good result- symptoms have resolved. On the 24th day after arthroplasty patient suffered a fall on the same level and sustained a torsion injury to the operated knee and a wound

dehiscence in its lower apex (8x3cm), as well as a tear in peripheral insertion of MCL [10] (Fig. 3). Range of motion was reduced up to 40 degrees, with full extension. Patient was once again admitted to the Trauma and Orthopedic Ward with Spinal Surgery in Chelm to undergo another surgical procedure.

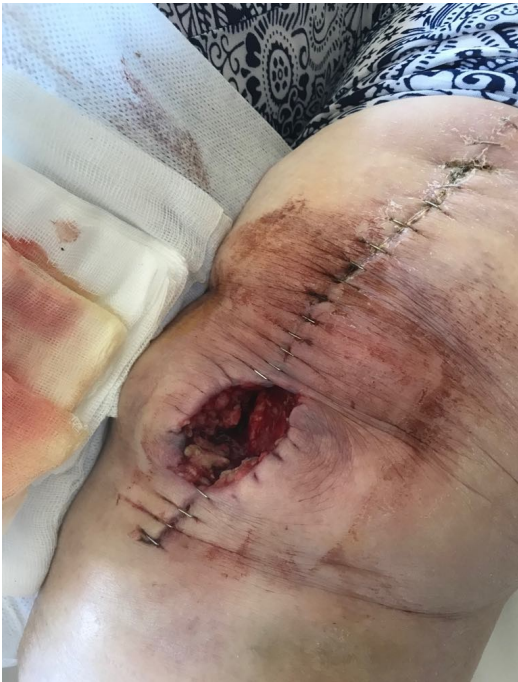

Fig. 3. Surgical wound dehiscence (day 24)

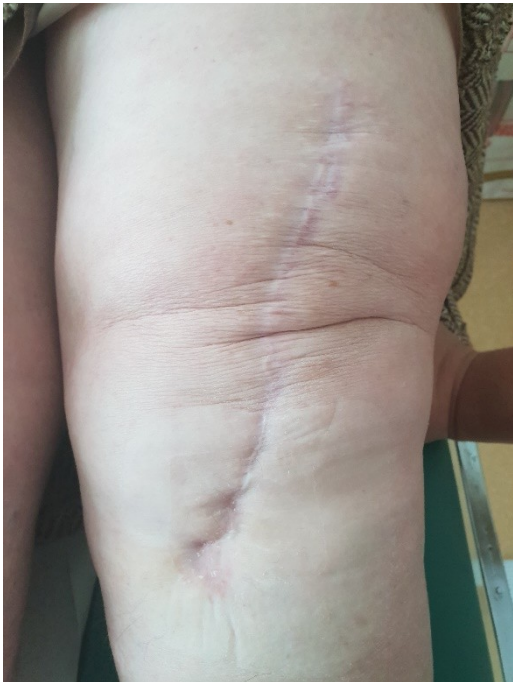

Fig. 4. Healed surgical wound (day 270)

The injury of the peripheral insertion of left MCL was confirmed with ultrasound scan, a radiograph of the left knee was also taken (Fig. 5). Wound swab was taken on admittance, and empirical antibiotic therapy with 1g of Cefazolin every 12 hours was administered and continued until the result of the culture came out negative. After debridement of necrotic tissue, on the 25th day after original arthroplasty, a Vacuum Assisted Closure (VAC) system was applied. On the 28th day we performed a reattachment of peripheral insertion of MCL using two Ti-Screw Biomet anchors for stabilization (Fig. 6).

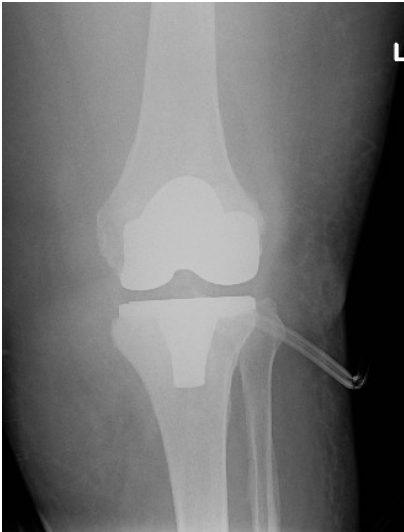
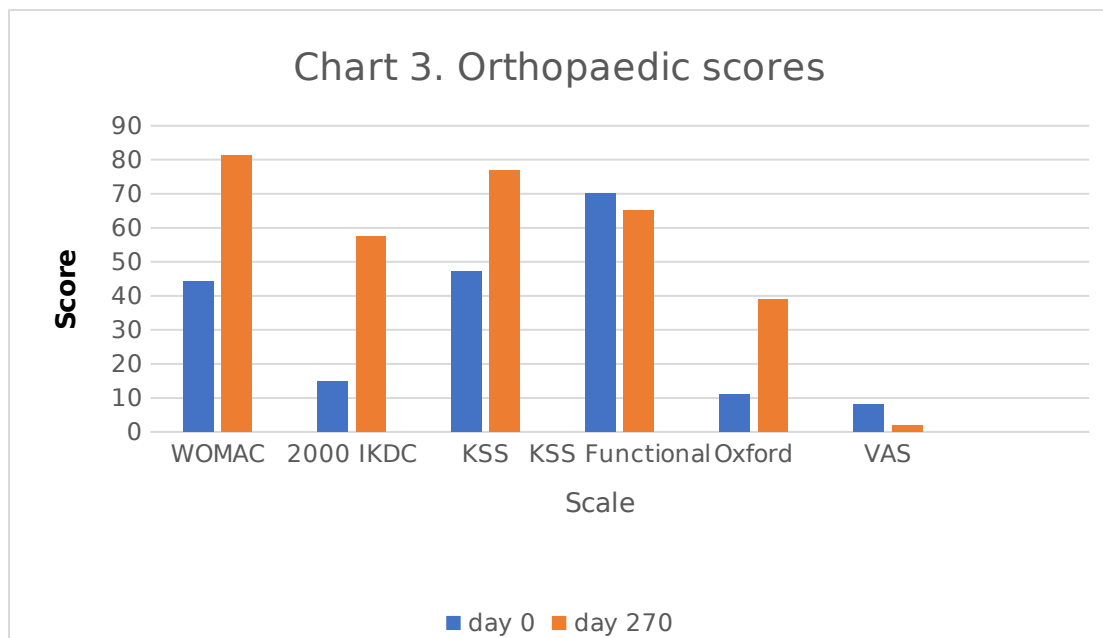
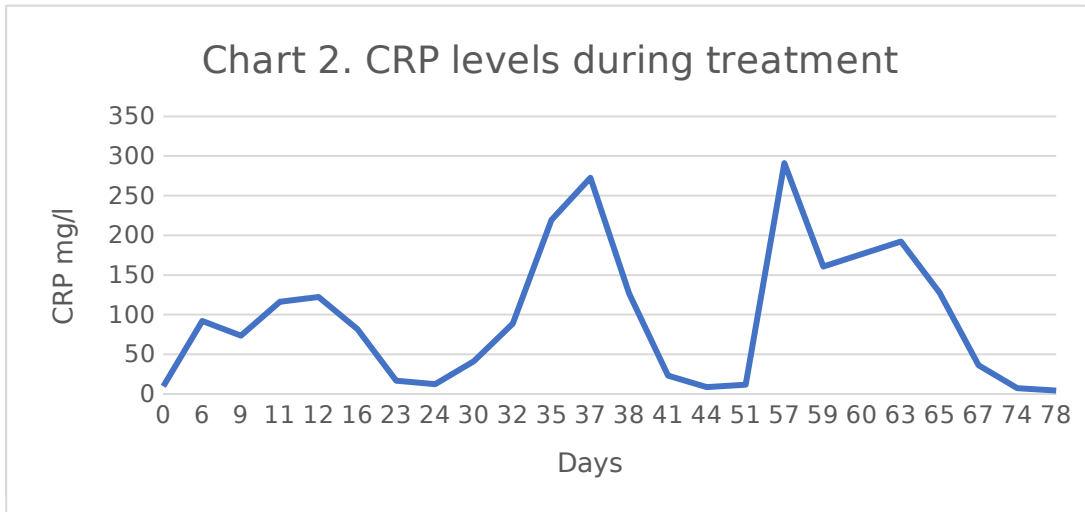


Fig. 5. Radiograph of the left knee- day 25

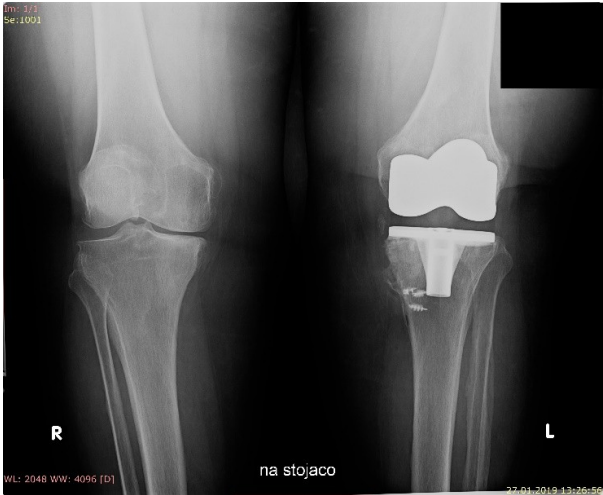

Fig. 6. Radiograph of the left knee- day 28

Patient was verticalized with forearm crutches, with use of knee brace with regulated range of motion. CPM device was used in the early stage of rehabilitation- two times a day for 30 minutes. On the 31st day after TKA patient once again contracted diarrhea caused by *C. difficile*. 250mg of vancomycin was used every 6 hours for 10 days. During hospital stay of the patient, high levels of CRP, without increased levels of WBC were noted. Highest level of CRP was noted on the 57th day after TKA- 291,2 mg/l (Chart 1,2).



On the 49th day after TKA another wound dehiscence in the lower apex of the incision was noted. Once again, VAC dressing was applied and continued for 23 days. Partial healing of the wound was obtained. From then on the healing process was continued with use of specialist dressings (Aquacel Ag, Sorbalgon). On the 80th day after TKA, patient was discharged from the hospital and referred to the outpatient's orthopedic clinic. Six months after arthroplasty of the knee, upon control visit to the clinic, patient was not complaining of strong pain- VAS score 3. Range of motion has improved up to 90 degrees flexion with persistent full extension. She was walking with use of one forearm clutch. Nine months after arthroplasty, patient did not complain of pain- VAS score 2. Range of motion of the operated knee was 0-110 degrees.

A stable knee joint was obtained both, in the sagittal and frontal plane. Complete healing of the wound was also obtained (Fig.4). Efficient walking without crutches was achieved. After nine months of treatment, therapy was finished with good result. (Chart 3.)

3. Discussion

Main goal of arthroplasty is to relieve patient from pain and restore motion of the joint [11]. Medial collateral ligament injury is one of the most severe complications associated with postoperative function after total knee arthroplasty [12,13,14]. Multiple studies have demonstrated that the MCL is the primary medial stabilizer of the knee resisting valgus loading, the secondary stabilizer against excessive external tibial rotation, and is also essential for providing stability during valgus stress and external rotation stress after TKA [15, 16, 17, 18]. A less constrained (PS/CR) implant may be acceptable if a good quality direct repair with or without augmentation is possible. When an unlinked semi constrained TKA endoprosthesis is not available, direct repair with or without augmentation is an acceptable alternative. In cases where the MCL repair is prone to stretching, tissue quality is poor, or in the elderly, conversion to a semi constrained unlinked implant is preferable. [19] Reconstruction of MCL without revision arthroplasty has good results for injured MCL after total arthroplasty of the knee. Ligament stability after total knee arthroplasty is critical for proper rehabilitation of the patient.

Acknowledgments

Declared none

References

1. Skopowska A., Biernacki M., Dekowska M., Ozóg P., Grochowska A., *The influence of vibroacoustic therapy on the functional status of patients with gonarthrosis. A preliminary report.* Reumatologia 2014; 52, 5: 292–298
2. Dziak A. *Musculoskeletal traumatology.* Vol. II, PZWL. – 1996. p. 94
3. Bondara E., Kozłowska H., Nowicka D., Staszkiwicz W., Frankowski S., Hagner W. *Function tests in assessing the efficiency of cruciate ligaments. – Therapeutic problems. – 1995. – nr 34 (7).- pp. 45-53.*
4. McAlindon TE, Cooper C, Kirwan JR, Dieppe PA. *Determinants of disability in osteoarthritis of the knee.* Ann Rheum Dis. 1993;52(4):258–62.
5. Kellgren JH, Lawrence JS. *Radiological assessment of rheumatoid arthritis.* Ann Rheum Dis. 1957;16(4):485–93.
6. Mark D. Kohn, BA, Adam A. Sassoon, MD, and Navin D. Fernando, MD . *Classifications in Brief: Kellgren-Lawrence Classification of Osteoarthritis,* Clinical Orthopaedics and Related Research® August 2016, Volume 474, Issue 8, pp 1886–1893
7. Riddle, Daniel L.; Stratford, Paul W. , *Body weight changes and corresponding changes in pain and function in persons with symptomatic knee osteoarthritis. A cohort study.* Arthritis Care & Research. 65, pp. 15–22
8. Young Bok Jung, Yong Seuk Lee, Eun Yong Lee, Ho Joong Jung, Chang Hyun Nam *Comparison of the modified subvastus and medial parapatellar approaches in total knee arthroplasty.* International Orthopaedics (SICOT) (2009) 33:419–423
9. Neyret P., Verdonk P. Ait Si Selmi T. *Chirurgie du genou,* Elsevier 2010, p. 144
10. Teza J., Frankowski S., Hagner W., Budny M. *Chronic instability of knee-pathogenesis, differential diagnosis, principles of treatment. Therapeutic problems. – 1995 (4). – pp. 45-51*
11. Marciniak W., Szulc A., *Wiktora Degi Ortopedia i Rehabilitacja,* Vol. 2, PZWL - 2008. p. 298).

12. Leopold SS, McStay C, Klafeta K, et al. *Primary repair of intraoperative disruption of the medial collateral ligament during total knee arthroplasty.* J Bone Joint Surg Am 2001;83:86–91.
13. Lee GC, Lotke PA. *Management of intraoperative medial collateral ligament injury during TKA.* Clin Orthop Relat Res 2011;469:64–8.
14. Siqueira MB, Haller K, Mulder A, et al. *Outcomes of medial collateral ligament injuries during total knee arthroplasty.* J Knee Surg 2016; 29:68–73.
15. Grood ES, Noyes FR, Butler DL, et al. *Ligamentous and capsular restraints preventing straight medial and lateral laxity in intact human cadaver knees.* J Bone Joint Surg Am 1981;63-A:1257–69.
16. Warren RF, Marshall JL. *Injuries of the anterior cruciate and medial collateral ligaments of the knee. A long-term follow-up of 86 cases part II.* Clin Orthop 1978;136:198–211.
17. Whiteside LA, Saeki K, Mihalko WM. *Functional medial ligament balancing in total knee arthroplasty.* Clin Orthop Relat Res 2000;380:45–57.
18. Saeki K, Mihalko WM, Patel V, et al. *Stability after medial collateral ligament release in total knee arthroplasty.* Clin Orthop Relat Res 2001;392:184–9.
19. P.K. Della Torre, A. Stephens, Horng Lii Oh, A. Kamra, B. Zicat, P. Walker, *Management of Medial Collateral Ligament Injury During Primary Total Knee Arthroplasty: A Systematic Review*, Joint Implant Surgery & Research Foundation Reconstructive Review Volume 4, Number 2, June 2014.