

Dziedzic Artur, Potoczniak Bartosz, Bąk Marcin, Blicharski Tomasz, Dziedzic Urszula, Massalska-Malecka Teresa, Jarecki Jaromir. Pilon fracture of the tibia with severe complications in a 42-year-old patient – case report. *Journal of Education, Health and Sport*. 2019;9(2):183-191. eISSN 2391-8306. DOI <http://dx.doi.org/10.5281/zenodo.2561214>  
<http://ojs.ukw.edu.pl/index.php/johs/article/view/6575>  
<https://pbn.nauka.gov.pl/sedno-webapp/works/903570>

The journal has had 7 points in Ministry of Science and Higher Education parametric evaluation. Part B item 1223 (26/01/2017).  
1223 Journal of Education, Health and Sport eISSN 2391-8306 7

© The Authors 2019;

This article is published with open access at Licensee Open Journal Systems of Kazimierz Wielki University in Bydgoszcz, Poland

Open Access. This article is distributed under the terms of the Creative Commons Attribution Noncommercial License which permits any noncommercial use, distribution, and reproduction in any medium, provided the original author (s) and source are credited. This is an open access article licensed under the terms of the Creative Commons Attribution Non commercial license Share alike. (<http://creativecommons.org/licenses/by-nc-sa/4.0/>) which permits unrestricted, non commercial use, distribution and reproduction in any medium, provided the work is properly cited.

The authors declare that there is no conflict of interests regarding the publication of this paper.

Received: 25.01.2019. Revised: 30.01.2019. Accepted: 10.02.2019.

## **Pilon fracture of the tibia with severe complications in a 42-year-old patient – case report**

**Artur Dziedzic<sup>1</sup>, Bartosz Potoczniak<sup>1</sup>, Marcin Bąk<sup>1</sup>, Tomasz Blicharski<sup>2</sup>,  
Urszula Dziedzic<sup>3</sup>, Teresa Massalska-Malecka<sup>4</sup>, Jaromir Jarecki<sup>1,2</sup>**

<sup>1</sup> Trauma and Orthopedic Ward with Spinal Surgery, Independent Public Province Specialist Hospital, Chełm, Poland

<sup>2</sup> Orthopedic and Rehabilitation Clinic, Independent Public Clinical Hospital No.4 in Lublin, Lublin, Poland

<sup>3</sup> The Pediatric Ward with the Pediatric Cardiology Unit, Specialist Hospital of the Holy Spirit, Sandomierz, Poland

<sup>4</sup> Human Physiology Department, Medical University of Lublin, Lublin, Poland

Correspondence: Artur Dziedzic, Trauma and Orthopedic Ward with Spinal Surgery, Independent Public Province Specialist Hospital, ul. Ceramiczna 1, 22-100 Chełm, Poland.  
Tel: 0048-791750758

E-mail: [arturdanieldziedzic@gmail.com](mailto:arturdanieldziedzic@gmail.com)

### **Abstract**

Pilon type fractures of the distal tibia are among the most difficult injuries of the lower extremity. They occur due to the axial loading injury which drives the talus into the tibial plafond, mainly because of high energy traumas such as car accidents and falls, but may arise from low energy traumas also. Due to specific conditions in the area of the injury: where skin and subcutaneous tissue is delicate, soft tissues are usually severely damaged, it is crucial to choose the correct timing for surgical intervention. There are several surgical options regarding treatment of the pilon fractures, however treatment plan of pilon fractures has not yet been unified. Surgical methods include open reduction with internal fixation and external

fixation. Main purpose of the treatment of pilon fractures are the preservation of length and restoration of the joint surfaces. Great risks for the successful treatment are skin and soft tissue infections, that occur quite commonly due to specific anatomy of the fractured area. Wound infection may have potentially catastrophic consequences.

Here we present a case of our 42-year-old patient, with a pilon fracture of the tibia who suffered multiple complications due to obtained trauma as well as his concurrent diseases: diabetes, alcohol and nicotine abuse, also as a result of his lack of compliance with medical advice. Despite the complications that occurred, outcome of the overall treatment was satisfactory both to the patient as well as orthopedic team. This example shows that treatment method should be chosen wisely not only on the type of the fracture, but also with patient's ability to comply with doctors' recommendation.

**Keywords:** pilon fracture, tibia, complications, Kirschner wires, internal fixation, external fixation

## 1. Introduction

Pilon type fractures of the distal tibia are among the most difficult injuries of the lower extremity. They account for up to about 5-7% of all fractures of the lower leg. The "pilon" (meaning hammer) term was first used in 1911 by Decoulx in description of intra-articular fractures of the distal tibia [1]

Pilon fractures occur due to the axial loading injury which drives the talus into the tibial plafond. Most intra-articular fractures of weight-bearing surface of the distal tibial plafond occur due to high energy impact such as: car accidents, falls from height, motorcycle accidents or, on the other hand low energy impact such as fall from own height. Placement of the foot, among with the direction of the force during the impact defines the type of the fracture [2]. There are two main X-ray classification schemes to describe pilon fracture types: Ruedi and Allgower [3] and the AO Foundation and Orthopaedic Trauma Association (AO/OTA) [4].

Due to specific conditions in the area of the injury: where skin and subcutaneous tissue is delicate, soft tissues are usually severely damaged, it is crucial to choose the correct timing for surgical intervention [5]. The main purpose of the treatment of pilon fractures are the preservation of length and restoration of the joint surfaces.

One of the great challenges for the outcome of the surgical intervention in pilon fractures is a correct assessment of risk factors for surgical site infections. Systemic risks such as diabetes, alcoholism, smoking and vascular diseases should also be taken into consideration. Results of the operative interventions in open pilon type fractures are bad and in general concern septic complications of the soft tissue and skin [6].

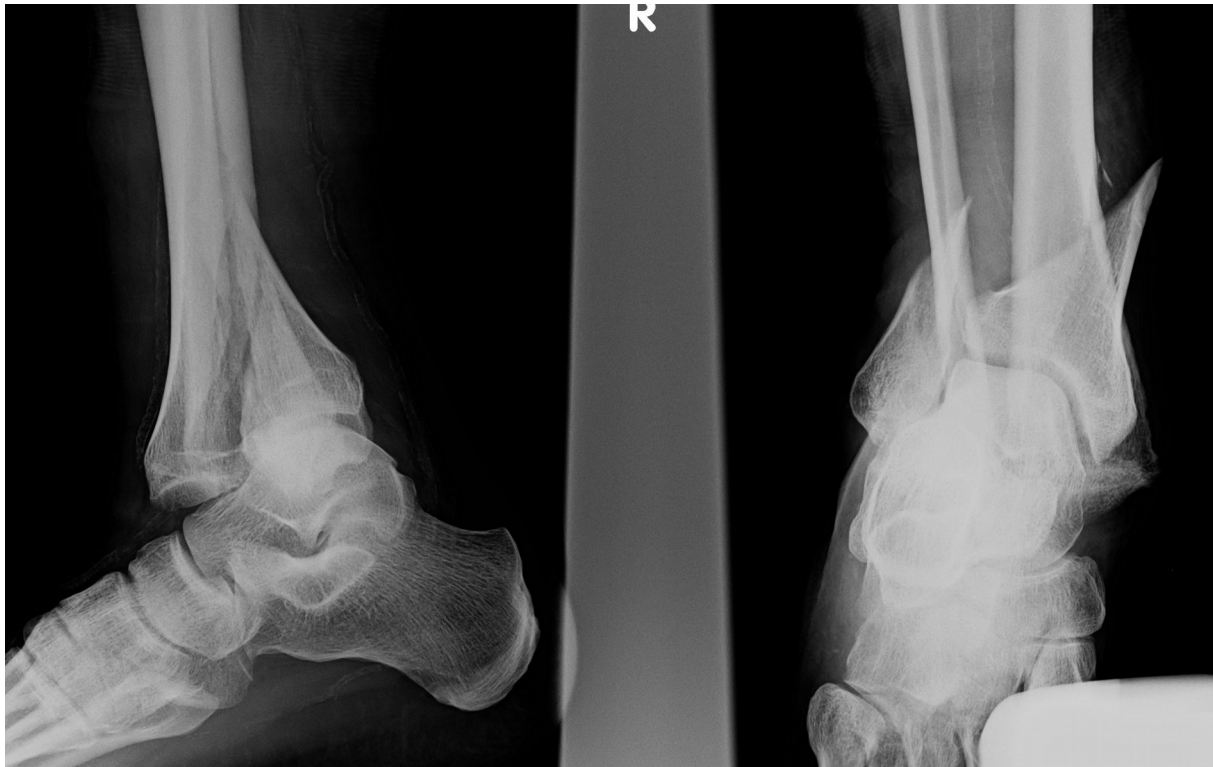Complications after treatment of tibial pilon fractures can occur intraoperatively or in the early or late postoperative period. Perioperative complications include malreduction, inadequate fixation, and intra-articular penetration of hardware, all of which may be minimized by preoperative planning and meticulous operative technique. Wound complications can lead to deep infection, with potentially catastrophic consequences [7].

## 2. Case report

A 42-year-old patient was brought to the Accident and Emergency Ward, after a fall on the same level in which he sustained an injury to the right lower leg with planar dysaesthesia in the right foot. Patient with a history of type 2 diabetes, alcohol and nicotine abuse, admitted to

drinking right before the accident. Anteroposterior radiograph on admission revealed intra-articular fracture of the distal tibia and fibula- type 43B1.1 in AO classification, with the lateral malleolar fracture. Patient was admitted to the Trauma and Orthopedic Ward with Spinal Surgery in Chelm.

Fig.1. Radiograph of the right leg on admission.



An attempt at reduction of the fracture was made, which improved the position of the ankle and allowed the neurological deficits to subside. The dislocation of the talocrural joint was however still present.

Fig.2. Radiograph of the attempted closed reduction, stabilized in a split plaster cast.

Because of this fact patient underwent a surgical procedure of ankle transfixation with Kirschner wires and a split plaster cast was applied. Bed rest and elevation of the right leg was recommended to the patient.

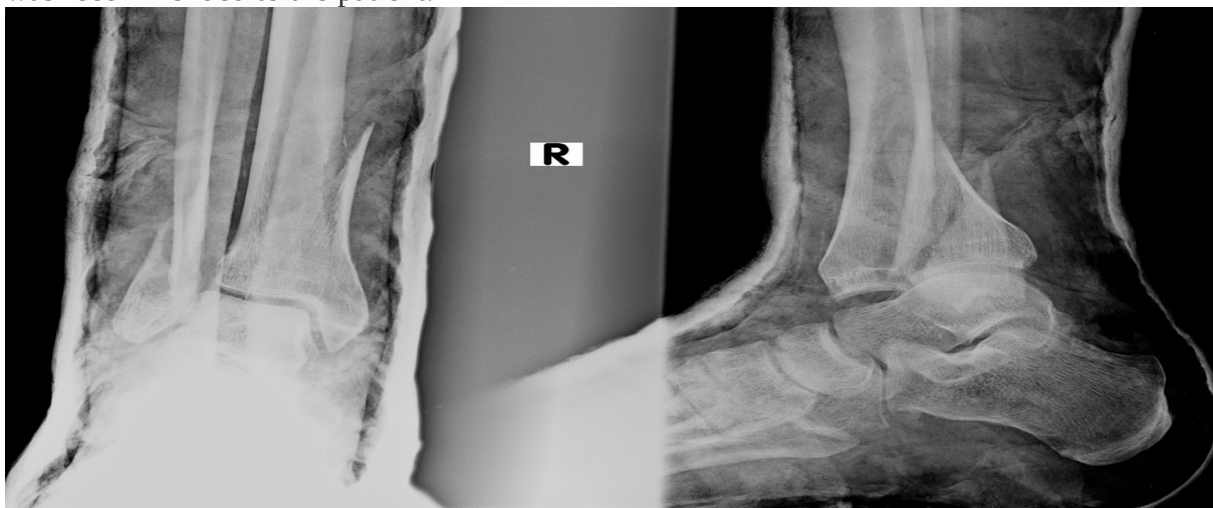
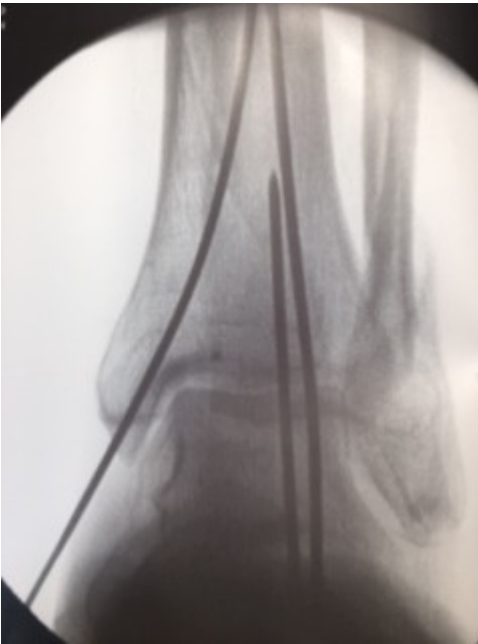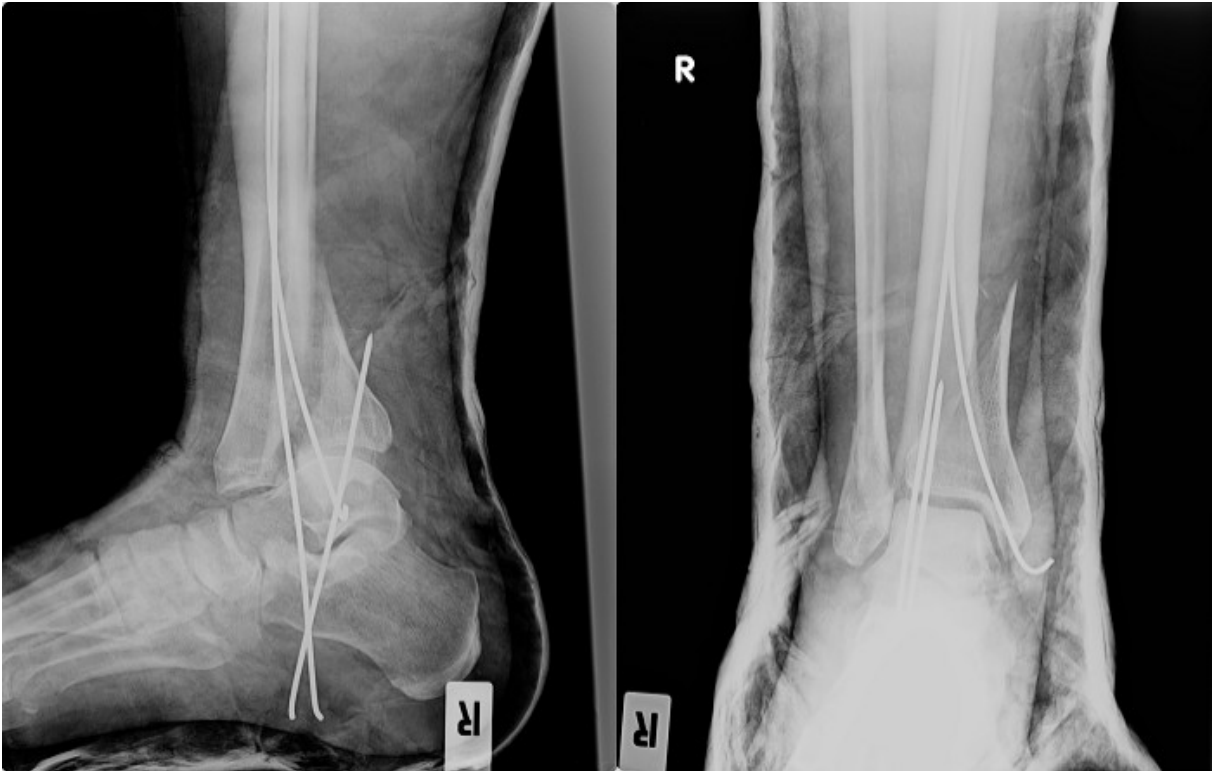


Fig.3. Intrasurgical radiograph of the Kirschner wire fixation



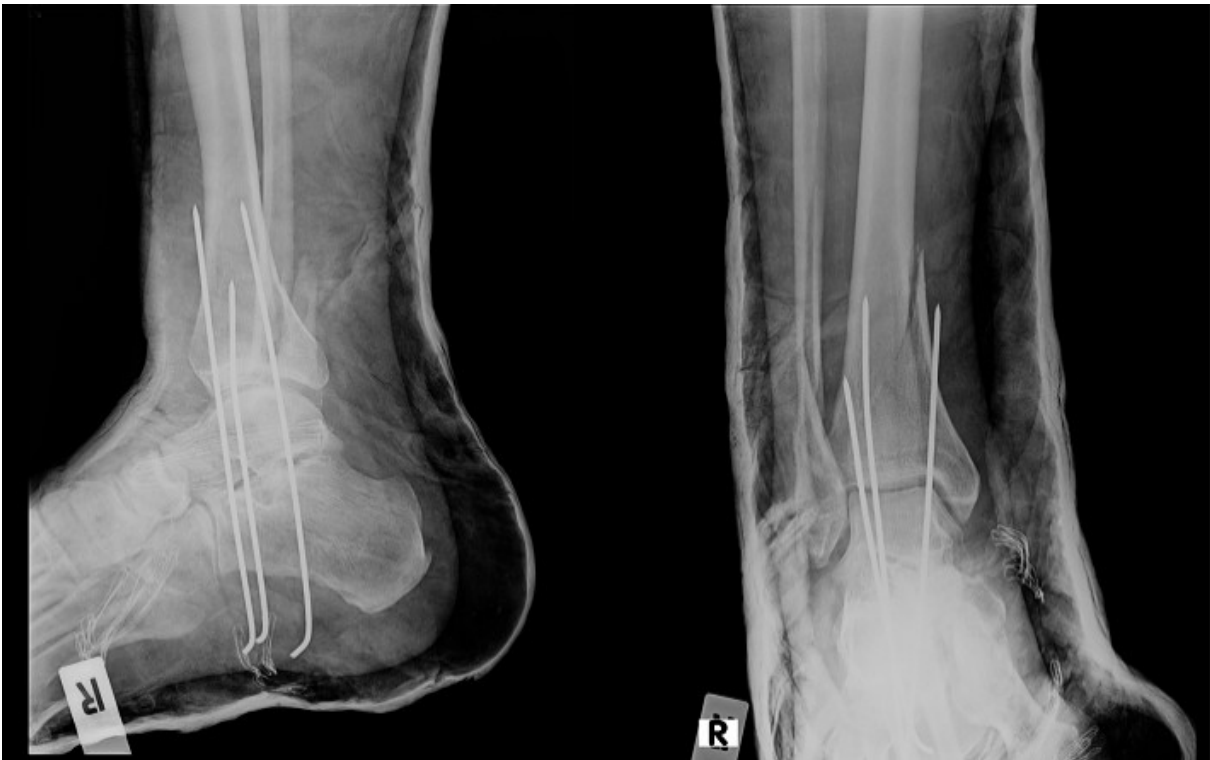Patient did not comply with the doctors' advice, leaving his bed to continue smoking, what resulted in exacerbation of the pain two days after initial admission to the ward. Radiograph of the right lower leg revealed displacement of the transfixion and dislocation in the talocrural joint.

Fig.4. Radiograph of the right ankle after another luxation in the talocrural joint.



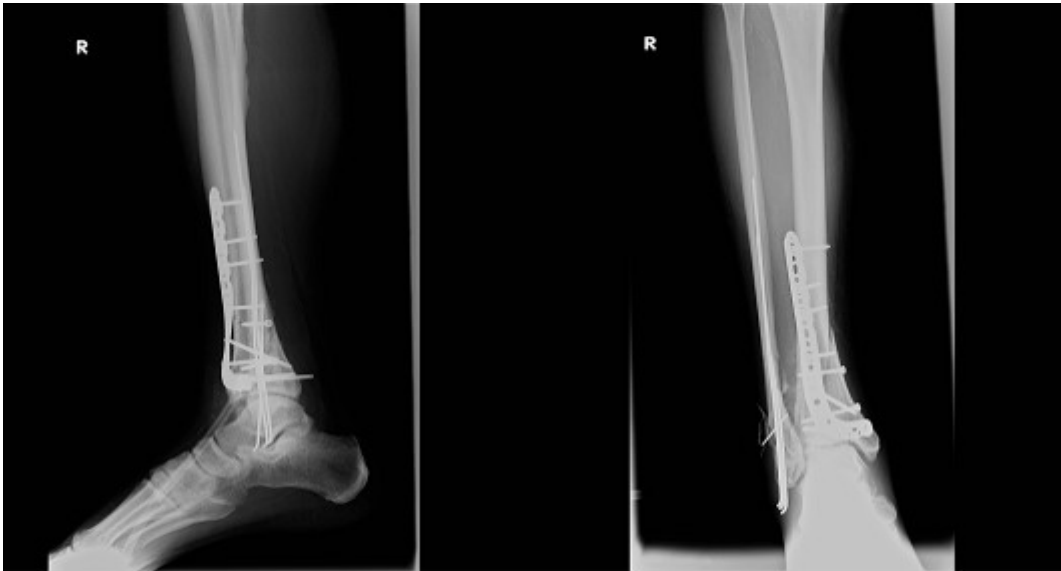Patient underwent second surgery to remove previously inserted Kirschner stabilization wires. Temporary transfixion of the right ankle, also with Kirschner wires, was performed.

Fig.5. Radiograph of the second fixation with Kirschner pins.



On the 17<sup>th</sup> day of hospitalization, once the soft tissues have recovered from injury, edema and blisters have subsided, patient underwent open reduction with internal fixation surgery. LCP plates were used to fixate the tibia, with intramedullary fixation of fibula. Wound swab revealed the growth of MSSA, therefore antibiotics: ciprofloxacin (400mg twice a day) and gentamicin (80mg twice a day) were administered intravenously.

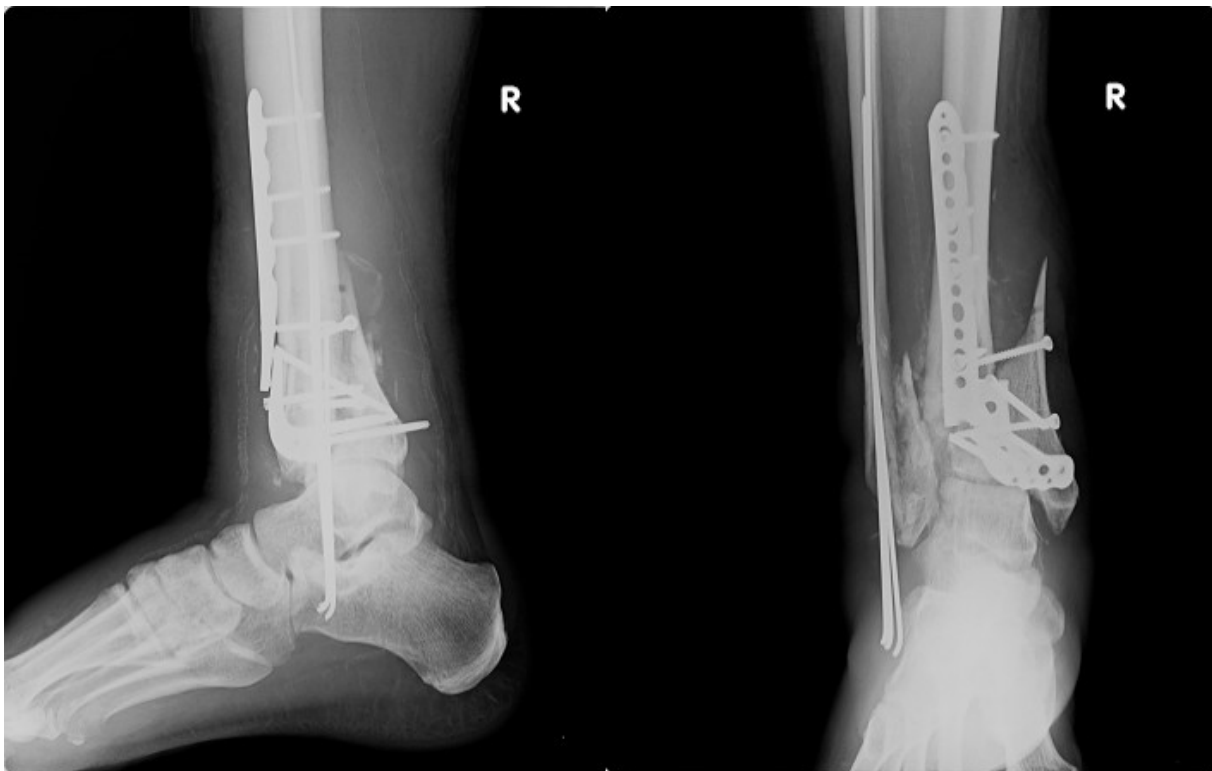Fig.6. Open reduction and internal fixation with LCP plates.



Because of the necrosis of the skin surrounding the operating field- on the 38<sup>th</sup> day of hospitalization a vacuum dressing system was applied. This method resulted in good healing of the wound, allowing us to discharge the patient in the 66<sup>th</sup> day of hospitalization. Laboratory tests upon discharge, revealed normal level of CRP- 6 mg/l (reference range 0-6), WBC 6,44 10<sup>3</sup>/uL (reference range 3,8-8,76). Patient. was not to put weight on the right lower limb, and was referred to outpatient orthopedic clinic.

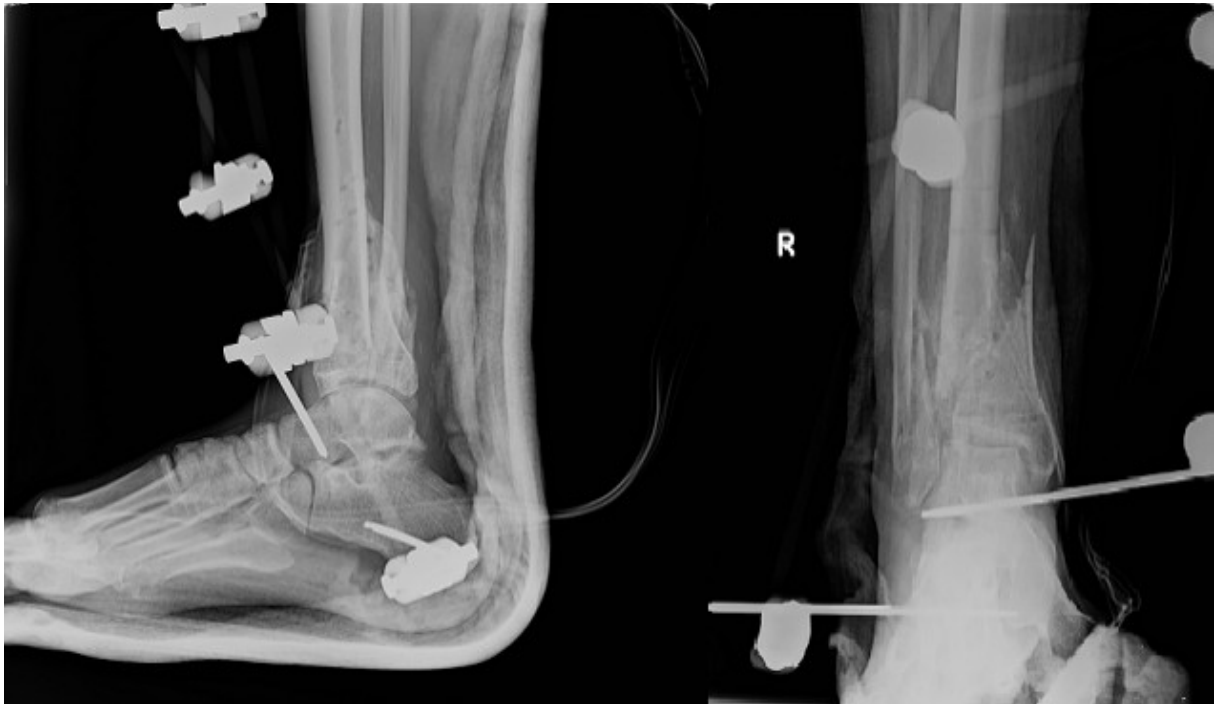During the first visit to the outpatient clinic, ten days after the discharge, patient complained of pain exacerbation in the operated area. He admitted to putting weight on the right leg and to a twisting injury to the right ankle. Patient was admitted to the Trauma and Orthopedic Ward with Spinal Surgery in Chełm again. Blood tests showed elevated levels of infection markers: CRP 295,1 mg/l (6,6-8,7 mg/l), WBC 16,57 10<sup>3</sup>/uL (3,8-8,76). Septic destabilization of the fracture and breaking of the LCP plate was noted.

Fig.7. Septic destabilization of the fixation with breaking of the LCP plates



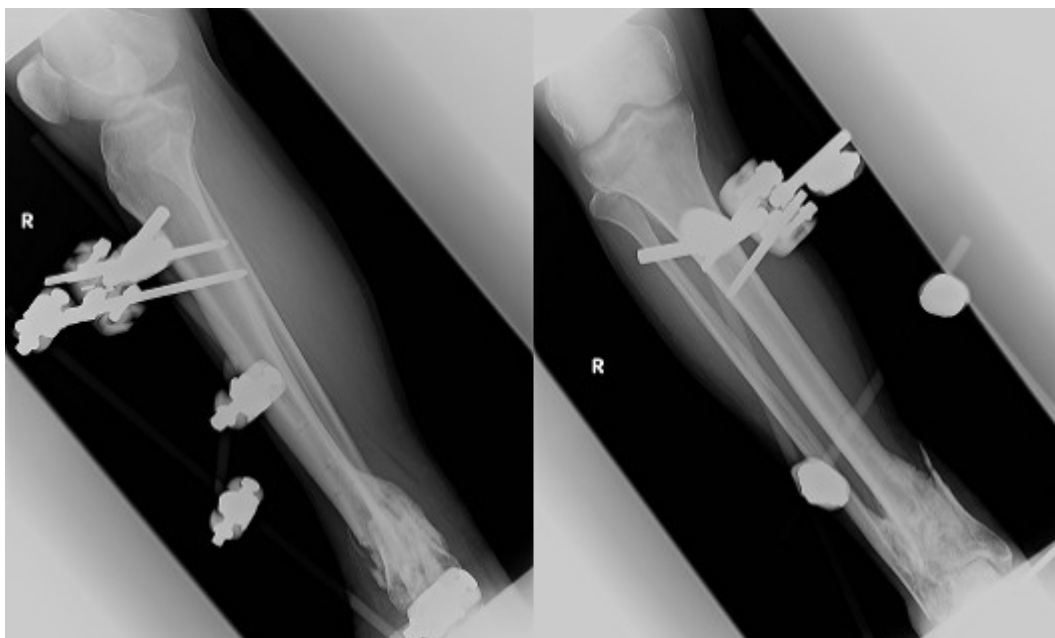
On the 4<sup>th</sup> day of hospitalization internal fixation was surgically removed and the Hoffman external fixation system was applied. Wound swab was taken.

Fig.8. External fixation with use of the Hoffman system



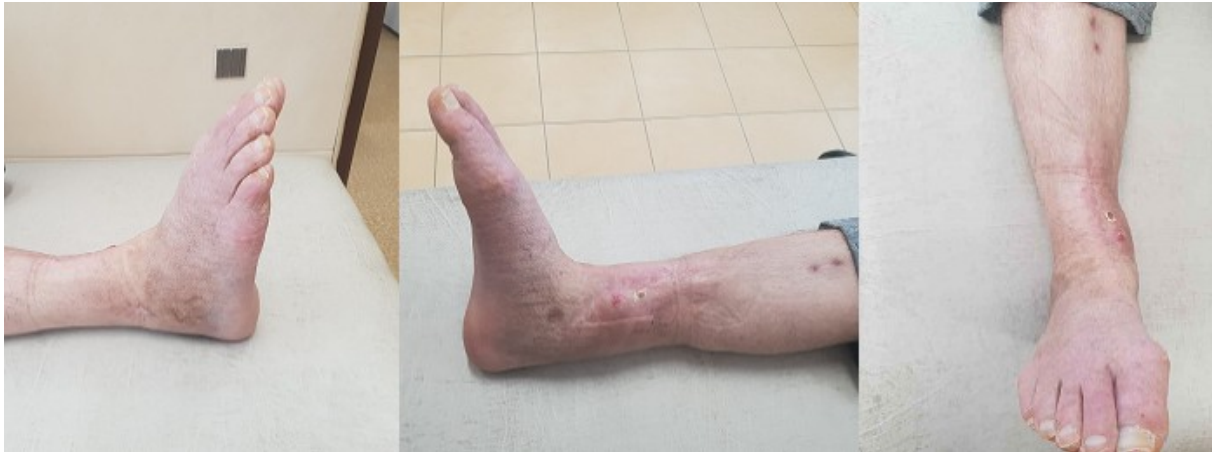In search of other sources of infection, a dentist consultation was performed, in which the dentist extracted 6 rotten teeth. Wound swab revealed another MSSA infection, therefore targeted treatment with antibiotics: gentamicin (80mg every twelve hours) and clindamycin (600mg twice a day) was administered. 16 days after application of the Hoffman external fixation system, we surgically debrided the wound and inserted the local intra-wound gentamicin. A vacuum dressing system was applied on the 27<sup>th</sup> day of hospitalization, allowing us to obtain good healing of the wound and lowering the inflammation markers in the blood. On the 33<sup>rd</sup> day infection markers levels were: CRP 4,3 mg/l (6,6-8,7 mg/l), WBC 6,02 10<sup>3</sup>/uL (3,8-8,76). On the 51<sup>st</sup> day of hospital stay, patient discharged himself from the hospital.

Fig.9. Radiograph of the ankle with the external fixation system, during the visit in the outpatient clinic.



After 4 months of supervision in the outpatient clinic patient was qualified for the external fixation removal. Nine months after the initial injury, an external fixation was removed. Upon follow up visit in the outpatient clinic our patient had no complaints, wound have healed correctly, range of motion in the right ankle was approximately 35 degrees.

Fig.10. Photograph of the right ankle after healing of the pilon fracture.



Patient was referred to the rehabilitation clinic

### 3. Discussion

Fractures of the tibial pilon are challenging injuries in traumatology. Few options are described for the surgical management of these fractures but the methods of their therapy have not been unified yet and treatment outcomes are not satisfactory. This is often due to extensive comminution of the distal tibia, bone defects or a thin coverage of soft tissue [8].

Treatment method should be carefully chosen not only depending on the type of fracture, but also on the level of the soft tissue compromise and general condition of the patient, as no single method of fixation is ideal for all pilon fractures, or suitable for all patients.

It is very important to adequately evaluate concurrent conditions affecting the soft tissue healing, possibility of the surgical wound infection and cooperation with the patient. Chronic diseases such as diabetes, nicotine and alcohol addiction significantly increase the risk of dangerous complication.

Patient suffered from most common pilon fracture complication- soft tissue infection, that occurs in 25,7% of pilon fracture cases [9] as well as multiple destabilization of the internal fixation. The fact that our patient did not comply with doctors' advice was had significant impact on the healing process. However, treatment administered- multiple surgeries including internal and external fixation, administration of antibiotics, dental treatment, vacuum dressing application, allowed for the inflammation and infection of the wound to subside and correct skin and soft tissue healing.

### Acknowledgments

Declared none.

### References

[1] Destot E. Traumatismes du pied et rayons X malleoles, astragale, calcaneum avantpied Paris7 Mason 1911; 1-10.



- [2] Nork SE. Distal tibia fractures. In: Stannard JP, Schmidt AH, Kregor PJ, eds. *Surgical Treatment of Orthopaedic Trauma*. New York, NY: Thieme; 2010:949.
- [3] Rüedi TP, Allgöwer M. The operative treatment of intra-articular fractures of the lower end of the tibia. *Clin Orthop Relat Res*. 1979;138:105–110
- [4] Marsh J, Slongo TF, Agel J, Broderick JS, Creevey W, DeCoster TA, Prokuski L, Sirkin MS, Ziran B, Henley B. Fracture and dislocation classification compendium-2007: Orthopaedic Trauma Association classification, database and outcomes committee. *J Orthop Trauma*. 2007;21(10):S1–S6. doi: 10.1097/00005131-200711101-00001
- [5] Herrera-Pérez M, Andarcia-Bañuelos C, Ayala-Rodrigo A, País-Brito JL. Our experience with orthopedic damage control in high-energy tibial pylon fractures. *Acta Ortop Mex*. 2013 Mar-Apr;27(2):71-7.
- [6] Orłowski J, Marczak D, Rylski W. Złamania typu „pilon fracture”. *Postępy Nauk Medycznych*. 2007;6:230-238.
- [7] Thordarson DB. Complications after treatment of tibial pilon fractures: prevention and management strategies. *J Am Acad Orthop Surg*. 2000 Jul-Aug;8(4):253-65.
- [8] Závitkovský P, Malkus T. Fractures of the tibial pylon: treatment options and outcomes. *Acta Chir Orthop Traumatol Cech*. 2004;71(4):228-36.
- [9] Kilian O, Bündner MS, Horas U, Heiss C, Schnettler R. Long-term results in the surgical treatment of pilon tibial fractures. A retrospective study. *Chirurg*. 2002 Jan;73(1):65-72.