



Journal Homepage: -[www.journalijar.com](http://www.journalijar.com)  
**INTERNATIONAL JOURNAL OF  
 ADVANCED RESEARCH (IJAR)**

Article DOI:10.21474/IJAR01/8288  
 DOI URL: <http://dx.doi.org/10.21474/IJAR01/8288>



### RESEARCH ARTICLE

#### USES OF ULTRASONICS IN ENDODONTICS, A REVIEW.

Afeef Ansar<sup>1</sup> And k. Harish s. Shetty<sup>2</sup>.

1. Post graduate student, Department of Conservative Dentistry and Endodontics, Yenepoya Dental College, Yenepoya University, Deralakatte, Mangalore, Karnataka-575018.
2. Senior Professor & Head of the Department, Department of Conservative Dentistry and Endodontics, Yenepoya Dental College, Yenepoya University, Deralakatte, Mangalore, Karnataka -575018.

#### Manuscript Info

##### Manuscript History

Received: 20 October 2018  
 Final Accepted: 22 November 2018  
 Published: December 2018

##### Key words:-

Ultrasonics , Endodontics.

#### Abstract

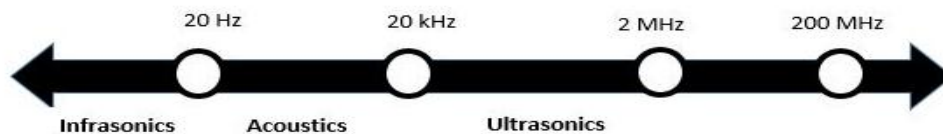
In the last few years endodontic treatment has advanced with the introduction of new techniques and equipment's. These have significantly improved the results and predictability of endodontic treatments. Magnification and ultrasonics use in endodontics have prominently increased leading to advanced endodontics. Ultrasonics in endodontics has enhanced the quality of treatment and has become an important adjunct in the treatment of difficult cases. This review aims at enlisting the uses of ultrasonics in endodontics stressing its broader application possibilities in modern day endodontic practice.

Copy Right, IJAR, 2017,. All rights reserved.

#### Introduction:-

During the past few decades endodontic treatment has aided from the introduction of new techniques and equipment, among which the use of ultrasonic sources has now gained such importance in the economy of endodontic treatment that leads us to consider it as one of most interesting innovations introduced into modern endodontics.

Ultrasonics is defined as waves with frequencies of at least 25 kHz, and are one of the most used non-invasive technology facilities in modern dentistry.



In recent years, this type of technique has been popular, not only in endodontics but also in other branches of dentistry. Endodontics is the specialization in which ultrasound has enabled the most visible advancement to be made. Above all when the use of ultrasonic tips is associated with that of the operative microscope, some stages of endodontic technique have even been modified. For this reason state-of-the-art endodontics cannot today neglect these two fundamental instruments.

#### Corresponding Author:-Afeef Ansar.

Address:-Post graduate student, Department of Conservative Dentistry and Endodontics, Yenepoya Dental College, Yenepoya University, Deralakatte, Mangalore, Karnataka-575018.

The ultrasonic technique is essentially a non-rotary method of cutting dental hard tissue and restorative materials using piezo-electric oscillations. Cutting dentine structure with ultrasonic tips is analogous to cutting dentine with the thinnest bur imaginable.

Ultrasonic instruments play an ever-increasing role in several aspects of endodontic treatment. Teeth with root canal obstructions are no longer automatically treatment planned for surgical endodontics; endodontic retreatment has become the procedure of choice. In addition, root canal obstructions are being removed in a more conservative manner that does not unnecessarily destroy the root structure. The identification of missed and hidden canals has become a predictable outcome rather than a serendipitous discovery. Access cavities are being cut and refined with greater precision, opening up gateways to better endodontics. Above all, these procedures are no longer being performed blindly; instead the clinician is now able to maintain visual contact with the operating field at all times during ultrasonic procedures.

#### **History:-**

The concept of using ultrasonics in endodontics was first introduced by Richman in 1957. However, it was not until Martin et al demonstrated the ability of ultrasonically activated K-type files to cut dentin that this application found common use in the preparation of root canals before filling and also obturation. The term "Endosonics" was coined by Martin and Cunningham and was defined as the ultrasonic and synergistic system of root canal instrumentation and disinfection. Around 1990s, after the introduction of the first ultrasonic tips by Gary Carr, the focus shifted to the use and possible consequences of ultrasonic root-end preparations during apicoectomy.

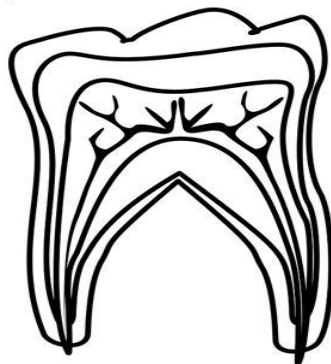The introduction of the piezoelectric device and numerous drawings of ultrasonic tips after 1990 has allowed clinicians to remove dentin or other dental materials in a very controlled and precise manner, using tips that are often approximately the same size as a root canal or smaller. In the same time were introduced in the market tips designed to deliver vibrational energy in a focused manner, without the intention to cut tooth structure.

#### **Application of Ultrasonics in endodontics:-**

Currently ultrasonics in dentistry is mainly used for scaling and root planing of teeth and in root canal therapy. It is also used in dentistry for therapeutic and diagnostic applications as well as for cleaning of instruments before sterilization. The concept of minimally invasive dentistry and the desire for preparations with small dimensions has stimulated new approaches in cavity design and tooth-cutting concepts, including ultrasound for cavity preparation.

The following are the most frequent applications of Ultrasonics in Endodontics-

1. Access refinement, finding calcified canals, and removal of attached pulp stones.
2. Removal of intracanal obstructions (separated instruments, root canal posts, silver points, and fractured metallic posts).
3. Increased action of irrigating solutions.
4. Ultrasonic condensation of gutta-percha.
5. Placement of mineral trioxide aggregate (MTA).
6. Surgical endodontics: Root-end cavity preparation and refinement and placement of root end obturation material.
7. Root canal preparation.




---

#### **Pulp Chamber**

Access refinement, finding calcified canals, removing pulp stones

---

#### **Coronal-middle third**

Removal of intracanal obstructions:  
Separated instruments, root canal posts etc.  
Increased action of irrigating solution  
Placement of MTA  
Condensation of Gutta-percha  
Root canal preparations

---

#### **Apical Third**

Surgical endodontics

**Access Refinement, Finding Calcified Canals, and Removal of Attached Pulp Stones:-**

One amongst the challenges in endodontics is to locate canals, especially the orifices which has become occluded by secondary dentin or calcified dentin secondary to the placement of restorative materials or pulpotomies. The risk of perforating of root in a calcified when performing an access preparation is higher when performed incorrectly and leads to complicating the subsequent procedures. A lack of a straight-line access is arguably the leading cause of separation, perforation, and the inability to negotiate files to the radiographic terminus.

**Advantages of using Ultrasonics over burs:-**

There are many advantages to using ultrasonic tips rather than burs to refine the access cavity to locate the underlying anatomy.

1. Vision- There is no handpiece head to obscure vision and, therefore, the progressive cutting action can be observed directly and continuously under the microscope.
2. Superior control- The size of ultrasonic tips is smaller than the smallest burs, therefore, the dentine can be brushed off in smaller increments and with greater control. The process allows for exposure of any missed or hidden canals or recesses containing necrotic pulp tissue without gutting down the tooth structure. The dentine must be brushed off in smaller increments until the road map on the floor of the pulp chamber is uncovered completely. For pulp chambers that have receded with calcification, the term “uncovering” the floor of the pulp chamber is more appropriate.
3. Cavitation- may be described simply as bubble activity in a liquid, which is capable of generating enough shock waves to cause disruption of remnants of necrotic pulp tissue and any calcific deposits. Thus the access cavities prepared with ultrasonic instruments have a thoroughly washed out and clean appearance.

**Removal of Intracanal Obstructions:-**

Dentist are frequently challenged by endodontically treated teeth that have obstructions such as hard impenetrable pastes, separated instruments, silver points, gutta percha or posts in their roots .

In teeth where endodontic treatment has failed, these obstructions need to be removed to perform nonsurgical retreatment. The various modalities include use of appropriate burs, ultrasonic instruments in direct or indirect contact, peripheral filing techniques in the presence of solvents, chelators, or irrigants, microtube delivery using mechanical adhesion techniques and different kits and extractors.

**Post removal:-**

Ultrasonics have been used since 1970s to aid in removal of post during retreatment. The efficacy and effectiveness of post removal can be dependent upon several factors, such as the depth of embedment of the post into the root, the type and design of post. The material of post fabrication, the type of tooth in which the post is cemented and as well as the luting agent used to cement the post.

Garrido et al has shown that those posts cemented with zinc phosphate and glass ionomer cements may have a retentive force that is easier to disrupt in comparison to resin cements.

A fiber-reinforced composite post has a significantly lower modulus of elasticity than stainless steel or titanium. Therefore, it conducts vibration less efficiently. Resin cements are not friable and do not tend to produce microfractures due to ultrasonic vibration . Hence removing a fibre reinforced post cemented with resin remains a challenge to ultrasonics.

Garrido et al with his study comments that posts cemented with zinc phosphate cement are loosened more easily when water coolant is used, whereas post cemented with resin are loosened more easily without the use of water-coolant. The water helps to dissolve the zinc phosphate cement and the heat along the post, generated during ultrasonic stimulation without water coolant, deteriorates the resin because of its high thermal expansion value.

**Methods:-**

Various methods of post removal are available, and these methods are often combined to maximize loosening of the post, or used sequentially if one method is not making sufficient progress after several minutes of use.

When removing a post, it is critical to break the seal between the post and the tooth structure. It has been recommended to reduce the extraradicular portion of the post to the same diameter as the intraradicular portion. This will reduce the necessary tension required to remove it.

Exposure of the post can be accomplished by using a combination of surgical length #2 and #4 round burs to remove the core material. Ultrasonic tips such as the BUC-1 or BUC-1A can be used to further remove cement and core materials immediately around the post in a circumferential manner without aggressively removing dentin around the orifice and coronal third of the root, as troughing or ditching with large burs around the post can result in the excessive loss of tooth structure. It is important to avoid the furcation area due to the relative thinness of dentin, when applicable.

After troughing, a basic spreader tip can be placed in the trough to break down the integrity of the cement or resin, usually resulting in loosening of the post. Alternatively, the ultrasonic tip can be placed on the post or on a hemostat that is clamped to the post.

In order to vibrate a post, the tip of the ultrasonic instrument, typically a tip such as the ENDO-1 (Dentsply Tulsa), CPR-1 (SybronEndo), VT (SybronEndo), or VibraPost (VP) (B&L Biotech) is set at high power, and the tip placed against the post. The ultrasonic energy transfers to the post as vibrational mechanical energy, and promotes the failure of the cement bond.

When the tip is placed near the cervical region of the tooth at an angle to the post, as opposed to the most incisal position of the post, the force required to dislodge the post is lesser. Many studies also place the ultrasonic tip on the post approximately 2 mm from the tooth structure to maximize the harmonics and conduction of energy.

The ultrasonic tip can also be moved up and down along the post as well as circumferentially to encourage further loosening. After sufficient loosening of the post, the post can be picked out of the canal with Stieglitz forceps or a similar tool.

For posts that have fractured at or near level of pulp floor, or are fully embedded within the root canal and where there is adequate thickness of dentin to expose the coronal portion, a small pointed ultrasonic tip such as the BUC-1, ENDO-2, or ENDO-3 can first be used to create space or a small gutter circumferentially or alongside the post. This may also involve carefully breaking up any visible core and cement materials around the fractured post with the ultrasonic tip. Loosening the fragment in such a manner may dislodge the post. If possible, a post vibration tip such as an ENDO-1, or a scaler tip, can be placed against the exposed portion of the post, as this allows vibrations to be transmitted to the post and will further shatter the integrity of the cement.

#### **Time required for post removal:-**

The amount of time required to sufficiently loosen a post using ultrasonics varies with the multiple factors mentioned that affect post retention. Post dislodgement has been found to occur in as little as 40 s, while other studies have found that often several minutes of ultrasonic use are required, with one study reporting 16 min to be the most effective amount of time. In general terms, if a post is not significantly loosened after 10–15 min of ultrasonic vibration, it may be wise to consider further removal of cement around the post with a thin and long ultrasonic tip, or using a different post removal method.

#### **Risks for post removal:-**

There is possibility of causing cracks and/or fractures of the root dentin during vibration and removal of a post. In a study conducted by Altshul et al on cadaver teeth, there was a statistically significant higher incidence of cracks in those teeth where ultrasonics was used for post removal. However, catastrophic root fracture is a rare occurrence. A survey of endodontic specialists conducted by Castrisos et al, has estimated a root fracture incidence of 0.002%; this group reported ultrasonic use to be the most common method of post removal.

The other risk associated with post removal is the production and conduction of heat from the ultrasonic tip to the post, which can be transmitted to the periodontal attachment apparatus. It is well known that a temperature increase to 47°C for 1 min can cause bone necrosis. It has been shown that as little as 15–20 s of continuous dry ultrasonic instrumentation can contribute to injurious heat trauma, especially when high power settings are used.

Using very short cycles of ultrasonic instrumentation coupled with cooling procedures in between such as copious water irrigation (15 mL/min and 30 mL/min have been recommended by certain studies) can prevent such trauma. Davis et al has suggested using a cotton pellet saturated with Endo-Ice has also been shown to be as effective as copious water cooling.

#### **Silver points and metallic posts:-**

An important point to realize when removing silver points is that one is dealing with a very soft material. Any misdirection of a bur can sever the point, complicating the case even further. Ultrasonics has proven to be very helpful in the removal of these points. Simply trough around the silver point with an ultrasonic spreader tip and carefully eliminate dentin while following the long axis, taking care not to cut the point. The space created around the silver point will usually loosen the silver point, which can then be removed with a Steiglitz forceps or hemostat. At all times, the use of intraoral radiographs is recommended to confirm the position and the remaining length of the obstruction, as well as the thickness of canal walls.

The traditional clinical procedure to remove root canal posts or silver points fractured at the orifice consists of exposing the coronal part of the obstacle by cutting an estimated 2.0-mm trough around the obstacle with a fine diamond bur. The tip of an ultrasonic unit is then applied to the side of the post fragment at full power with water irrigation. Ultrasonic vibration is applied for periods of a few seconds followed by drying with compressed air. This will lead to dislodgement of the fragment of the post, which can then be removed with a fine forceps.

#### **Separated Instruments:-**

The removal of fractured instruments within a root canal has become a safer and more predictable procedure with the use of ultrasonics and the dental operating microscope.

Management of fractured files should be governed by the evaluation of factors such as the location of the file, the root curvature, and the presence of apical disease. Aggressive file removal procedures can induce additional stresses in a tooth that might initiate vertical root fracture.

The success of using ultrasonics alone to remove fractured instruments has been favourable, with studies reporting success rates of 54.4% and as high as 93.3%. Most recent studies use an ultrasonic file removal method that closely follows or is a variation of the Ruddle technique. This technique uses modified Gates Glidden burs (size 3 or 4) to create a "staging platform" at the coronal aspect of the fractured instrument. Then, fine ultrasonic tips of various lengths are used without water to trough around the most coronal part of the instrument in order to expose it, followed by ultrasonic vibration of the instrument fragment to loosen it. Counter-clockwise movements of the tips can also be used to dislodge the fractured file.

Attention must be paid during preparation of a staging platform, because a size 3 or 4 Gates Glidden may perforate or weaken a root, for instance the mesial and distal root of mandibular molars, the distobuccal and mesiobuccal roots of maxillary molars and central and lateral mandibular incisors.

#### **Increased action of irrigating solutions:-**

Use of ultrasonics in endodontics as a supplementary method of irrigant agitation in helping to achieve improved treatment outcomes by enhancing disinfection and dissolution of tissue is becoming well established.

Agitation of the various irrigants used during root canal treatment, whether by ultrasonic, sonic, or manual techniques, has become a routine part of endodontic treatment for many clinicians. It is also seen by some as an additional step or option for teeth with persistent infection, presenting as continuous exudation or haemorrhage.

The effectiveness of irrigation relies on both the mechanical flushing action and the chemical ability of irrigants to dissolve tissue. Furthermore, the flushing action of irrigants helps to remove organic and dentinal debris and microorganisms from the canal. The flushing action from syringe irrigation is relatively weak and dependent not only on the anatomy of the root canal but also on the depth of placement and the diameter of the needle. Ram et al has shown that irrigants can only progress 1 mm beyond the tip of the needle.

Using thinner needles (30 gauge) may facilitate reaching the apical area directly. However, thorough cleaning of the most apical part of any preparation remains difficult especially in narrow or curved canals. The only effective way to clean webs and fins is through movement of the irrigation solution, as they cannot be mechanically cleaned. Ultrasonics is a useful adjunct in cleaning these difficult anatomical features.

The flushing action of irrigants are enhanced by using ultrasonics.. There by improving the efficacy of irrigation solutions in removing organic and inorganic debris from root canal walls.

The tissue-dissolving capability of solutions with a good wetting ability may be enhanced by ultrasonics if the pulp tissue remnants and/or smear layer are wetted completely by the solution and become subject to the ultrasonic agitation.

Ultrasonics creates both cavitation and acoustic streaming. The cavitation is minimal and is restricted to the tip. The acoustic streaming effect, however, is significant. In fact, the irrigant is activated by the ultrasonic energy imparted from the energized instruments, producing acoustic streaming and eddies.

#### **Acoustic streaming:-**

Acoustic streaming is the rapid movement of fluid in a circular or vortex-like motion around a vibrating file. The acoustic streaming that occurs in the root canal during ultrasonic irrigation has been described as acoustic microstreaming. This is defined as the streaming which occurs near small obstacles placed within a sound field, near small sound sources, vibrating membranes or wires, which arise from the frictional forces between a boundary and medium carrying vibrations of circular frequency.

Acoustic streaming, as described by Ahmad et al., has been shown to produce sufficient shear forces to dislodge debris in instrumented canals. When files were activated with ultrasonic energy in a passive manner, acoustic streaming was sufficient to produce significantly cleaner canals compared with hand filing alone.

Ahmad et al confirmed that ultrasonically activated files produced streaming patterns close to the file, continuously moving irrigants around, thereby producing shear stress, which can damage biological cells, as stated by Williams et al.

#### **Cavitation and cavitation microstreaming:-**

Cavitation in the fluid mechanical context can be described as the impulsive formation of cavities in a liquid through tensile forces induced by high-speed flows or flow gradients. These bubbles expand and then rapidly collapse producing a focus of energy leading to intense sound and damage, e.g. pitting of ship propellers and pumps.

Acoustic cavitation can be defined as the creation of new bubbles or the expansion, contraction and/or distortion of pre-existing bubbles (so-called nuclei) in a liquid, the process being coupled to acoustic energy.

Cameron et al postulated that there is a synergistic effect between sodium hypochlorite (NaOCl) and ultrasonics. The ability of NaOCl to dissolve collagen is enhanced with heat therefore, the effect of heat on the irrigant produced by ultrasonic action plays an important role.

#### **Passive ultrasonic irrigation:-**

The technique of ultrasonic activation of an irrigant after instrumentation has been completed has been referred to as passive ultrasonic irrigation. The term passive is used to denote the intention to simply activate the irrigant, and not to cut or contact the dentin with the activated file, thus differentiating it from previous efforts to ultrasonically instrument the root canal walls. During passive ultrasonic irrigation, the irrigant is intermittently replenished using a conventional irrigation syringe.

#### **Continuous ultrasonic irrigation:-**

Continuous ultrasonic irrigation is achieved by simultaneously and continuously delivering irrigation during ultrasonic activation through a water port incorporated into the ultrasonic tip, such as the ProUltra® PiezoFlow™ or the VPro™ StreamClean™ system. Unlike passive ultrasonic irrigation, the replenishment of irrigant with a conventional syringe between ultrasonic file activations is not required.

Continuous ultrasonic irrigation has been shown to be more effective in clearing apically placed debris than other irrigation modalities, such as conventional syringe irrigation, manual dynamic activation, and apical negative pressure. When comparing passive ultrasonic irrigation and continuous ultrasonic irrigation, both modalities have been shown to perform similarly in the removal of debris in a root canal.

**Time of activation:-**

Thirty seconds to 1 minute of ultrasonic activation seems to be sufficient to produce clean canals, whereas others recommend 2 minutes. Shorter passive irrigation time makes it easier to maintain the file in the center of the canal, thus preventing it from touching the canal walls. Syringe delivery of NaOCl every minute was as effective as a continuous flow of NaOCl during 3 minutes of passive ultrasonic irrigation in the removal of dentin debris.

**Removal of intracanal medicaments:-**

The use of a calcium hydroxide paste or similar intracanal paste as an inter-appointment medicament is used during multiple-visit treatments in order to prevent the regrowth of root canal bacteria and has been shown by many studies to improve the long-term outcome of endodontic treatment. Its complete removal from the root canal after it is used during treatment by irrigation is known to be impossible, but generally desired. Residual calcium hydroxide may interfere with sealer penetration into the dentinal tubules.

Studies show passive ultrasonic irrigation to enhance its removal. Ultrasonic activation time varied in these studies, ranging from 8–10 s per canal up to 1 min per canal, so there is no consensus on the amount of agitation time required for maximum removal of an intracanal medicament.

**Ultrasonic Condensation of Gutta-Percha:-**

Ultrasonically activated spreaders have been used to thermoplasticize gutta-percha in a warm lateral condensation technique. Ultrasonic spreaders that vibrate linearly and produce heat, thus thermoplasticizing the gutta-percha, achieved a more homogeneous mass with a decrease in number and size of voids and produced a more complete three-dimensional obturation of the root canal system.

Ultrasonic condensation of gutta-percha is quickly mastered and has several advantages over other warm lateral condensation techniques. It was observed that heat was generated only during ultrasonic activation, and the plugger appeared to cool rapidly once activation ceased. The size of the heat carrier (ultrasonic spreader) can be chosen to match the diameter of the root canal, and the ultrasonic spreader can be curved to match the curvature of the root canal. Furthermore, gutta-percha does not stick to the ultrasonic file when the ultrasonic unit is activated. Also, the low temperature produced by the unit at its lowest power setting may result in less volumetric changes of gutta-percha upon cooling.

The obturation technique recommended when using the ultrasonic techniques consists of initial placement of a gutta-percha cone to the working length followed by cold lateral condensation of two or three accessory cones using a finger spreader. The ultrasonic spreader is then placed into the center of the gutta-percha mass 1 mm short of the working length and activated at intermediate power to prevent charring of root surfaces and fracture of the ultrasonic spreader. After activation, the ultrasonic spreader is removed, and an additional accessory cone is placed, followed by energizing with the activated ultrasonic spreader. This process is repeated until the canal is filled. During each subsequent step, the ultrasonic spreader should be placed slightly more coronally. The ultrasonic spreader must be in the mass of gutta-percha for about 10 seconds to achieve thermoplasticization. Leaving it in the canal for more than 10 seconds can produce a rise in temperature that is damaging to the root surface.

In addition, it has been demonstrated that placement of sealers with an ultrasonically energized file promoted a better covering of canal walls with better filled accessory canals (evaluated by radiography) than placement of sealers with hand instruments.

**Placement of Mineral Trioxide Aggregate (MTA):-**

Witherspoon and Ham et al described the use of ultrasonics to aid in the placement of MTA. The inherent irregularities and divergent nature of some open apices may predispose the material to marginal gaps at the dentin interface. It was demonstrated that, with the adjunct of ultrasonics, a significantly better seal with MTA was achieved. Placement of MTA with ultrasonic vibration and an endodontic condenser improved the flow, settling, and

compaction of MTA. Furthermore, the ultrasonically condensed MTA appeared denser radiographically, with fewer voids.

The recommended placement method consists of selecting a condenser tip, then picking up and placing the MTA with the ultrasonic tip, followed by activating the tip and slowly moving the MTA material down using a 1- to 2-mm vertical packing motion. Direct ultrasonic energy will vibrate and generate a wavelike motion, which facilitates moving and adapting the cement to the canal walls. In a case of repairing a defect apical to the canal curvature.

Ruddle recommends incrementally placing MTA deep into a canal, then shepherding it around the curvature with a flexible trimmed gutta-percha cone utilized as a plugger. A precurved 15 or 20 stainless steel file is then inserted into the material and placed to within 1 or 2mm of the working length. This is followed by indirect ultrasound, which involves placing the working end of an ultrasonic instrument on the shaft of the file. This vibratory energy encourages MTA to move and conform to the configurations of the canal laterally as well as controlling its movement. This technique was recommended initially for placing MTA in open and diverging apices, but it can also be used to put the material in root-end cavities, in perforations, and especially in perforations of the floor of the pulp chamber.

#### **Surgical endodontics: Root-end cavity preparation and refinement and placement of root end obturation material:-**

Surgical endodontic treatment has adopted new materials, new techniques, and benefits from the use of the surgical operating microscope. These changes have resulted in predictable healing and higher incidences of healing than when traditional techniques are used. A recent meta-analysis by Setzer et al indicates that root end surgery performed using a traditional technique results in a 59% positive outcome, while root-end surgery performed using modern microsurgery techniques results in a 94% positive outcome.

Root-end cavities have traditionally been prepared by means of small round or inverted cone burs in a microhandpiece. Since sonically or ultrasonically driven microsurgical retrotips became commercially available in the early 1990s, this new technique of retrograde root canal instrumentation has been established as an essential adjunct in periradicular surgery.

The first root-end preparation using modified ultrasonic inserts following an apicoectomy is attributed to Bertrand et al.

Conventional root-end cavity preparation using rotary burs in a microhandpiece is faced with several problems such as a

1. Cavity preparation not being parallel to the canal,
2. Difficult access to the root end,
3. Risk of lingual perforation of the root.
4. The inability to prepare to a sufficient depth,
5. Compromised retention of the root-end filling material,
6. Root-end resection procedure requires a longer cutting bevel,
7. Exposes more dentinal tubules and isthmus tissue.

The development of ultrasonic and sonic retrotips has revolutionized rootend therapy, improving the surgical procedure with better access to the root end, resulting in better canal preparation.

The most relevant clinical advantages are the :

1. Enhanced access to root ends in a limited working space.
2. Smaller osteotomy for surgical access
3. Deeper and more conservative cavities that follow the original path of the root canal
4. Reduced risk of lateral perforation
5. Does not require a bevelled root-end resection for surgical access
6. Decreased the number of exposed dentinal tubules
7. Minimized apical leakage
8. Enable the removal of isthmus tissue present between two canals within the same root
9. Produces less smear layer



10. Timesaving technique
11. Lower failure rate

Fracture of the ultrasonic tip 2–3 mm from the end is possible with use and coincides with the bend, which can be acutely angled at 75° or 80° in certain surgical tips. In a study by Walmsley et al. the breakage of ultrasonic root-end preparation tips was investigated and attributed to the design of the tip. Increased angulation of retrotips increases the transverse oscillation and decreases the longitudinal oscillation, putting the greatest strain at the bend of the instrument.

While the widely-used diamond coated retrotip has been found to be effective due to its abrasive properties, the recently introduced stainless steel micro projection has been found to be equally effective. The diamond coated retrotips can lose a significant portion of the diamond particles after repeated use.

One concern with the use of ultrasonic retrotips for cavity preparation is the possible creation of cracks at the root-end, although the clinical impact is not exactly clear. Some studies indicated that this was a possible drawback, other studies however, disputed these findings and did not report a higher prevalence of microfractures.

It is recommended that the ultrasonic unit be set at medium power and the cavities be prepared to a depth of 2.5-3 mm. This depth allows for a minimum thickness of material that can still provide an effective apical seal. The cavity walls should be parallel and follow the anatomic outline of the pulpal space. It has also been suggested that root-end cavities should be initiated with a diamond-coated retrotip, using its better cutting ability to provide the main cavity. This aids in the removal of root canal obturation materials and should be followed by a smooth retrotip to smooth and clean cavity walls.

A condenser tip ultrasonically activated can be utilized for placement of retrograde filling materials, as the ultrasonic vibration is meant to improve the flow, settling and compaction of these materials to rootend dentinal walls. This should improve the delivery of materials into the cavity thus enhancing their seal. Ultrasonic tips can also be used to polish root end material and apical surfaces. Utilizing specific ultrasonic tips for refinement of the external radicular surface may be beneficial in the elimination of extraradicular bacteria, which may be responsible for infection.

#### **Root canal preparations:-**

Ultrasonic devices were introduced for use in root canal preparation in 1957 by Richman. In 1980, Martin et al. demonstrated the ability of ultrasonically activated K-type files to cut dentin. A commercial ultrasonic unit, designed by Cunningham and Martin was introduced in 1982. Barnett et al. and Tronstad et al. were the first to report on its use in endodontics.

#### **Method:-**

1<sup>st</sup> Technique: This technique emphasizes direct physical contact of the file with the canal wall for the shaping procedure. Here the canal is ultrasonically filed in rasping action

A 10 K-file and a 15 K-file was used by hand to working length.



Then the 15 K-file was placed into the ultrasonic file adaptor, placed into the canal and activated, moving in a push-and-pull motion for approximately 1 min until the working length was reached.



Then, the 20 K-file was placed into the ultrasonic adaptor, and this was repeated with sequentially larger files until the desired apical size was reached.

Other instrumentation techniques in addition to step-back procedures, such as step-down or other modifications have been reported as well.

**Modified Technique: -**

All steps are followed as mentioned above and on completion of instrumentation a #15 endosonic file is inserted into canal to full working length and allowed to oscillate freely at a power setting of 2.5 for 5 minutes with free flow of 1% NaOCl. Extreme care is taken to prevent any physical contact with the walls of root canal by positioning the file in the centre of root canal.

Endosonic file generates acoustic streaming, but qualitatively the velocity of streaming depends on several factors ;

Position along the file – higher streaming velocity is observed at apical region of file where the radius is smaller.

Power setting: Increased streaming velocity occurred with higher power settings.

**Size of file:-**

Smaller the file size – increased velocity.

High efficiency of ultrasonics in dentin removal with reduced operator fatigue raised the hope that it would be an ideal power driven device for root canal preparation. However, the results achieved by the ultrasonic units have ranged from outstanding to disappointing. The explanation for such wide variance in results lies in the difficulty of controlling the exact position of the tip and also the vibration of the file inside the canal. This decreases its hope as a precise tool for root canal preparation, particularly in the apical part. One of the problems with the ultrasonic units is their choice of enlarging instrument – the K file. These files are made to function best in a push-pull, in and out motion. The action of the ultrasonic units, however is an oscillating side-to-side, transverse motion. Walmsley and Williams suggested that the devices would work much better if the transverse motion could be changed to an up and down, longitudinal oscillation. May be rather than change the configuration of motion, the problem would be better solved by changing the canal instruments into a shape that functions better in an oscillating fashion.

**Advantages:-**

1. Greater amount of debris is removed by ultrasonic use in teeth with open apices and necrotic pulps, those with chronic lesions, and teeth that have been left open for long periods that need to be reclosed.
2. The ultrasonic unit is quite useful in preparing teeth for retreatment because of its ability to gain a cleaner environment.

**Disadvantages:-**

1. The creation of irregular canal shapes, straightening and transportation of the canal—more than is seen with hand instrumentation. Pre-curving the ultrasonic files was reported to help prevent transportation and aid in creating a continuous canal shape.
2. The frequent need to enlarge the canal by hand in order to accommodate the next endosonic file.
3. The lack of tactile sensation.
4. The risk of file fracture if the tip gets bound during use.
5. The time required for ultrasonic instrumentation is also significantly longer than hand instrumentation.
6. In the mesial roots of molars proper care should be shown as Ultrasonic may cause strip perforations.
7. Ultimately, the preparation of root canals with rotary endodontic files allows clinicians to efficiently produce a well centered and more tapered preparation in comparison to ultrasonic or hand instrumentation, and ultrasonically activated files are no longer used with the intent to instrument or remove dentin from root canal walls.

It has been reported that many factors such as power setting, the interfacial force between the file and dentin, direction of file oscillation, root canal geometry, type of irrigant and the super imposition of operator assisted movement of the file may affect the final shape of the preparation.

There is a relative inefficiency of ultrasounds in debridement of the canals, Ultrasonic instrumentation as the sole modality of root canal shaping and tapered preparation has not been overwhelmingly adapted by clinicians. It cannot be used as initial instrument but if used judiciously along with hand instruments, ultrasonics may be a useful adjunct for root canal preparation.

Despite the multitude of studies conducted on ultrasonic root canal preparation with ultrasonically activated files, the current consensus is that this is not a viable clinical technique.

## Conclusion :-

Ultrasonics offers many applications and advantages in clinical endodontics. Improved visualization combined with a more conservative approach when selectively removing tooth structure, particularly in difficult situations in which a specific angulation or tip design permits access to restricted work areas, offers opportunities that are not possible with conventional treatment. As a result, access refinement, location of calcified canals, and removal of separated instruments or posts have generated more predictable results. In addition, better action of irrigation solutions and condensation of gutta-percha have benefited from the use of Ultrasonics. Rootend cavity preparation followed by placement of materials in an area that is more often than not constrained has especially improved the quality of treatment and long-term success. Finally, integration of new technologies such as ultrasonics, leading to improved techniques and use of materials, has changed the way endodontics is being practiced today.

## References :-

1. Park E.(2013): Ultrasonics in endodontics. *Endodontic Topics*.;29(1):125–59.
2. PLOTINO G, PAMEIJER C. (2007): Ultrasonics in Endodontics: A Review of the Literature. *JOE*.;33(2):81-95.
3. Arnau A, Soares D.(2004): Fundamentals of piezoelectricity. In: Vives AA, ed. *Piezoelectric Transducers and Applications*. Berlin, Germany: Heidelberg,; 1–37.
4. Gary Glassman, Sam Kratchman (2011): Ultrasonic in endodontics luxury or necessity in *Endodontics Dent Today*, September 14:13.
5. M.K Iqbal(2004): Nonsurgical Ultrasonic Endodontic Instruments *Dent Clin N Am*48, 19–34.
6. Ajit Shaligram(2014): Role of ultrasonics in endodontics, *BUJOD*, September 2 Vol. 4 Issue-3.
7. Dr. Fabio Gorni(2006): The Use of Ultrasound in Endodontics, *Inside Dentistry*, May Volume 2, Issue 4.
8. L. W. M. Van der Sluis (2007): Passive ultrasonic irrigation of the root canal: A review of the literature, *International Endodontic Journal*, 40, 415–426.
9. Nai r PNR, Henry S, Cano V, Vera (2005): Microbial status of apical root canal system of human mandibular first molars with primary apical periodontitis after one visit endodontic treatment. *J Oral Surgery, Oral Medicine, Oral Pathology, Oral Radiology and Endodontics*99, 231–52.
10. Wu MK, van der Sluis LWM, Wesselink PR(2003): The capability of two hand instrumentation techniques to remove the inner layer of dentine in oval canals. *International Endodontic Journal* 36, 218–24.
11. Ahmad M, Pitt Ford TR, Crum LA(1987): Ultrasonic debridement of root canals: acoustic streaming and its possible role. *Journal of Endodontics a* 14, 490–9.
12. Ahmad M, Pitt Ford thr, Crum LA (1987): Ultrasonic debridement of root canals: an insight into the mechanism involved. *Journal of Endodontics b* 13, 93–100.
13. Ahmad M, Pitt Ford TR, Crum LA, Walton AJ(1988 ): Ultrasonic debridement of root canals: acoustic cavitation and its relevance. *Journal of Endodontics* 14, 486–93.
14. Lumley PJ, Walmsley AD, Walton RE, Rippin JW (1993): Cleaning of oval canals using ultrasonic or sonic instrumentation. *Journal of Endodontics* 19, 453–7.
15. Luc van der suis (2007): *Ultrasound in endodontics Endo*,1(1):29-36.
16. Gianfranco De Paolis, Valentina Vincenti (2010): Ultrasonics in endodontic surgery: a review of the literature .*Annali di Stomatologia* Apr-Jun; 1(2): 6–10.
17. John Wiley & Sons A/S (2013): *Ultrasonics in endodontics Endodontic Topics* 2013, 29, 125–159 . Published by John Wiley & Sons Ltd 1601-153.
18. Cohen *Pathways Of Pulp* 10th edition chapter 21 Periradicular Surgery Bradford R. Johnson, Mohamed I. Fayad, And David E. Witherspoon pg no 750 , 75.
19. Gutmann *Surgical endodontics* James L. Gutmann , John W. Harrison chapter 8 periradicular curettage, Root end resection, Root end filling pg 221, 222.
20. Ingle 6th edition Chapter 33 endodontic surgery Gerald N. Glickman, Gary , R. Hartwell pg no 1256,1257.
21. Franklin S Weine *endodontic therapy* 6th edition chapter 9 Periapical surgery ;intraoral imaging & its use with surgery & other procedure pg 386, 392,393.
22. Cohen chapter 25 *Nonsurgical Retreatment* robert s. roda and bradley h. gettleman pg 903, 904.
23. Lea SC, Walmsley AD.( 2009): Mechano-physical and biophysical properties of power-driven scalers: driving the future of powered instrument design and evaluation. *Periodontol* 2000: 51: 63–78.
24. Yousefimanesh H, Robati M(2012): A comparison of magnetostrictive and piezoelectric ultrasonic scaling devices: an in vitro study. *J Periodontal Implant Sci*: 42: 243–247.

25. Clark SM.(1969): The ultrasonic dental unit: a guide for the clinical application of ultrasonics in dentistry and in dental hygiene. *J Periodontol*: 40: 621–629.
26. Bains VK, Mohan R (2008): Properties, effects and clinical applications of ultrasound in periodontics: an overview. *Perio*: 5: 291–302.
27. Antonio AG, Primo LG, Maia LC (2005): Case report: ultrasonic cavity preparation—an alternative approach for caries removal in paediatric dentistry. *Eur J Paediatr Dent*: 6: 105–108.
28. Vieira ASB, Santos dos MPA (2007): Preparation time and sealing effect of cavities prepared by an ultrasonic device and a highspeed diamond rotary cutting system. *J Oral Sci*: 49: 207–211.
29. Vanderlei AD, Borges ALS, Cavalcanti BN, Rode SM.(2008): Ultrasonic versus high-speed cavity preparation: Ultrasonics in endodontics 151 analysis of increases in pulpal temperature and time to complete preparation. *J Prosthet Dent*: 100: 107–109.
30. Busslinger A, Lampe K, Beuchat M, Lehmann B(2001): A comparative in vitro study of a magnetostrictive and a piezoelectric ultrasonic scaling instrument. *J Clin Periodontol*: 28: 642–649.
31. Walmsley AD (1987): Ultrasound and root canal treatment: the need for scientific evaluation. *Int Endod J*:20: 105–111.
32. Bertrand G, Festal F, Barailly R (1976): Use of ultrasound in apicoectomy. *Quintessence Int*: 7: 9–12.
33. Plotino G, Pameijer CH, Grande NM (2007): Ultrasonics in endodontics: a review of the literature. *J Endod*: 33: 81–95.
34. Felver B, Landini G, Walmsley AD (2009): Three-dimensional analyses of ultrasonic scaler oscillations. *J Clin Periodontol*: 36: 44–50.
35. ENRICO CASSAI(2016):ULTRASONICS IN ENDODONTICS: PART 1. June 2016 *Style italiano*.
36. ENRICO CASSAI(2016):ULTRASONICS IN ENDODONTICS: PART 2. June *Style italiano*.
37. Deepak Ranjan Dalai (2014):Modern Concepts of Ultrasonic Root Canal Irrigation. *International Journal of Advanced Health Sciences* | August | Vol 1 | Issue 4.
38. Fabio Gorni (2006): The Use of Ultrasound in Endodontics. *Roots international magazine of endodontology*.